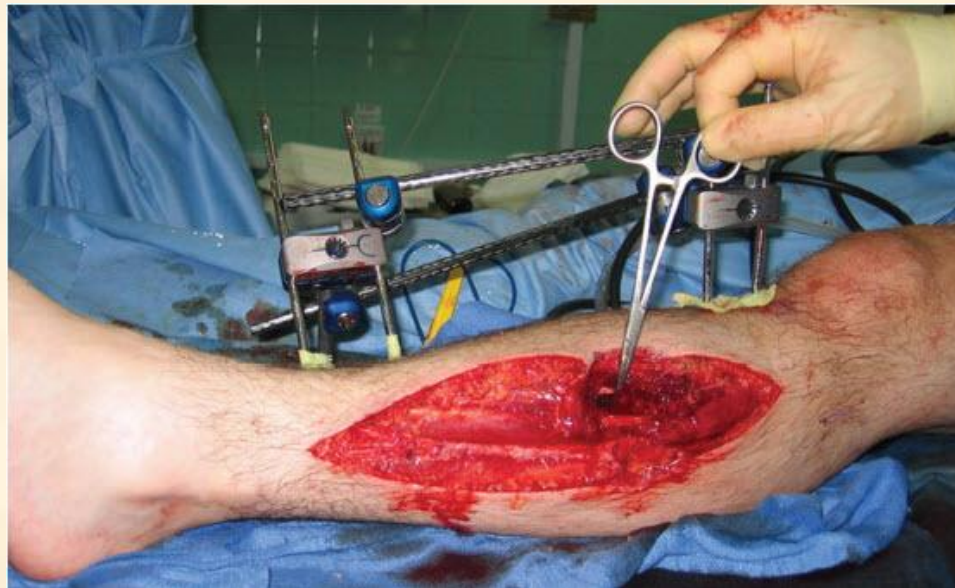

FRACTURE MANAGEMENT AND PRIMARY CARE



Description

- A fracture is a disruption or break in the continuity of the structure of bone
- The extent of damage to the fracture can be complete in which the bone is broken completely, and incomplete, when there is only a bone fracture or crack it.

On the basis of Etiology:

1. Traumatic fractures

Most common type of fractures

Road accidents, falls, fight, etc.

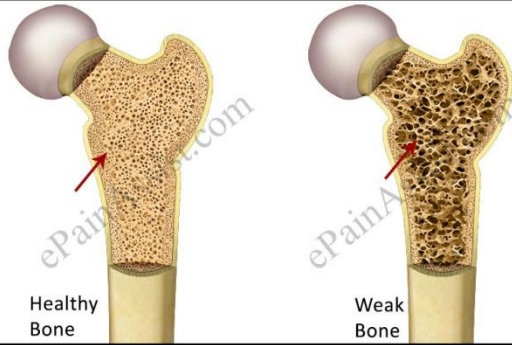
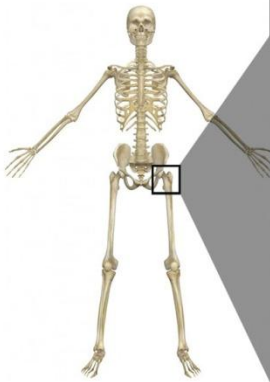
2. Pathological fractures

Bone made weak by some underlying disease

3. Stress fractures

Most **stress fractures** are caused by overuse and repetitive activity, and are common in runners and athletes who participate in running sports, such as soccer and basketball.

Secondary Bone Cancer

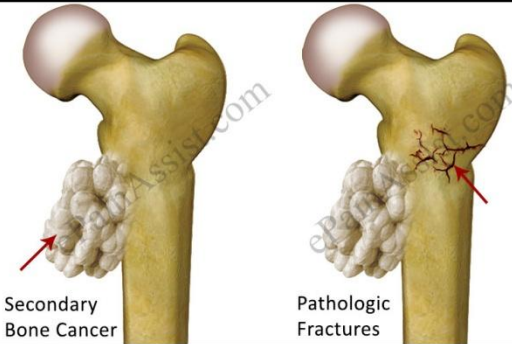


Healthy Bone

Weak Bone

Fractures caused as a result of Secondary Bone Cancer or spread from primary cancer are called as pathologic fractures.

For More Information, Visit: www.epainassist.com

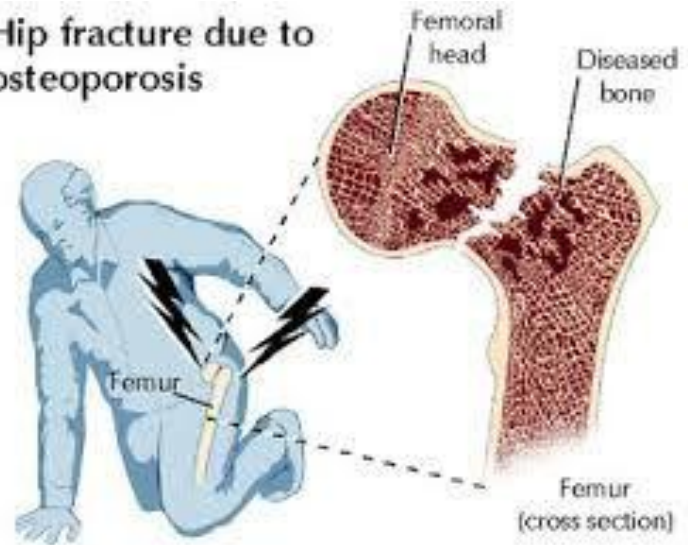


Secondary Bone Cancer

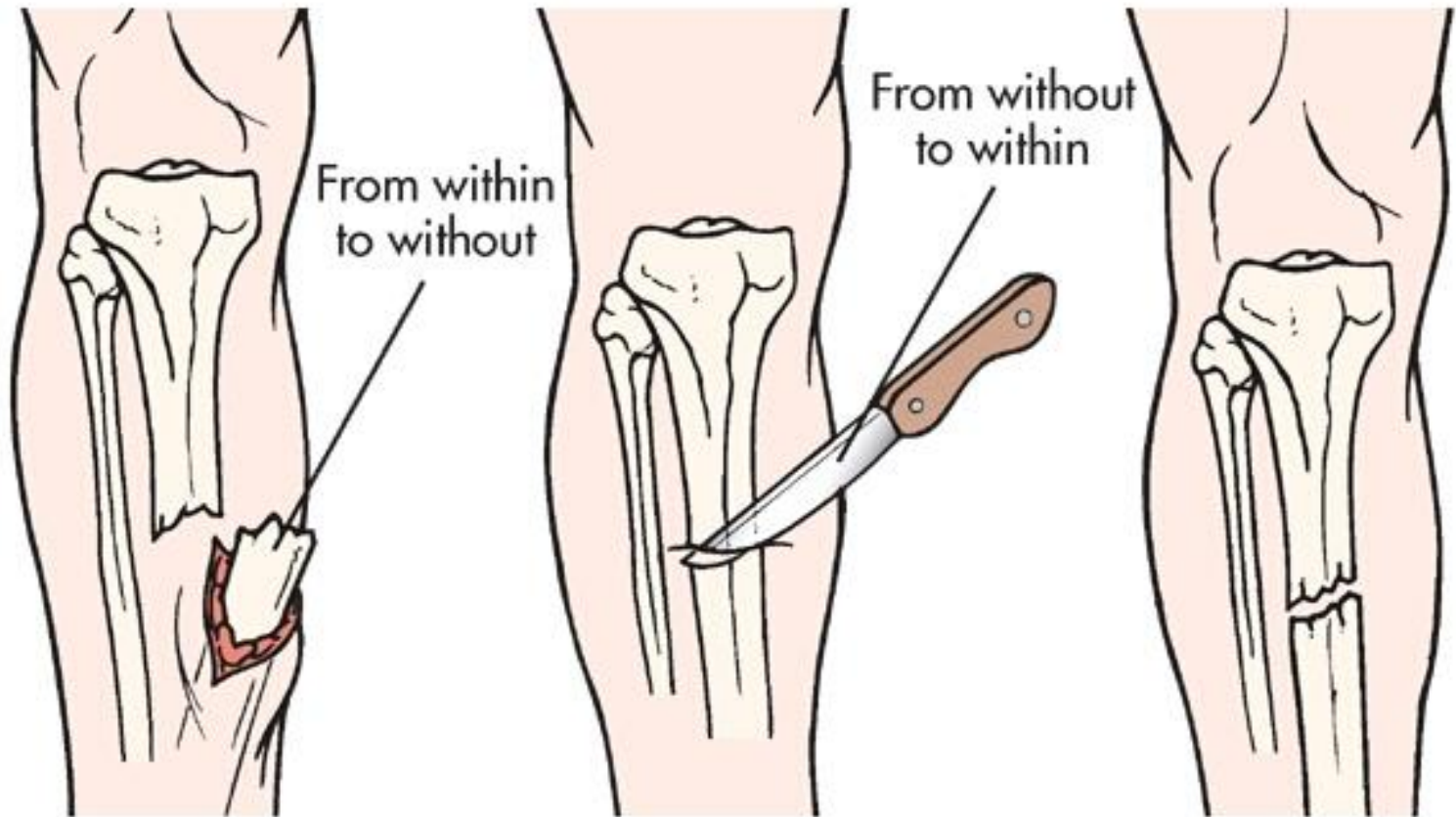Pathologic Fractures

Visit: www.epainassist.com

Hip fracture due to osteoporosis



Classification by Communication with External Environment



Open fracture

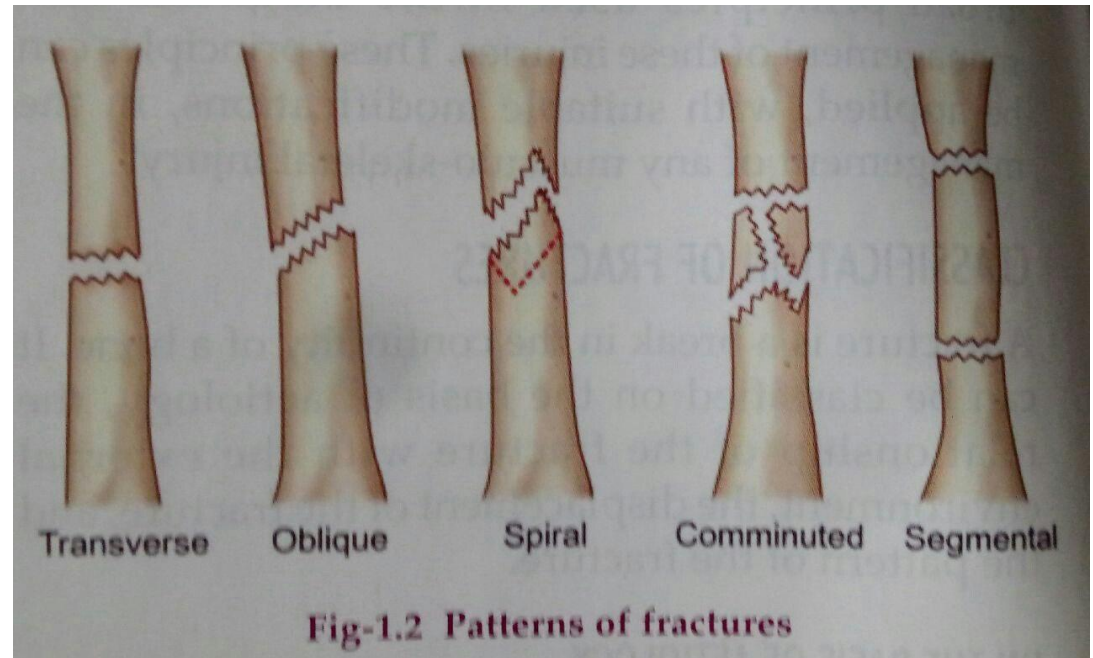
Closed fracture

On the basis of complexity of fractures:

- Simple fractures
- Complex fractures

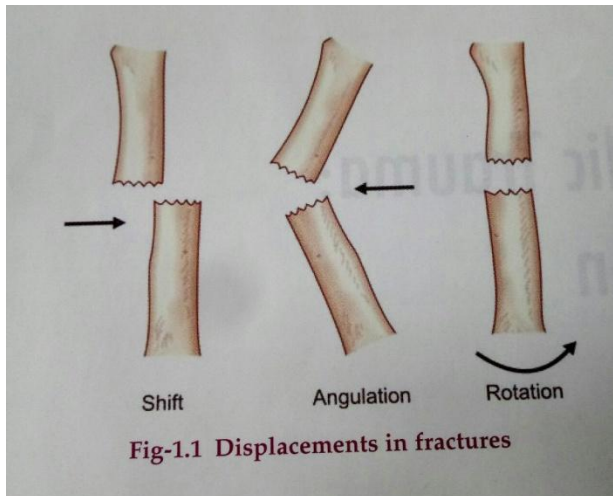
On the basis of Pattern:

- Transverse fracture
- Oblique fracture
- Spiral fracture
- Comminuted fracture
- Segmental fracture



On the basis of Displacements:

- Undisplaced fracture
- Displaced fracture



Signs of bone fractures

- Strong swelling,
- bruising,
- sometimes the limb is bent outside the joint; with an open fracture,
- the bone ends may protrude from the wound.
- With casual movements, you can notice the abnormal movement of the limb in the place where there is no joint;
- sometimes you hear the crunch from rubbing bone.

Closed Fractures

- There are closed fractures in which skin integrity is not broken.

Treatment of fractures can be considered in 3 phases:

- PHASE I: EMERGENCY CARE
- PHASE II: DEFINITIVE CARE
- PHASE III: REHABILITATION

EMERGENCY CARE

- At the site of Accident

RICE

Rest to the
part, by
Splinting

Ice therapy,
to reduce
occurrence
of Swelling

Compressio
n,
To reduce
Swelling

Elevation, to
Reduce
Swelling

Rest is done by
“SPLINTING”

Purpose

- Reduce pain
- Reduce bleeding and swelling
- Prevent further soft tissue damage
- Prevent vascular constriction

What to splint

- ✓ Fracture
- ✓ Dislocation
- ✓ Tendon rupture

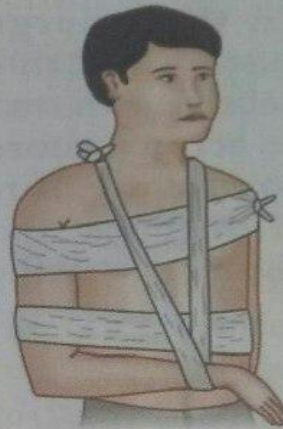
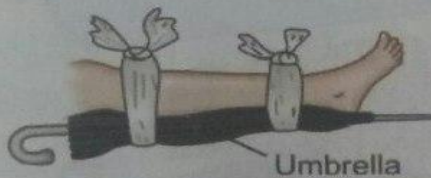
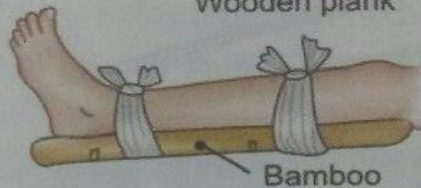
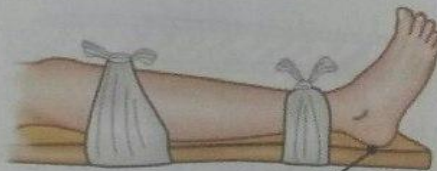
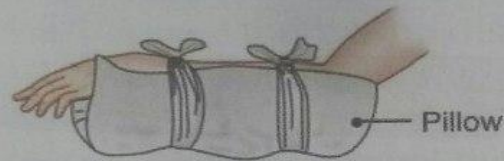
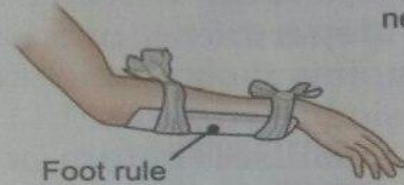
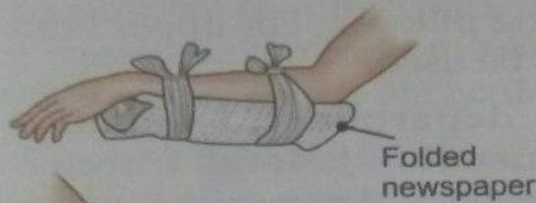
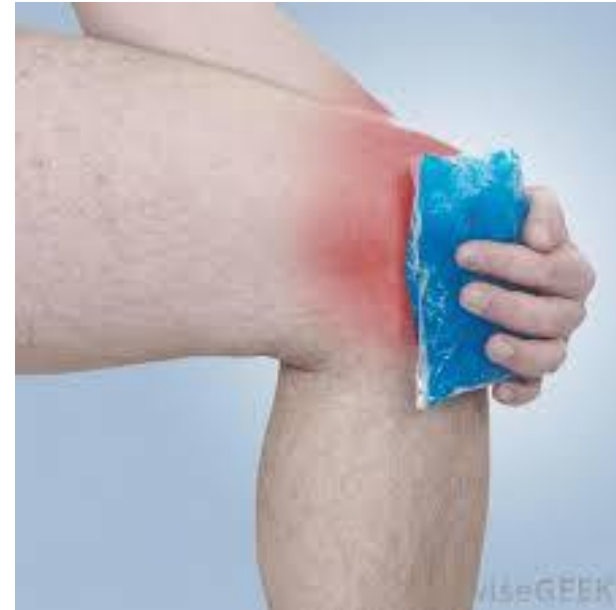
Fig-3.1 Some of the commonly available articles used for splintage of fractures

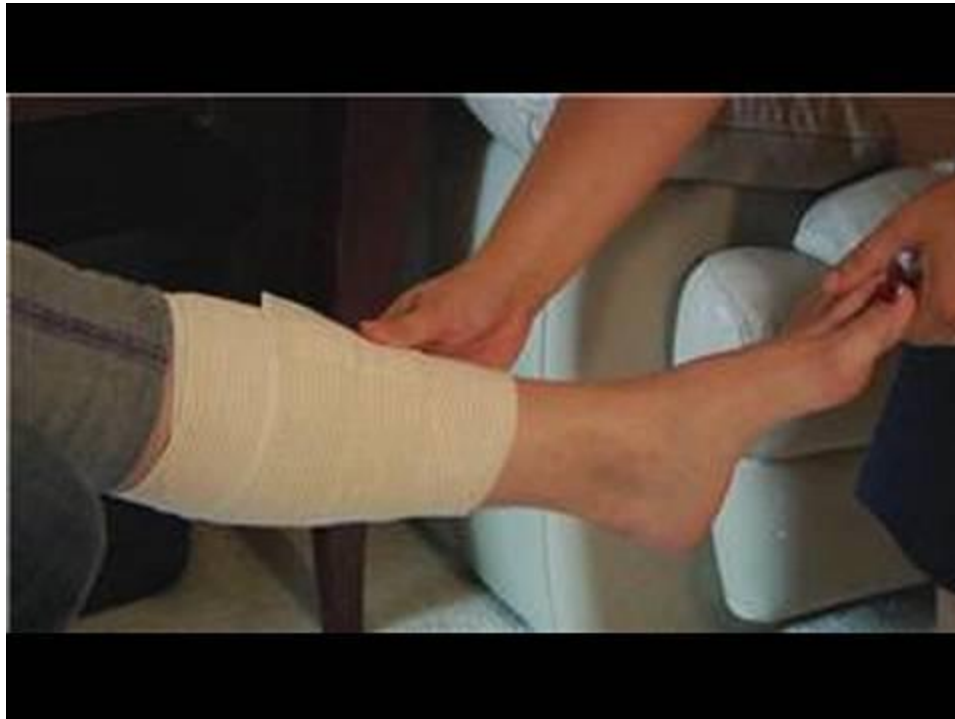Ice therapy

- An immediate application of ice to the injured part reduces pain and swelling.
- Done by taking crushed ice in a polythene bag, and covering it with a wet cloth, or simply commercially available ice pack can be used.
- If any wound is present then it has to be covered with a sterile clean cloth.



Compression

- A crepe bandage is applied over the injured part, making sure that it is not too tight.

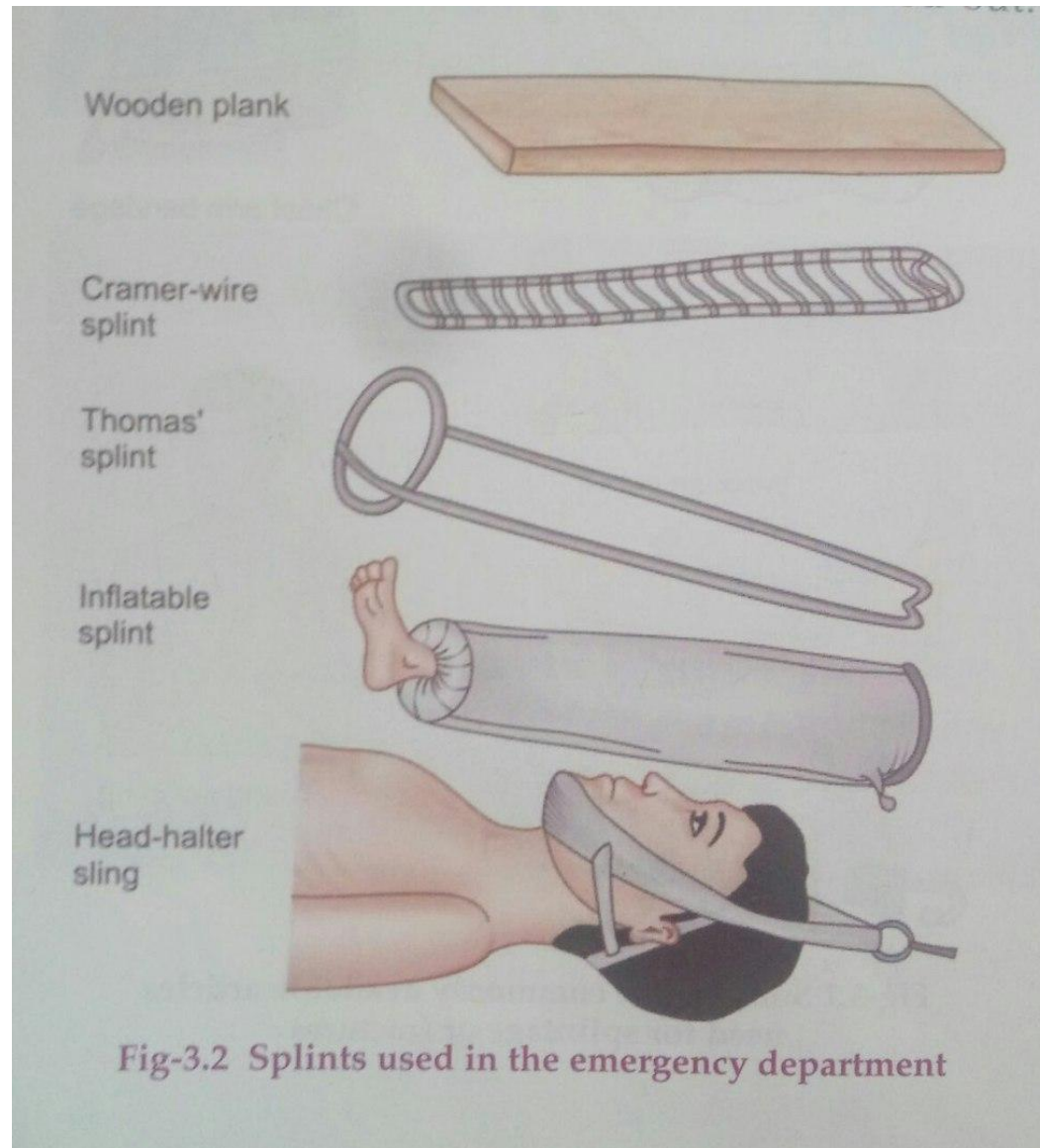


Elevation

- Limb is elevated so that the injured part is above the level of the heart.
- Can be done using pillows or slings.



- In the Emergency Department:



Open fractures

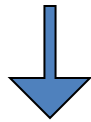
- An open fracture can be defined as 'a break in the skin and underlying soft tissue leading directly into, or communicating with, a fracture or its hematoma.
- Estimated Annual frequency = 11.5 per 100,000

- Results from high-energy trauma, often with extensive soft tissue injury and contamination.
- Therefore, they carry a much higher rate of non-union, deep infection and implant failure than closed injuries.

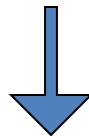
Table-3.4: Modified Gustilo and Anderson Classification for open fractures

| Type | Description |
|------|--|
| I | Skin wound less than 1 cm Clean Simple fracture pattern |
| II | Skin wound more than 1 cm Soft-tissue damage not extensive No flaps or avulsions Simple fracture pattern |
| III | High-energy injury involving extensive soft-tissue damage Or multi-fragmentary fracture, segmental fractures, or bone loss irrespective of the size of skin wound Or severe crush injuries Or vascular injury requiring repair Or severe contamination including farmyard injuries A later modification subdivided type III injuries based on the degree of contamination, the extent of periosteal stripping and the presence of vascular injury. IIIA. Adequate soft-tissue cover of bone despite extensive soft-tissue damage IIIB. Extensive soft-tissue injury with periosteal stripping and bone exposure Major wound contamination IIIC. High-energy injury involving extensive soft-tissue damage |


Debride the wound








Stabilise the wound

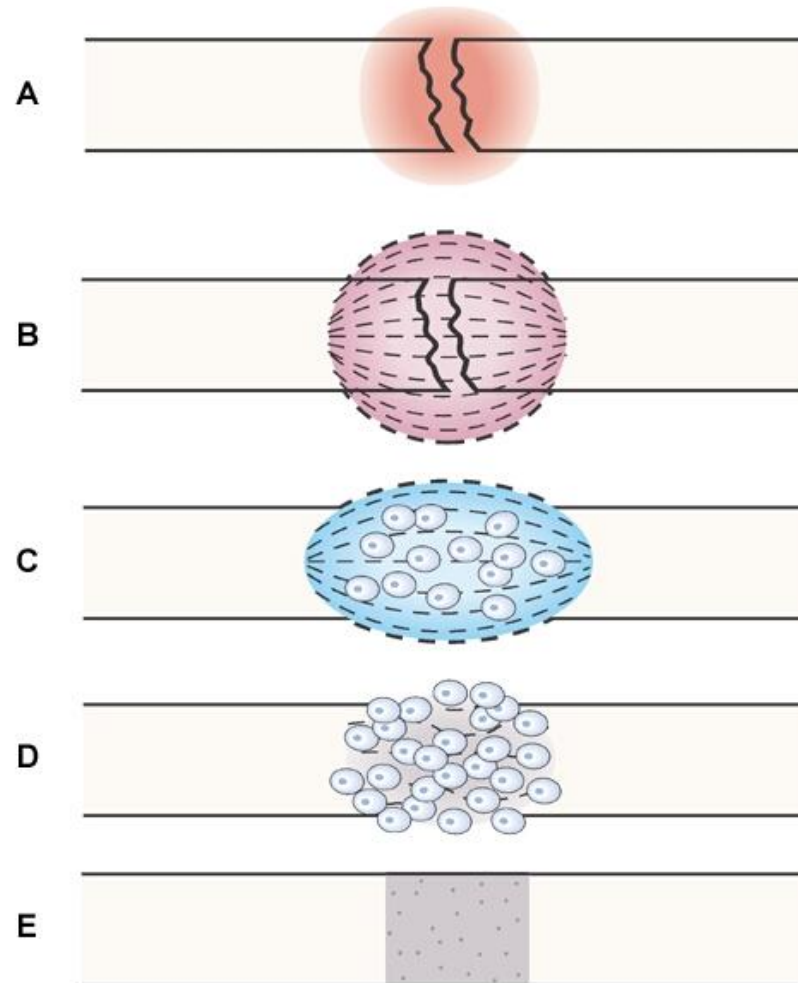


Cover the defect



| Stage of healing | Approximate time | Essential features |
|--|------------------|---|
| Stage of haematoma  | Less than 7 days | Fracture end necrosis occurs. Sensitisation of precursor cells. |
| Stage of granulation tissue  | Up to 2-3 weeks | Proliferation and differentiation of daughter cells into vessels, fibroblasts, osteoblasts etc. Fracture <i>still mobile</i> . |
| Stage of callus  | 4-12 weeks | Mineralisation of granulation tissue. <i>Callus</i> radiologically visible. Fracture clinically united, <i>no more mobile</i> . |
| Stage of remodelling  | 1-2 years | Lamellar bone formation by multicellular unit based remodelling of callus. Outline of callus becomes dense and sharply defined. |
| Stage of modelling  | Many years | Modelling of endosteal and periosteal surfaces so that the fracture site becomes indistinguishable from the parent bone. |

Bone Healing



Redrawn from Long B, Phipps W, Cassmeyer V: *Medical-surgical nursing: a nursing process approach*, St. Louis, 1993, Mosby.

Copyright © 2004, 2000, Mosby, Inc. All Rights Reserved.

Thank you for attention 😊