

Карагандинский Государственный Медицинский Университет
Кафедра иностранных языков

СРСП
Lobular Pneumonia
Modal verb

Выполнила: Семашко Е. 2-067

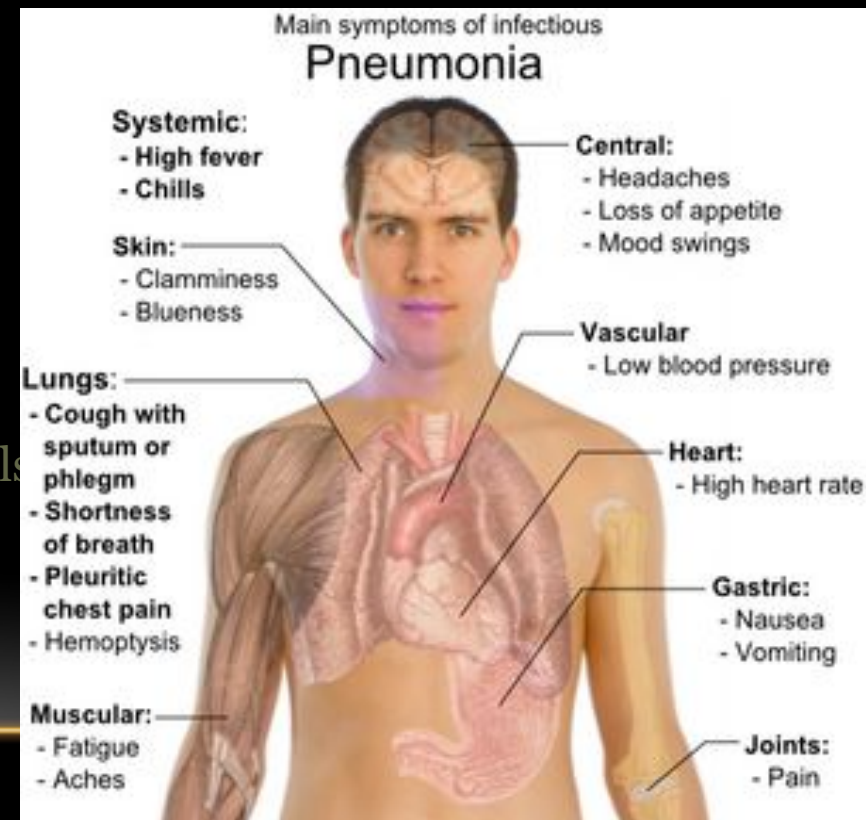
Проверила: Дашкина Т.Г.

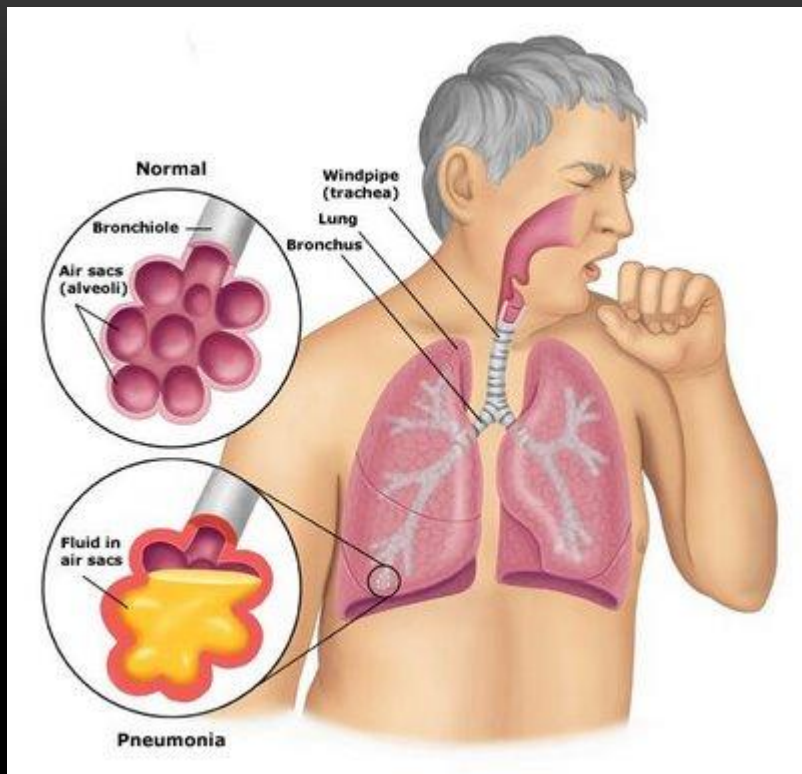
Lobular Pneumonia

Pneumonia is an acute exudative inflammation secondary to airborne infection with bacteria, viruses or mycoplasma.

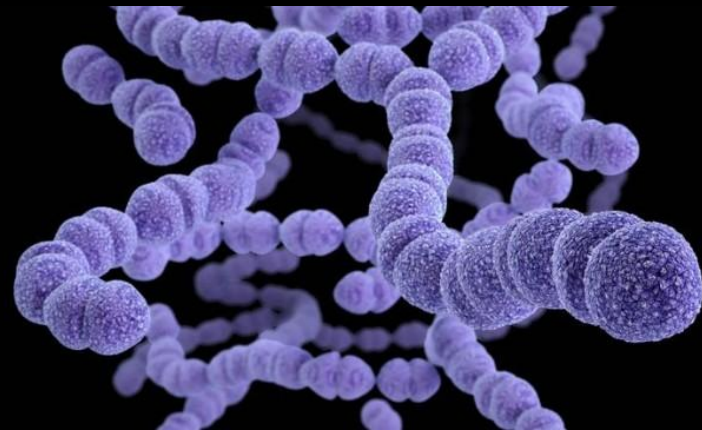
Depending on the extent of lesions, pneumonia can be :

- lobular (a lobe segment is affected)
- lobar (an entire lobe is affected)
- bronchopneumonia (affects bronchioles and adjacent alveoli)
- interstitial (inflammation affects the interstitial tissue, mainly the alveolar walls)





Lobar pneumonia is an acute exudative inflammation of an entire pulmonary lobe, produced in 95 % of cases by *Streptococcus pneumoniae* (pneumococci).



SCIENCE PHOTO LIBRARY

If not treated, lobar pneumonia evolves in four stages. Common to all stages is the enlargement of the affected lobe with loss of its spongy appearance.

Modal

Verbs

Modal verbs (can, could, must, should, ought to, may, might, will, would, shall) are modal auxiliary verbs that express ability, necessity, obligation, duty, request, permission, advice, desire, probability, possibility, etc. Modal verbs express the speaker's attitude to the action indicated by the main verb.

Example:

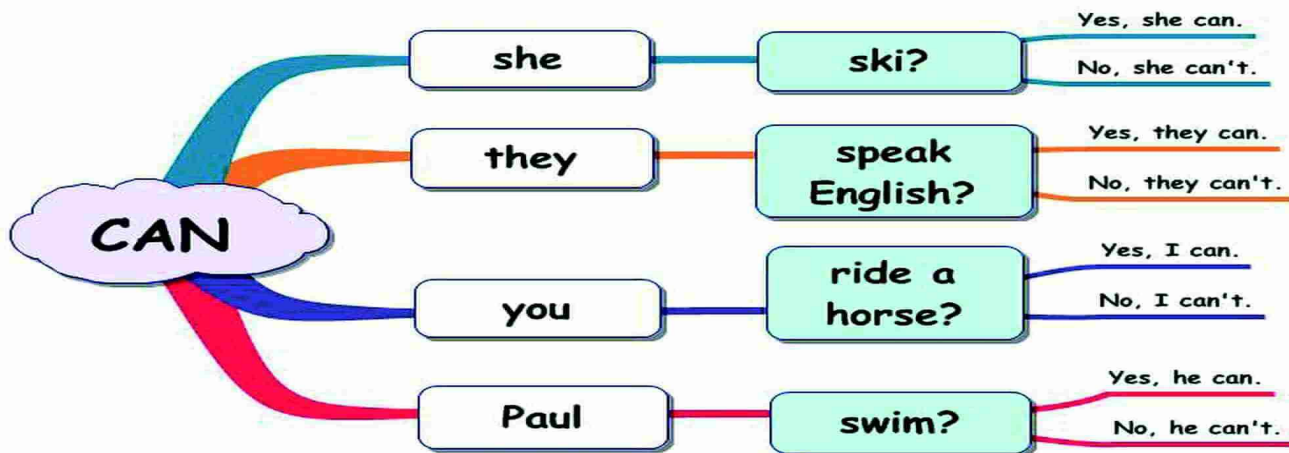
- She can drive (Она может водить машину)
- I must go (я должен идти)
- You should call him (вам следует позвонить ему)
- You may stay here (вы можете остаться здесь)
- I would like to see her (я хотел бы увидеть ее)
- He must be at the tennis club now (он, наверное, в теннисном клубе сейчас)

"Can" is one of the most commonly used modal verbs in English. It can be used to express ability or opportunity, to request or offer permission, and to show possibility or impossibility.

Modal verb CAN



Questions



C
A
N

Pneumonia **can** develop gradually

The patient's breathing **can** become more frequent

Cyanosis **can be** associated with the accompanying bronchitis, decrease in the respiratory surface and occlusion of numerous bronchioles and alveoli.

The patient **can** complain of the pain in the chest.

The blood analysis **can** reveal leukocytosis.

The urine **can** contain a small amount of protein and erythrocytes.

The X-ray examination of the lungs **can** reveal numerous foci of inflammation or various size, irregular form and different intensity.

The liver and spleen were **can** enlarged.

Patient's condition didn't **can** improve
