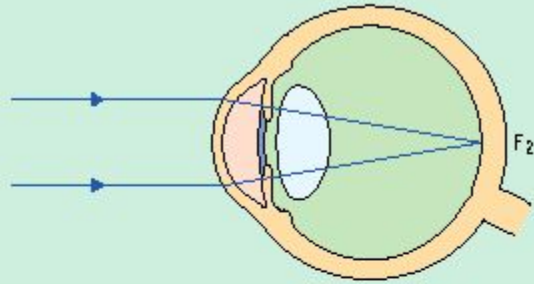


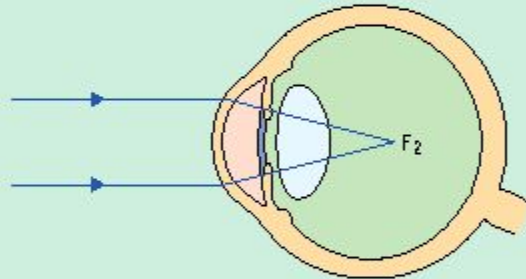
РЕФРАКЦИЯ. АККОМОДАЦИЯ

EMMETROPIA, MYOPIA, AND HYPEROPIA

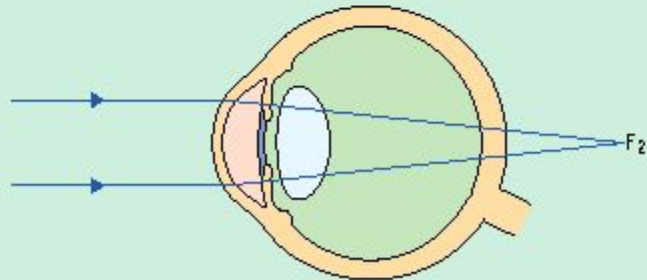
Emmetropia

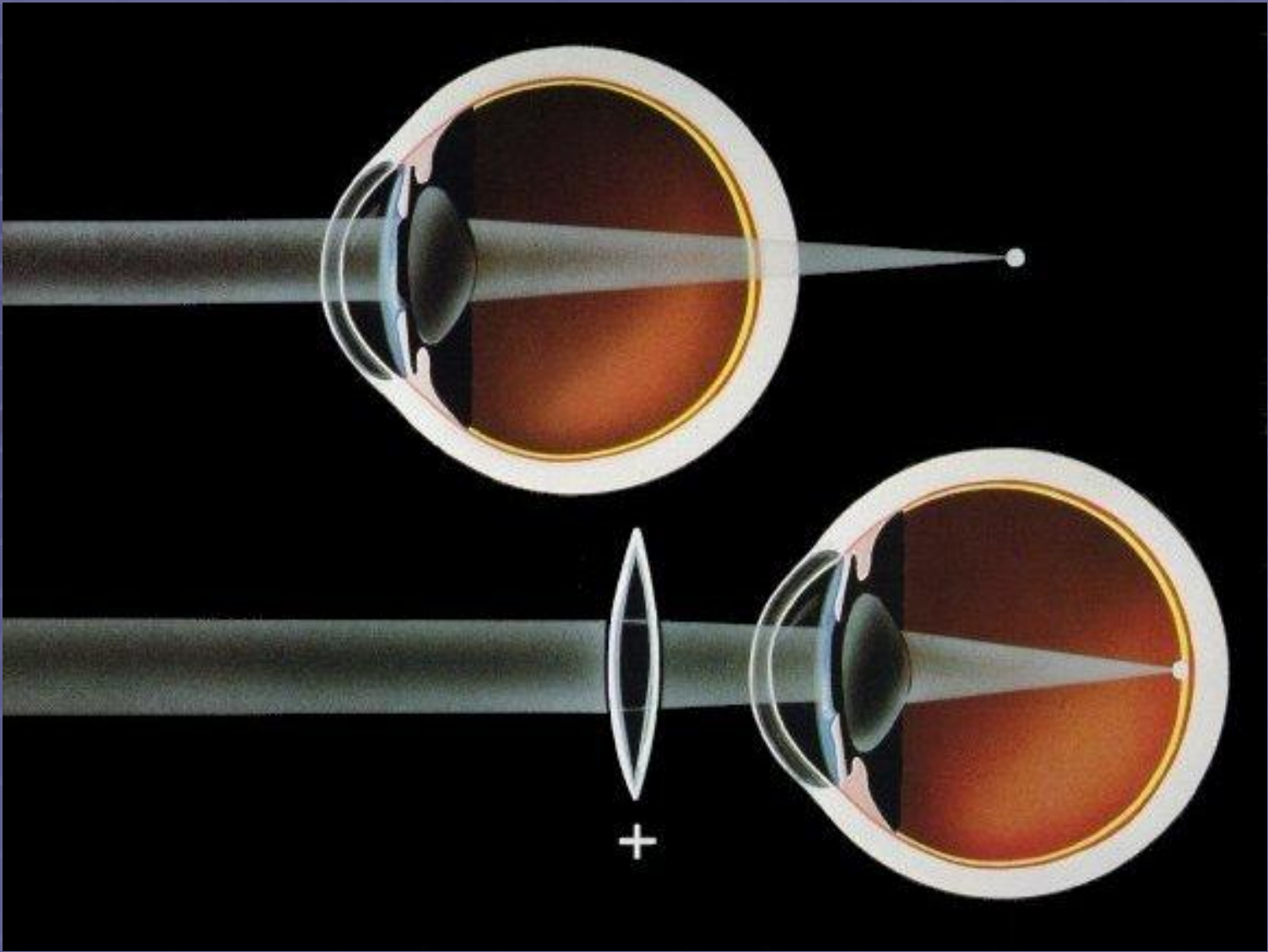


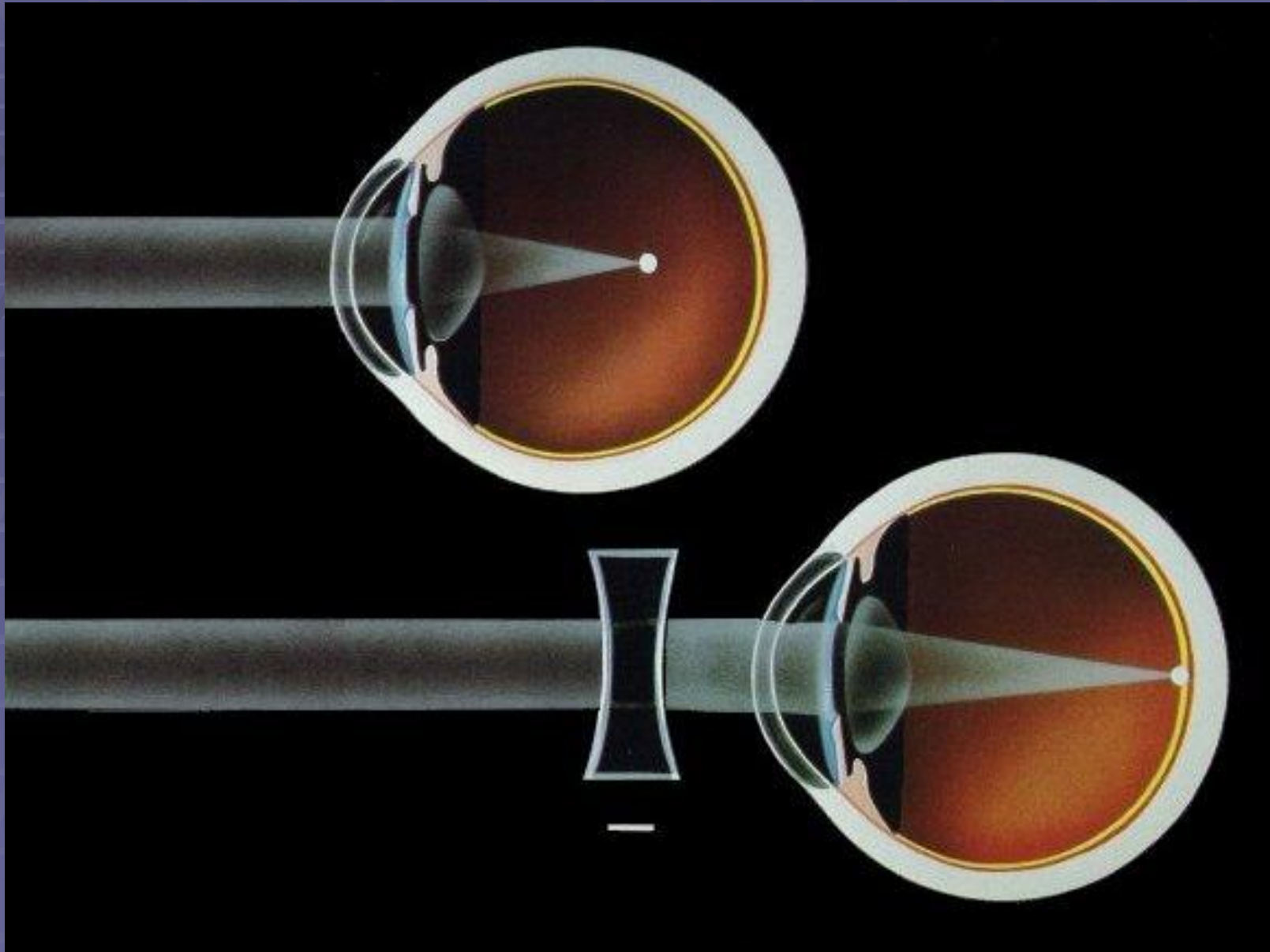
Myopia

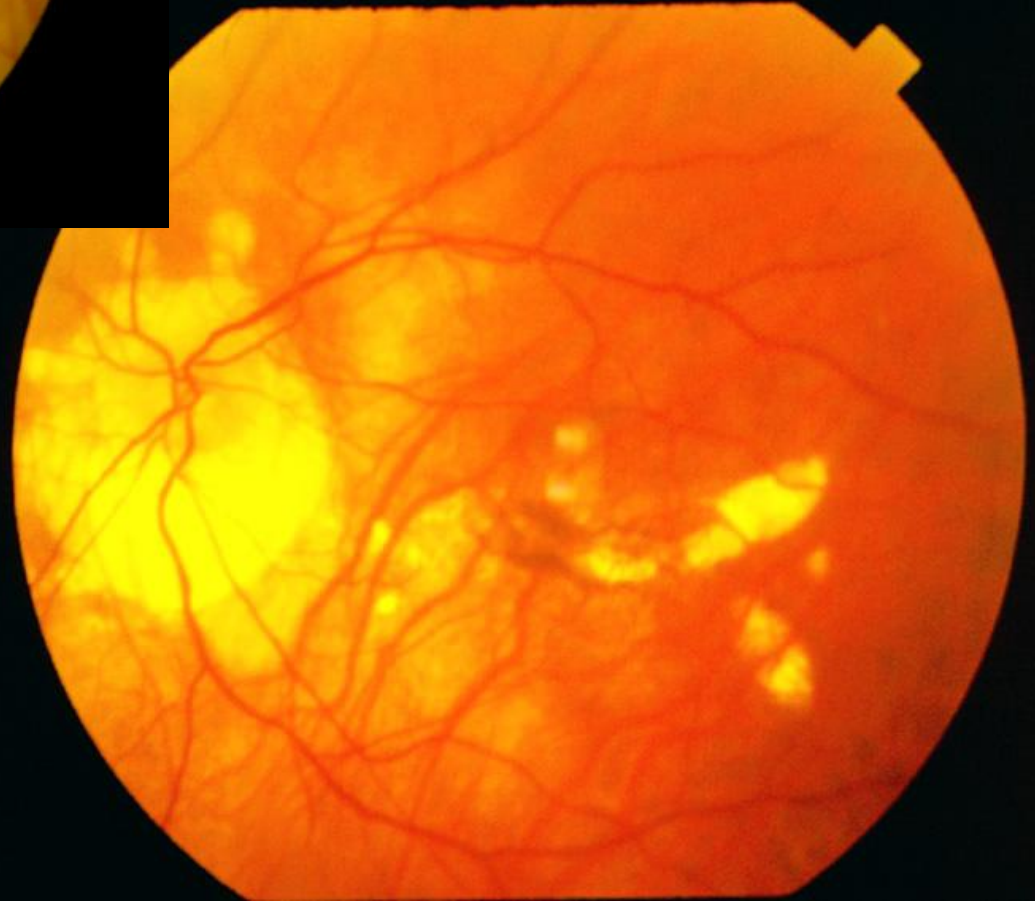
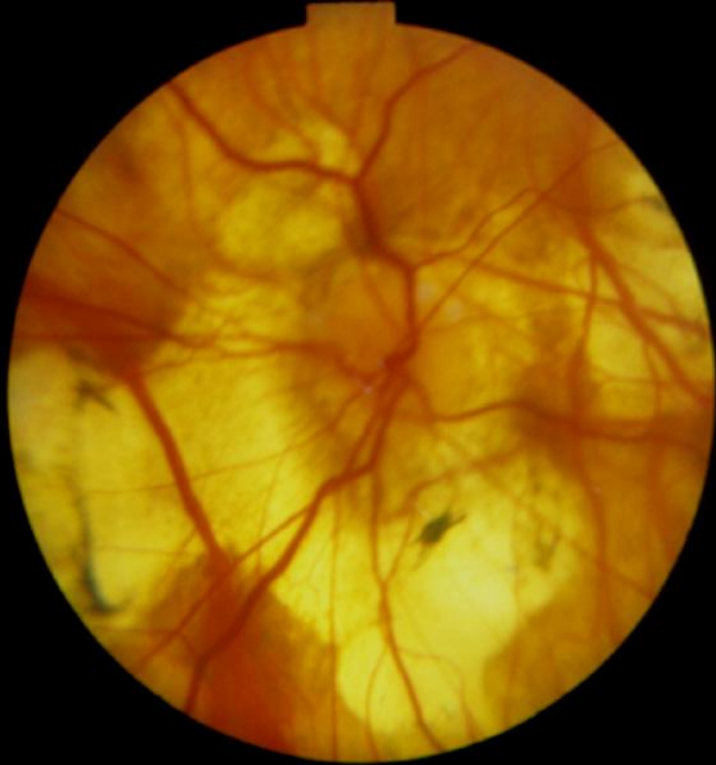


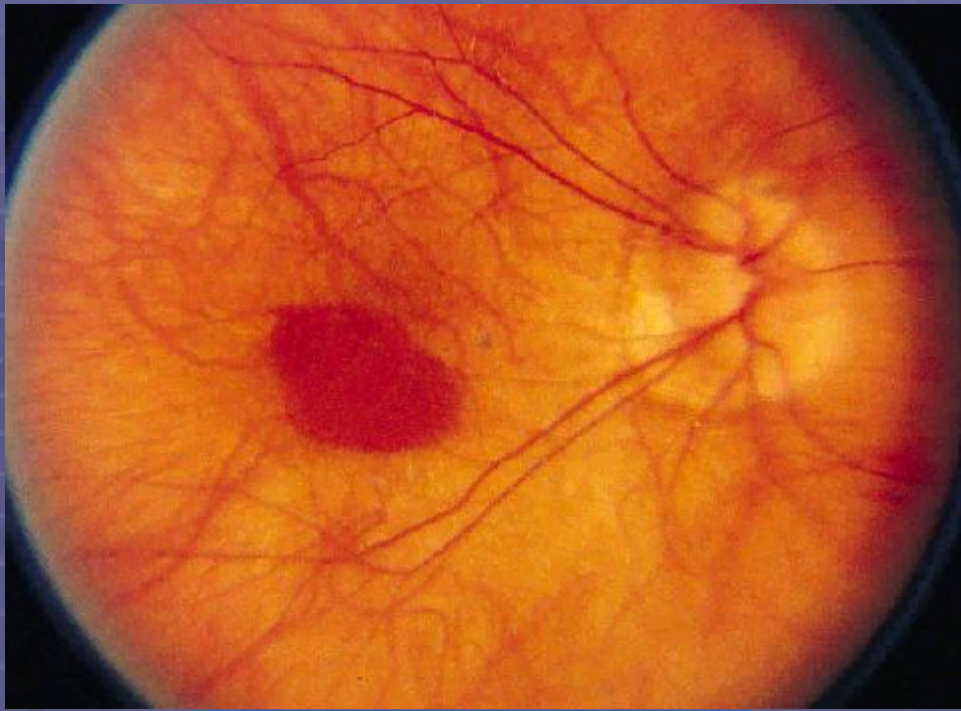
Hyperopia



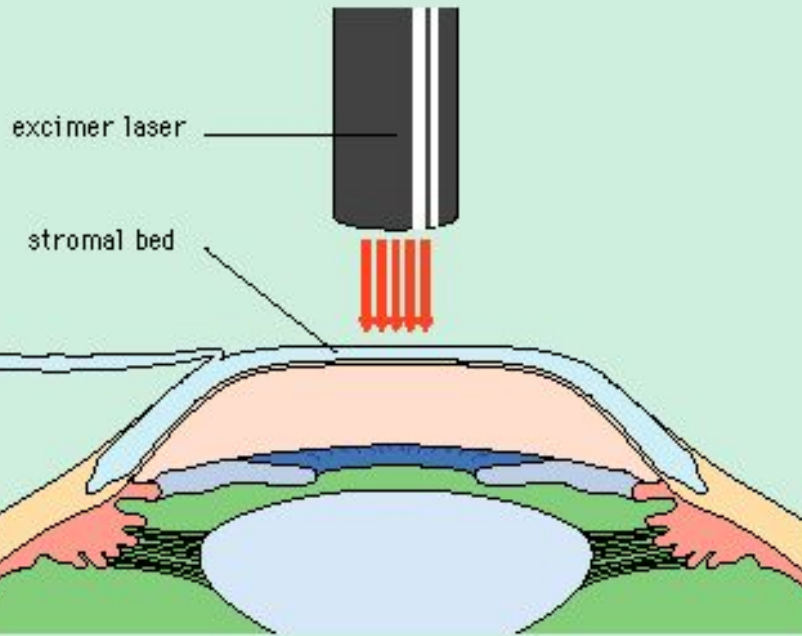






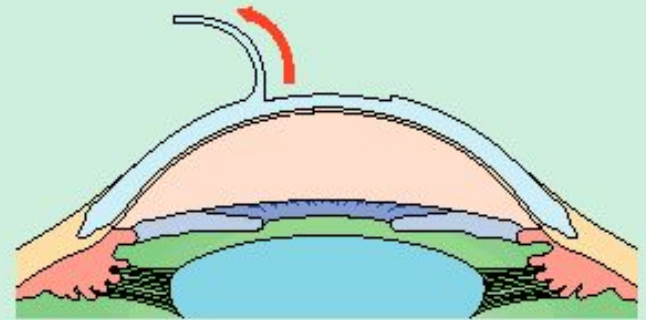


LASER IN SITU KERATOMILEUSIS

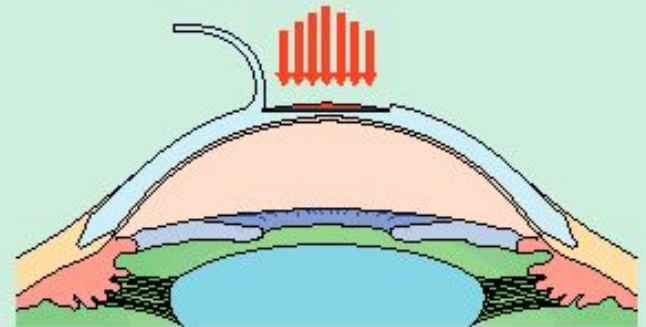


LASER-ASSISTED STROMAL IN SITU KERATOMILEUSIS

Flap lifted from eye



Lenticle removed using laser light



Flap sewn back down

