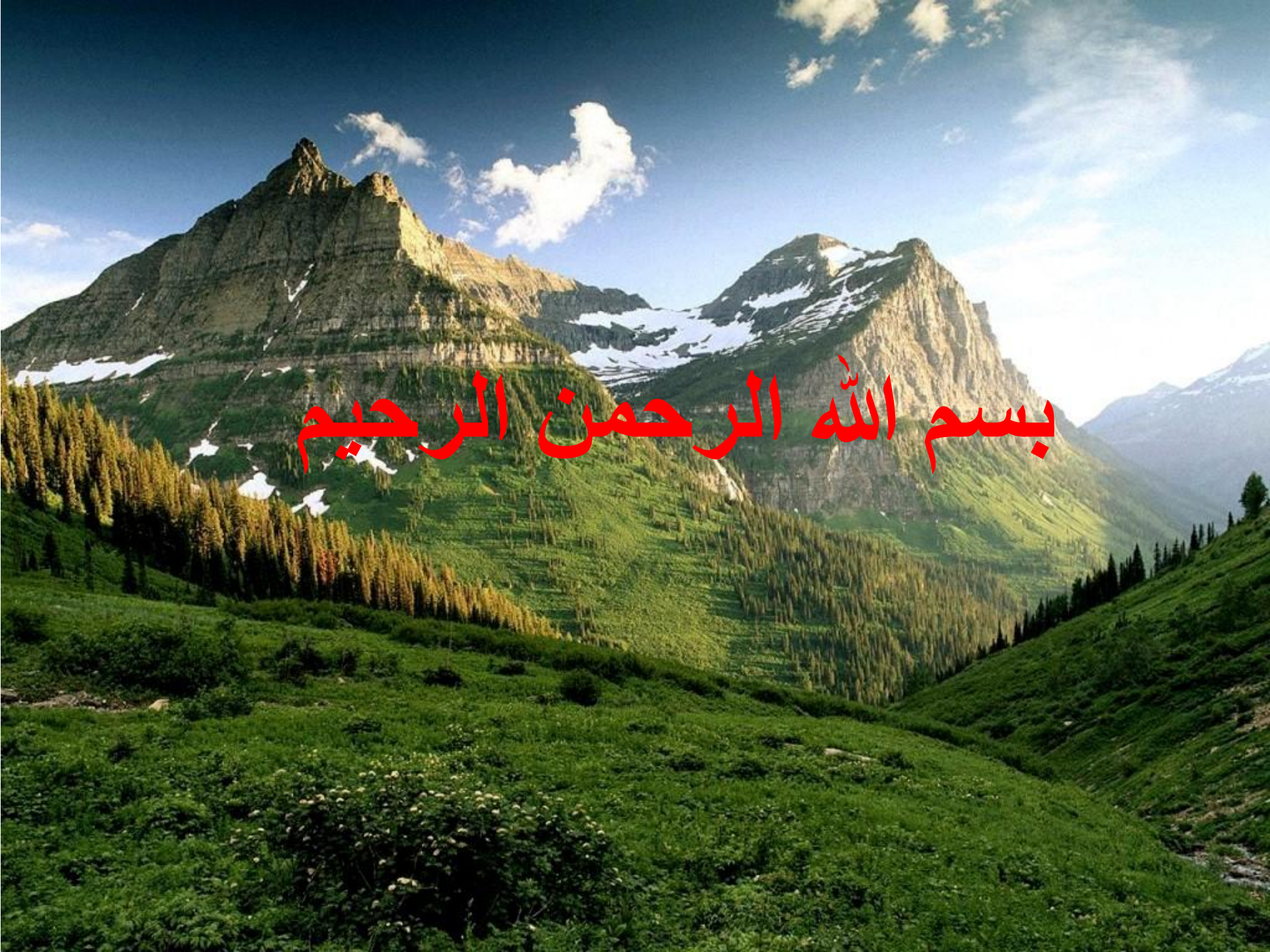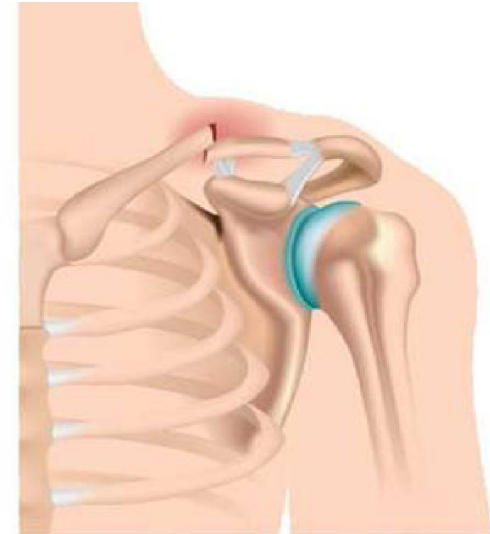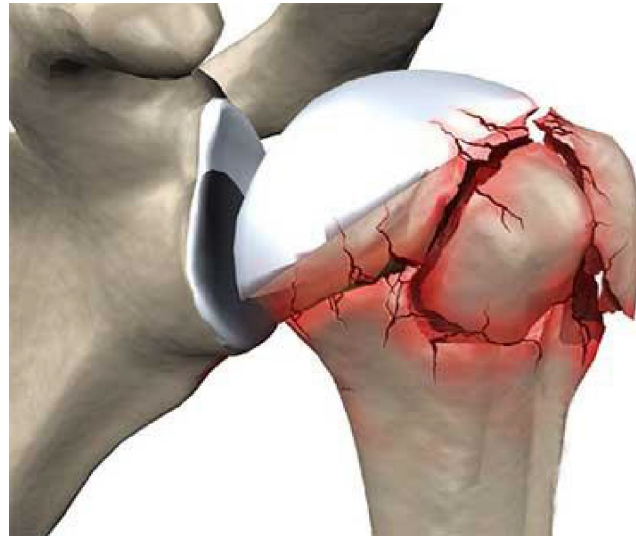




بِسْمِ اللَّهِ الرَّحْمَنِ الرَّحِيمِ

REHABILITATION FOR SHOULDER FRACTURES & SURGERIES

- Clavicle fractures
- Proximal head of humerus fractures



Dr. ahmed Samir Mohamed

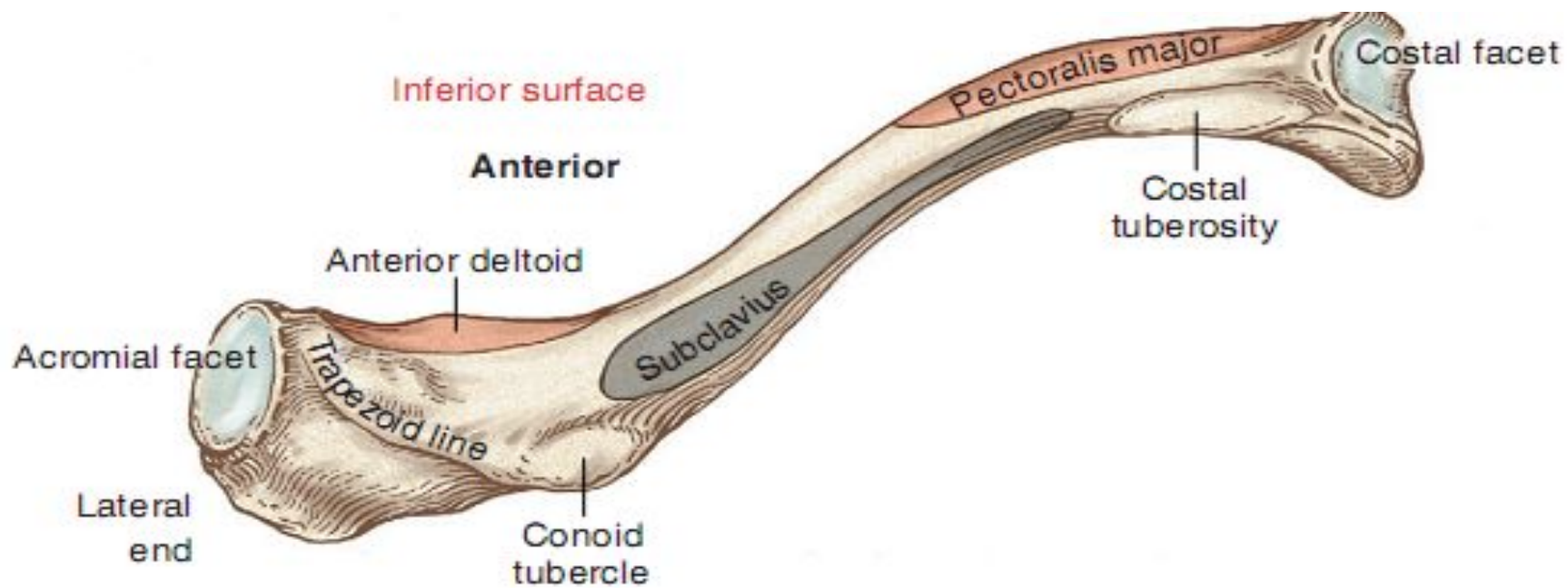
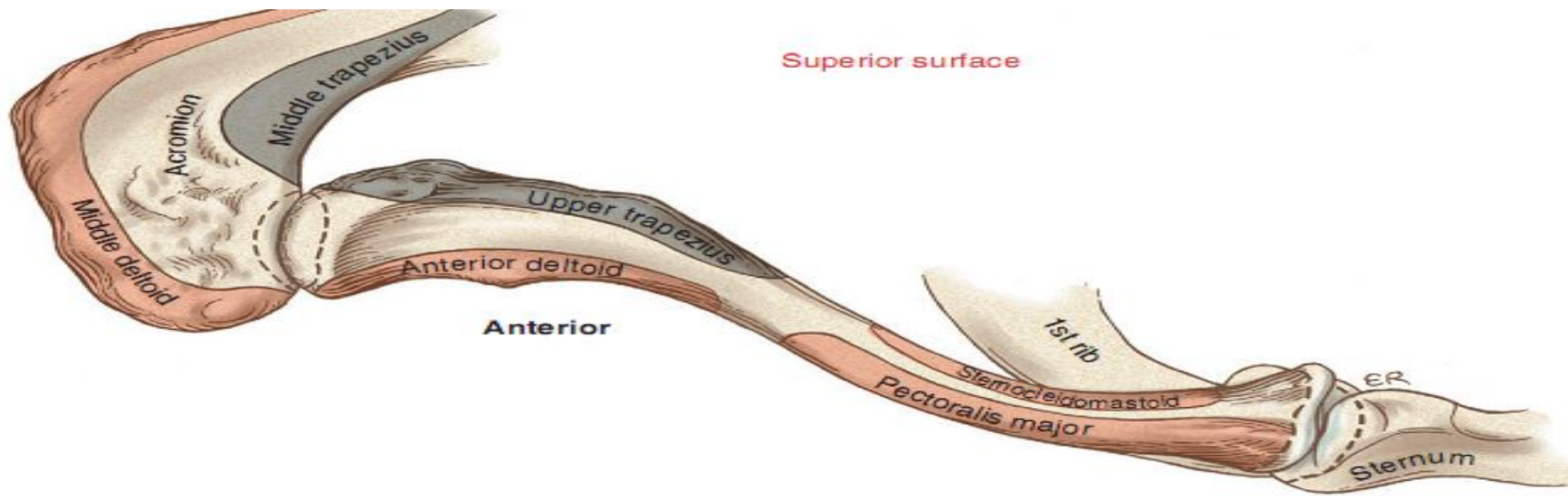
Lecturer of physical therapy for orthopedic and its surgeries

Clavicle fractures

When one looks from above, it is evident that the shaft of the clavicle is curved, with its anterior surface being generally convex medially and concave laterally.

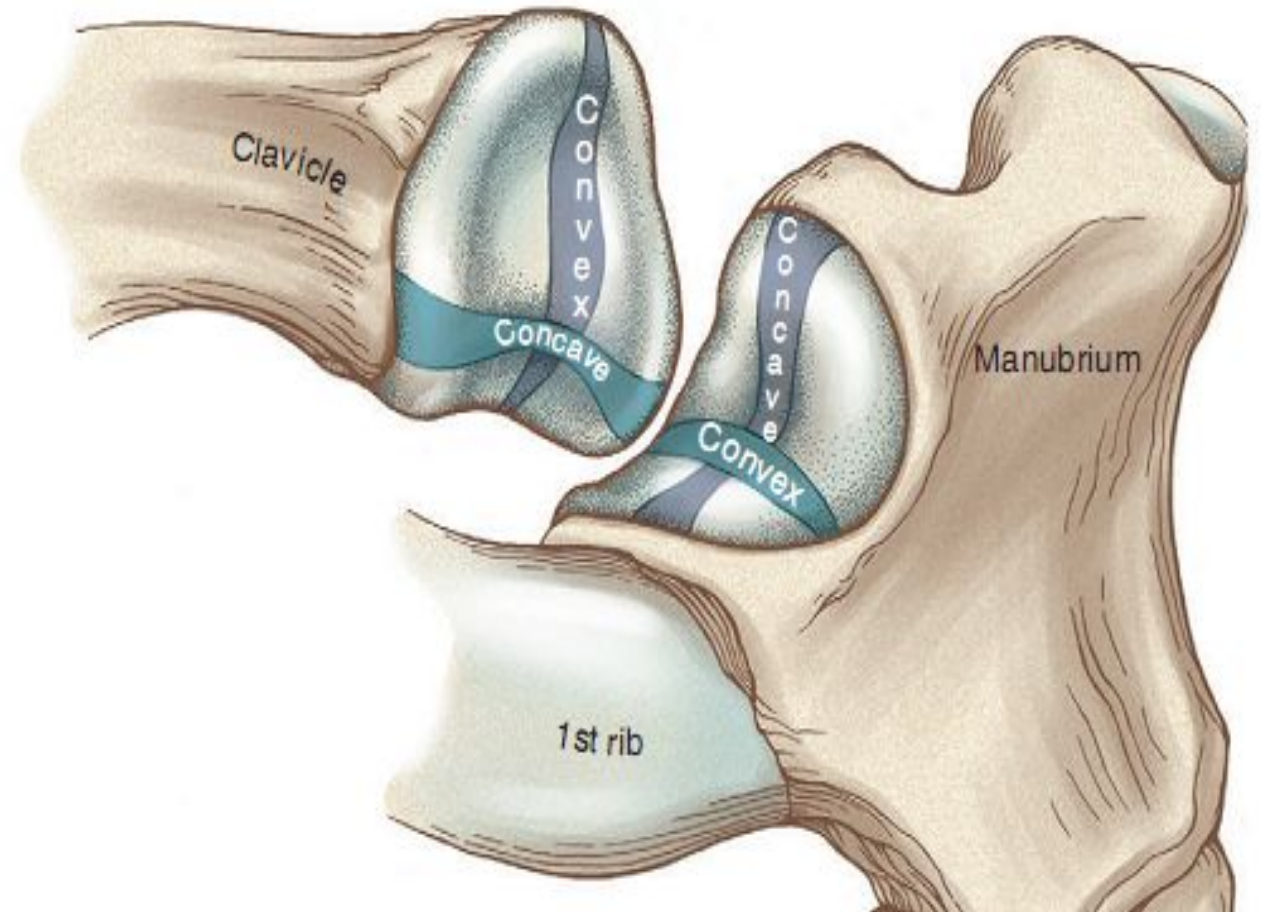
Osteologic Features of the Clavicle

- Shaft
- Sternal end
- Costal facet
- Costal tuberosity
- Acromial end
- Acromial facet
- Conoid tubercle
- Trapezoid line

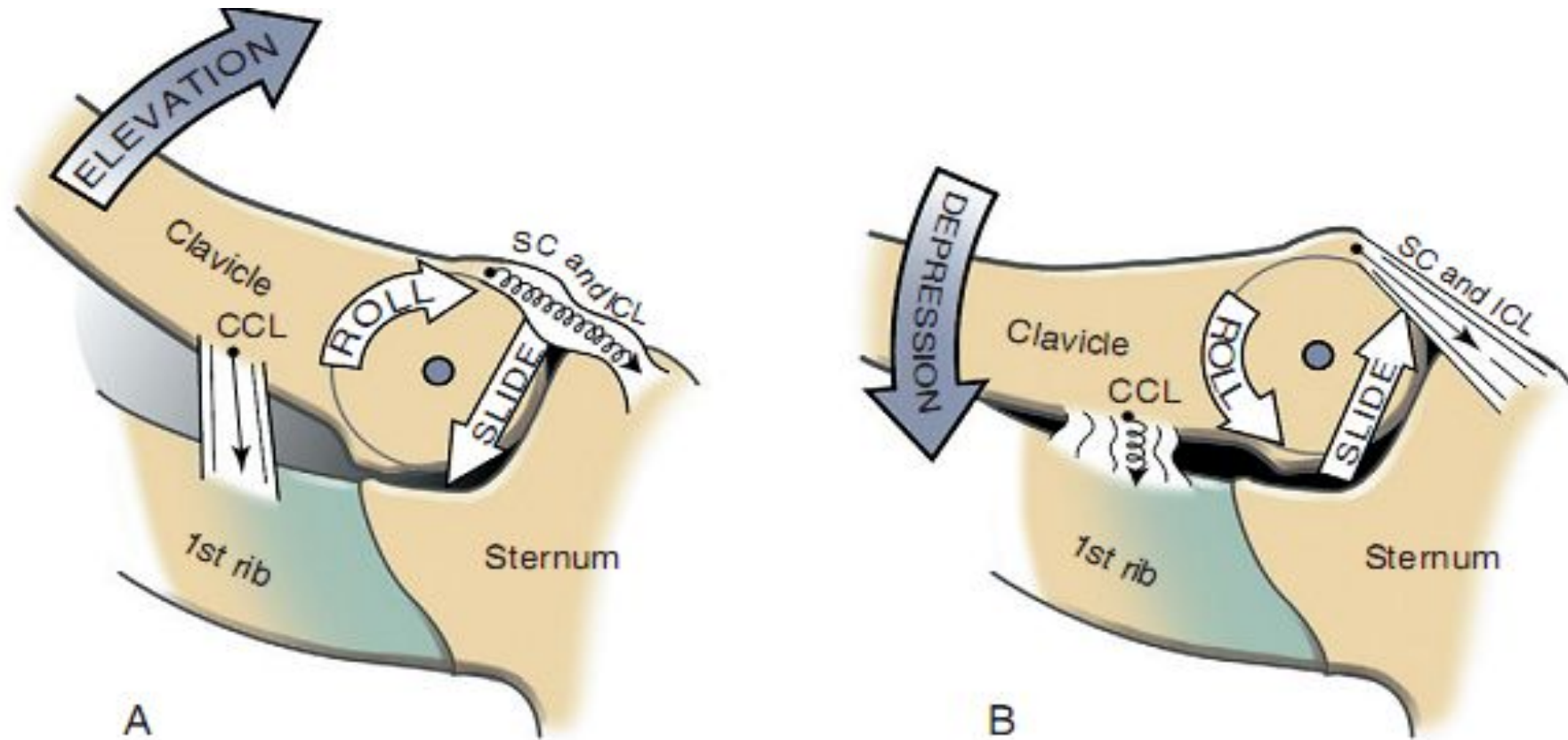


Sternoclavicular Joint

The sternoclavicular (SC) joint is a complex articulation, involving the medial end of the clavicle, the clavicular facet on the sternum, and the superior border of the cartilage of the first rib



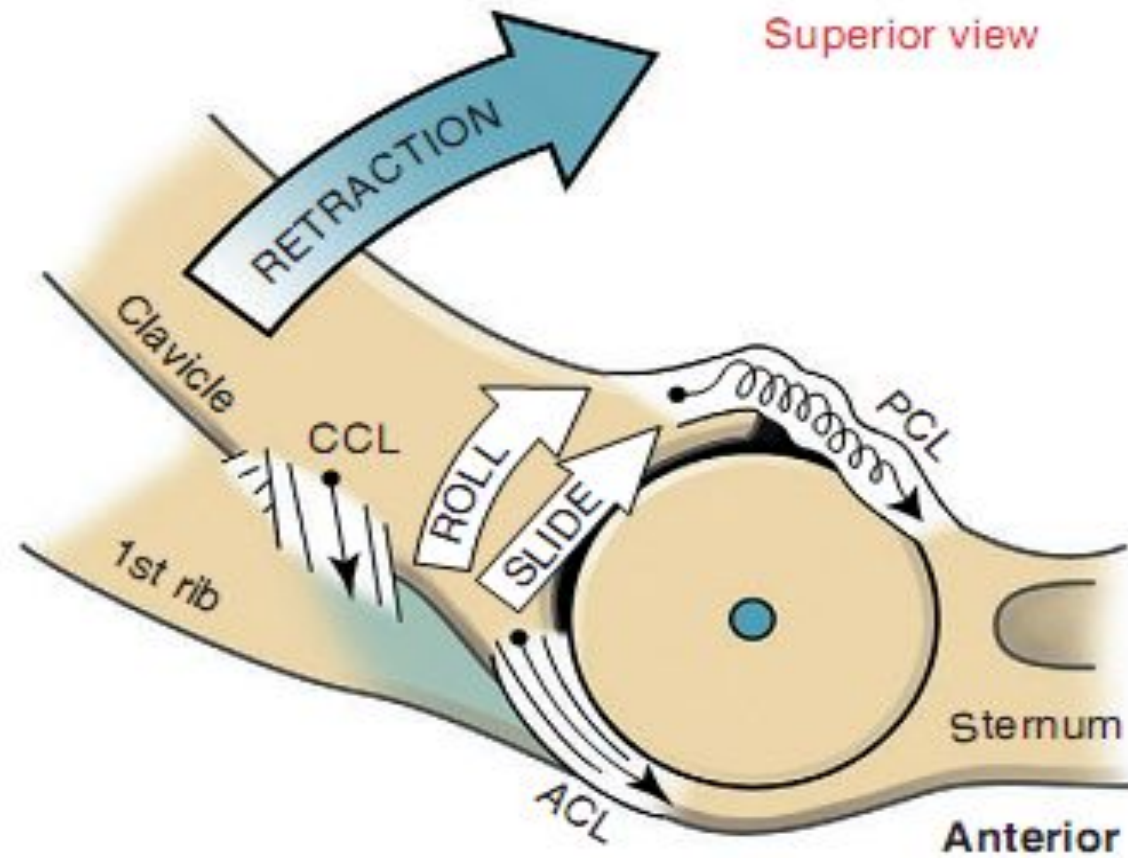
Arthrokinematics of SCJ



Tissues That Stabilize the Sternoclavicular Joint

- Anterior and posterior sternoclavicular joint ligaments
- Interclavicular ligament
- Costoclavicular ligament
- Articular disc
- Sternocleidomastoid, sternothyroid, sternohyoid, and subclavius muscles

Arthrokinematics of SCJ



Acromioclavicular joint (ACJ)

The acromioclavicular (AC) joint is the articulation between the lateral end of the clavicle and the acromion of the scapula

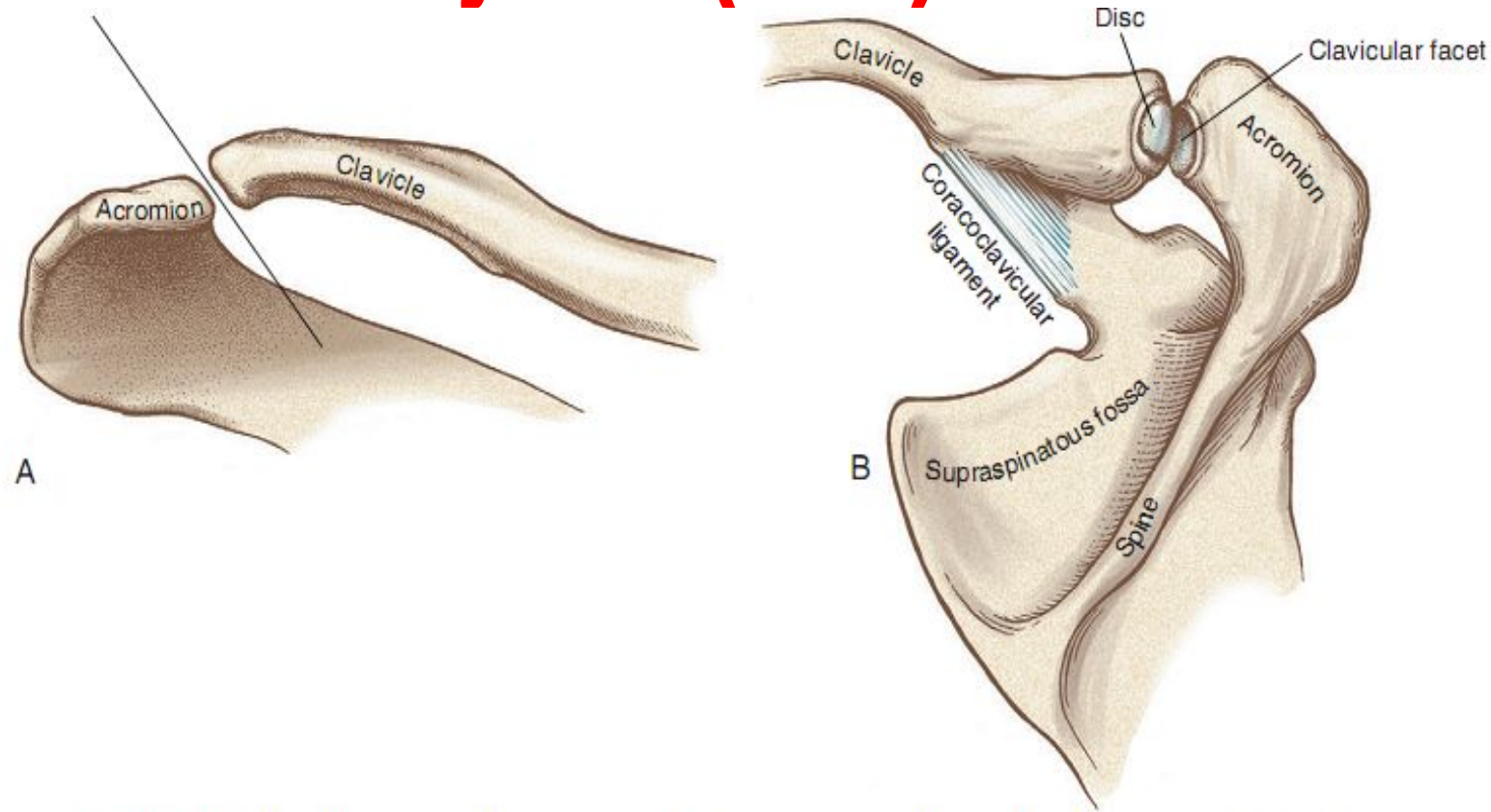
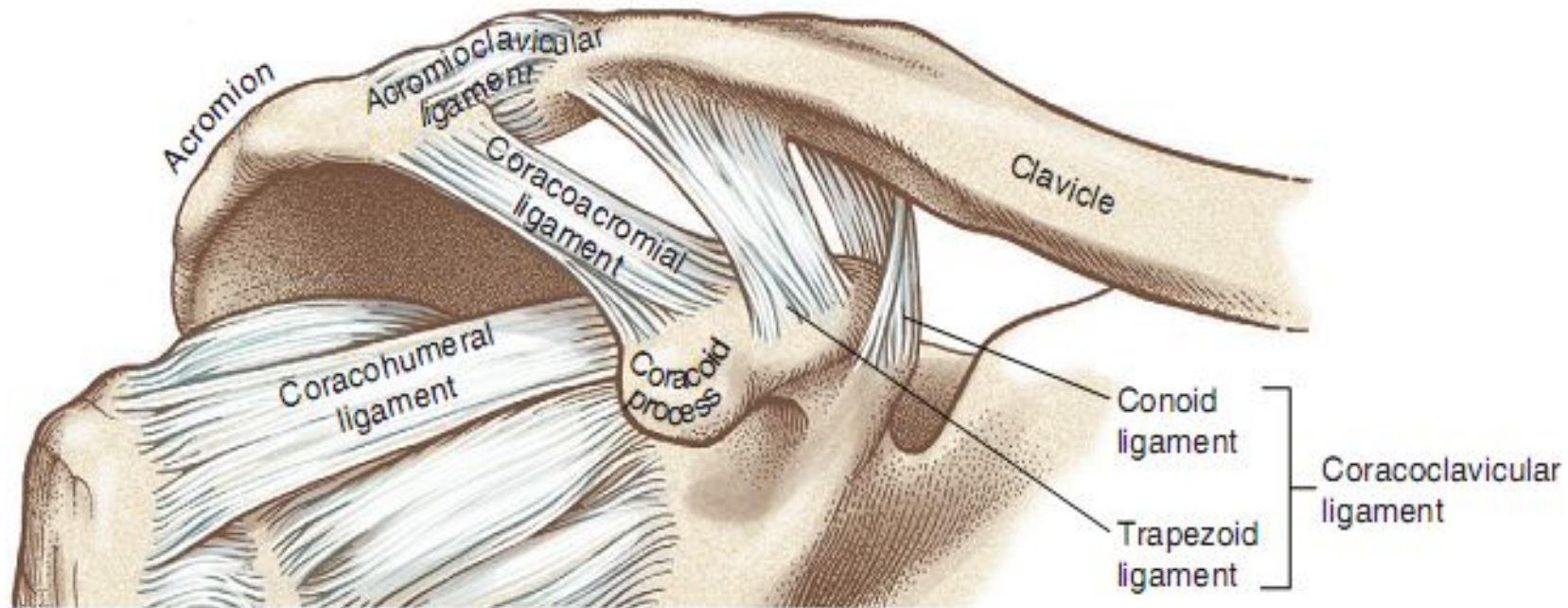


FIGURE 5-16. The right acromioclavicular joint. **A**, An anterior view showing the sloping nature of the articulation. **B**, A posterior view of the joint opened up from behind, showing the clavicular facet on the acromion and the disc.

AC stabilizers



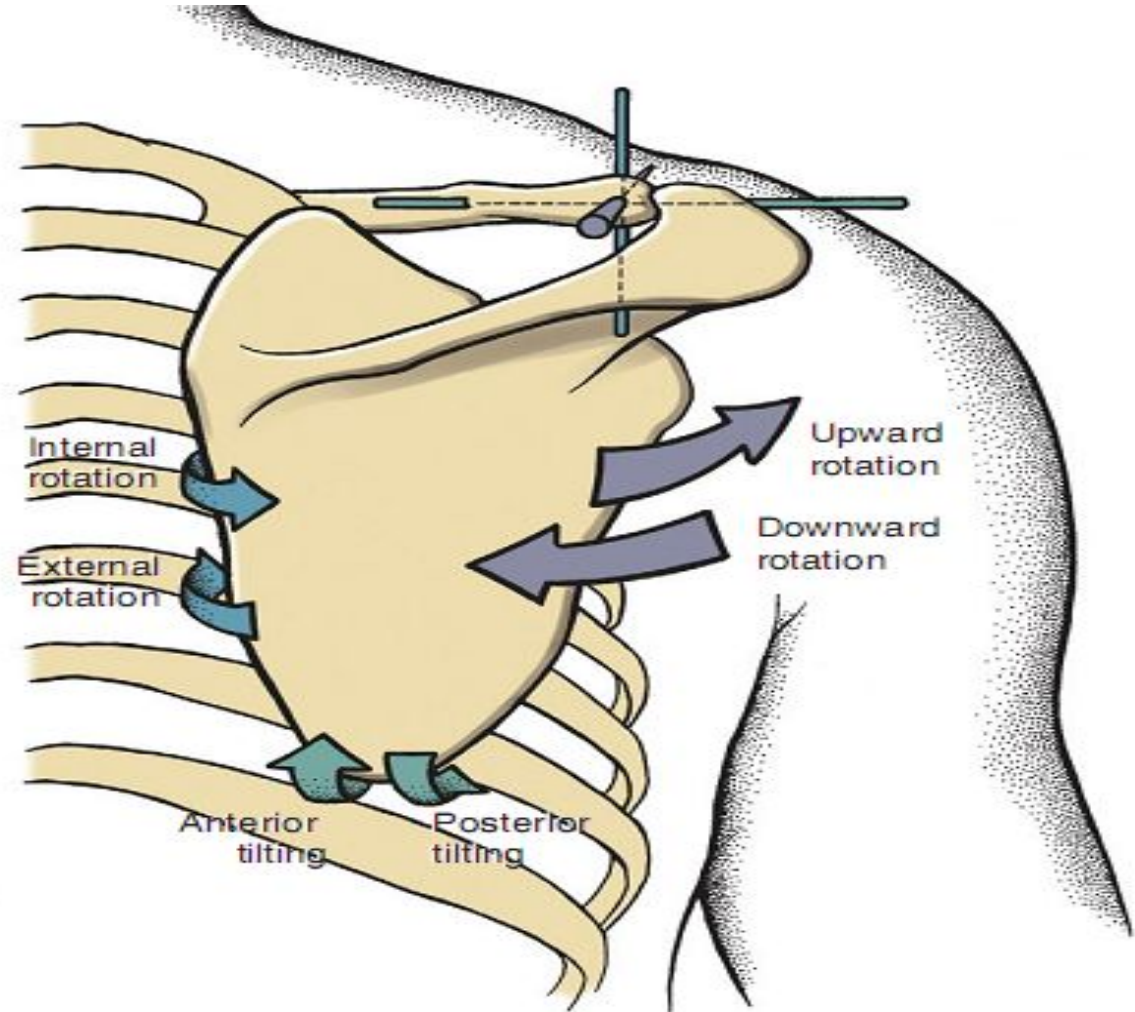
Tissues That Stabilize the Acromioclavicular Joint

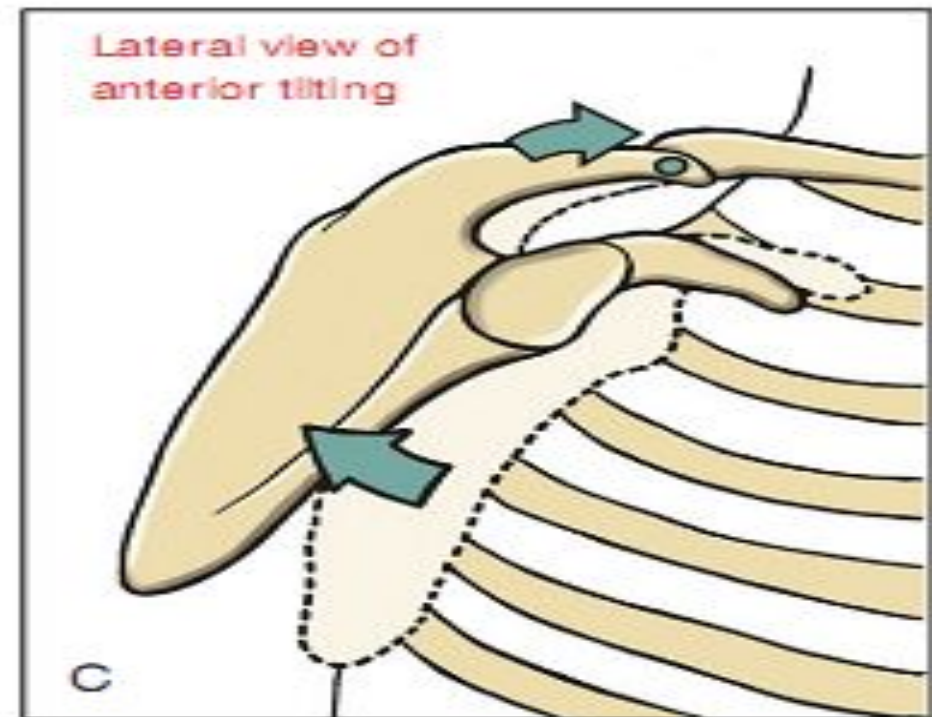
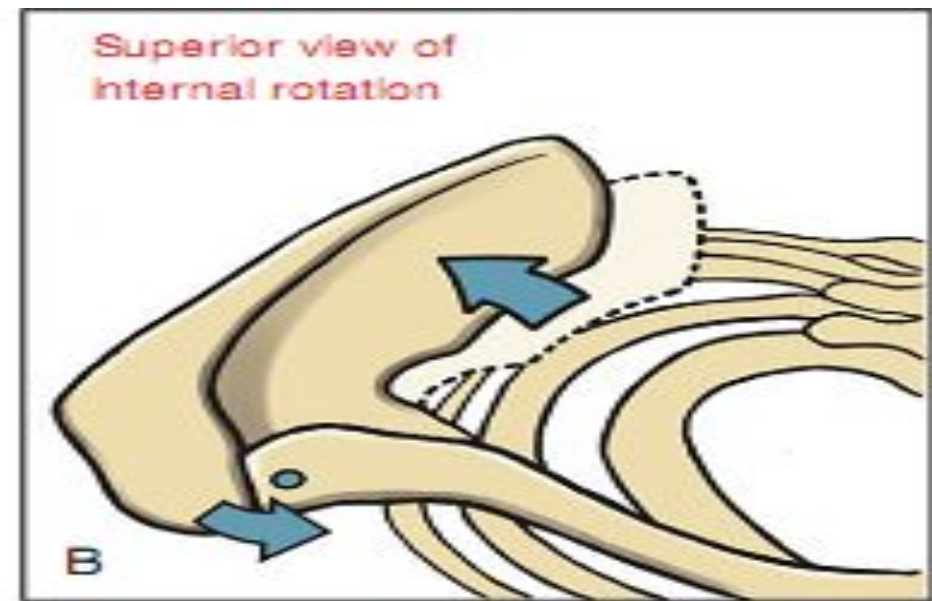
- Superior and inferior acromioclavicular joint ligaments
- Coracoclavicular ligament
- Articular disc (when present)
- Deltoid and upper trapezius

Arthrokinematics of AC joint

Upward and Downward Rotation

Upward rotation of the scapula at the AC joint occurs as the scapula “swings upwardly and outwardly” relative to the lateral end of the clavicle

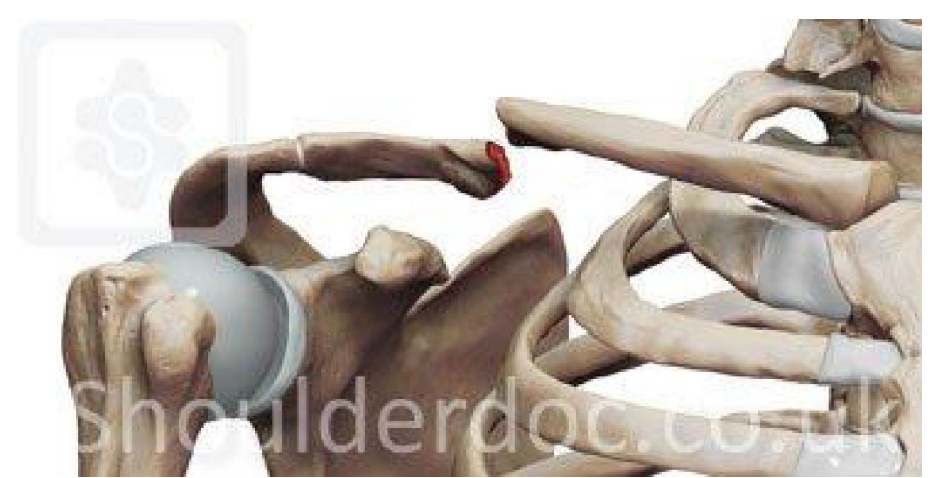




Rotational adjustment

B and C show examples of rotational adjustments at the AC joint: internal rotation during scapulothoracic protraction (B), and anterior tilting during scapulothoracic elevation (C)

Clavicle Fractures

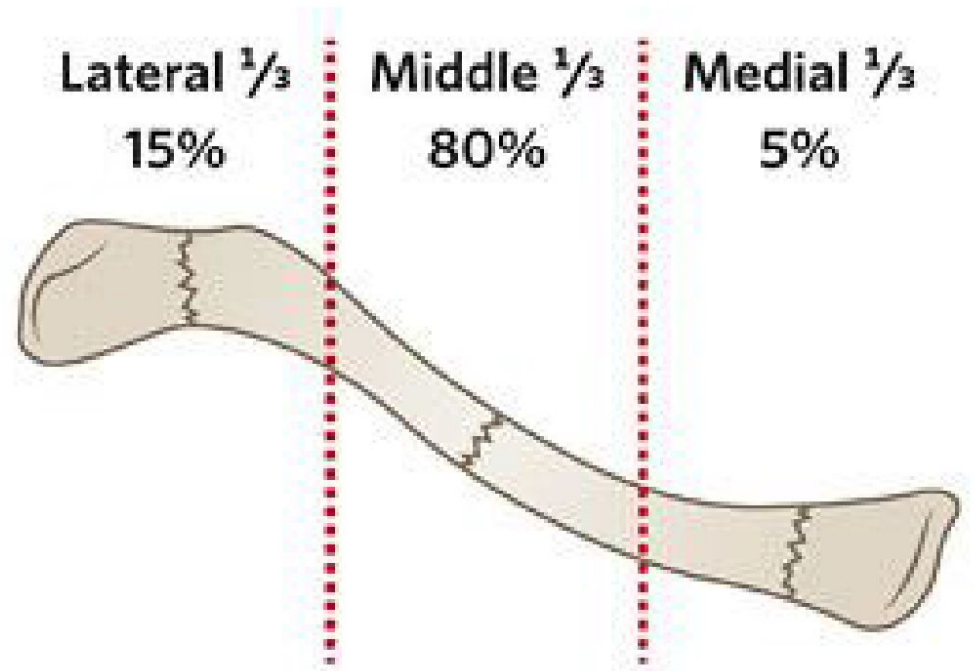
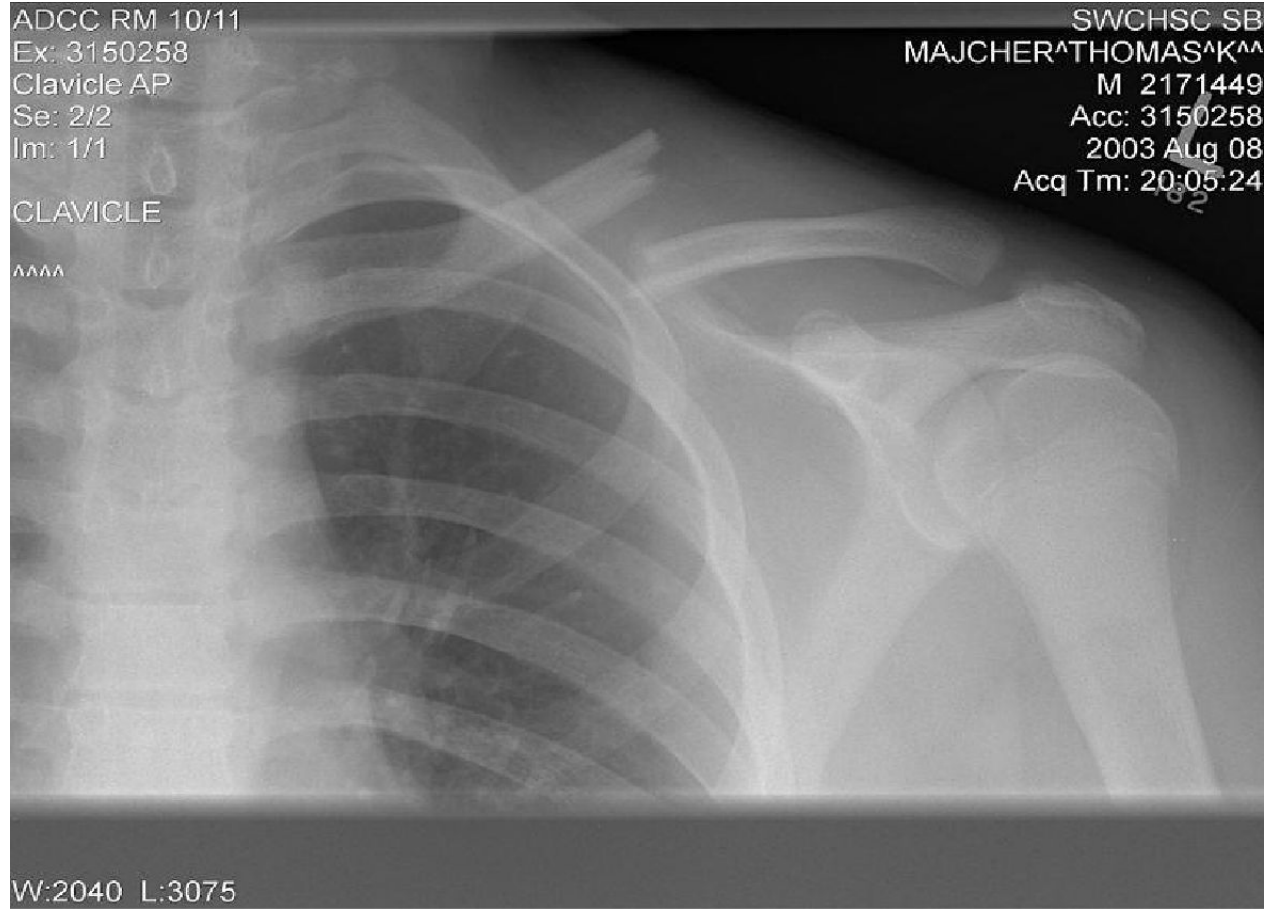

Classification

There is more than one accepted classification for clavicle fractures.

The following is Craig's classification:

1. Group I-fracture of the middle one third (most clavicular fractures are group I fractures)
2. Group II-fracture of the lateral or distal one third
3. Group III-fracture of the medial one third



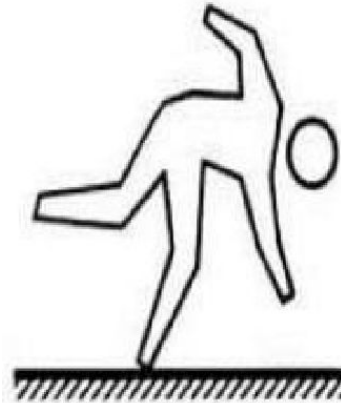© The Royal Children's Hospital,
Melbourne, Australia

Mechanism of Injury

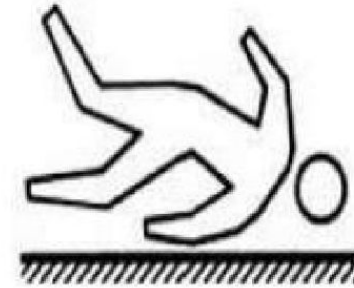- Most clavicle fractures are caused by a fall or other direct trauma to the shoulder
- Falls on an outstretched hand (**FOOSH**), although commonly cited, account for a smaller percentage of clavicle fractures.

MECHANISM OF INJURY


a) Fall with arm out, onto hand.

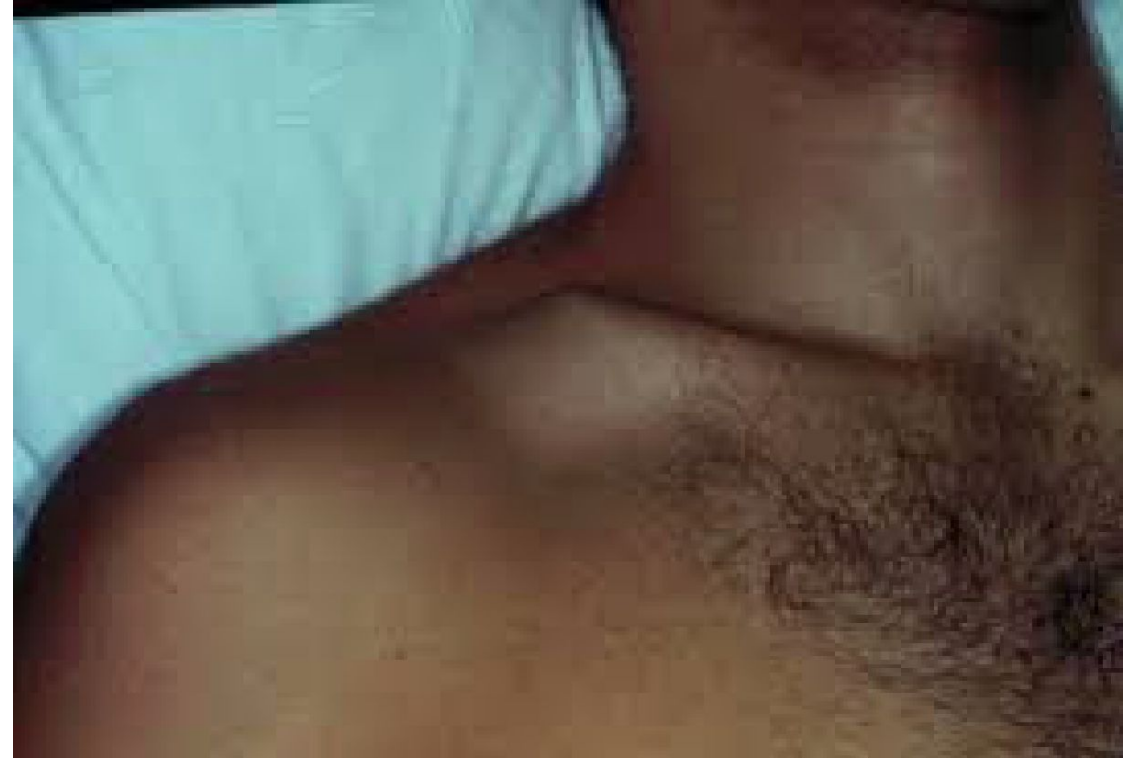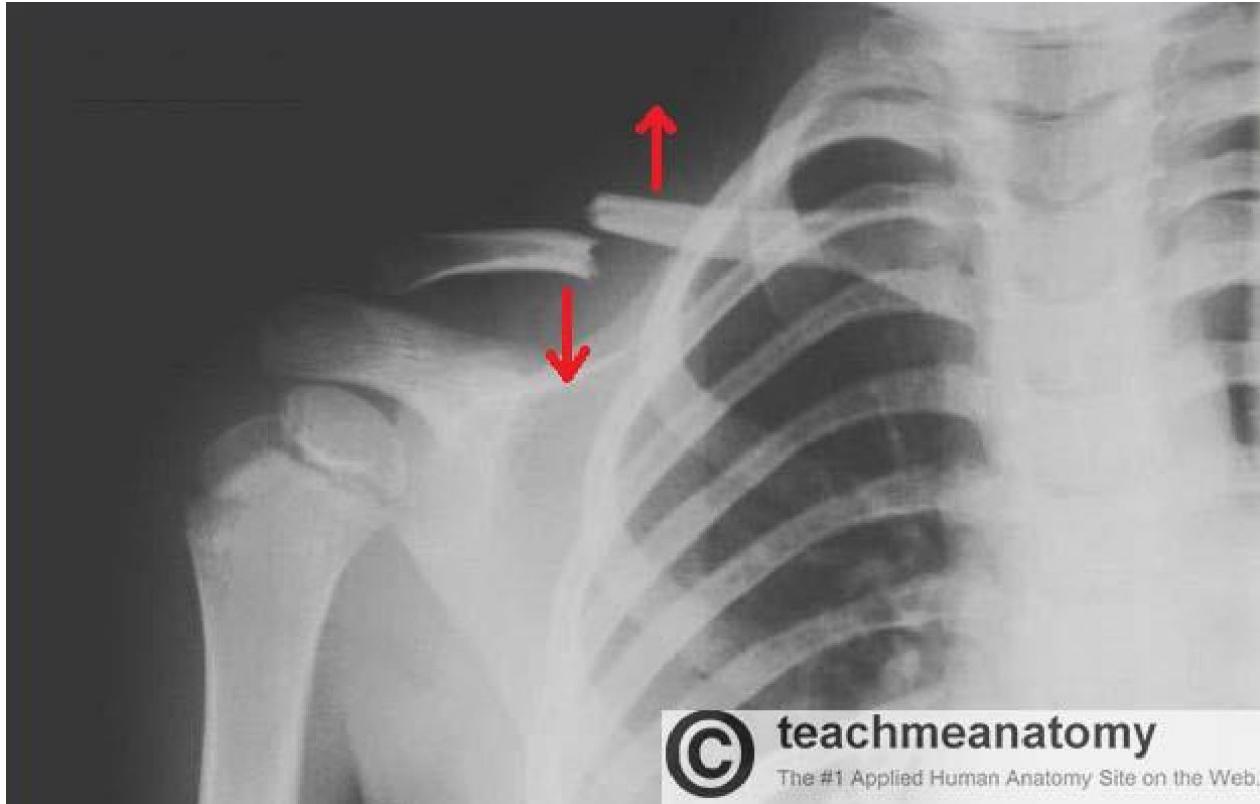


b) Fall onto shoulder.



c) Direct blow to shoulder.





Treatment Goals

1. *Range of Motion*

Restore and improve the range of motion of the shoulder girdle.

2. *Muscle Strength*

Improve the strength of the following muscles:

- ✓ Sternocleidomastoid (neck rotation)
- ✓ Pectoralis major (arm adduction)
- ✓ Deltoid (arm abduction)

3. Functional Goals

- ✓ Improve and restore the function of the shoulder for
- ✓ activities of daily living and vocational and sports activities.

- **Expected Time of Bone Healing** 6 to 12 weeks.
- **Expected Duration of Rehabilitation** 10 to 12 weeks.

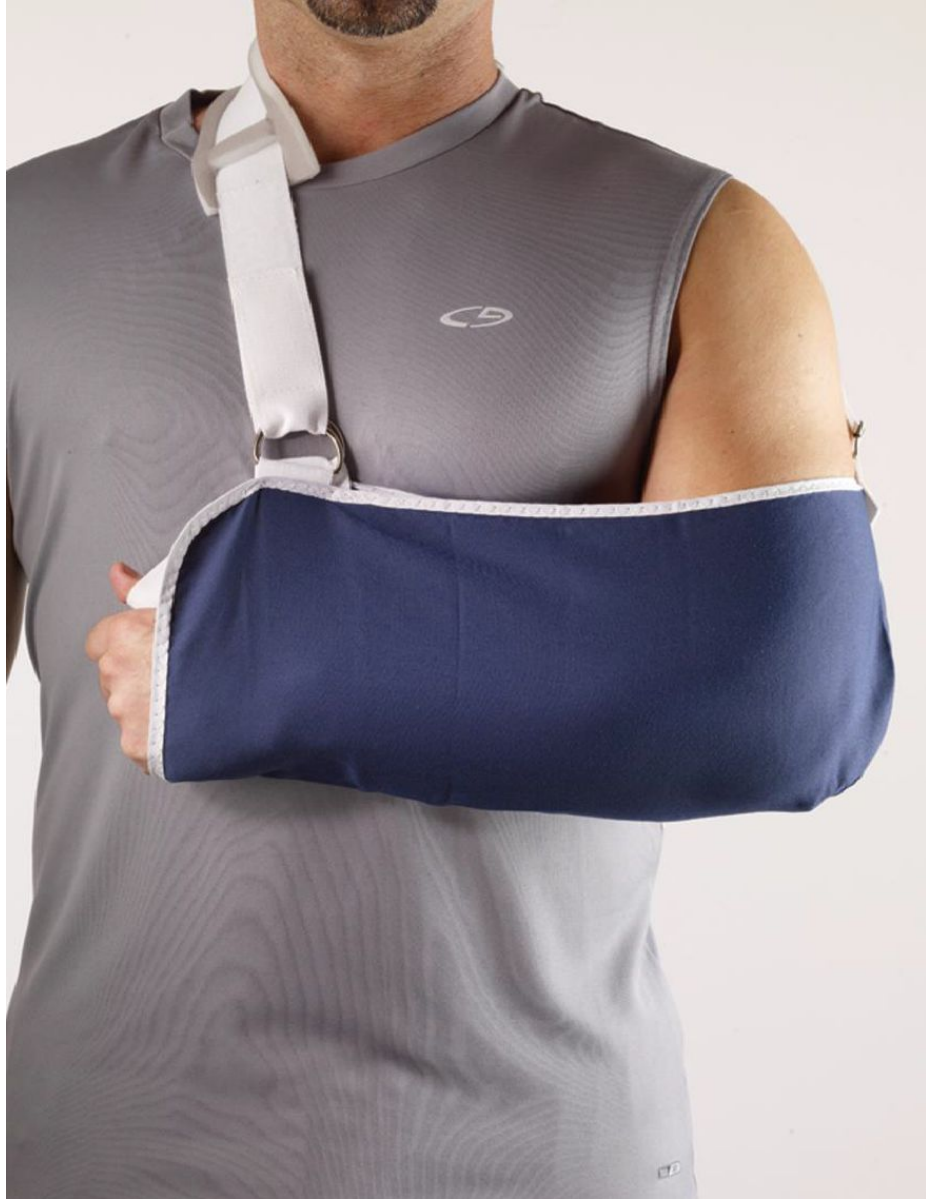Treatment methods

Sling or Supportive Immobilization

- This is the method of choice for most clavicle fractures. Many comparisons of plain sling treatment to figure-of-eight bracing in adults have shown no difference.

Open Reduction and Internal Fixation

- Open reduction and internal fixation is the method of choice for open fractures



Arm sling

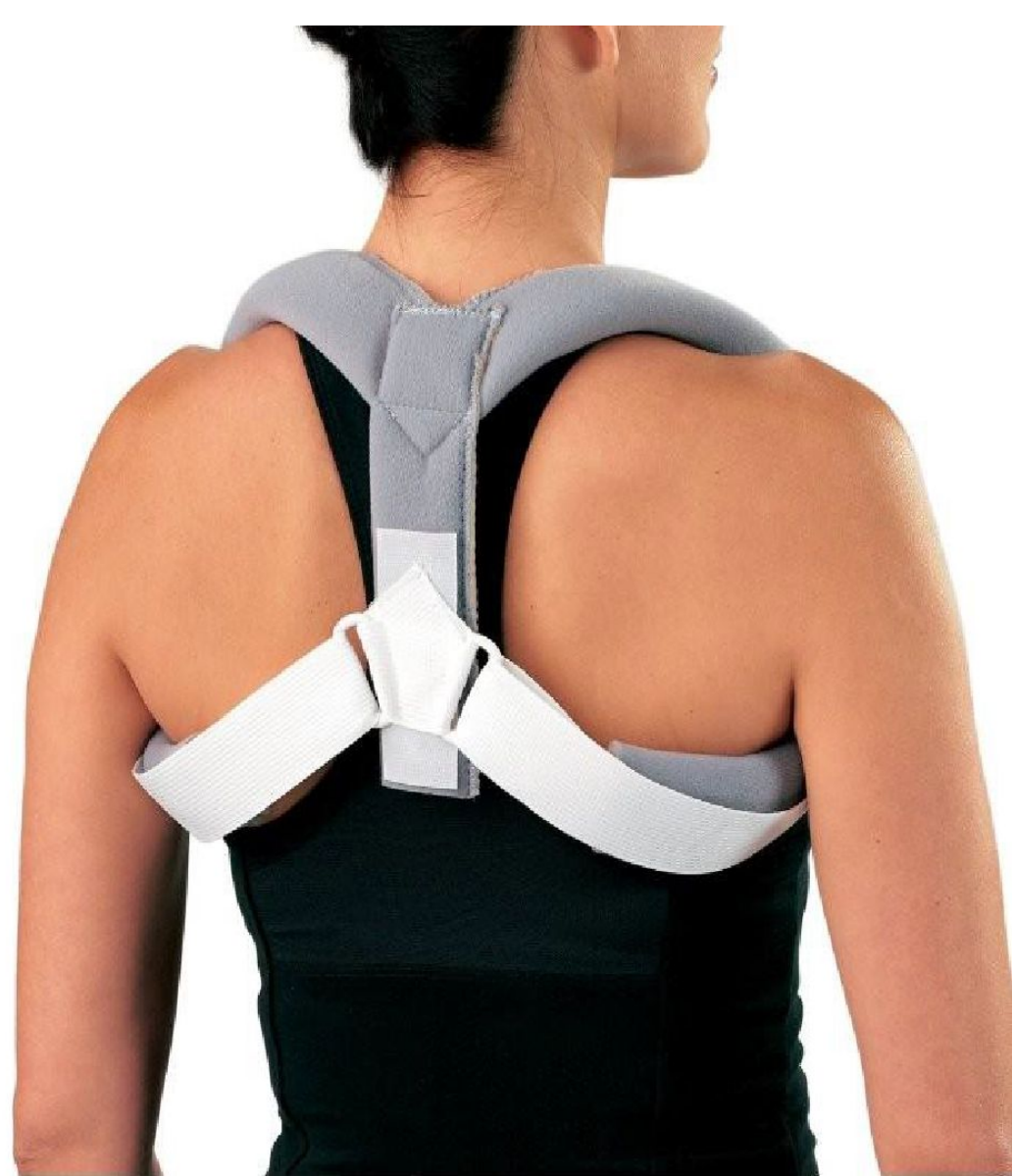

Figure-of-eight bracing

TREATMENT

Treatment: Early to Immediate (Day of Injury to One Week)

- **BONE HEALING**
- **Stability at fracture site:** None.
- **Stage of bone healing:** Inflammatory phase.
- **X-ray:** No callus.

Physical Examination

1. Check for capillary refill.
2. Sensory evaluation.
3. The active and passive range of motion of the affected extremity, including the elbow, wrist, and digits.
4. Evaluate any incision site for drainage, erythema.
5. Evaluate the patient's neurovascular status with a thorough brachial plexus assessment.
6. Check the sling for proper fit and padding at the axillary area and back of the neck

Prescription

- **Precautions:** Shoulder is held in adduction and internal rotation. Elbow is maintained at 90 degrees of flexion.
- **Range of Motion:** No range of motion to the shoulder. Full, active range of motion is encouraged to the wrist, hand, and digits.
- **Muscle Strength:** No strengthening exercises to the shoulder, Begin isometric exercises to elbow arm and wrist 3 to 4 days after the fracture, once the pain subsides.

Prescription

- **Functional Activities:**

Personal hygiene The uninjured extremity is used in self-care and personal hygiene.

Bed mobility: The patient is instructed to roll over to the unaffected side to come to a sitting position in bed.

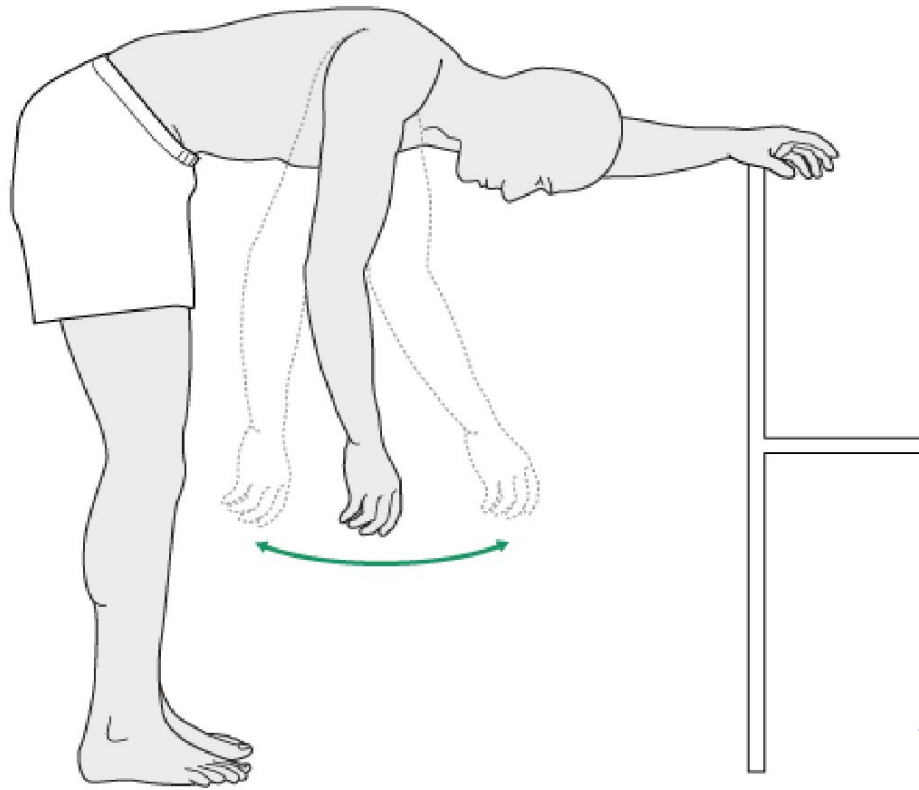
- **Weight bearing** : None.

Treatment: 2 to 4 Weeks

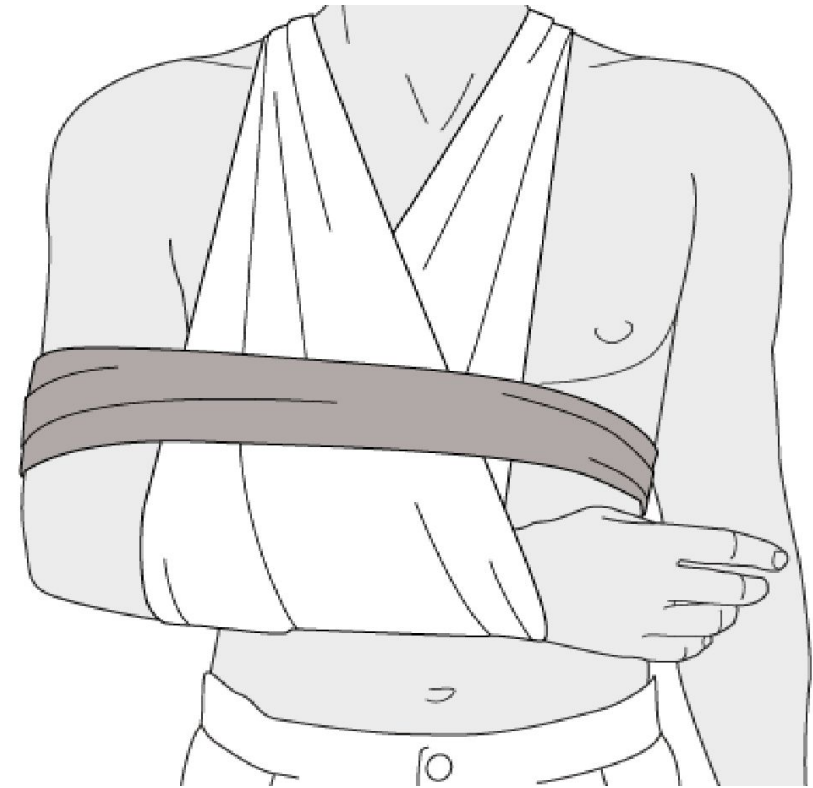
- **Stability at fracture site:** None to minimal
- **Stage of bone healing:** begin to reparative phase.
- **X-ray:** No to early callus. (Visible fracture line)

Prescription

- **Precautions:** The same as previous weeks.
- **Range of Motion:** Gentle pendulum exercises to the shoulder in the sling as pain permits.
- **Muscle Strength:** No strengthening exercises to the shoulder. Start gentle isometric exercises to the deltoid.
- **Functional Activities:** The same as previous weeks.
- **Weight bearing:** None.



Gentle pendulum exercises



Shoulder is held in adduction and internal rotation. Elbow is maintained at 90 degrees of flexion

Treatment: 4 to 6 weeks

BONE HEALING

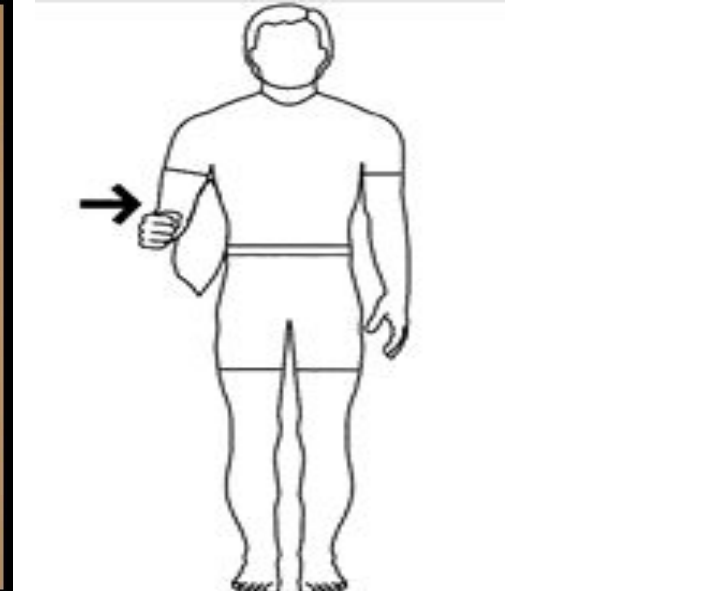
- **Stability at fracture site:** with bridging callus the fracture is usually stable.
- **Stage of bone healing:** Reparative phase.
- **X-ray:** Bridging callus is visible.

Prescription

- **Precautions:** At the end of 6 weeks, once there is good callus formation and the fracture site is stable, the sling or brace is removed with limitation of abduction.
- **Range of Motion:** At the end of 6 weeks, gentle active assisted range of motion to the shoulder is allowed. Abduction is limited to 80 degrees.

Prescription

- **Muscle Strength:** Start isometric exercises to the rotator cuff and deltoids.
- **Functional Activities:** The patient uses the affected extremity for some self-care and personal hygiene.
- **Weight bearing:** None.



A, Isometric shoulder internal rotation. B, Isometric shoulder external rotation. C, Isometric shoulder abduction. D, Isometric shoulder flexion. E, Isometric shoulder extension.

Treatment: 6 to 8 Weeks

BONE HEALING

- **Stability at fracture site:** with bridging callus the fracture is usually stable.
- **Stage of bone healing:** Reparative phase.
- **X-ray:** Bridging callus more apparent.

Prescription

- **Precautions:** Avoid contact sports.
- **Range of Motion:** active range of motion in all planes.
- **Muscle Strength:** Resistive exercises to the shoulder girdle muscles.
- **Functional Activities:** The patient uses the affected extremity for personal hygiene, self-care, stabilization, and light activities.
- **Weight bearing:** Gradual weight bearing is allowed (when pushing off from a chair or bed or using axillary crutches or a cane).

Treatment: 8 to 12 Weeks

BONE HEALING

- **Stability at fracture site:** Stable.
- **Stage of bone healing:** Remodeling phase.
- **X-ray:** Bridging callus is very visible.
- **N.B** frequently, it takes years for the large callus to remodel and be less visible cosmetically.

Prescription

- **Precautions:** Contact sports should be avoided for approximately 2 months.
- **Range of Motion:** Full ROM with abduction is encouraged.
- **Muscle Strength:** The resistance is gradually increased.
- **Functional Activities:** The involved extremity is used in self-care and functional activities.
- **Weight bearing:** Full weight bearing.

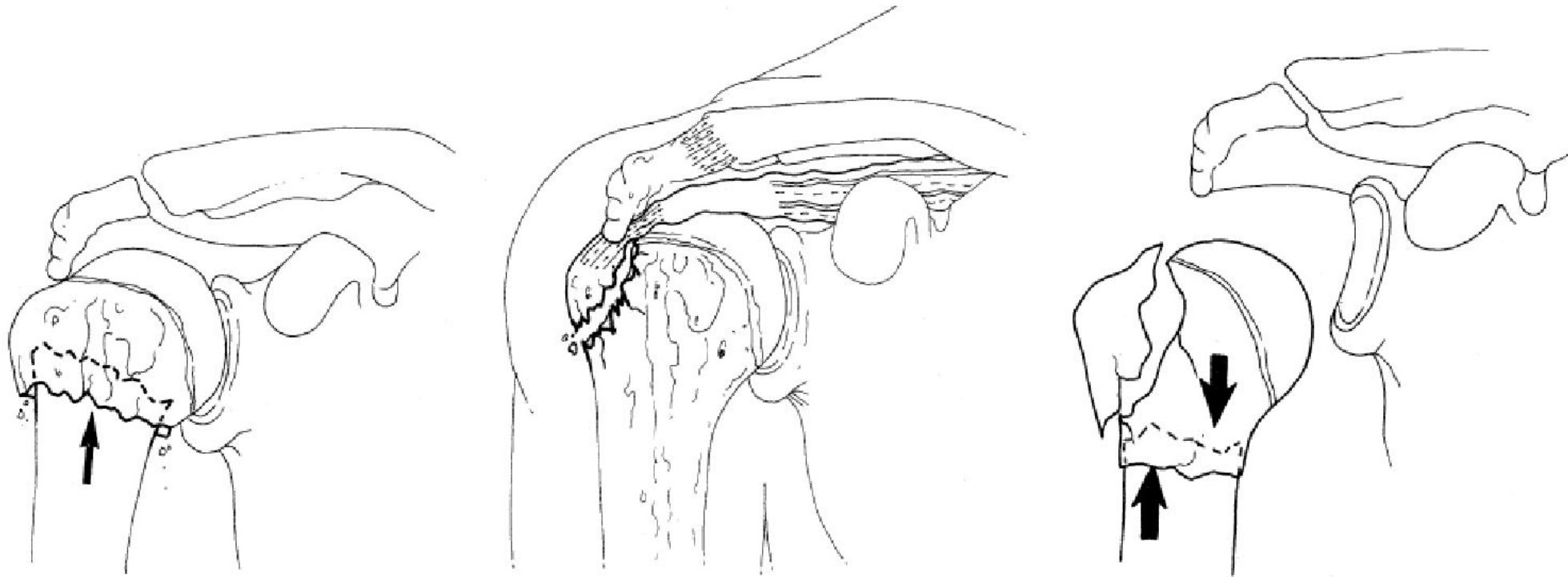
Proximal Humeral Fractures

- **Definition**

Fractures of the proximal end of the humerus involve the humeral head, anatomic neck, and surgical neck of the humerus.

Neer's classification system categorizes these fractures as one-, two-, three-, or four-part fractures based on the displacement and angulation of the parts, which are:

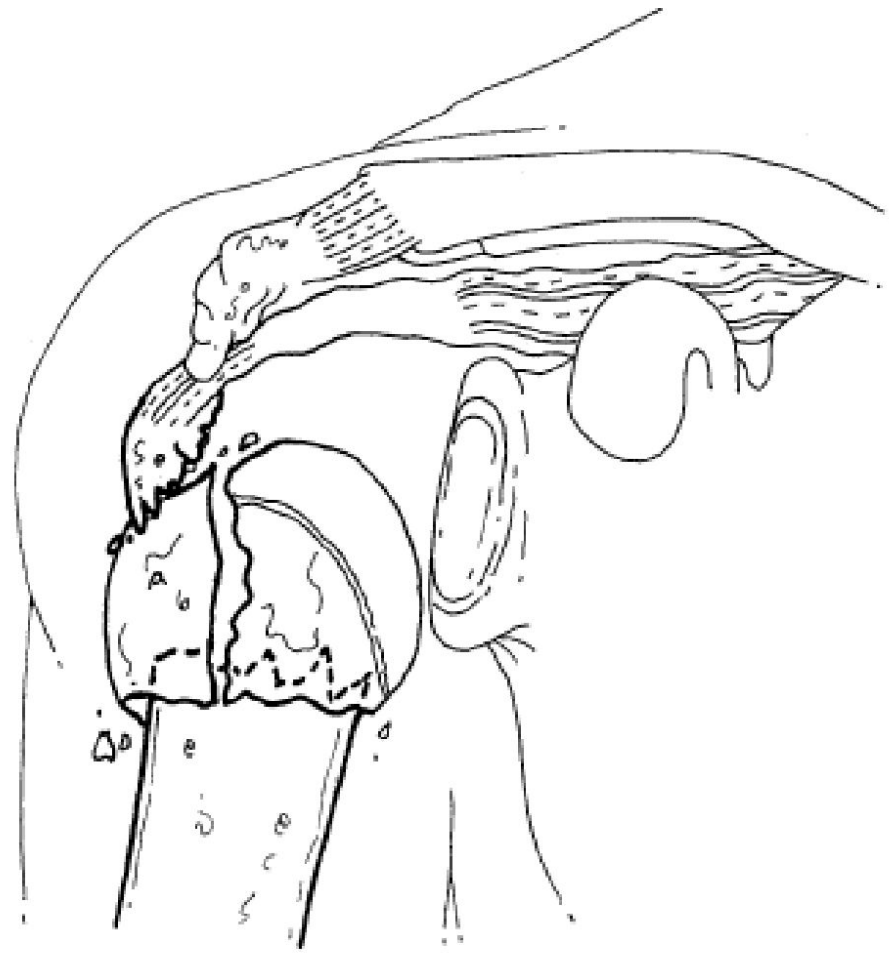the head, shaft, greater tuberosity, and lesser tuberosity in the proximal humerus.



Impacted proximal humeral fracture, also considered a one part fracture (Neer *(above, left)* classification). A two-part fracture involves either 1 cm of separation or 45 degrees of angulation of the fracture fragments

(above, middle) Displaced fracture of the greater tuberosity, also considered a two-part fracture. Rotator cuff injury may occur with this fracture pattern

(above, right) Three-part fracture of the proximal humerus: one part is the head separated from the shaft at the surgical neck, the second part the shaft, and the third part the greater tuberosity.



Four-part fracture of the proximal humerus. One part is the shaft, the second part the head, the third and fourth parts the greater and lesser tuberosities. The head is left without a blood supply and becomes prone to avascular necrosis.

X-ray

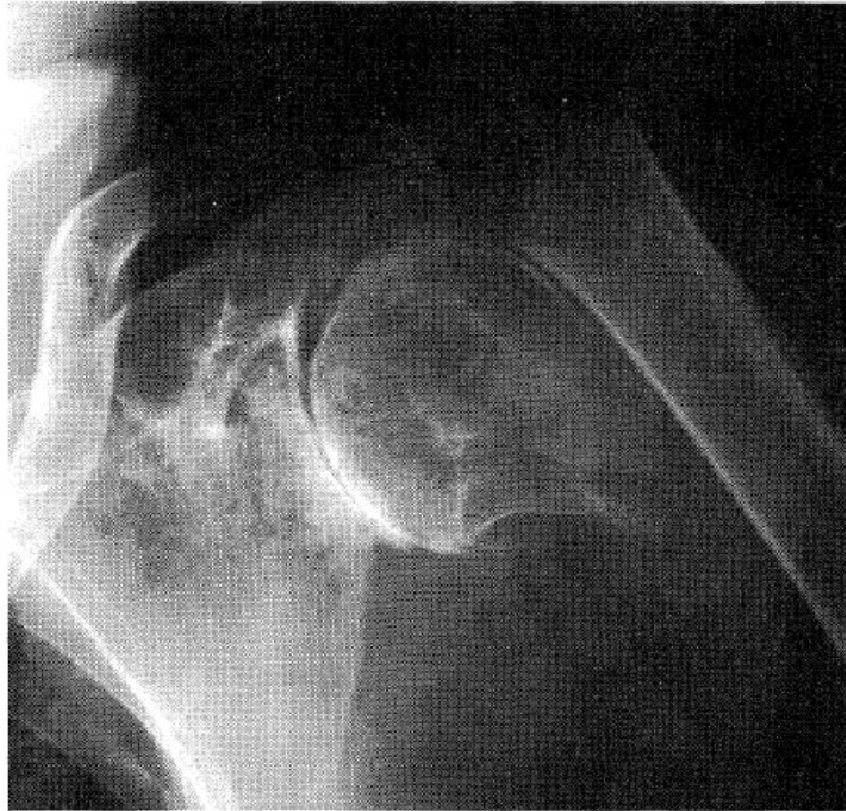

FIGURE 11-5 Two-part fracture of the proximal humerus through the surgical neck with obvious displacement. One part is the head and anatomic neck, the second the displaced shaft of the humerus.

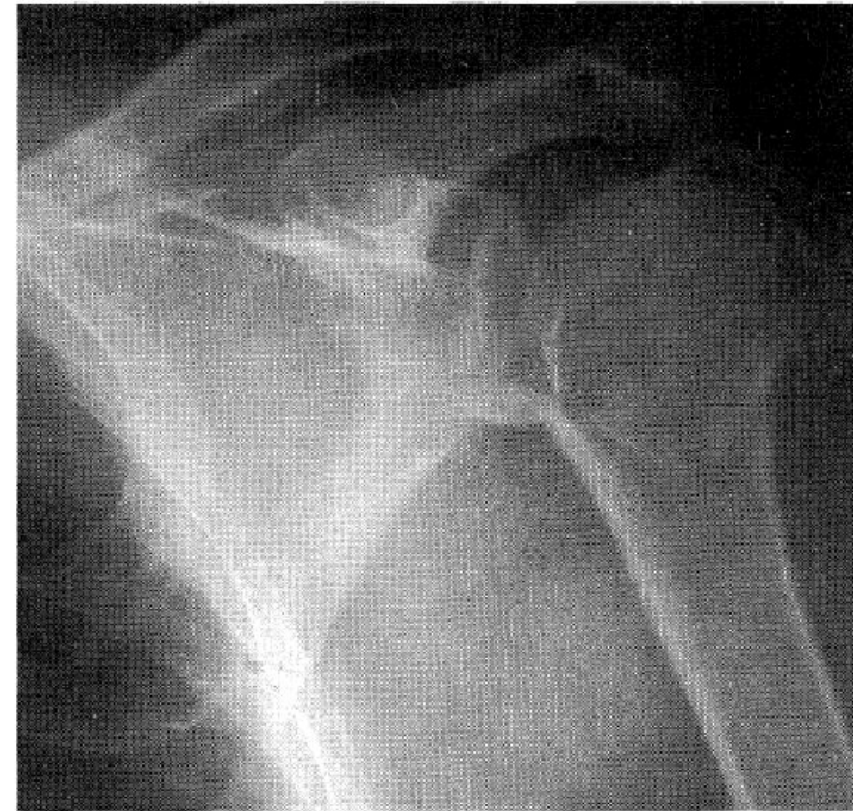
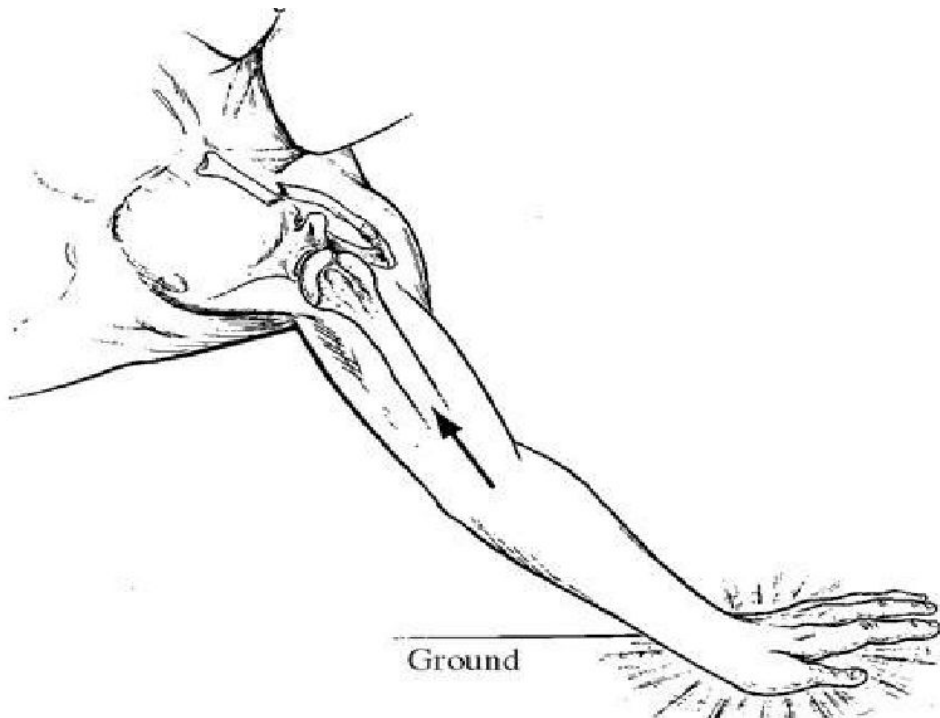


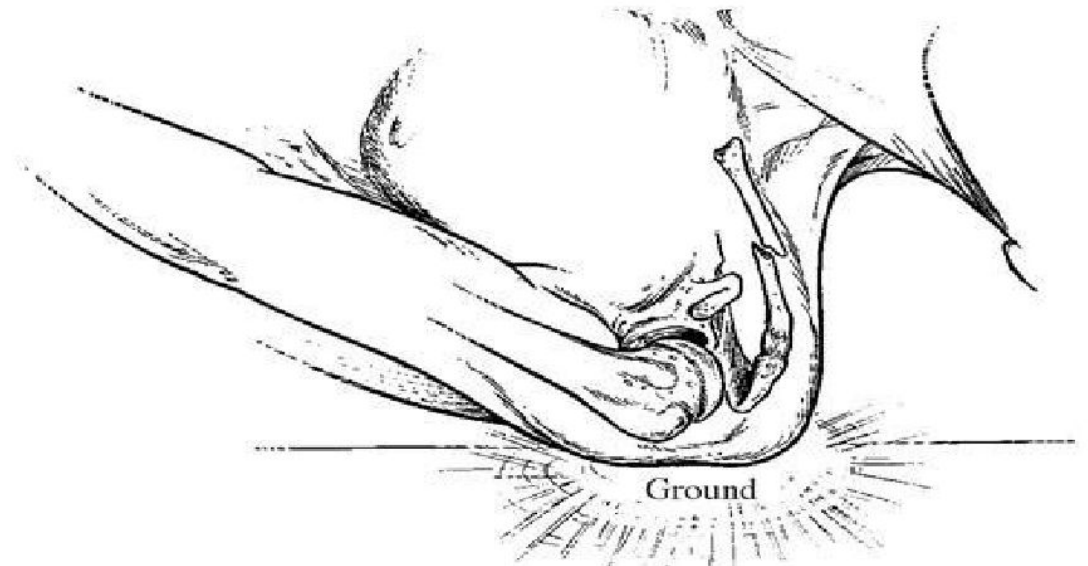
FIGURE 11-7 A three-part fracture of the proximal humerus, with displacement of the head from the shaft and the greater tuberosity from the other two parts.

Mechanism of Injury

- Proximal humeral fractures can be caused by a fall on an elbow or an outstretched hand, especially in an elderly patient, or by trauma to the lateral aspects of the shoulder.
- Seizures can occasionally result in fracture/ dislocation of the shoulder.



A



B

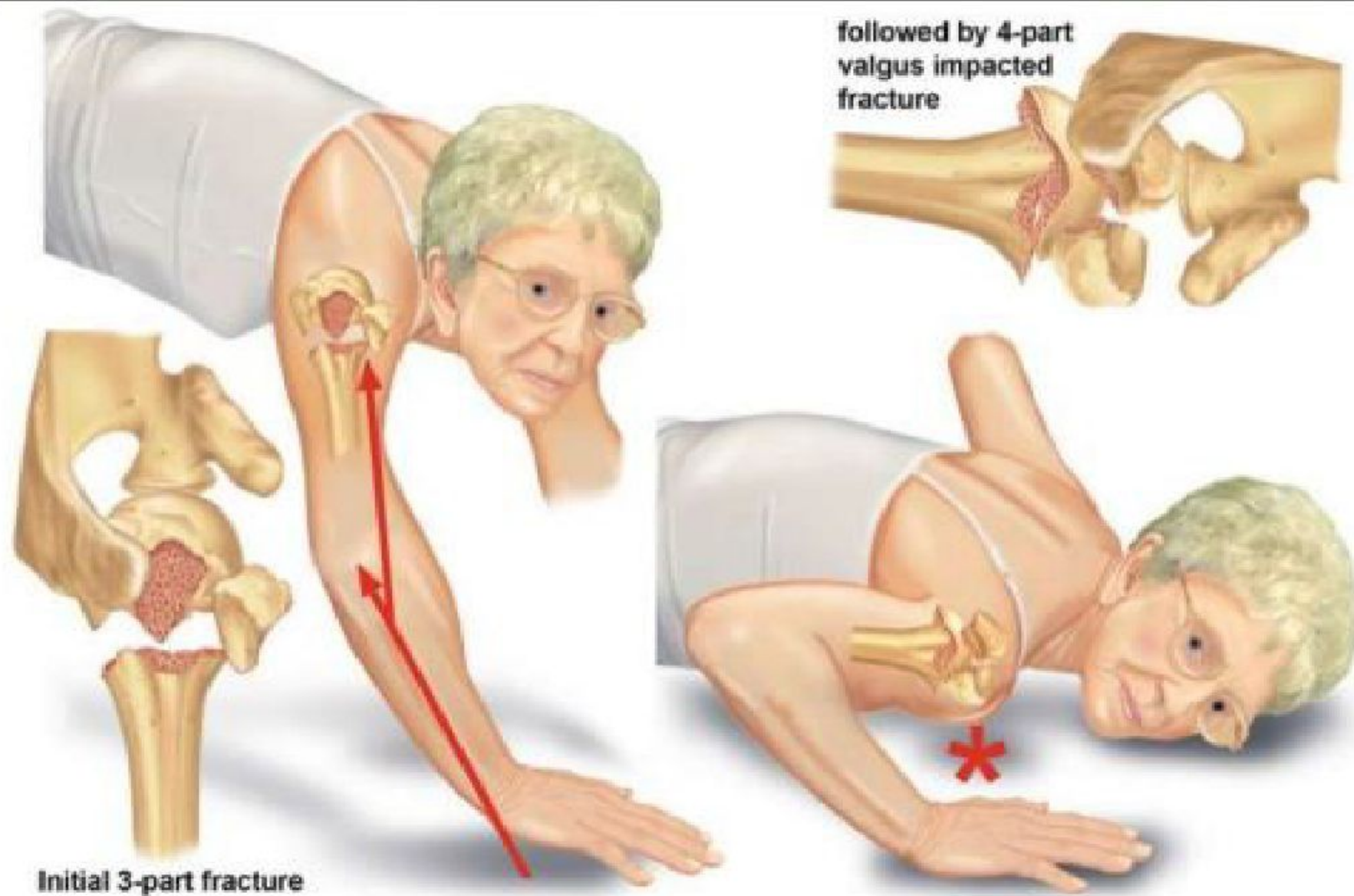


Fig. 2.2 Common mechanism for low energy proximal humerus fractures in elderly patients

Treatment Goals

Rehabilitation Objectives

- 1-Restore the full range of motion of the shoulder in all planes. Frequently, there may be residual loss of range of motion secondary to the fracture
- 2-Improve the strength of the shoulder muscles , especially of the deltoid muscles.
- 3-Improve and restore the function of the shoulder for activities of daily living and sports activities.

Treatment Methods

1. Sling

Indications: undisplaced, impacted, or minimally displaced fractures usually are immobilized for 2 to 3 weeks until the patient's pain subsides.

85 % of proximal humeral fractures are minimally displaced.

2. Open Reduction and Internal Fixation

Indications: two- and three-part fractures and those that may also require repair of the rotator cuff

3. External Fixator

Indications: used for open and severely comminuted fractures.

- **Expected Time of Bone Healing**

6 to 8 weeks.

- **Expected Duration of Rehabilitation**

12 weeks to 1 year.

- **Associated Injury**

Rotator cuff Tears are associated with displacement of either tuberosity and require repair .

Neurovascular Injuries

axillary nerve or posterior cord of the brachial plexus

TREATMENT

Treatment: Early (Day of Injury to One Week)

BONE HEALING

Stability at fracture site: None.

Stage of bone healing: Inflammatory phase.

X-ray: No callus.

Prescription

- **Precautions:** Avoid shoulder motion.
- **Range of Motion:** None at the shoulder and elbow.
Gentle pendulum exercises are allowed for undisplaced fractures.
- **Muscle Strength:** No strengthening exercises to the elbow or shoulder are permitted.

Prescription

- **Functional Activities:** One-handed activities with the uninvolved extremity. The patient needs assistance in dressing, grooming, and preparing meals.
- **Weight Bearing:** None on affected extremity.

Treatment: 2 to 4 Weeks

BONE HEALING

Stability at fracture site: None to minimal.

Stage of bone healing: Beginning of reparative phase.

X-ray: No callus; fracture line is still visible.

Prescription

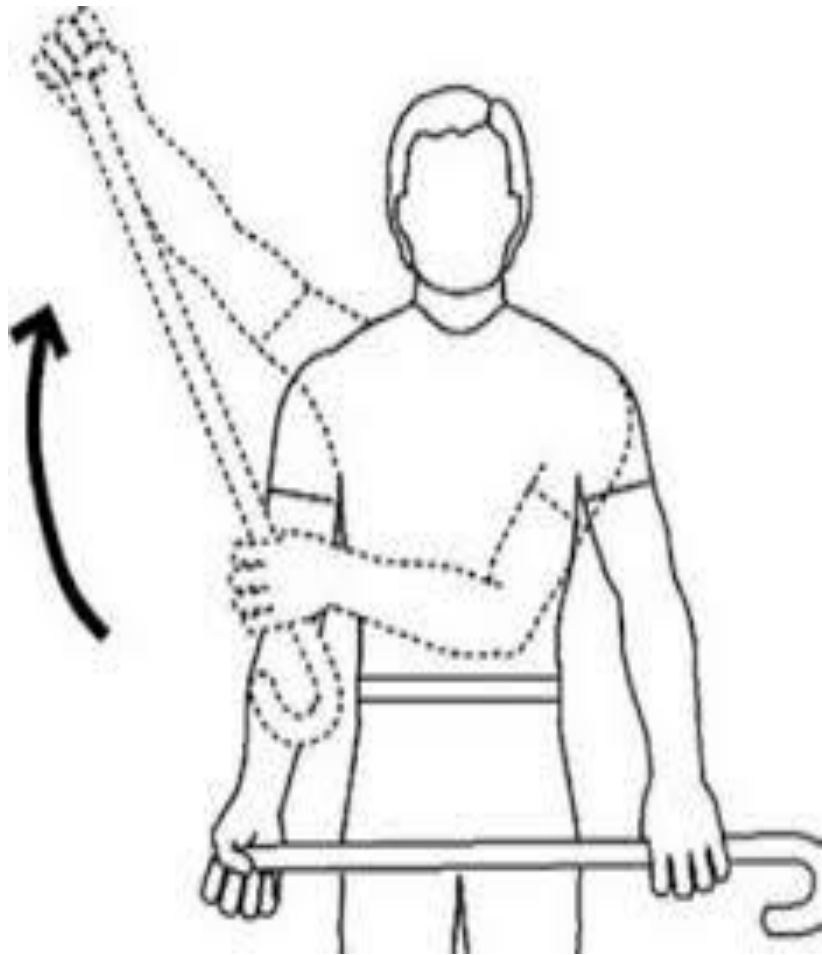
Precautions: Avoid internal/external rotation of the shoulder because they displace the fracture.

- Applying moist heat before and ice after exercises minimizes swelling.
- The patient should do ball-squeezing exercises to maintain the strength of the intrinsic muscles of the hand.
- **Sling**
 - At the end of 2 weeks, the sling is removed
 - The sling is replaced at night for support or during the day when the patient feels a need for it.
- **Open Reduction and Internal Fixation**
 - Remove sutures or staples from the operative site at 2 weeks and check for evidence of superficial infection (erythema, drainage)

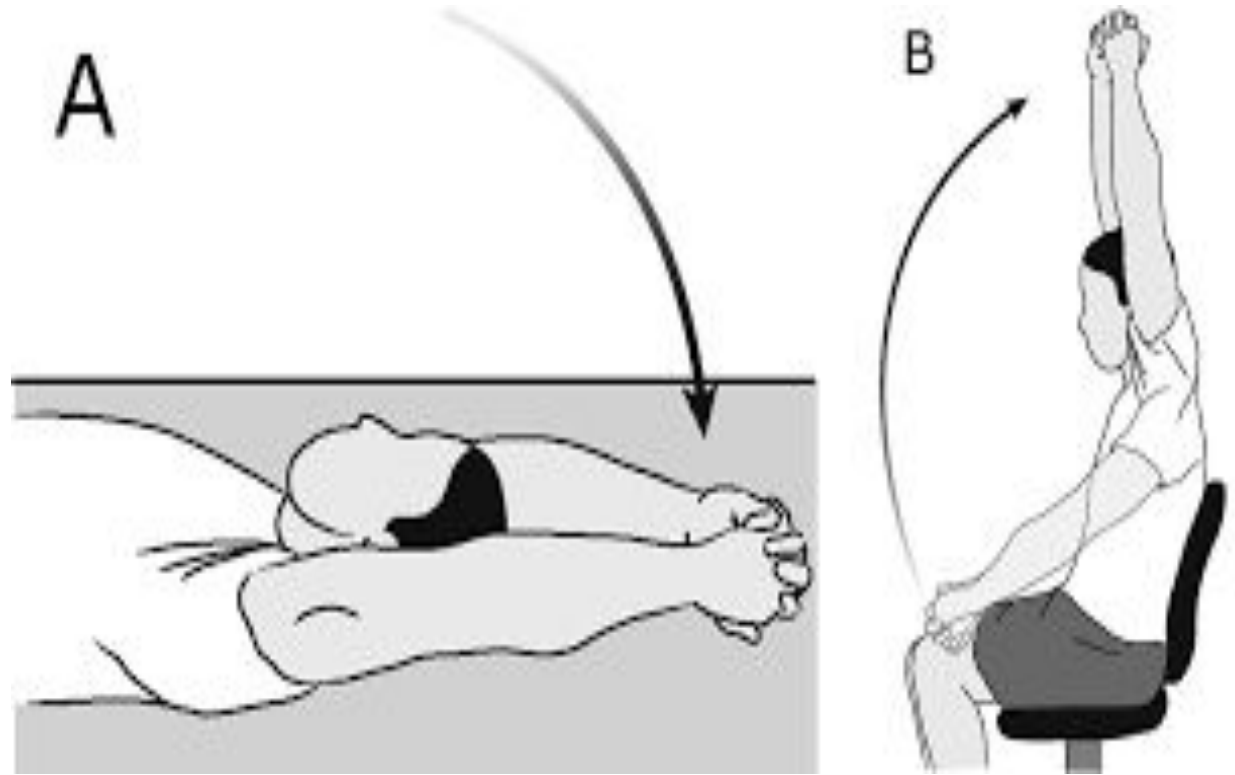
- **Range of Motion:** Patients treated with a sling should start active to gentle passive exercises to the shoulder e.g. lying supine, the patient can try to flex the shoulder up to 180 degrees using the other arm.

Patients treated surgically should start passive range of motion in supine position. No active range of motion to the shoulder.

- **Muscle Strength:** Isometric shoulder exercises in patients treated with sling only. No strengthening exercises for patients treated with surgical intervention.
- **Functional Activities:** Patient continues with one handed activities.
- **Weight Bearing:** None on affected extremity.



Active-assisted shoulder abduction.



Active assistive flexion exercises

Treatment: 4 to 6 Weeks

BONE HEALING

Stability at fracture site: With bridging callus, the fracture is usually stable.

Stage of bone healing: reparative phase.

X-ray: Bridging callus is visible.

Prescription

Precautions: Do not apply force in attempting to regain the full range of motion.

Range of Motion: Shoulder-limited range Flexion/abduction up to 100 to 110 degrees e.g. wall-climbing exercises (fingers against the wall and reaching up)

- Internal/external rotation-limited , Elbow-full range of motion.
- Surgically treated patients may continue with passive ROM exercises.

Muscle Strength:

- Avoid exercises to the deltoid if it is incised during surgery
- Isometric and isotonic exercises to the elbow muscles.


Functional Activities: Involved extremity used as tolerated. Patient still needs assistance in house cleaning and preparing meals.

Weight Bearing: None on affected extremity.

- Check for early evidence of adhesive capsulitis (frozen shoulder)



wall-climbing exercises



Codman's pendulum.

Treatment: 6 to 8 Weeks

BONE HEALING

Stability at fracture site: With bridging callus, the fracture is usually stable.

Stage of bone healing: reparative phase.

X-ray: Bridging callus is visible.

Prescription

Precautions: Avoid forced range of motion.

Range of Motion: Active, active-assistive, and passive range of motion to the shoulder and elbow in all planes, to tolerance.

Muscle Strength:

- Continue isometric exercises to the shoulder , and isotonic exercises to the elbow.
- Start progressive resistive exercises for patients treated with a sling.

Functional Activities: The involved extremity is used for self-care and feeding.

Weight Bearing: Weight bearing as tolerated

Treatment: 8 to 12 Weeks

BONE HEALING

Stability at fracture site: stable.

Stage of bone healing: Remodeling phase.

X-ray: Abundant callus; fracture line begins to disappear.

Prescription

Muscle Strength:

- Resistive exercises to the shoulder with gradual increases in weights.

Weight Bearing: full Weight bearing.

References

1. David J. Magee, Pathology and Intervention in Musculoskeletal Rehabilitation , 2nd ed. 2016
2. Rehabilitation for the Postsurgical Orthopedic Patient, 3rd Edition. 2013
3. Treatment and Rehabilitation of Fractures. 2000
4. David J. Magee , Orthopedic Physical Assessments Atlas And Video: Selected Special Testes and Movements , 5th ed. 2011
5. James Wyss, Therapeutic programs for musculoskeletal disorders .2013

Thanks