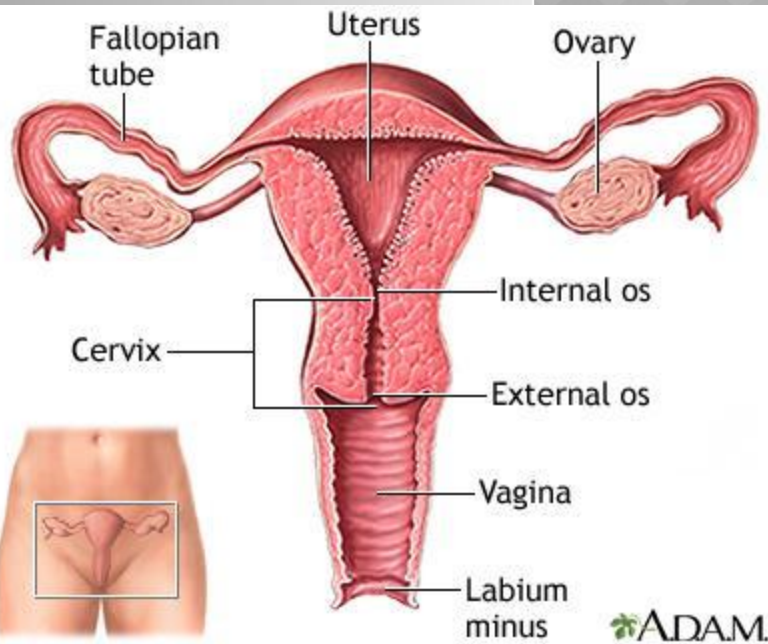
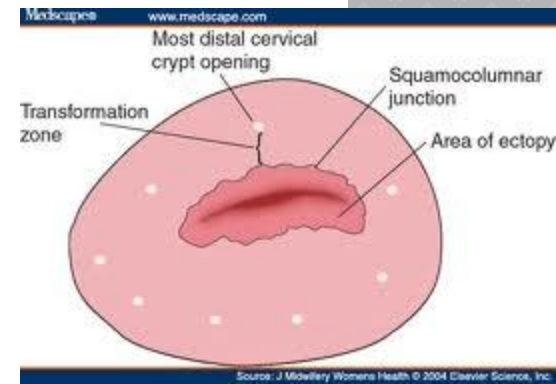
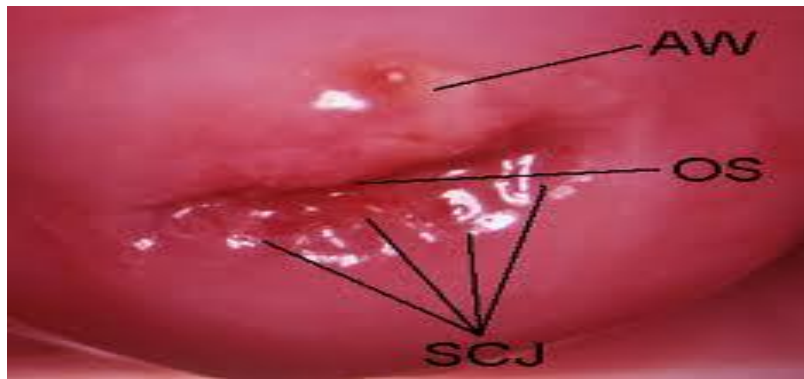


PREMALIGNANT CONDITIONS OF THE CERVIX



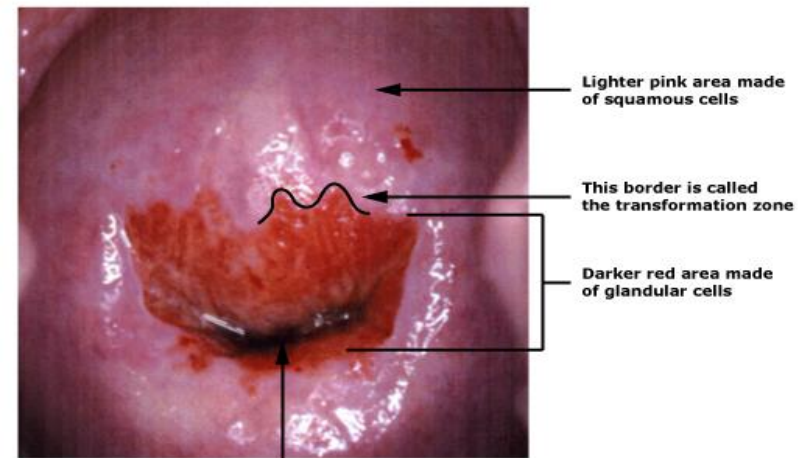
CERVIX

- The cervix is a tubular structure. It is composed of stromal tissue which is lined by squamous epithelium in the vagina (**ectocervix**) and columnar epithelium within the cervical canal (**endocervix**).
- The meeting of the two types of the epithelium is called **squamocolumnar junction SCJ** and this is usually at the ectocervix.



The position of the SCJ changes throughout the reproductive years.

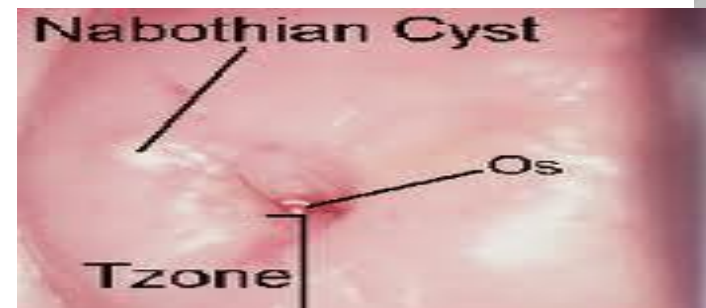- In children it lies at the ectocervix that is just at the external os.
- At puberty and during pregnancy it extends outwards as the cervix enlarges and in adult life it returns to the ectocervix through the process of metaplasia



Cervical OS (opening)-some women require a biopsy of

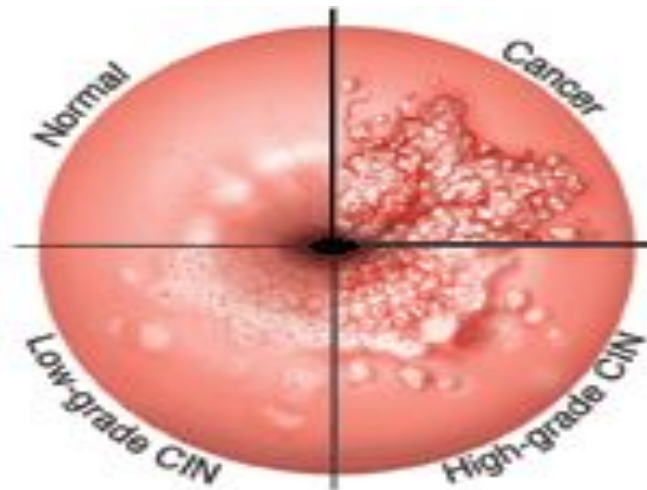
TRANSFORMATION ZONE:

- is an important area on the cervix which is defined as the area where the original SCJ was to the current SCJ and it includes areas of metaplasia.
- Occasionally, when the mucous columnar epithelium is covered by the squamous epithelium there is retention of the mucus- this is called a **nabothian follicle**.
- The transformation zone TZ is the site where pre-malignancy and malignancy develop.

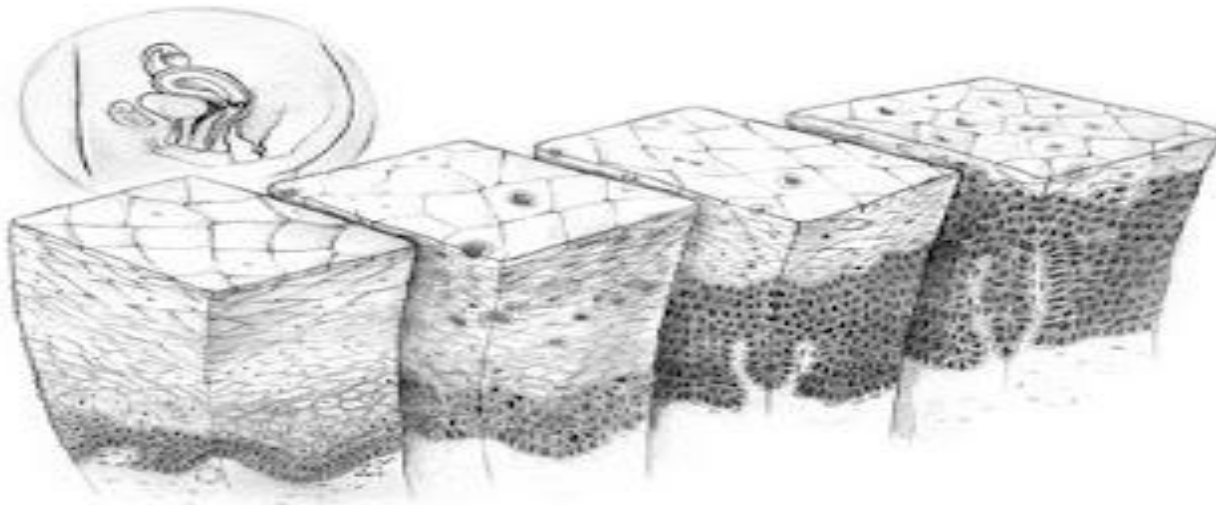


DEFINITIONS AND TERMINOLOGY:

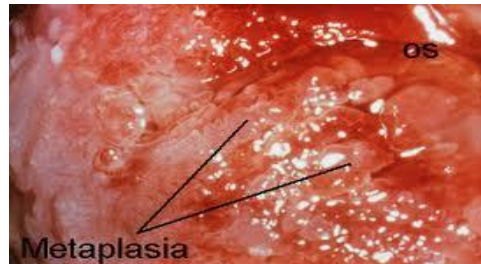
- CIN: cervical intraepithelial neoplasia,
- Dysplasia: a histological term describing architectural abnormalities within the tissue.
- Dyskaryosis: a cytological term describing the nuclear abnormalities- not synonymous with dysplasia



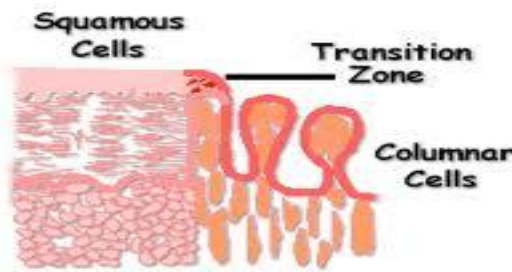
- ◉ CIN I: minimal dysplasia.
- ◉ CIN II: moderate dysplasia.
- ◉ CIN III: severe dysplasia or CIS carcinoma in situ (CIN III, severe dysplasia and CIS are all different names for the same thing that is early cervical cancer)



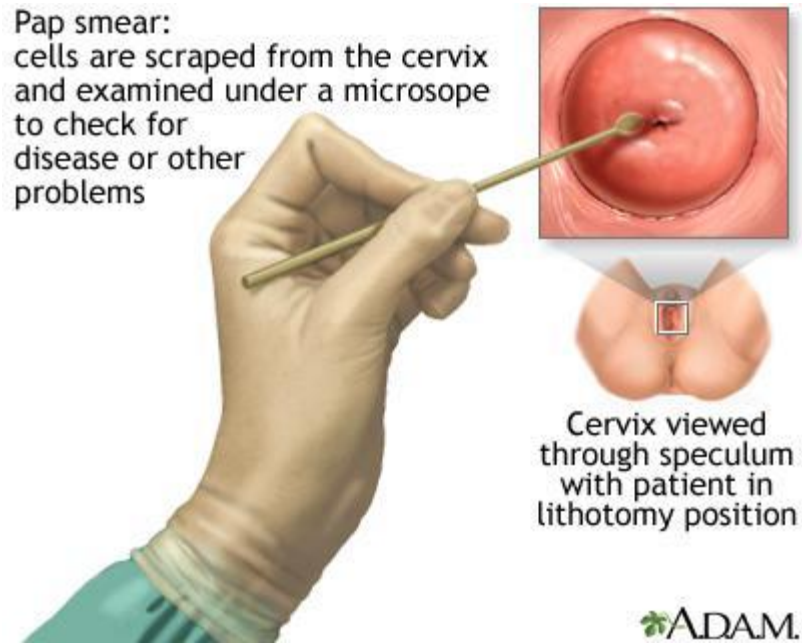
- Metaplasia: a physiological process whereby columnar epithelium is replaced by squamous tissue in response to the acid environment of the vagina.



- Squamocolumnar junction SCJ: where squamous and columnar tissue meets, this is not fixed, but is affected by metaplasia.

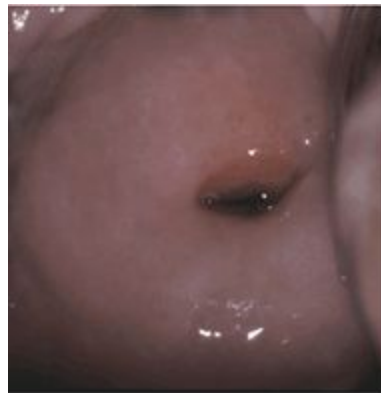


- Paps smear: or cervical smear- cytological test described by Papanicolaou.

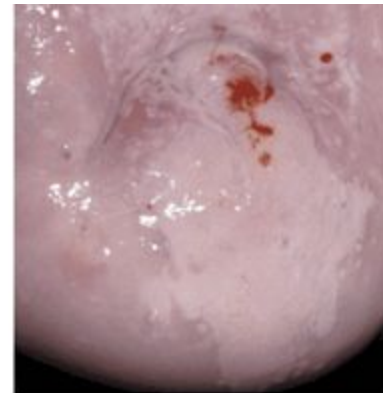


CIN

- CIN is a condition characterized by new cellular growth (**neoplasia**) in a normal tissue. Once CIN is diagnosed this alarms us that an abnormal tissue has been diagnosed in the cervix of that lady.
- The most important causative factor is **HPV** which could cause other combined genital and anal cancer.



Healthy

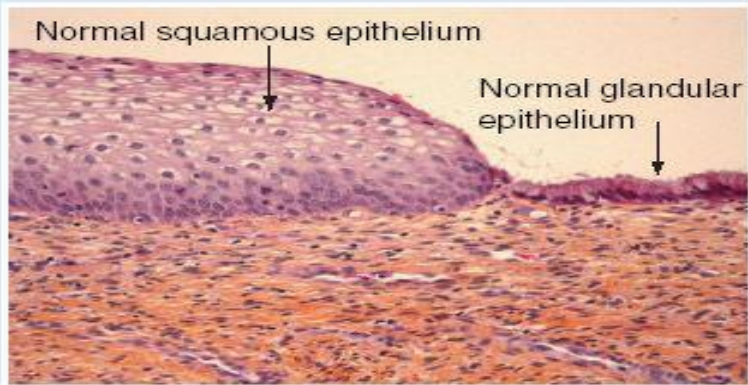


CIN I

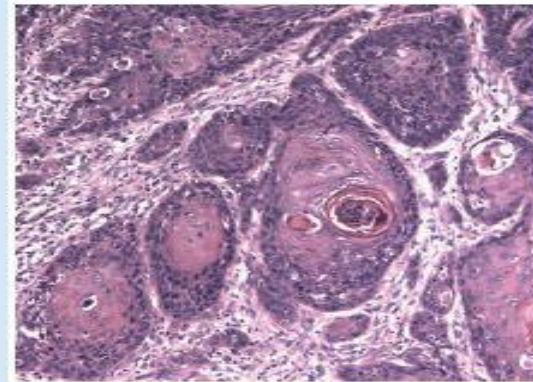
- However, CIN is much more common than the other types of genital neoplasia.
- The tissue changes associated with CIN signify presence of premalignant or precancerous condition **i.e. CIN is essentially a precursor to invasive cervical** cancer and is collectively composed of cells that have undergone abnormal individual changes that is with abnormal mitotic activity and leads to formation of a lesion in the cervix.

CLASSIFICATION OF CIN:

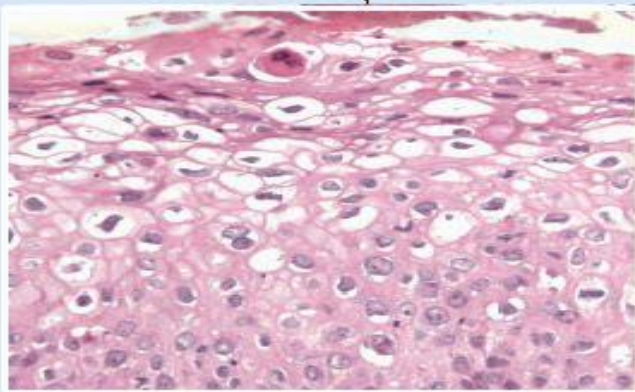
- ◉ A revised classification has been introduced:
- ◉ Low - grade lesion CIN I and HPV associated changes with unknown but a likely low progressive potential.
- ◉ High-grade lesion CIN II and CIN III that is likely to behave as cancer precursors.
- ◉ Simpler classification is according to **Bethesda** divided to:
- ◉ Low grade squamous intraepithelial lesion (LSIL) = CIN I.
- ◉ High grade squamous intraepithelial lesion (HSIL) = CIN II and CIN III



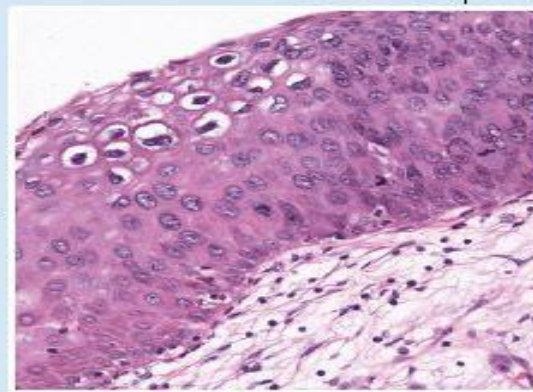
Transformation zone



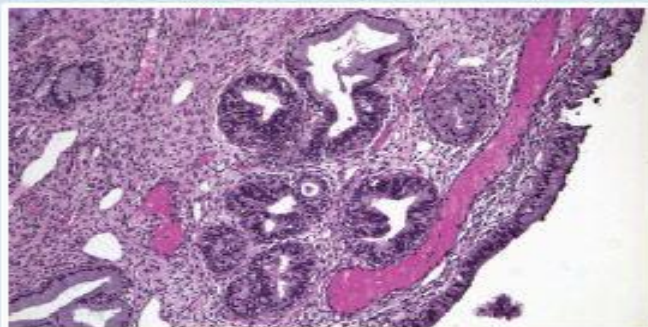
Squamous cell carcinoma



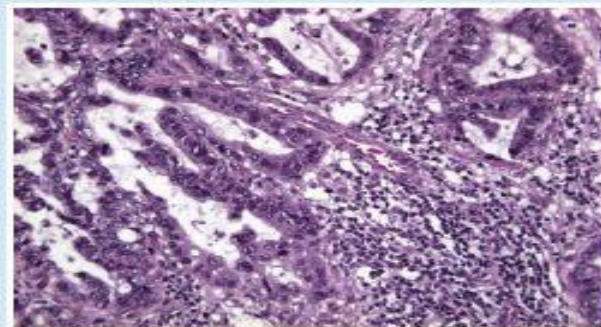
CIN 1 with HPV features



High-grade CIN (CIN 2-3)



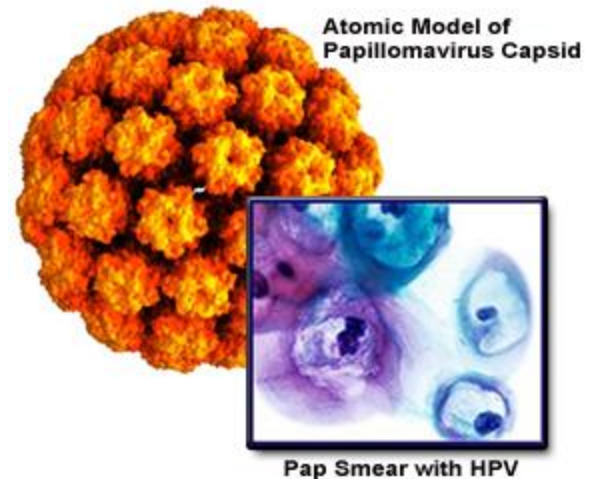
Adenocarcinoma *in situ*



Invasive adenocarcinoma

AETIOLOGY

- Human papillomavirus HPV infection is the essential prerequisite for the development of cervical malignancy.
- HPV infection is extremely common with up to 80% of sexually active women being HPV positive at some point during their lifetime.



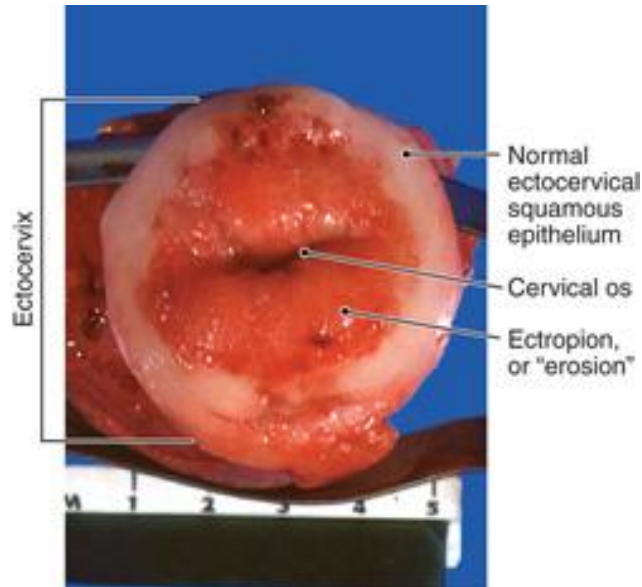
- Using the incidence of genital wart as a marker, the incidence appears to be raising five fold in the female population and eight fold in male population with approximately 15% prevalence of the oncogenic HPV types 16 and 18.
- However most infections are usually transient with 90% of women clearing the infection within 2 year and young competent women are able to eliminate the infection.

RISK FACTORS

- ◉ Smoking reduces local cervical immunity.
- ◉ Multiple sexual partners.
- ◉ Having a partner with multiple sexual partners or with sexually transmitted disease.
- ◉ Presence of other sexually transmitted disease like HIV and genital herpes.

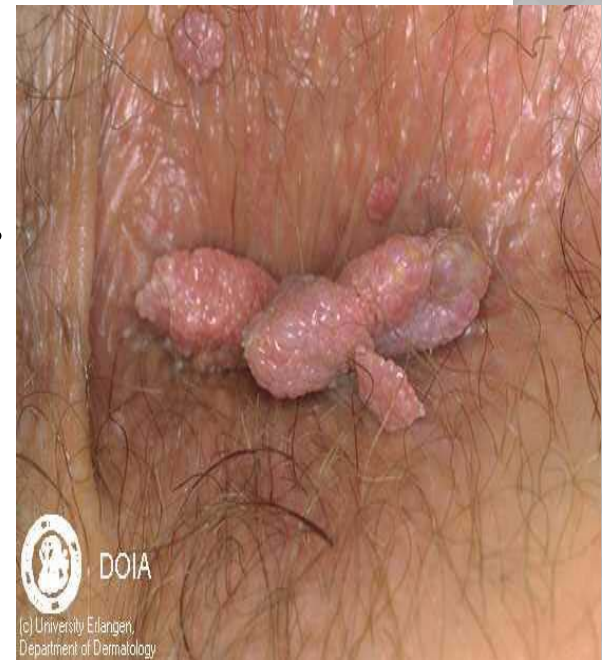RISK FACTOR

- Long term use of contraceptive pill.
- Immunosuppression or use of anticancer drugs.
- Being born to mother used diethylstilbestrol.



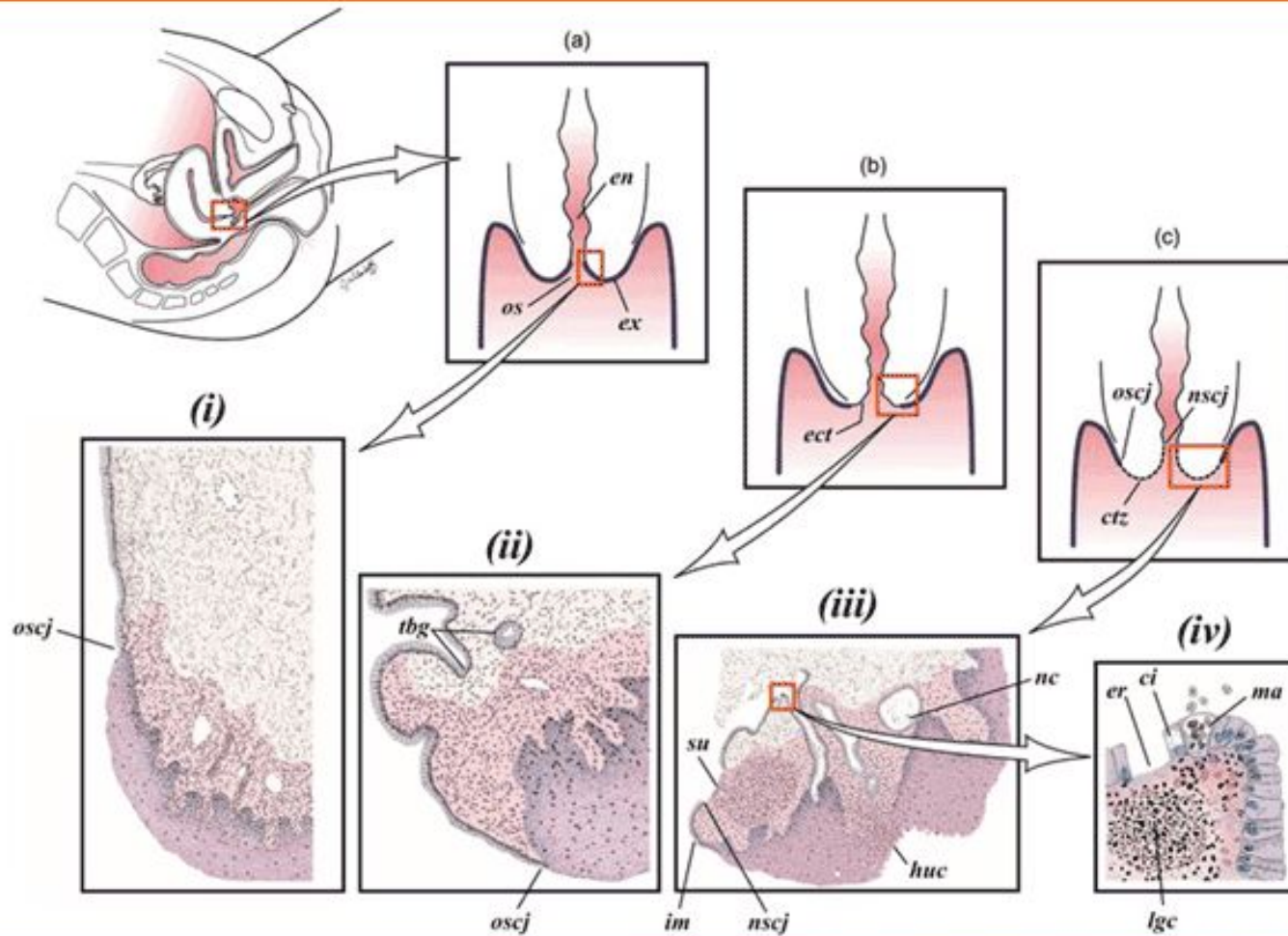
CLINICAL FEATURE:

- Often it's a symptomatic and diagnosed during routine annual Pap smear,
- non-specific:
- Genital lesion (wart)
- Abnormal lower genital bleeding.
- Abnormal vaginal discharge.
- Vague lower abdominal pain.



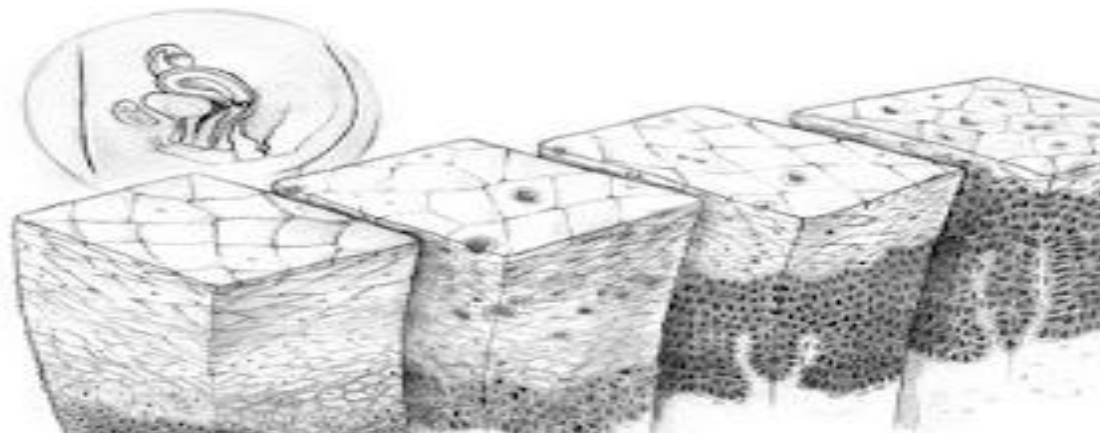
PATHOPHYSIOLOGY:

- Metaplasia is a normal finding but this may be disrupted by some factors like HPV, smoking or immunosuppression and etc.. And lead to development of disorder squamous epithelium called dysplasia which characterized by:
 - Lack of normal maturation of cell as they move from basal layer to superficial layer.
 - Large nuclei more variable in size and shape.
 - High mitotic activity means more rapidly dividing cell.



THESE CELLULAR CHANGES ARE DIVIDED TO CIN I, II AND III DEPENDING ON :

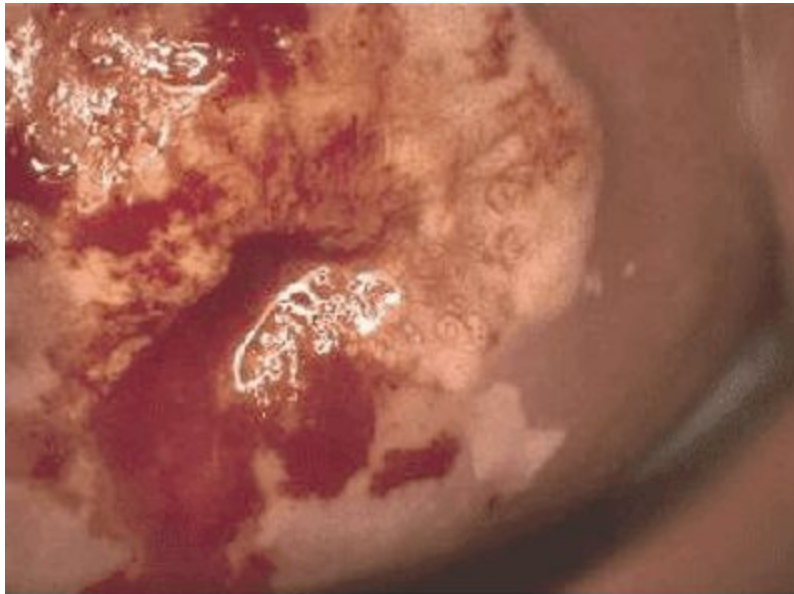
- Severity of atypia.
- Thickness of the epithelium involved.
- CIN I means $1/3$ of the epithelium from the basal layer is involved.
- CIN II means $2/3$ of the epithelium from the basal layer is involved.
- CIN III means no maturation **throughout** the full thickness.



NATURAL HISTORY

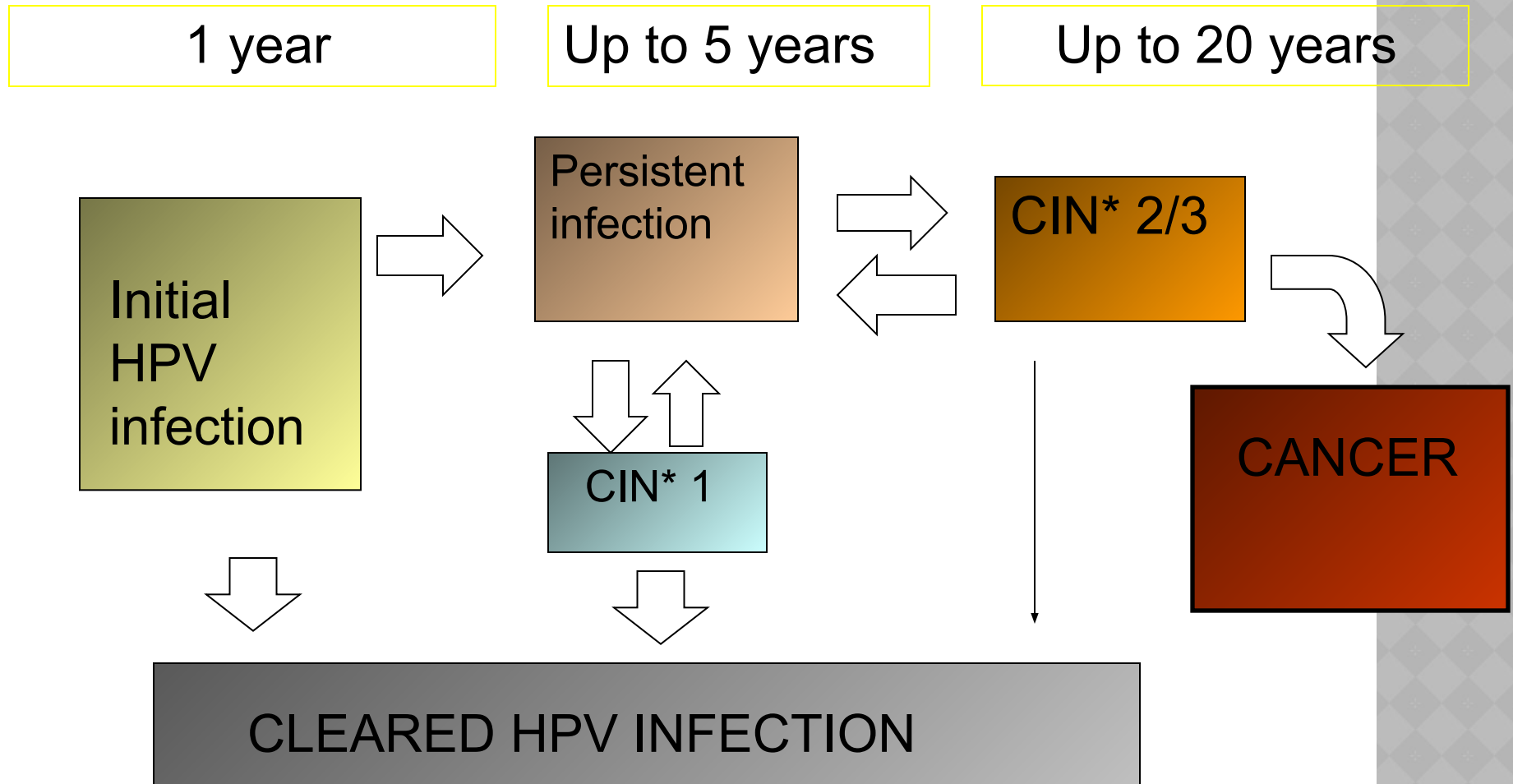
Regression and progression of CIN may occur. Spontaneous regression of low grade disease is common and is likely to occur through the patient's own cell mediated immunity.

- ◉ High grade lesion is less likely to regress spontaneously and requires treatment as there is risk of progression to cancer.



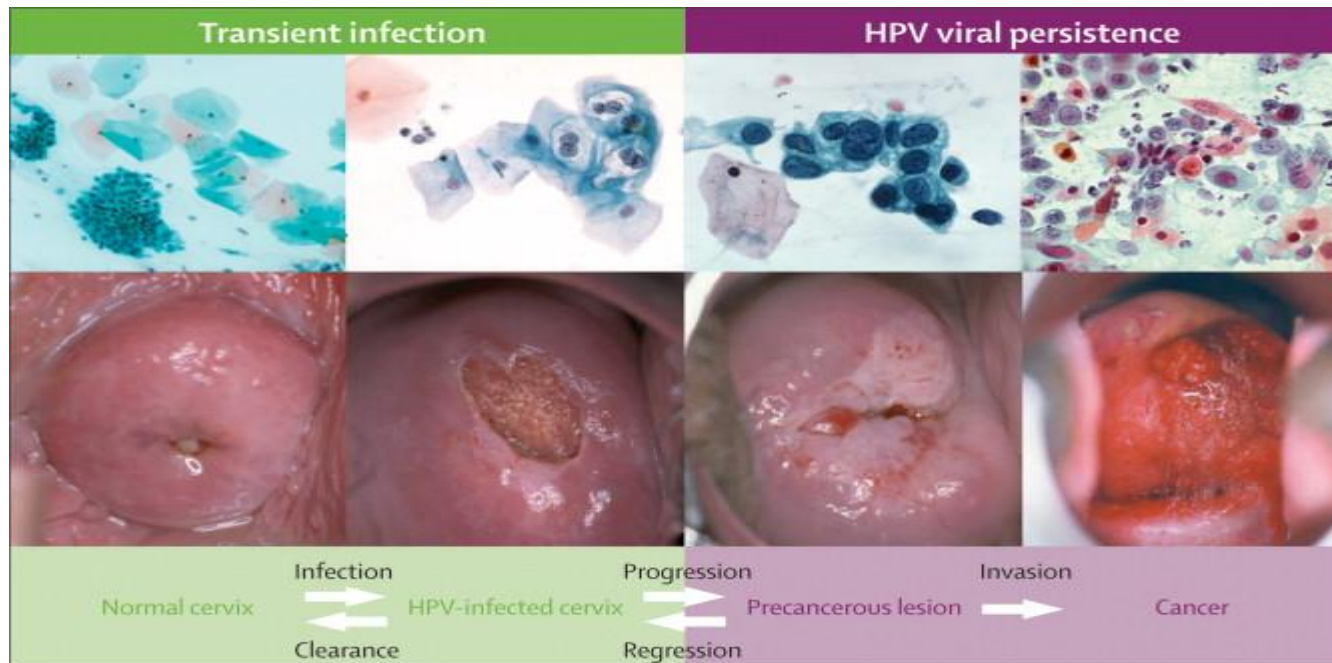
A cervix with CIN III

NATURAL HISTORY OF HPV INFECTION AND CIN



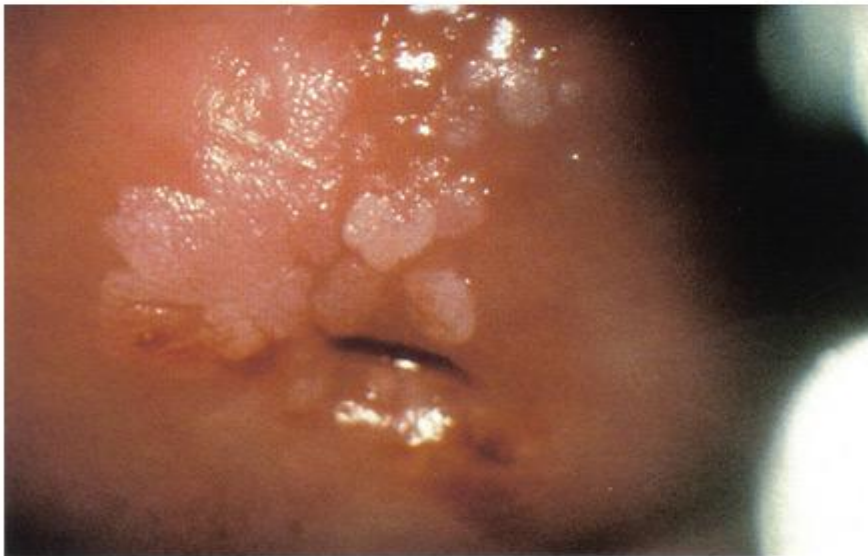*cervical intraepithelial neoplasia

- If left untreated 20% of patients with high grade abnormalities may develop cancer of cervix. Reasons for this remain unclear but may include reduced host immunity, oncogenic HPV and smoking.

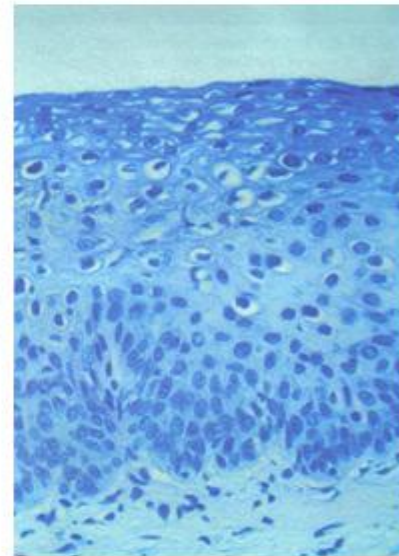


SCREENING:

- . Even the most sever CIN III take several many years to change to cancer, this mean we can apply screening test to do early detection of premalignant condition and do appropriate treatment and follow up.



A



B

SCREENING IS DONE BY USING PAP CYTOLOGICAL TEST

- Since 1988, the UK has offered population based cervical screening for women. Women aged 25 and 64 are tested routinely as follow:
 - **25** *first test*
 - **25-49** *every 3 years*
 - **50-64** *every 5 years*
 - **64+** *only screen those who have not screened since age 50 or has recent abnormal test*

TEST PERFORMANCE:

- Originally the “Pap” smear was introduced by Papanicolou, where cell removed from the cervix using a wooden spatula and placed on glass slide and fixed. This was then examined by a cytologist for the immature squamous cells sheds from the area of the CIN.

- Now Pap smear is superseded by liquid based cytology where a small brush is used to sample cells from the transformation zone and the brush head placed in the fixative. This is then spun down and read by cytologist.
- Normal cervical cell has small nuclei that is flattened and pyknotic but abnormal cell has large nuclei, cytological atypia and high N/C

- An abnormal smear can show cells in different degree of maturity (dyskaryosis) and is divided into:
- **Mild dyskaryosis** and borderline changes (low grade)
- **Moderate and sever dyskaryosis** (high grade)
- Abnormal smears act as a mean of referring the patient to the colposcopic clinic for further assessment.

- The sensitivity of cervical smear in picking up women with CIN is around 70 percent, however, as there is slow progression for most women with CIN to cancer, if a lesion is missed then this should be picked up on subsequent smear. The specificity is 90%.
- If the test is negative the patient is re-placed on routine recall.

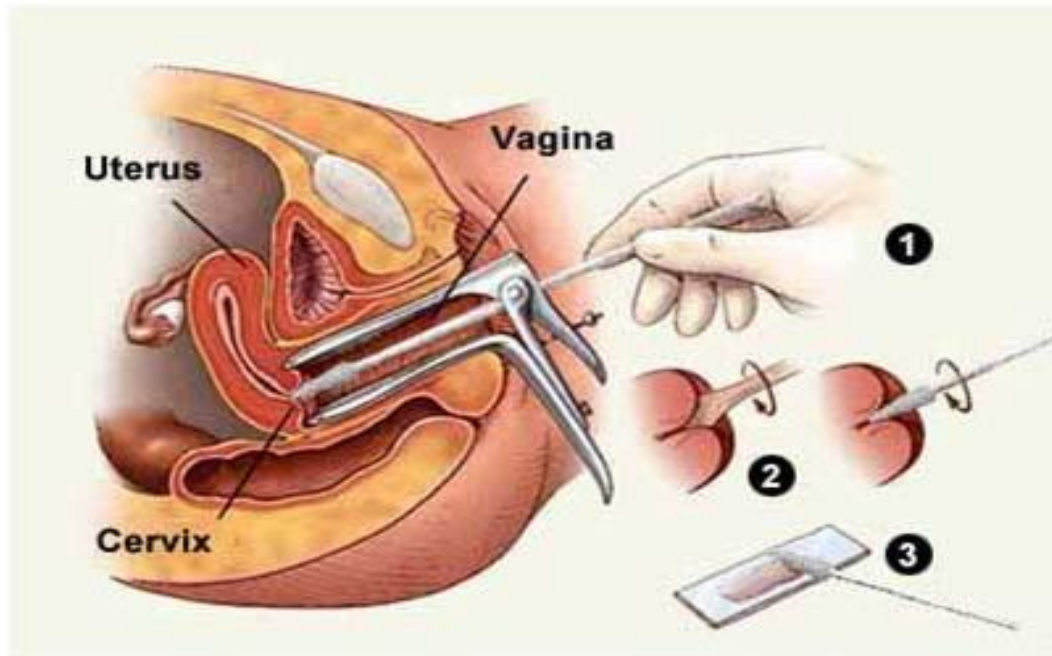
- If the smear shows low grade changes the patient offered repeated test in next 3-6 months and managed accordingly and if test shows high grade lesion the patient is urgently referred to colposcopy.

TECHNIQUE OF SMEAR:

- Patient in lithotomy position under good light,
- start by inspection (spread labia and look for any discharge or abnormal growth and ulcer) then
- insert warm vaginal speculum (not too hot), do not use any lubricant , Vaseline or K-Y jelly. The blades of speculum is kept closed until is fully inserted.



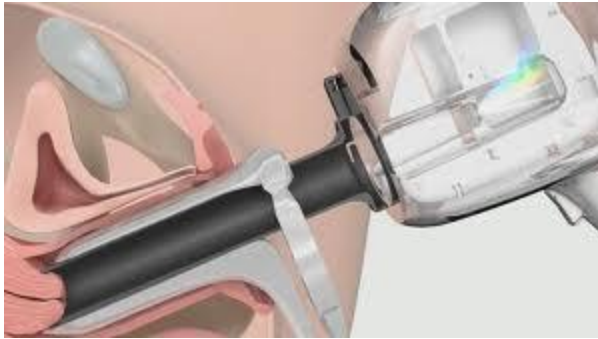
- Identify the SCJ that is the junction of pink cervical skin and red endocervical canal then use Ayres spatula is used to sample the cervix



- ◉ the concave end is used to fit the cervix and should be rotated 360 degree
- ◉ do not use too much force as it may cause bleeding and pain
- ◉ or too little force as it may lead to in adequate sample).
- ◉ The smear should be as thin as possible,
- ◉ properly labeled,
- ◉ allow fully drying before packaging and spraying with fixative within 10-15 seconds.

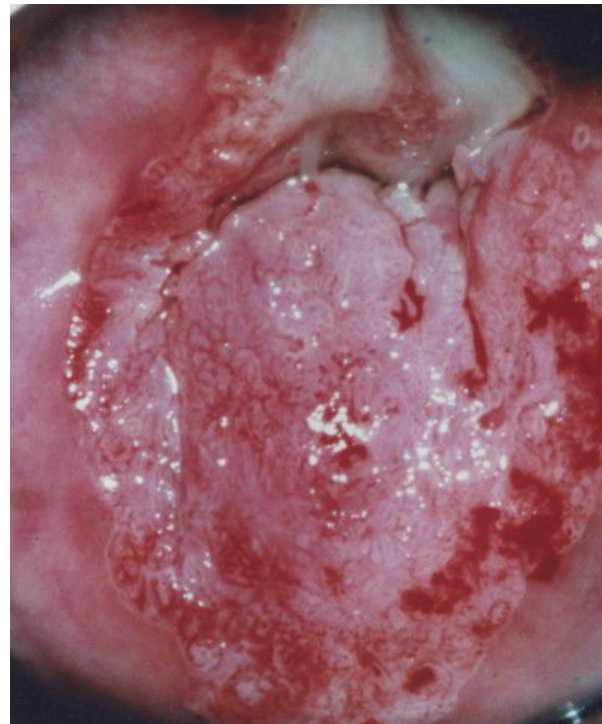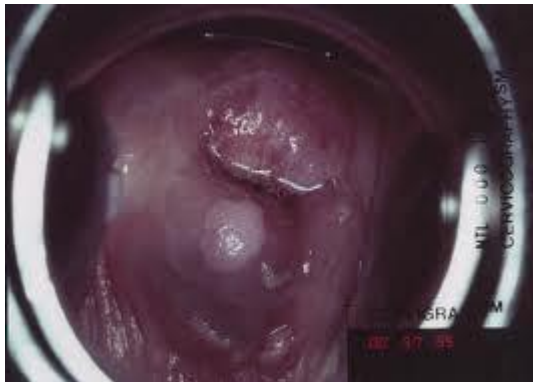COLPOSCOPY:

- Colposcopy is the outpatient examination of the magnified cervix using a light source. It is used for both diagnosis and treatment. After inserting a speculum the cervix is examined using Binocular operative microscope under magnification (5-20 time).



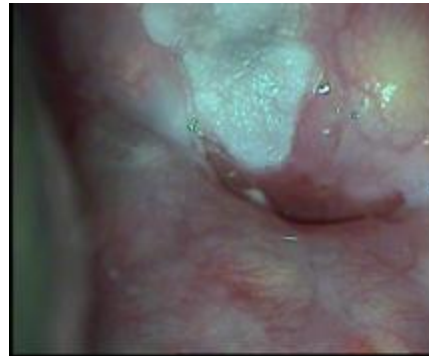COLPOSCOPY

- **5% acetic acid is applied**, as it causes nucleoproteins within the cells to coagulate. Therefore areas of increased cell turnover, for example CIN will appear white.



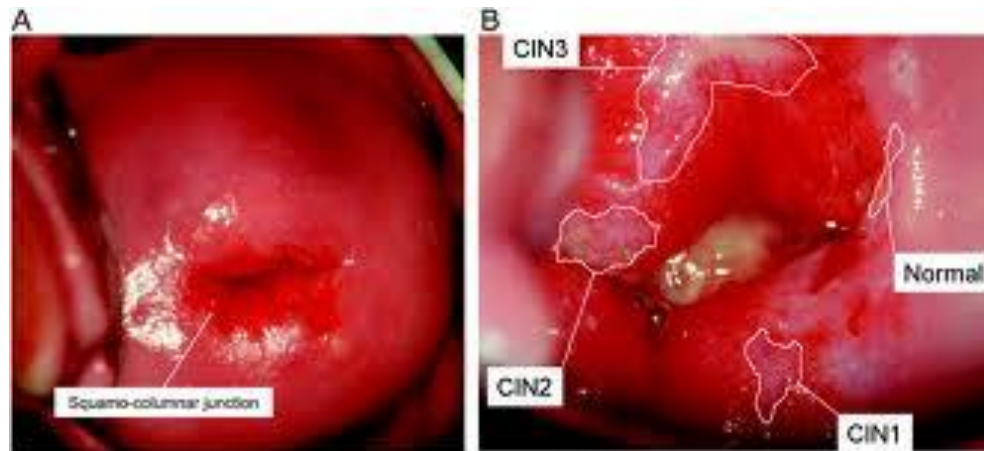
COLPOSCOPY

- **Schiller's test:** by application of iodine, areas of CIN lack the presence of intracellular glycogen and therefore are stain yellow as opposed to normal which stain brown when iodine is applied.



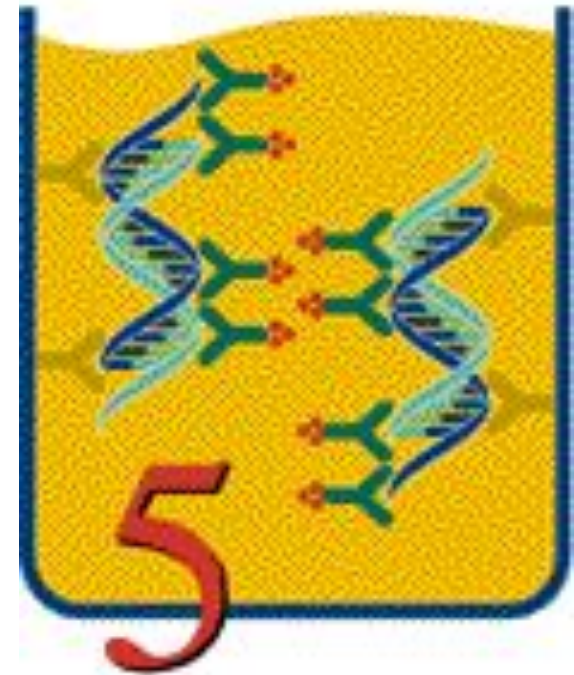
COLPOSCOPY

- Abnormal vascular pattern like punctuate or mosaic.
- Biopsy is taken from the most abnormal site.
- Colposcopy is deemed unsatisfactory if TZ is not viewed adequately.



HPV DNA TESTING:

- As HPV is the main causative factor of CIN and cervical cancer, recently detection of HPV DNA in serum has been introduced to screening program but this is still used under research.



TREATMENT OF CIN:

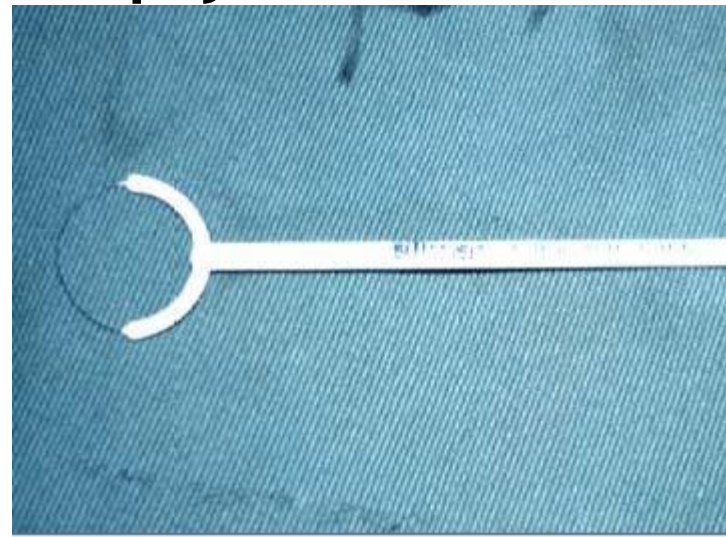
- The aim of treatment is to make the post-treatment test negative while minimizing harm to the patient.
- Low grade lesion will regress spontaneously in over 60% of cases and usually they require no treatment but careful follow up by with colposcopy and cytology in next six month after initial diagnosis.
- If CIN is not resolve on follow up tests or progress to high grade then treatment is needed to avoid development of active disease.

TREATMENT

Could be out patient or in patient

Excisional methods like:

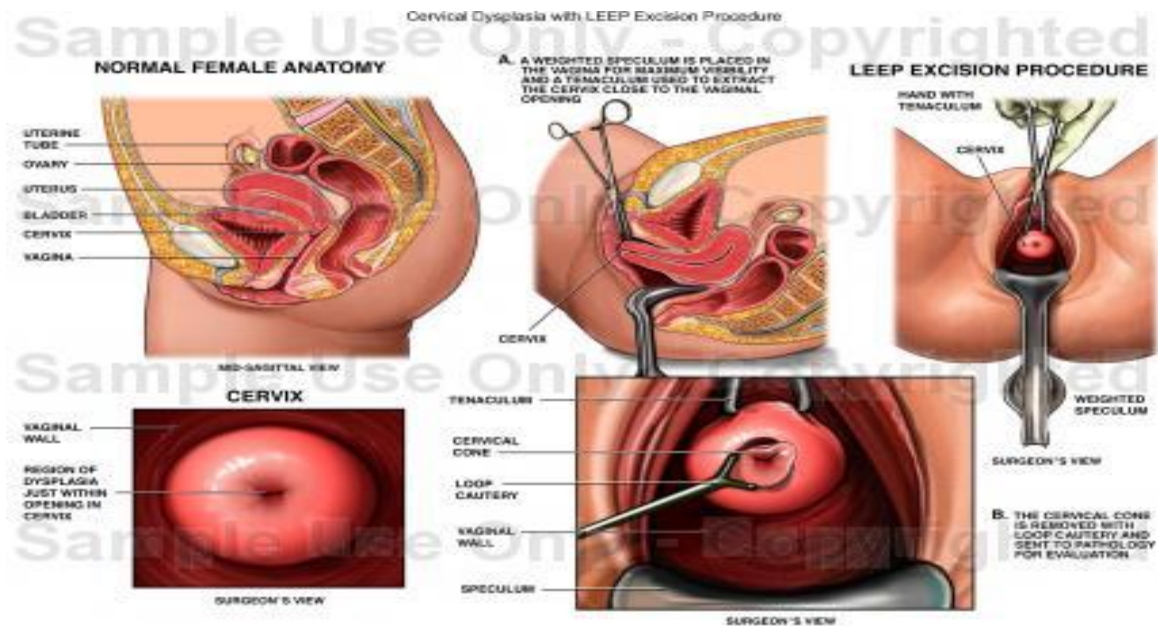
- ⦿ Loop electrosurgical excision (LEEP) and large loop excision of TZ (LLETZ)
- ⦿ Laser TZ excision
- ⦿ Knife, laser or loop cone biopsy.
- ⦿ Hysterectomy.



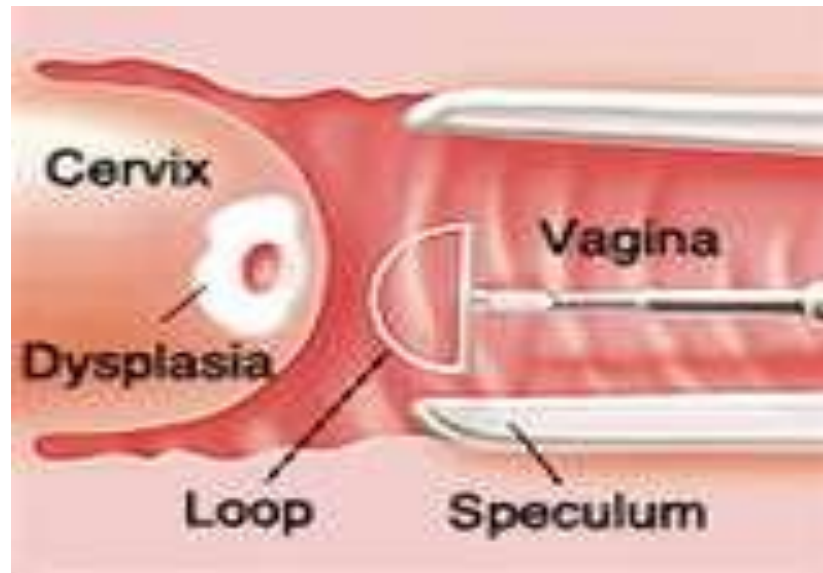
Ablative methods:

- ⦿ **Cryocautery.**
- ⦿ **Electrodiathermy**
- ⦿ **Coagulation**
- ⦿ **Laser.**

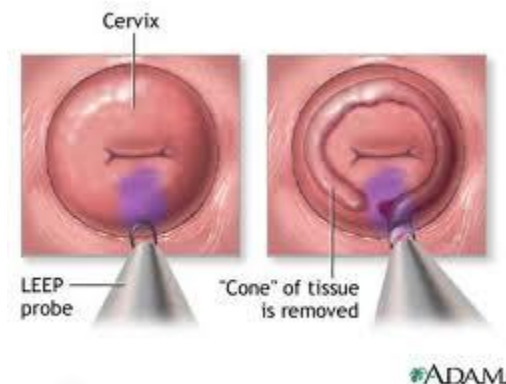
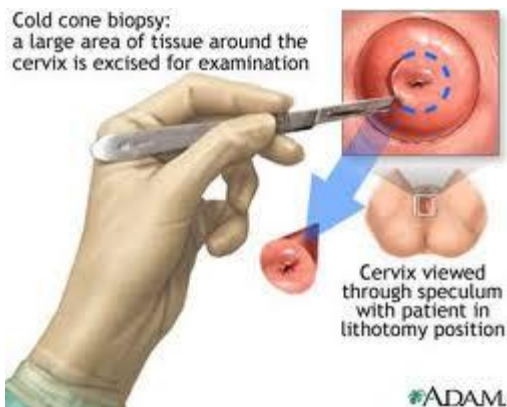
- The favored method is LLETZ which is done as outpatient under local anesthesia and take 15 minutes and should go 10 mm deep down cervical stroma,



- the advantage is that its effective (**95% test negative post treatment**), cost-effective and provide specimen for histology. The disadvantage may lead to poor obstetric outcome as it may weaken the cervix



- Cone biopsy or conization is both treatment and diagnosis and done under anesthesia.
- If hysterectomy is performed (usually after completion of family), annual vault smears should be performed.



FOLLOW UP:

- Close follow up after initial treatment by regular cervical smear is needed after six month then yearly for ten year, as the risk of recurrence and cancer is remains.

HPV VACCINES

- Recently HPV vaccines have been developed to prevent primary infection with certain oncogenic HPV types (16,18,31,33).
- Many countries have a national program with the sole aim to reduce death rate .
- The evidence to date suggests that the vaccination is not only effective in preventing the development of high grade CIN, but is safe to be given.
- Its debatable.