

Introduction to the Practice of Medicine - II



Examination of the Abdomen

Tuesday, January 28, 2003

Michael J. Klamut, M.D.



Examination of the Abdomen

Session Objectives:

- Describe relevant anatomy and physiology as it pertains to the examination of the abdomen
- Demonstrate the steps in examining the abdomen using illustrations and a SP
- Review common abnormalities encountered on the Physical Examination of the abdomen



Examination of the Abdomen

- Introduction:
 - The Medical History is an account of the events in the pt's life that have relevance to the mental/physical health of the pt. Accurate information is essential before undertaking the PE of the abdomen.



Examination of the Abdomen

- *Pain* is a common symptom of diseases of the abdomen It is important to assess different aspects of a pt's abdominal pain so that a reasonable Differential Diagnosis can be formulated



Examination of the Abdomen

- Important aspects of *abdominal pain*:
 - Location and radiation of pain
 - Character of pain (cramping, sharp, dull, burning, constant)
 - Timing of the pain
 - Exacerbating/alleviating features
 - Relationship to food intake
 - Relationship to defecation



Examination of the Abdomen

- Important related symptoms/signs in patients with abdominal pain:
 - Fever/rigors/sweats
 - Nausea/vomiting
 - Weight loss
 - Change in bowel habits
 - Evidence of GI blood loss (hematemesis, melena, hematochezia, occult loss)



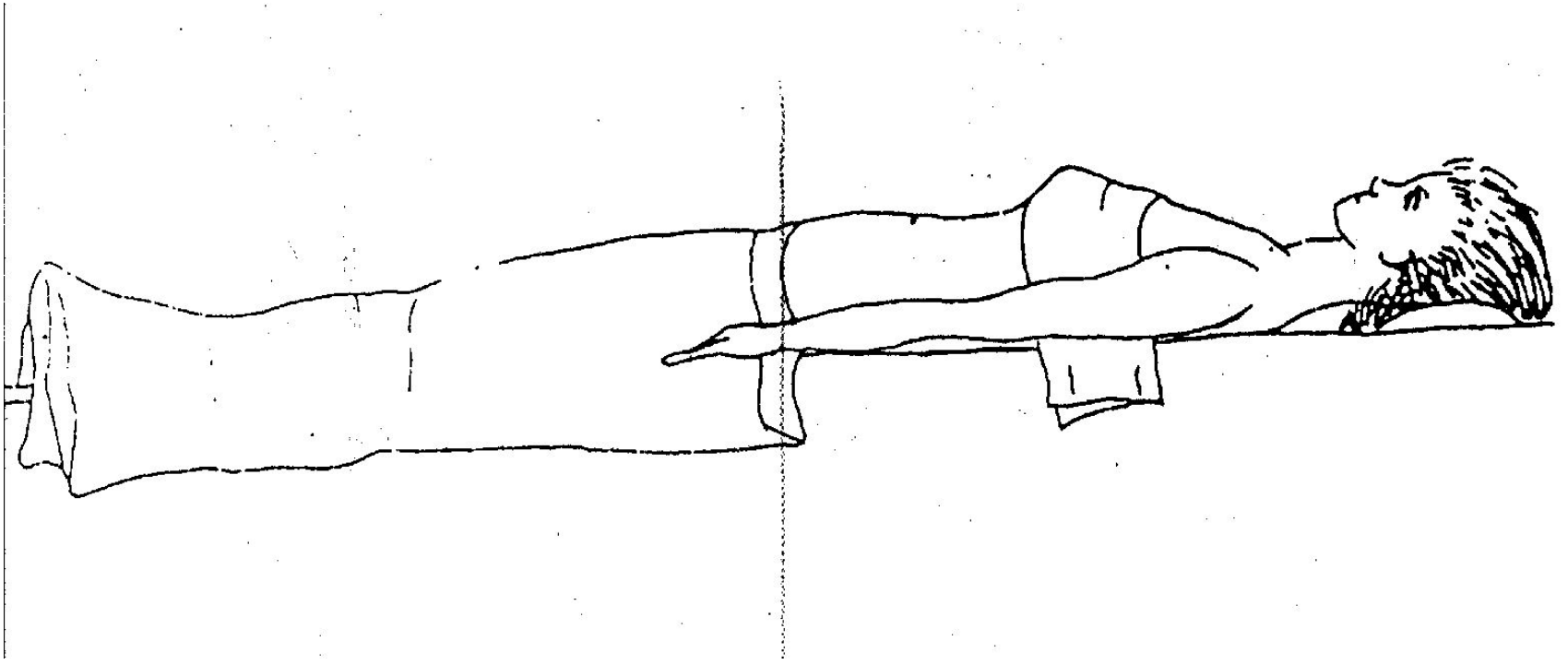

Examination of the Abdomen

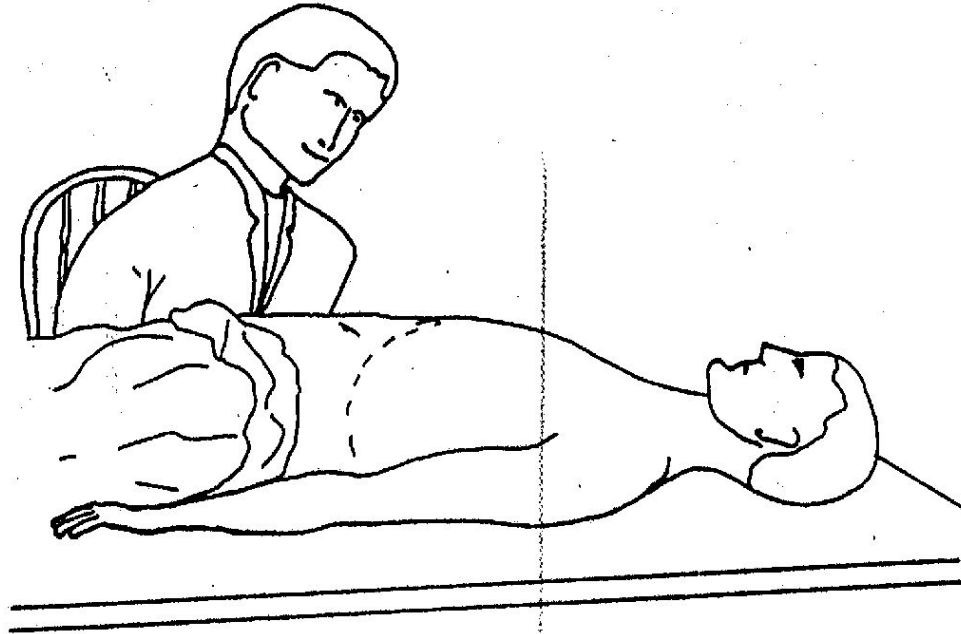

- Physical Examination:
 - The PE of the abdomen must be performed in an organized, systematic fashion in order to yield accurate and consistent results. Pt should be properly prepared. Pt should be lying supine, relaxed, draped, with hands at sides or crossed on chest. Quiet room/temp. Relaxed, confident examiner.



Examination of the Abdomen

- Physical Examination of the Abdomen is conducted in four parts
 - Inspection/observation
 - Auscultation
 - Percussion
 - Palpation

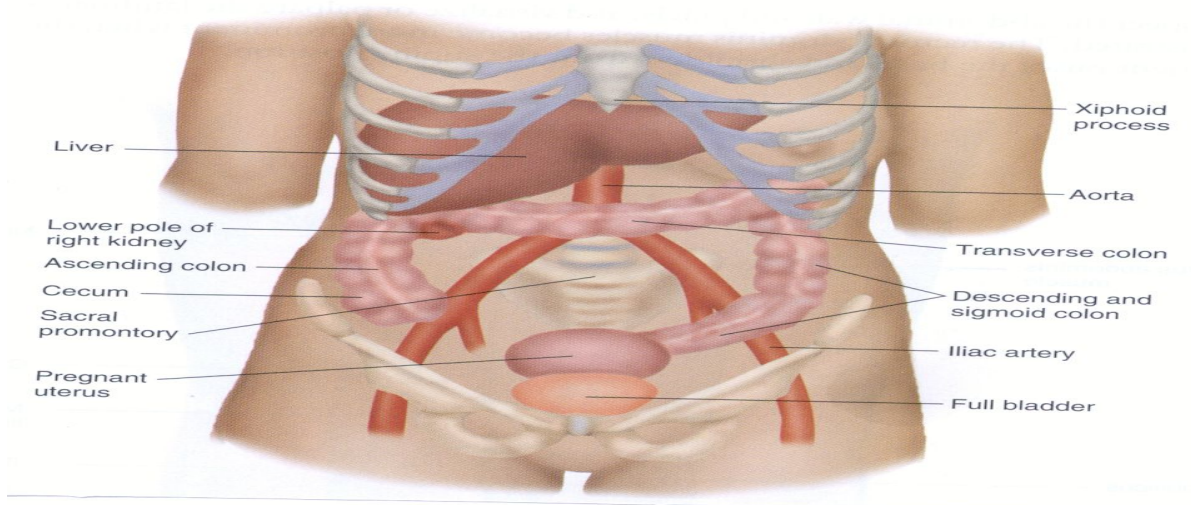
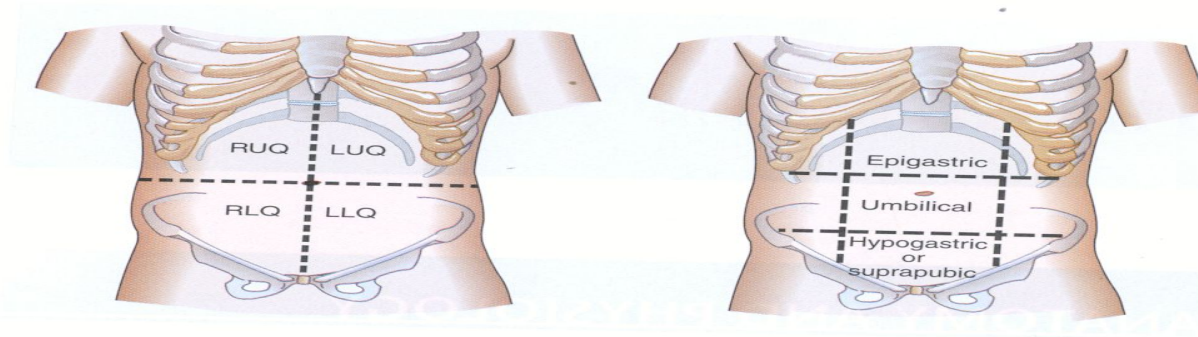



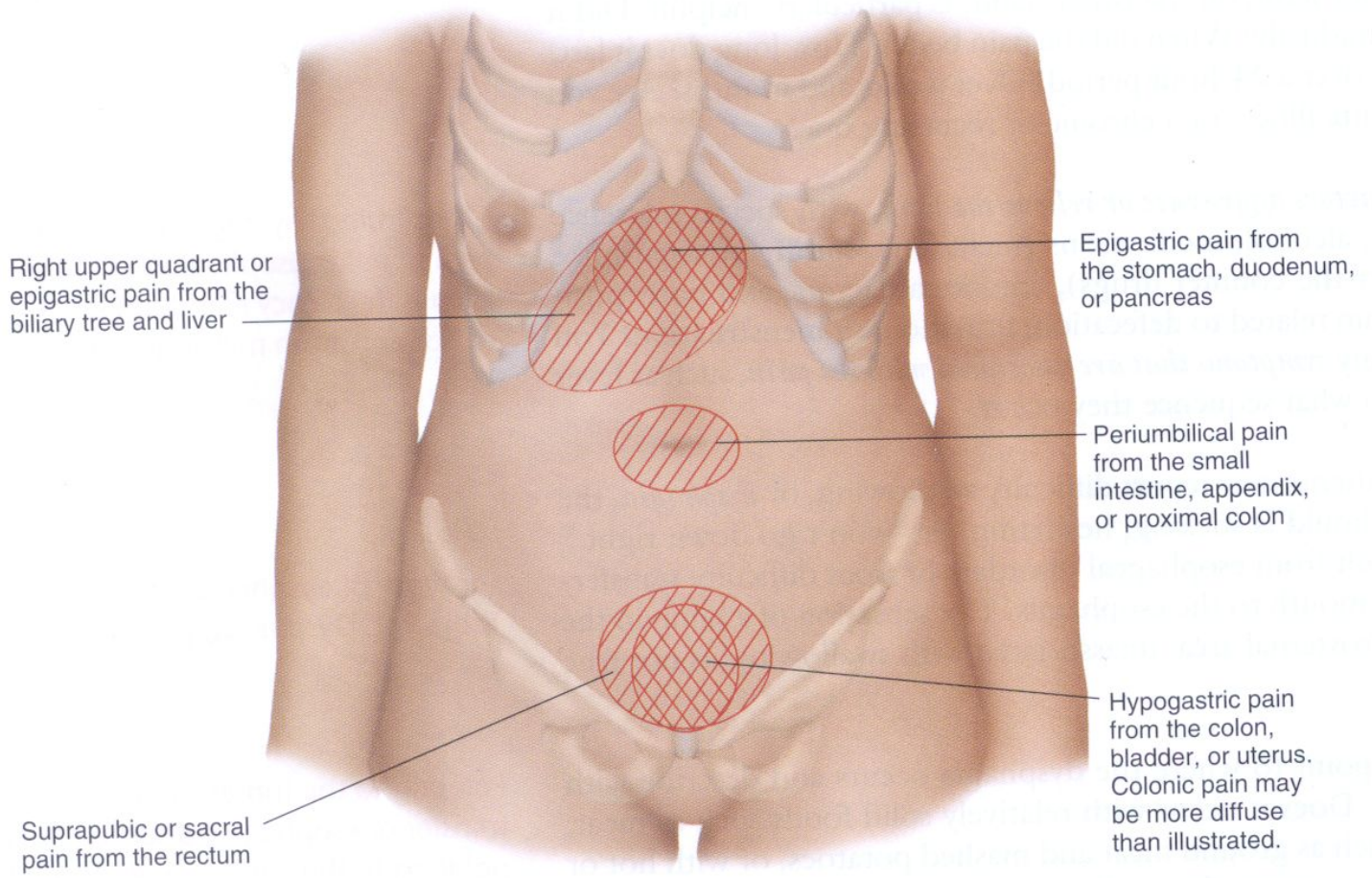





Examination of the Abdomen

- For descriptive purposes, the abdomen is divided into four quadrants
 - RUQ,LUQ,RLQ,LLQ
- Epigastric,umbilical, periumbilical, suprapubic are terms also used by clinicians to describe symptoms and findings in those specific regions

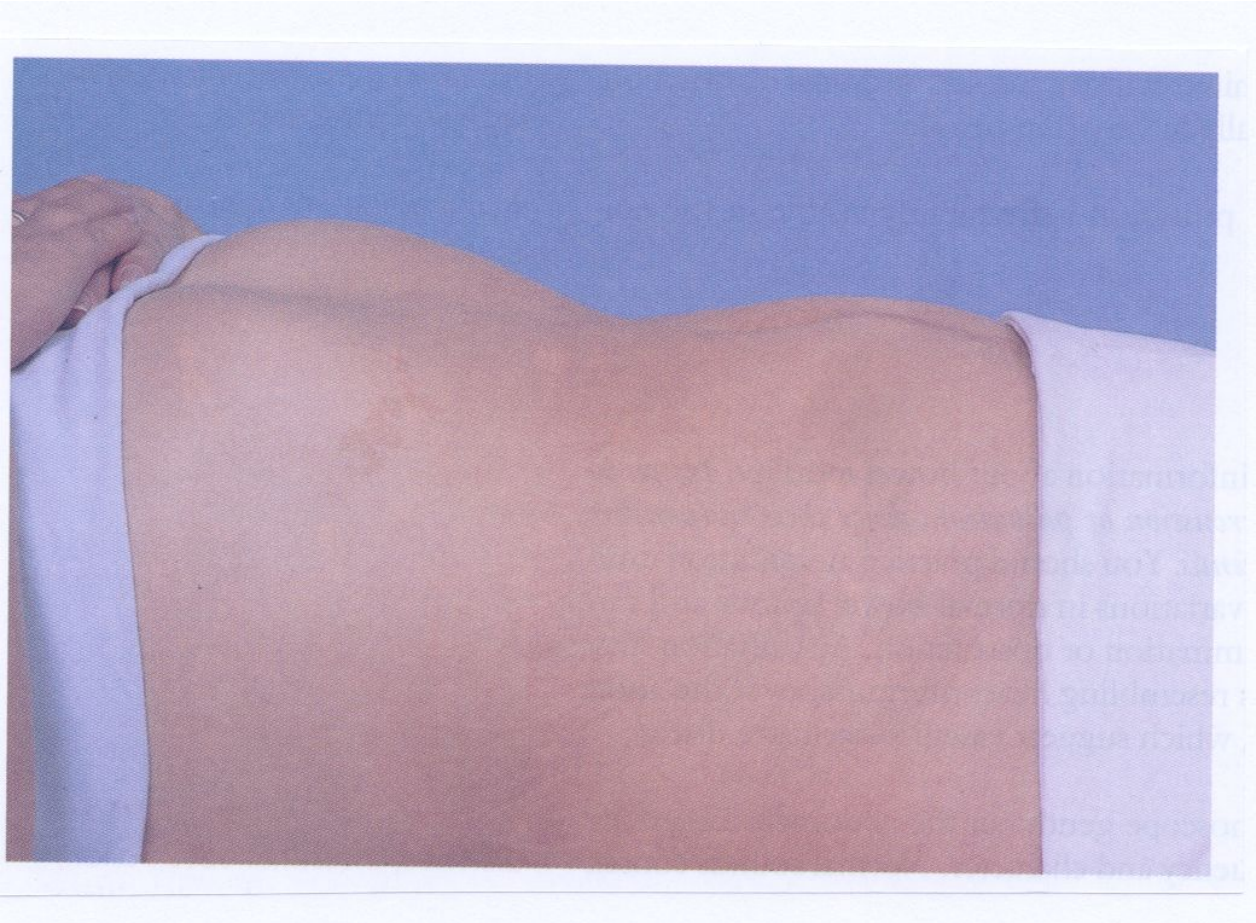







Examination of the Abdomen

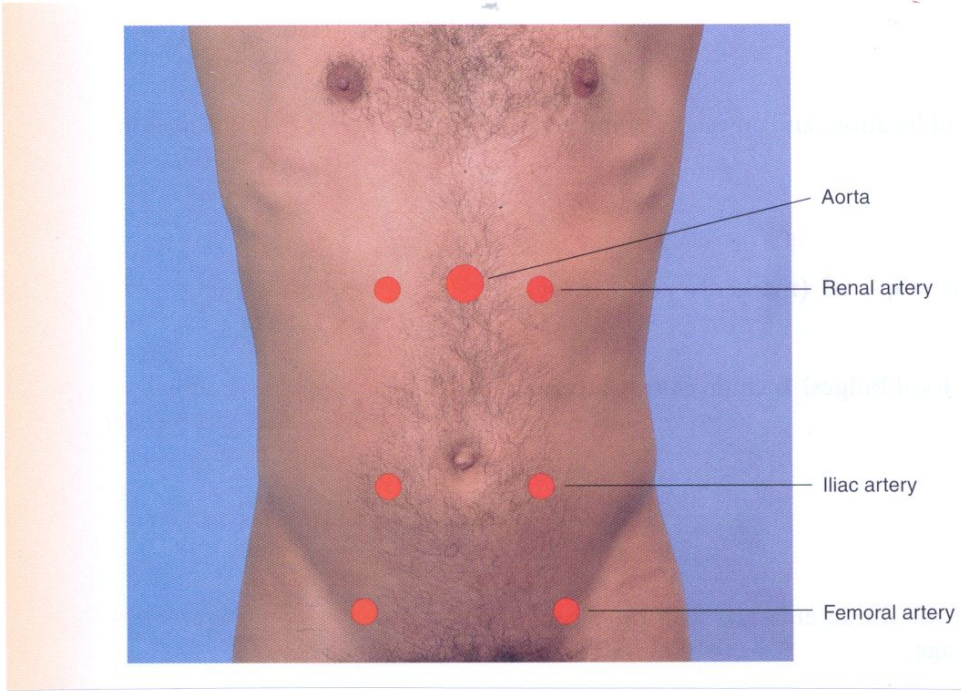

- Inspection/Observation (#40)
 - Inspect the contour of the abdomen. It may be flat, rounded, protuberant, or scaphoid
 - Are there any visible pulsations/masses?
 - Do the flanks bulge (ascites)?
 - Inspect skin (scars, striae, veins, rashes)
 - Inspect umbilicus





Examination of the Abdomen

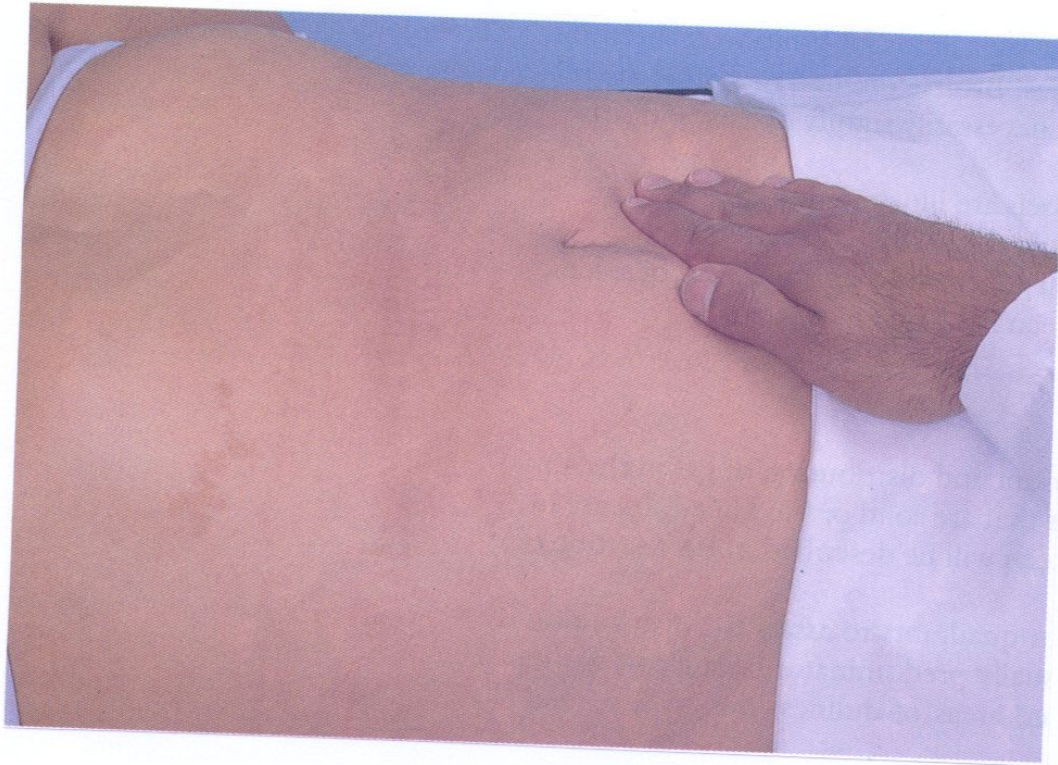
- Auscultation (#41)
 - Useful in assessing bowel motility and vascular bruits
 - Note frequency/character of the bowel sounds (borborygmi) with stethoscope. Listen in one spot. Listen for bruits.
 - No particular bowel sound is diagnostic but rushes and high pitched tinkles suggest obstructed gut.

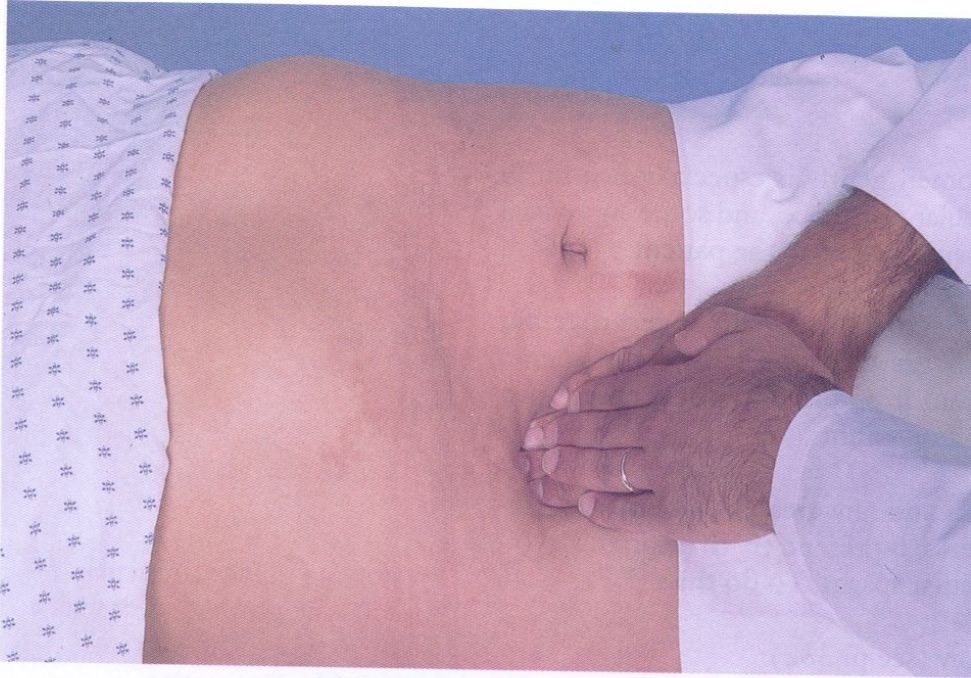




Examination of the Abdomen

- Palpation (#43-#50)
 - Palpate lightly then deeply in all four quadrants
 - Differentiate between voluntary and involuntary guarding
 - If a mass is detected note its location, size, shape, consistency, tenderness, pulsation, and mobility



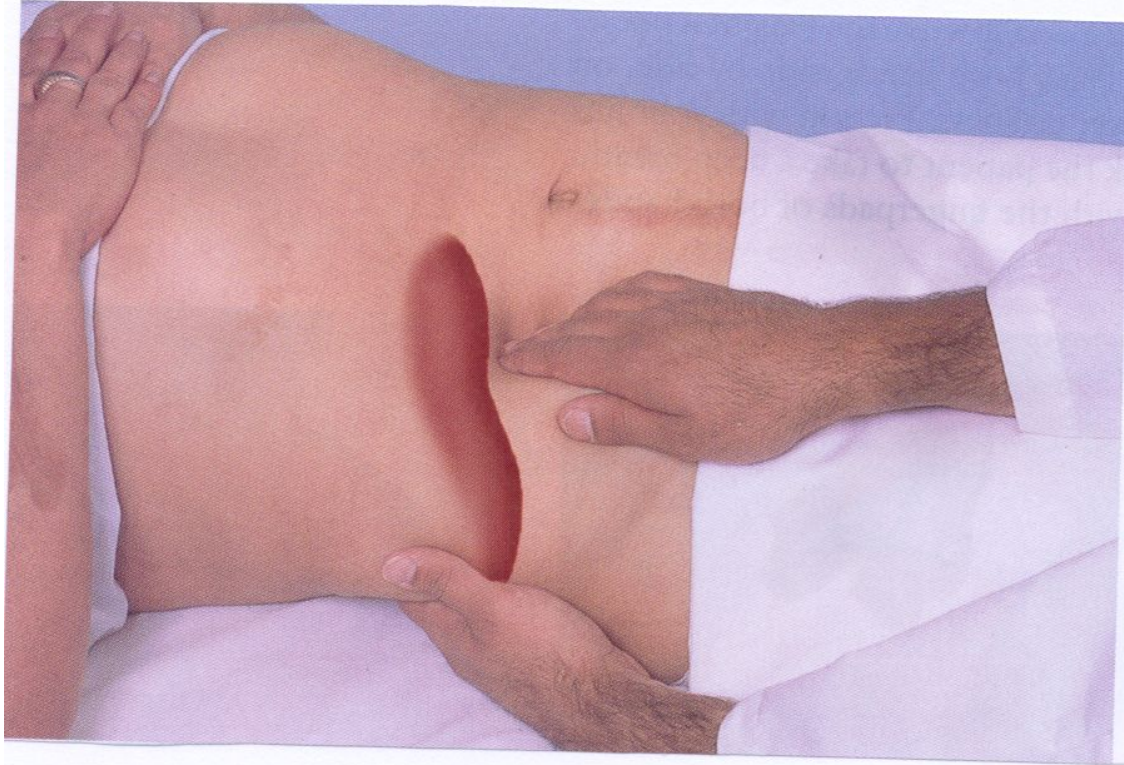



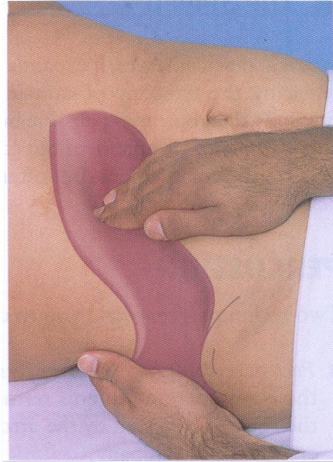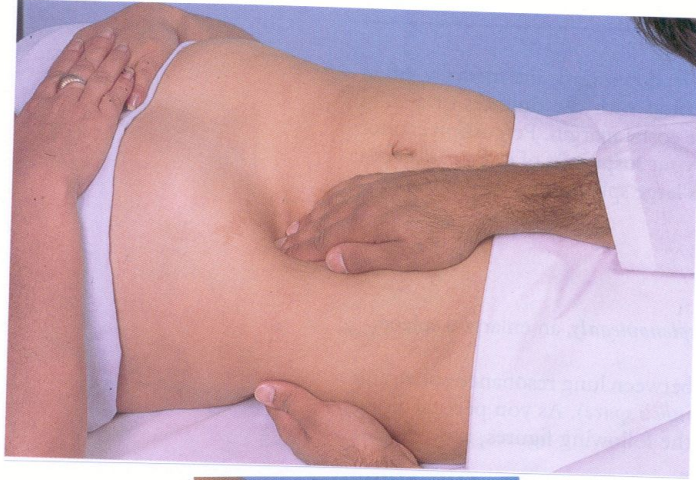

TWO-HANDED DEEP PALPATION

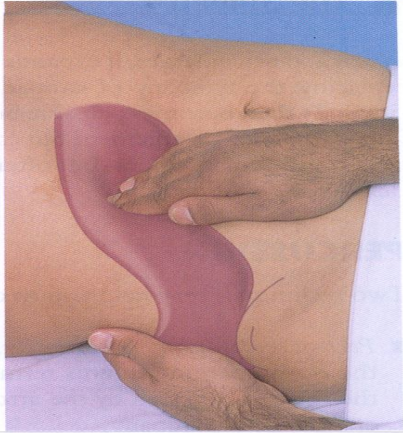
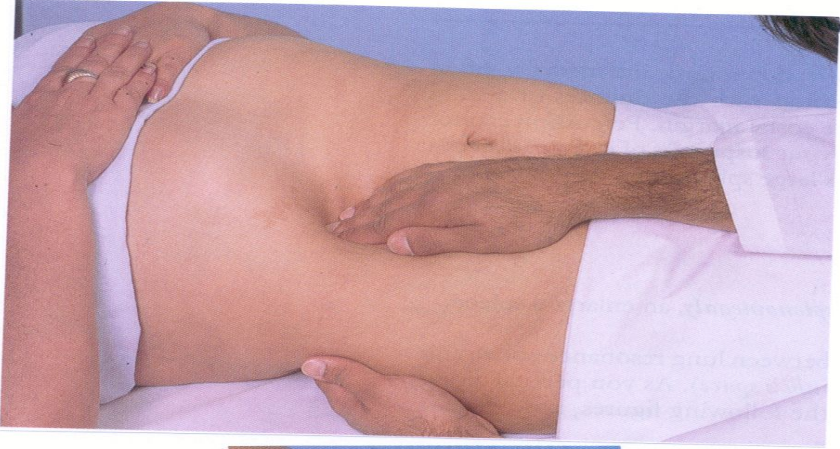


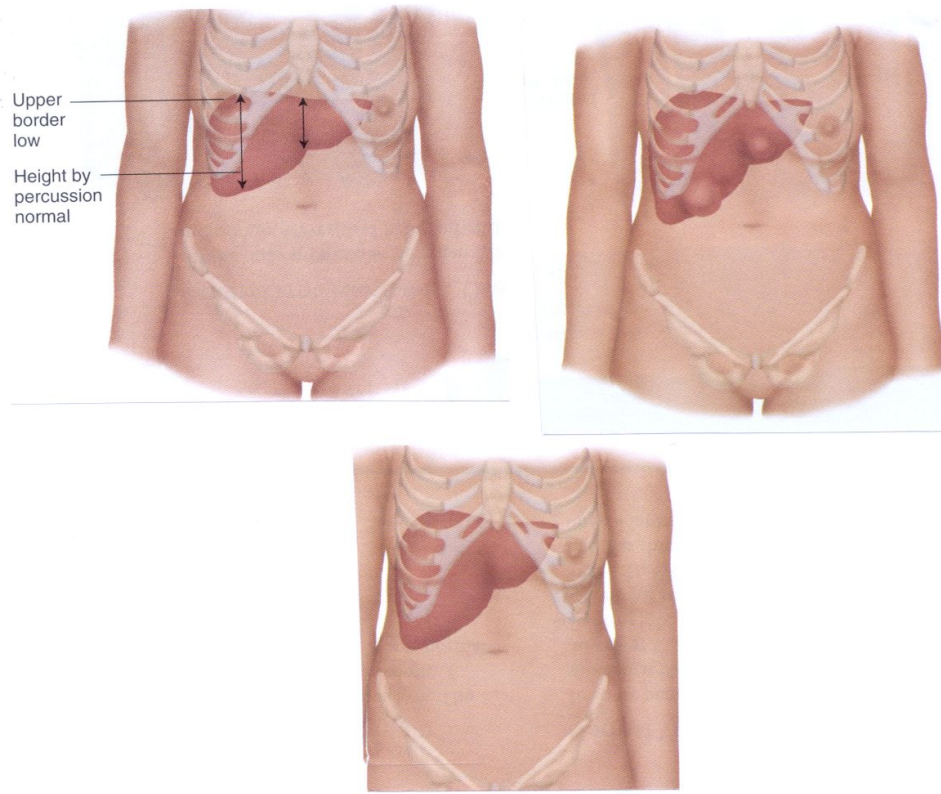

Examination of the Abdomen

- Palpation (#43-#50) cont'd
 - Assess peritoneal irritation and rebound tenderness
 - Palpate liver, spleen, inguinal and femoral lymph nodes





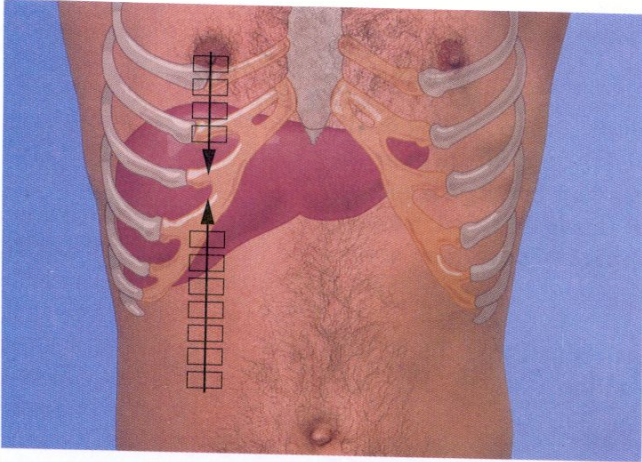





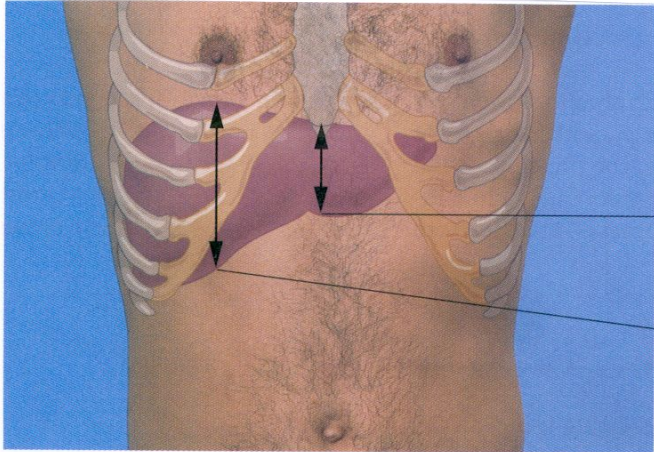


Examination of the Abdomen

- Percussion (#48)
 - Percuss the liver in mid-clavicular line. Assess size by percussing upper and lower borders. In COPD, normal sized livers are frequently palpated and lower border may be displaced downward.
 - In lean pts, spleen may be percussed



PERCUSSING LIVER SPAN



4 – 8 cm in
midsternal line



6 – 12 cm
in right
midclavicular
line

NORMAL LIVER SPANS

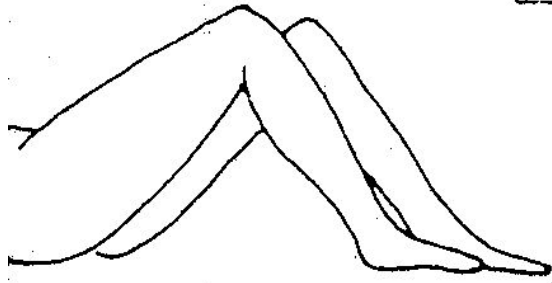


Examination of the Abdomen

- Rectal examination and stool specimen for FOBT
 - Last step of the physical examination. Stool sample retained for FOBT



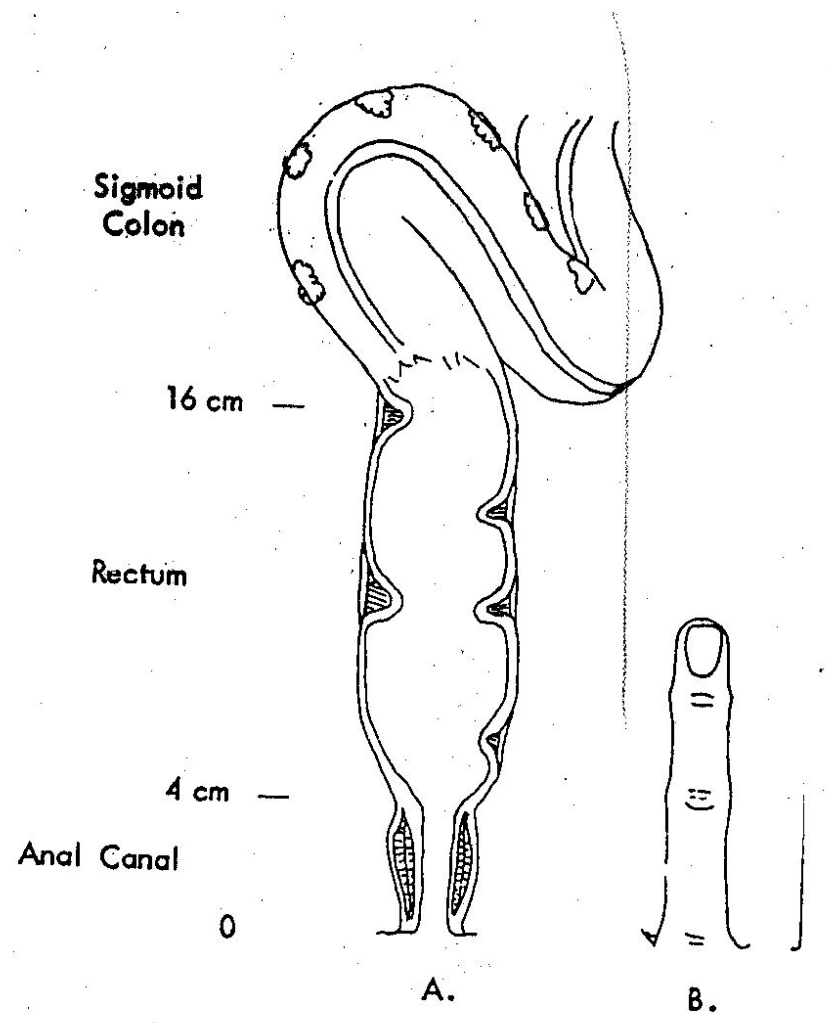

B.

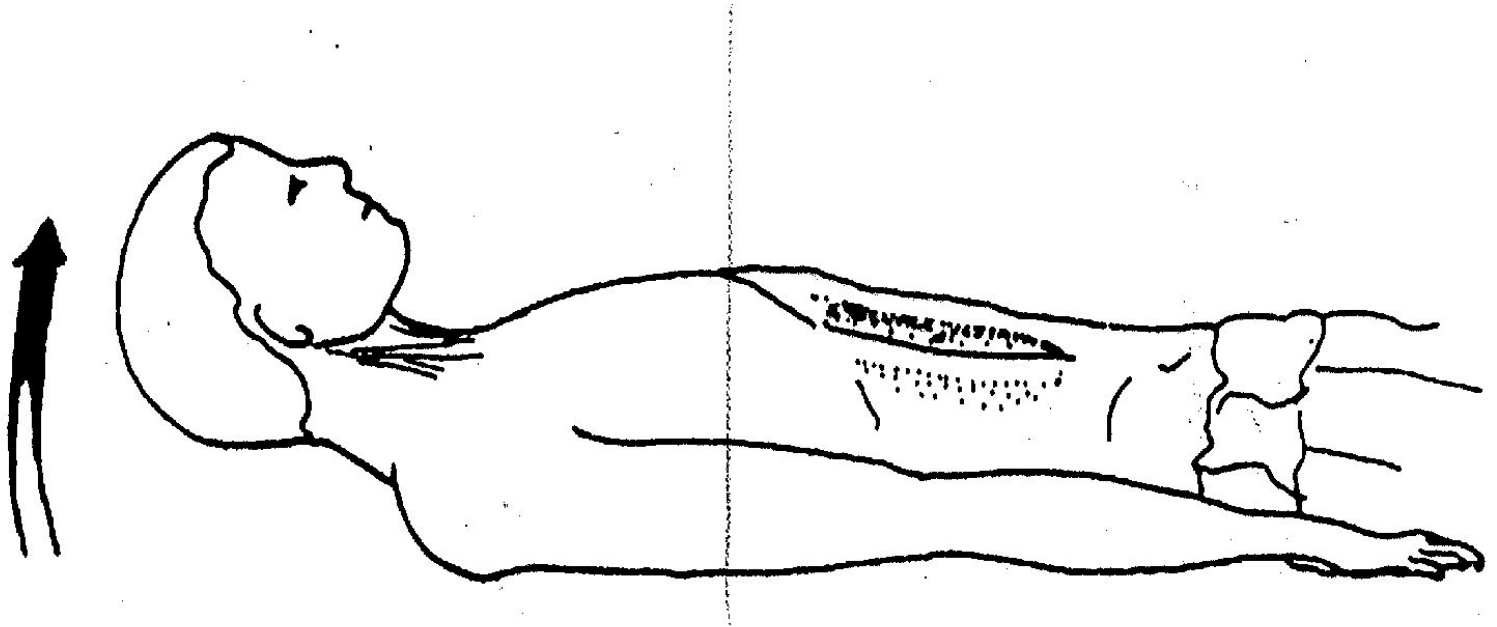



A.



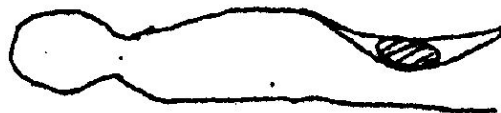
C.



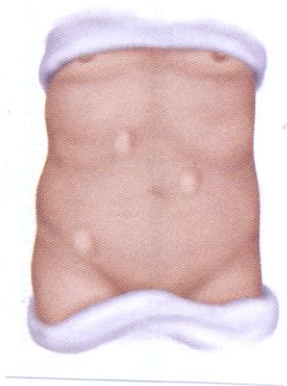
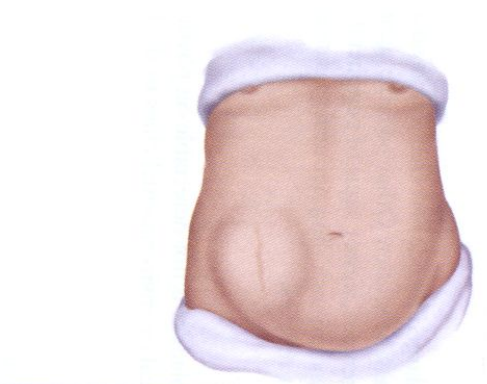
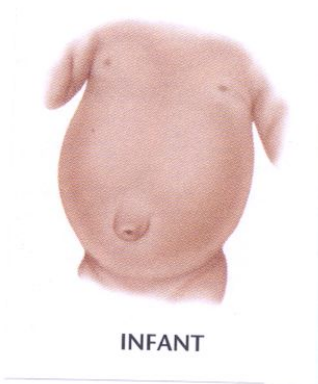



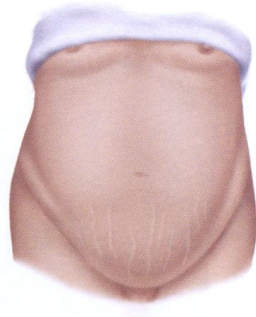



A.

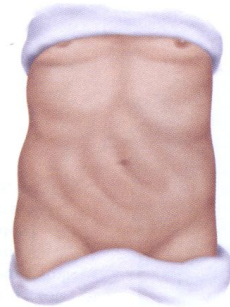


B.

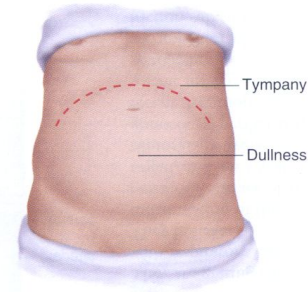




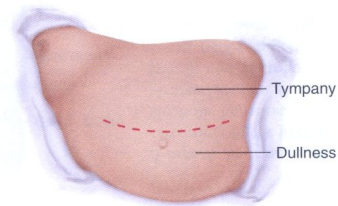
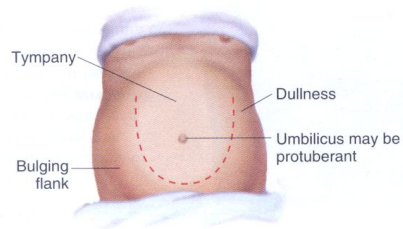
Fat

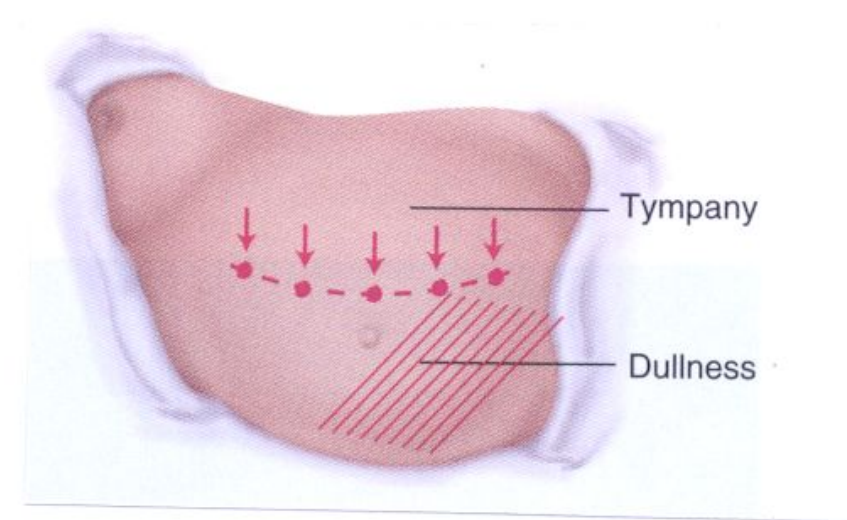
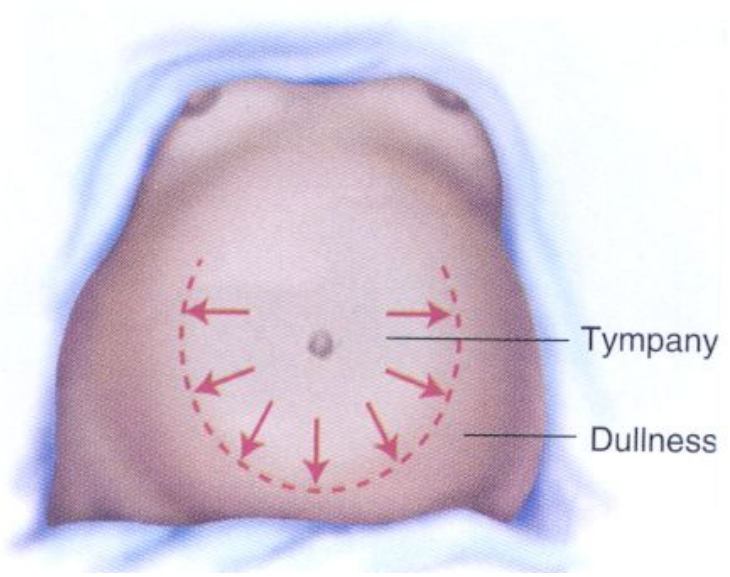



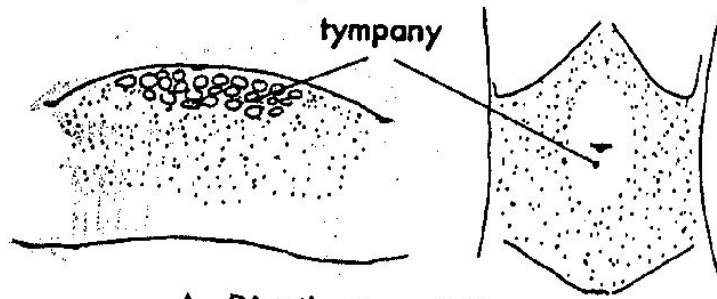
Gas



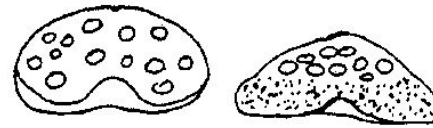
Tumor



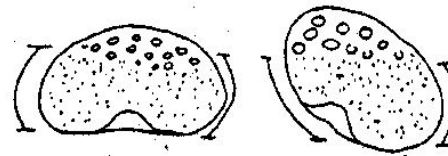




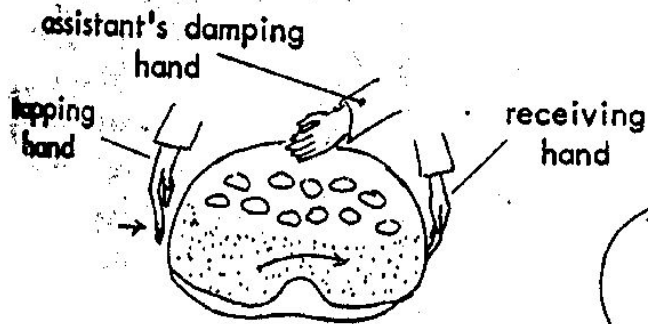
A. Distribution of Tympany



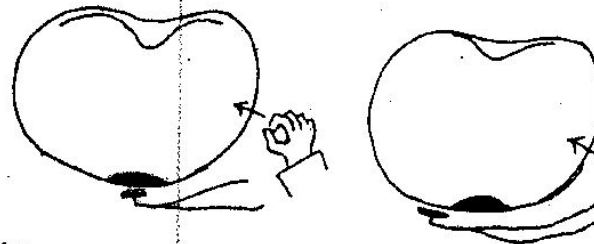
B. Bulging of Flanks



C. Shifting Dullness



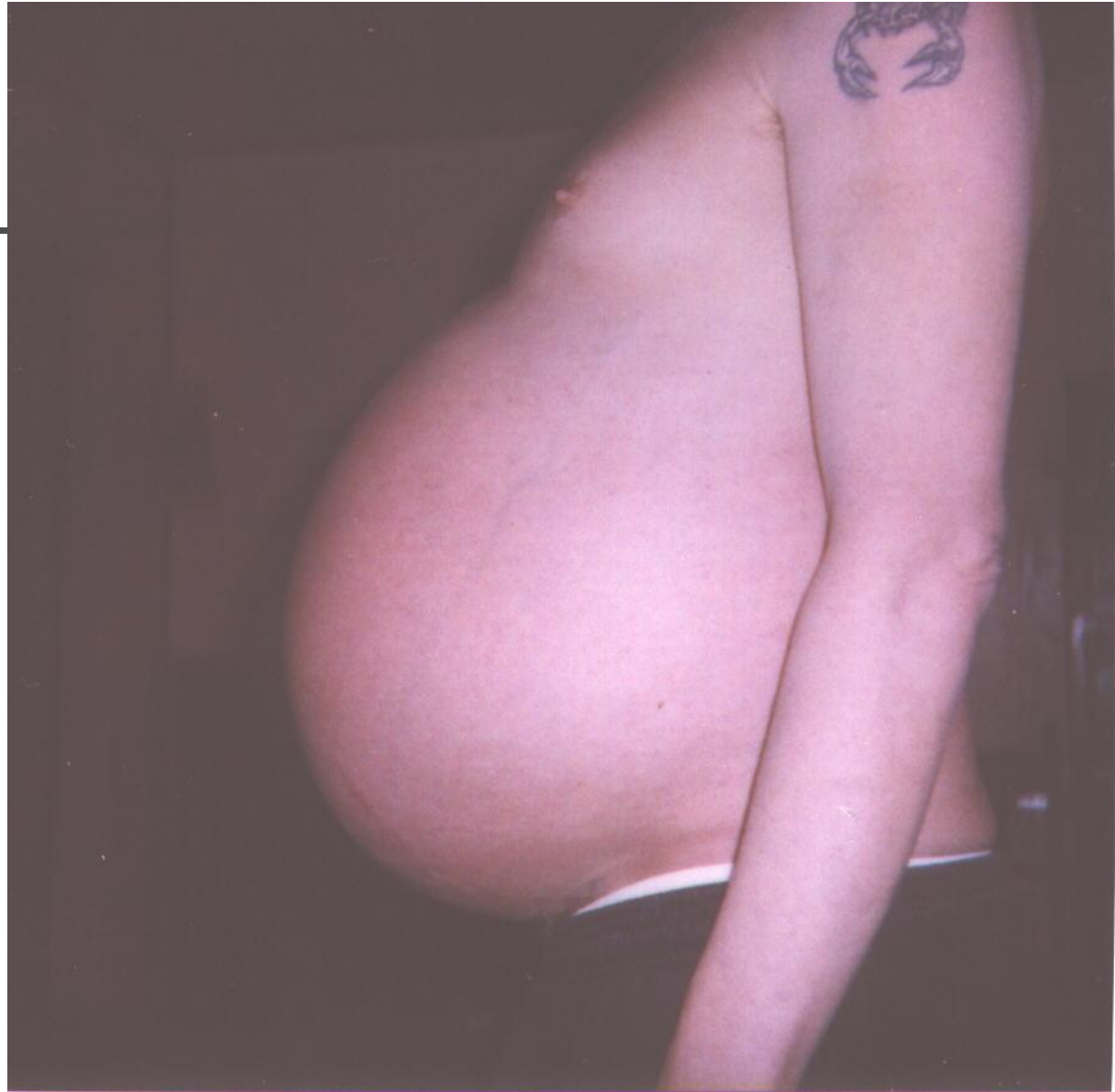
D. Fluid Wave

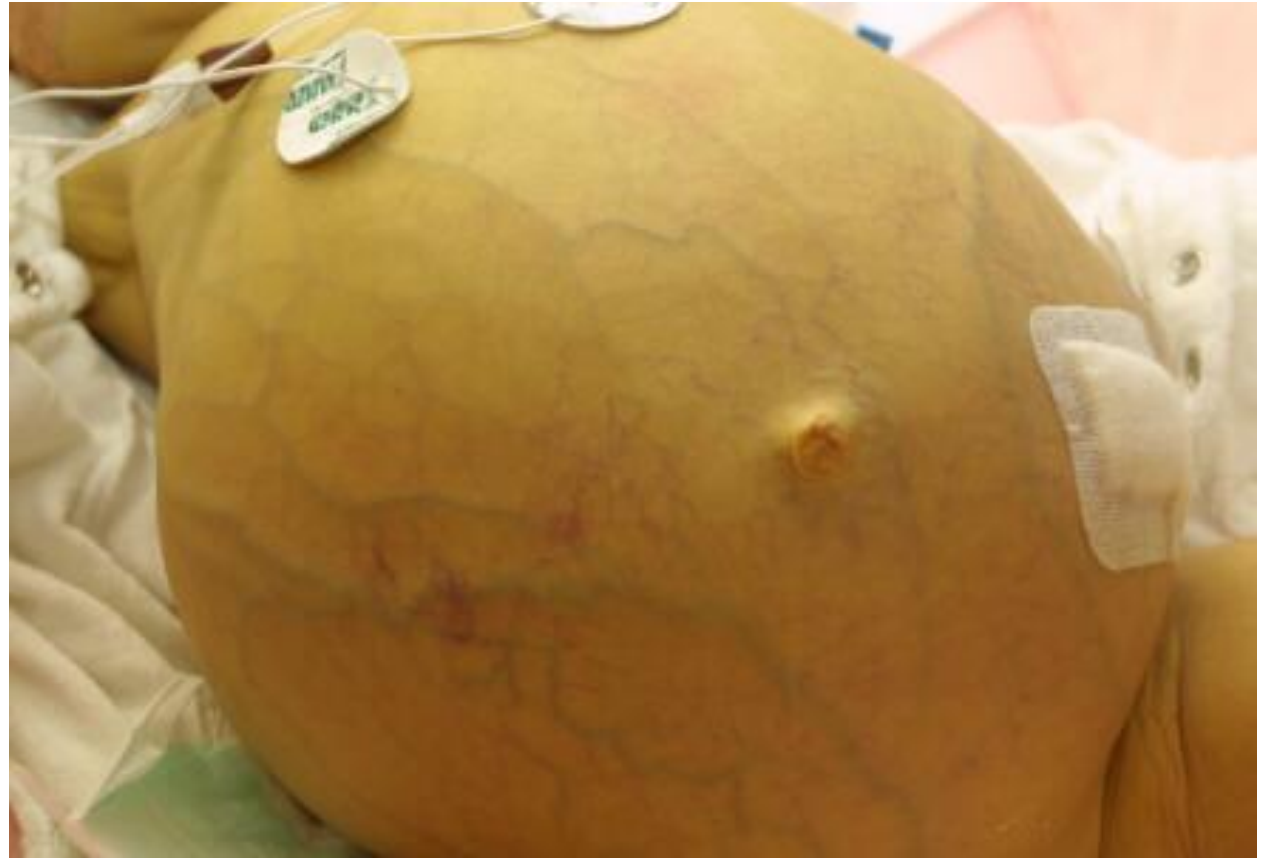


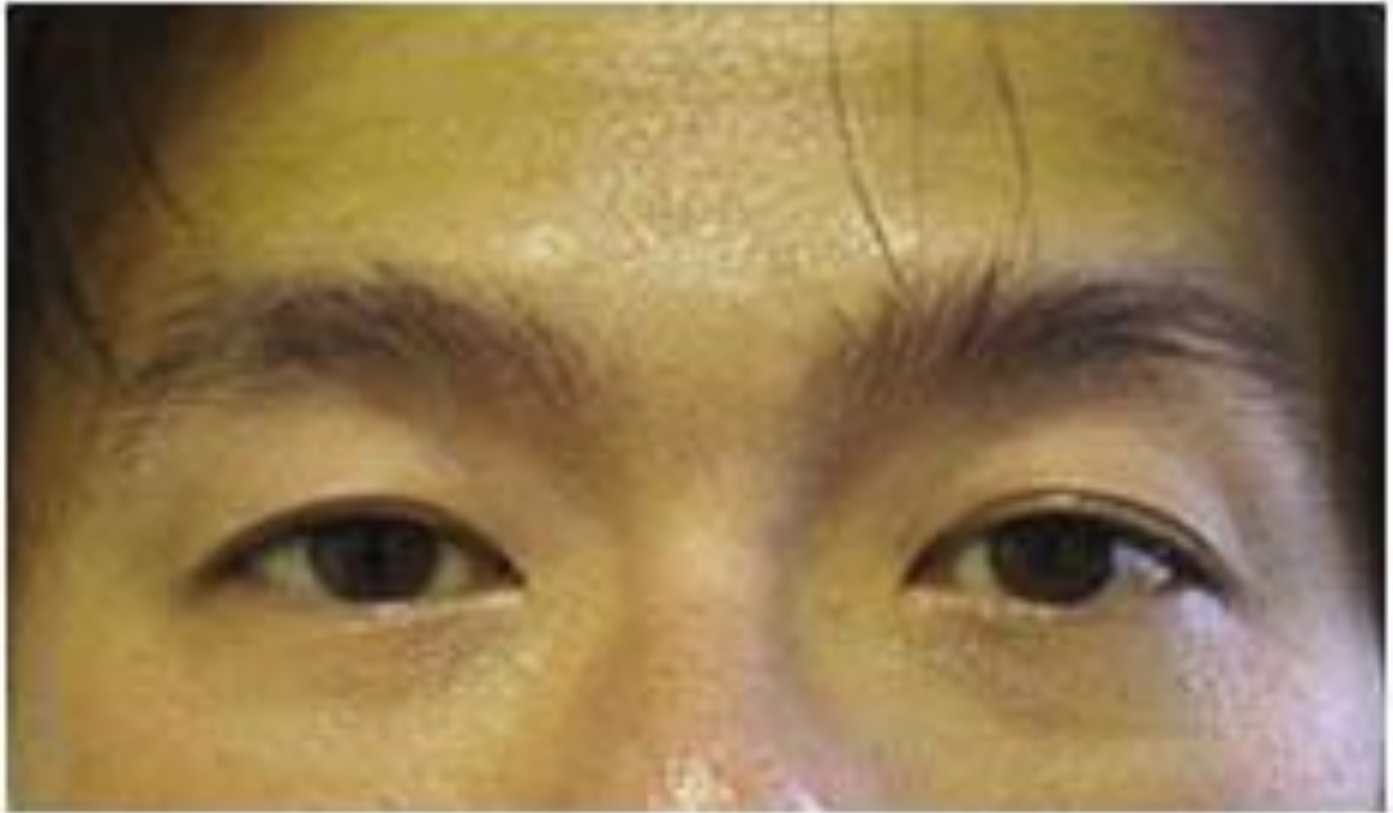
flicking sound damped by fluid

flicking sound transmitted better through gas in bow

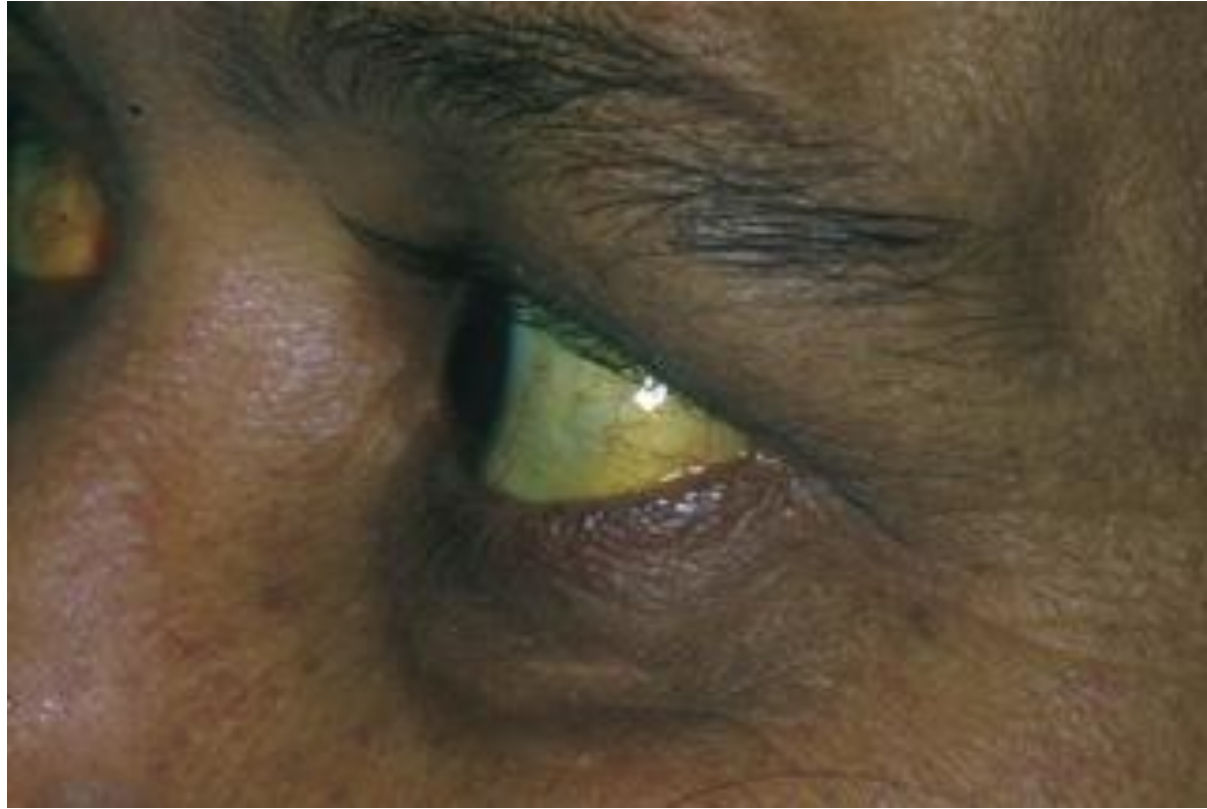
E. Puddle Sign

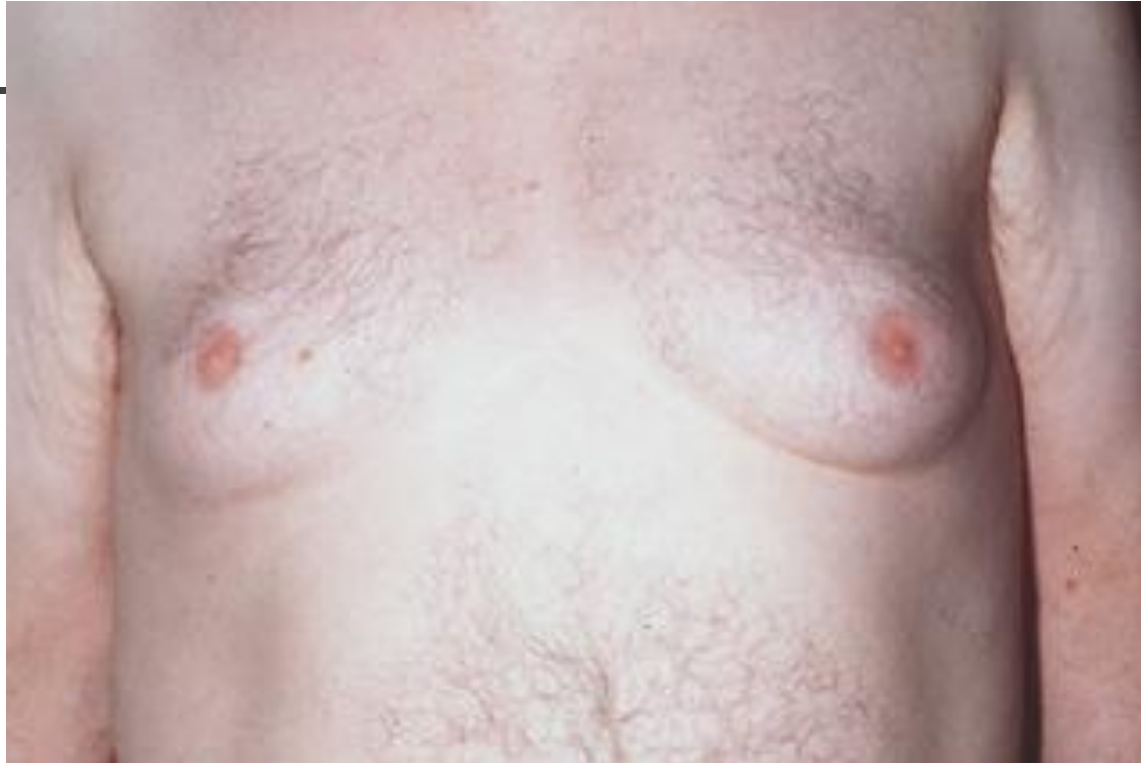




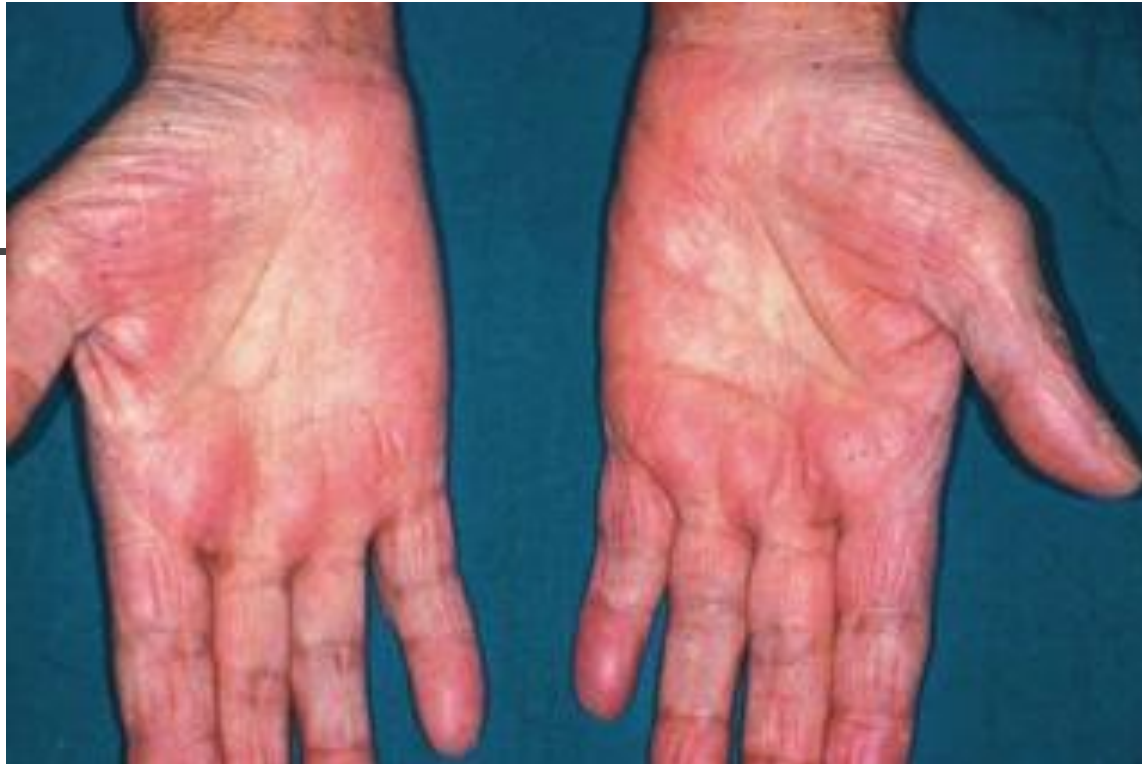
Jaundice and Scleral Icterus

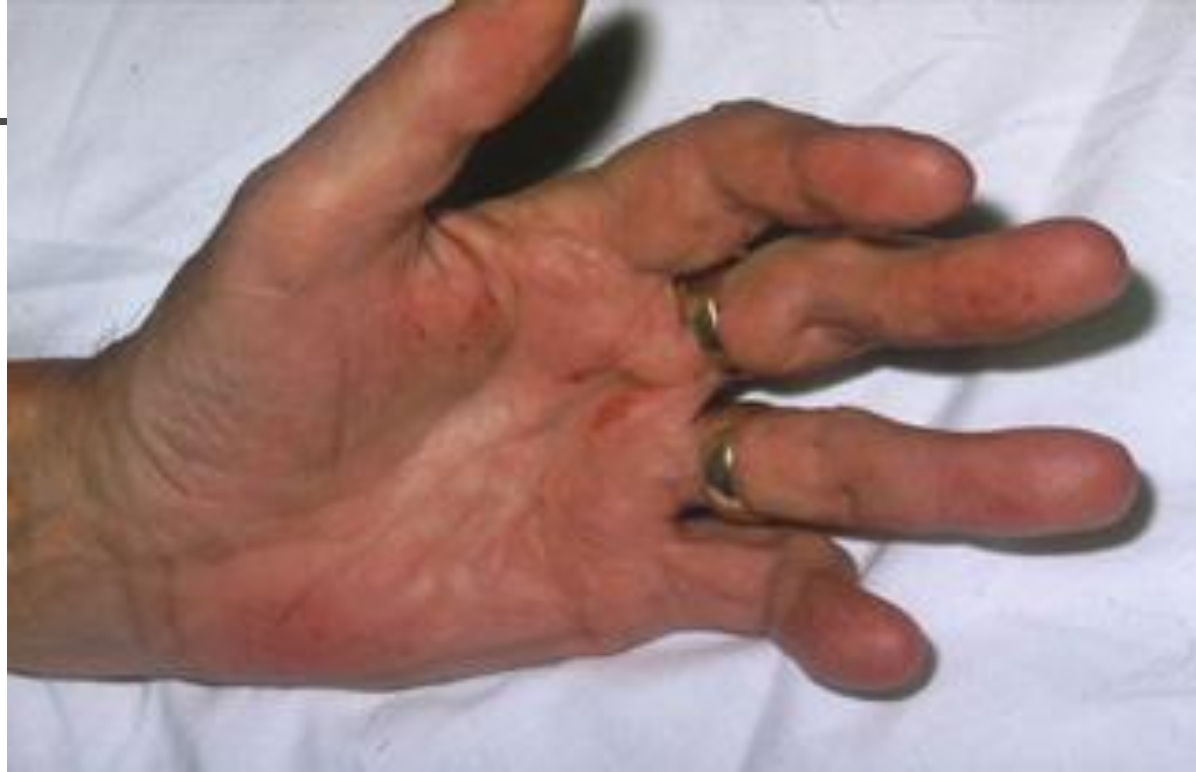



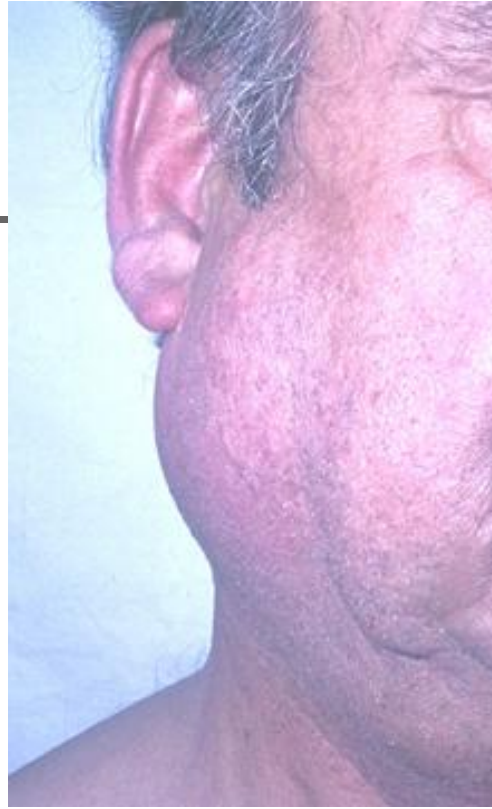Gynaecomastia or enlargement of breast tissue in men may occur either bilaterally or unilaterally.



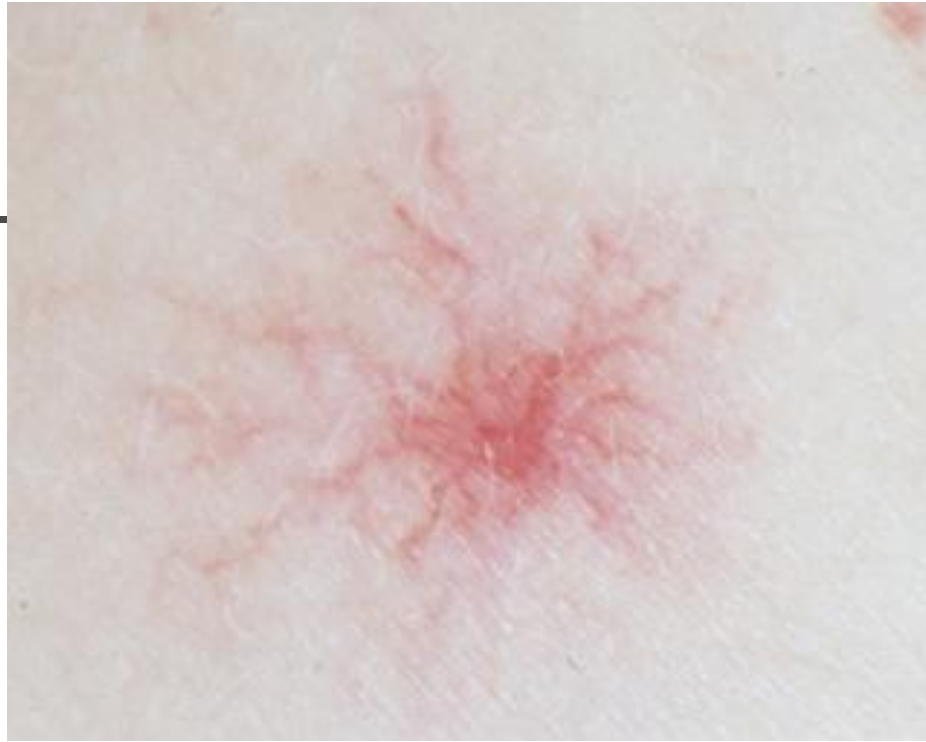Palmar Erythema is characterized by a prominent rim of colour beginning on the hypothenar border of the hand but also in some individuals involving the thenar eminence and even the fingertips. Similar changes may be observed on the soles of the feet.



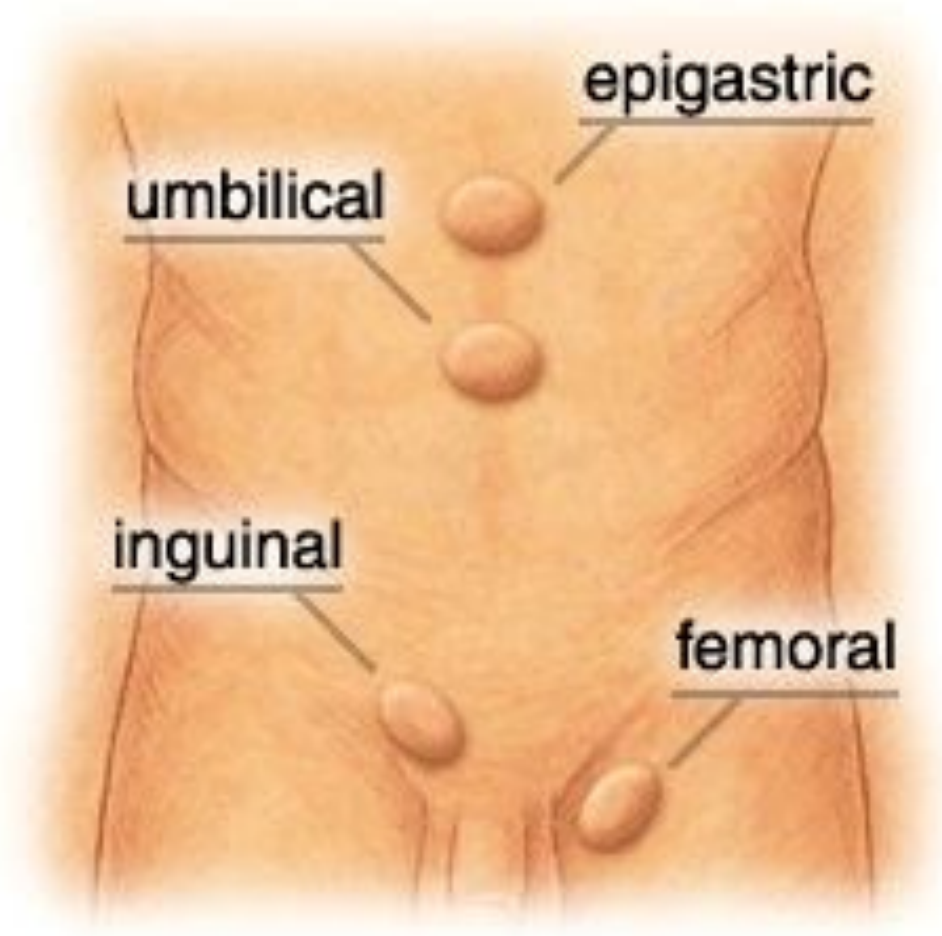
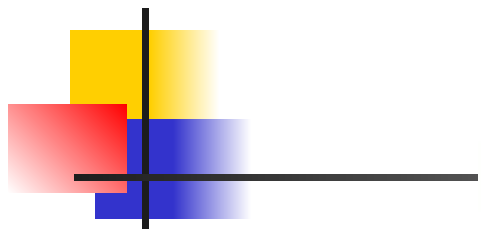
Dupuytren's Contractures arise as a result of fibrous change in the palmar fascia which inserts into the flexor tendons, most commonly affecting the ring fingers

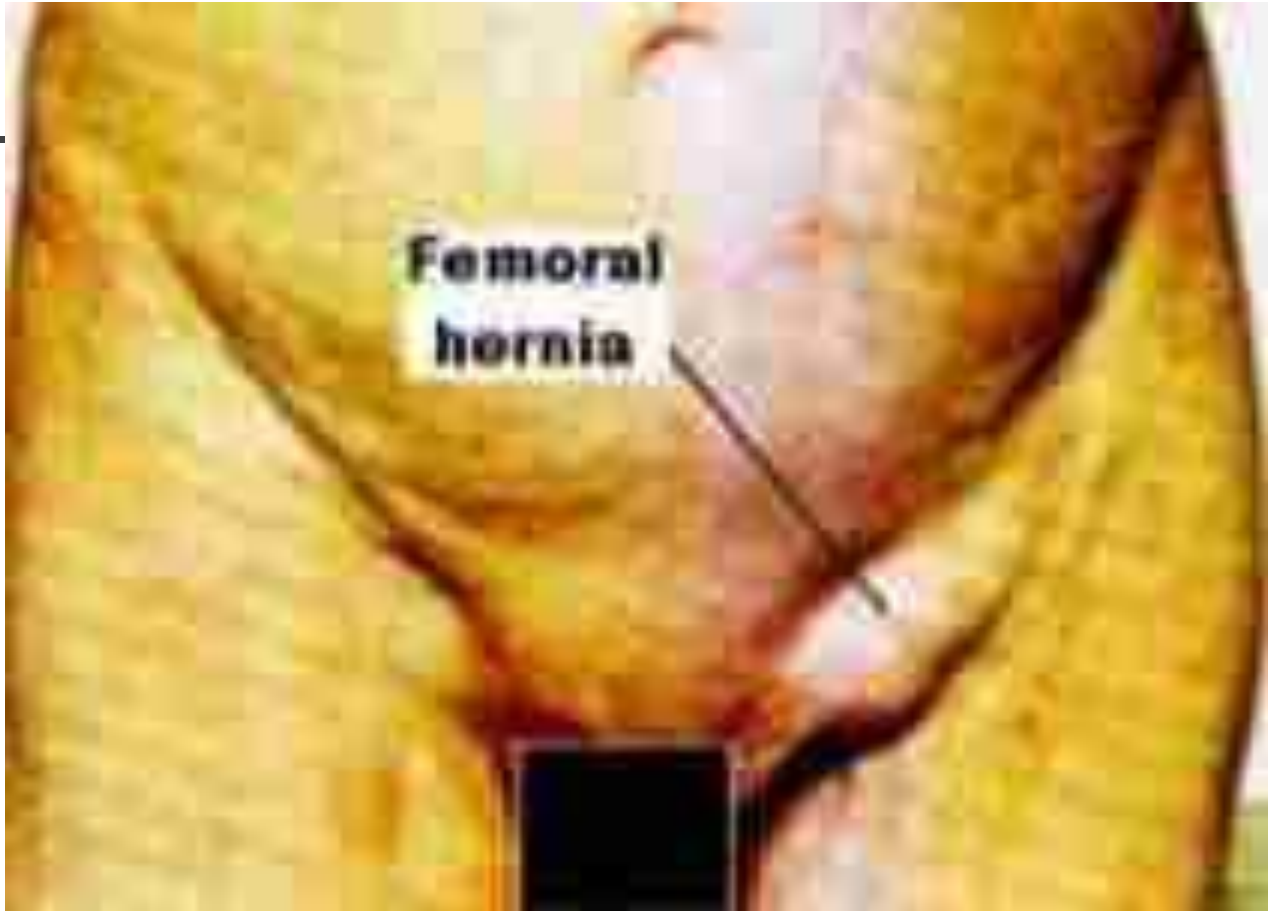

Parotid Hypertrophy contributes to the rounded appearance of the face; the submandibular glands may also be enlarged.



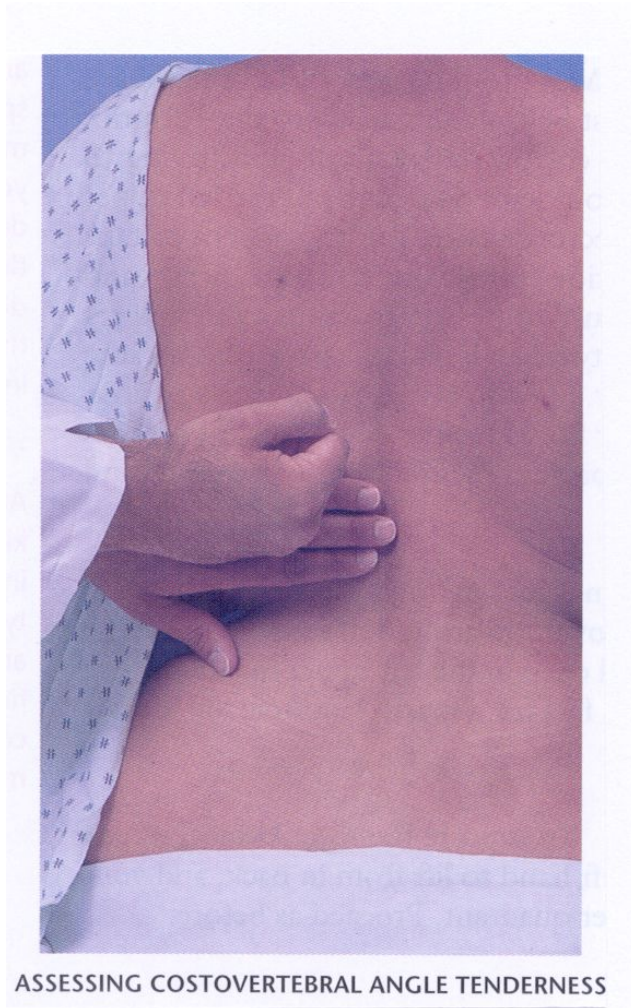
Spider Naevi are found only in the distribution of the superior vena cava, most commonly on the face and the anterior chest wall. They comprise an enlarged central arteriole from which vessels radiate in a spoke-like manner.



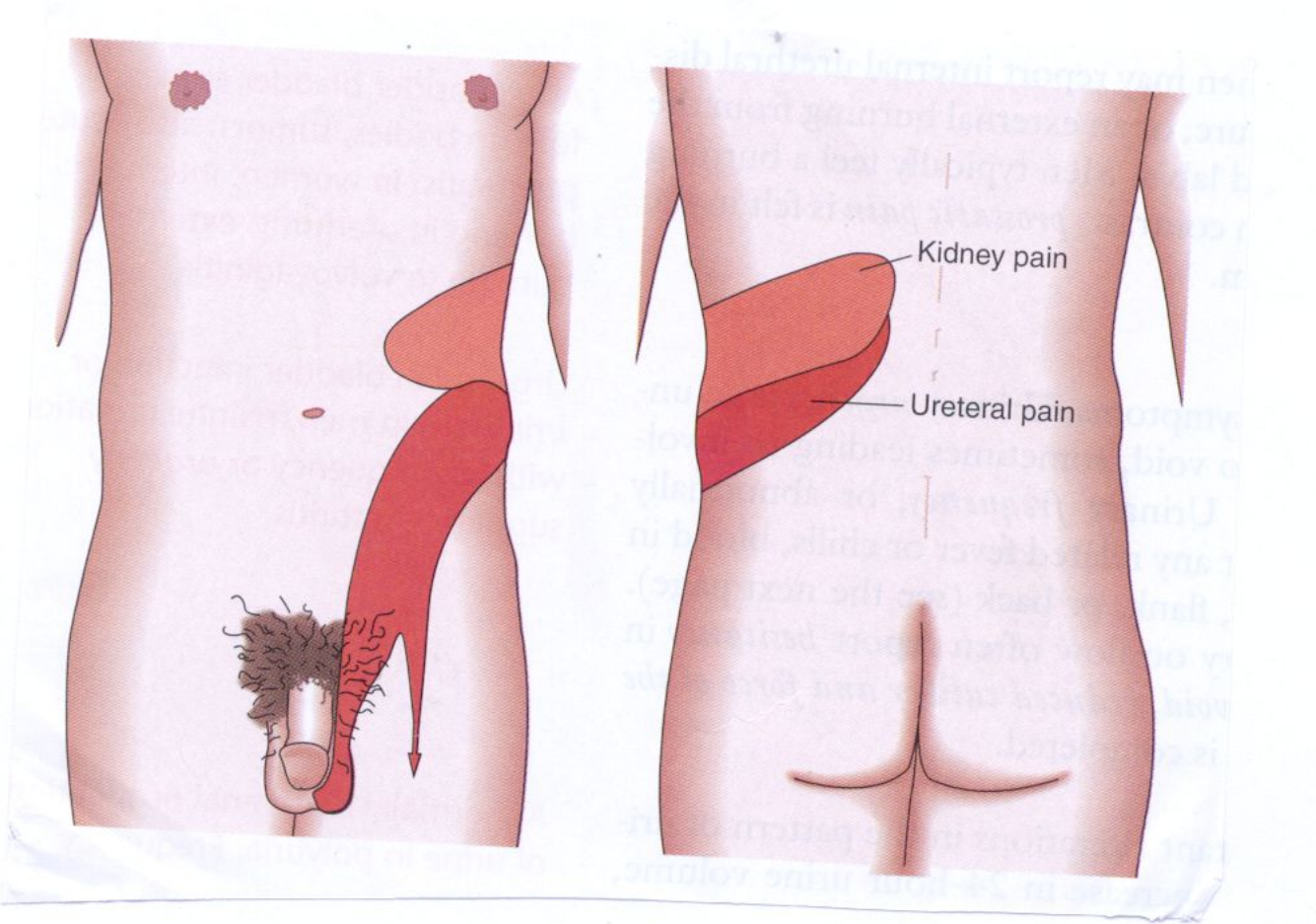



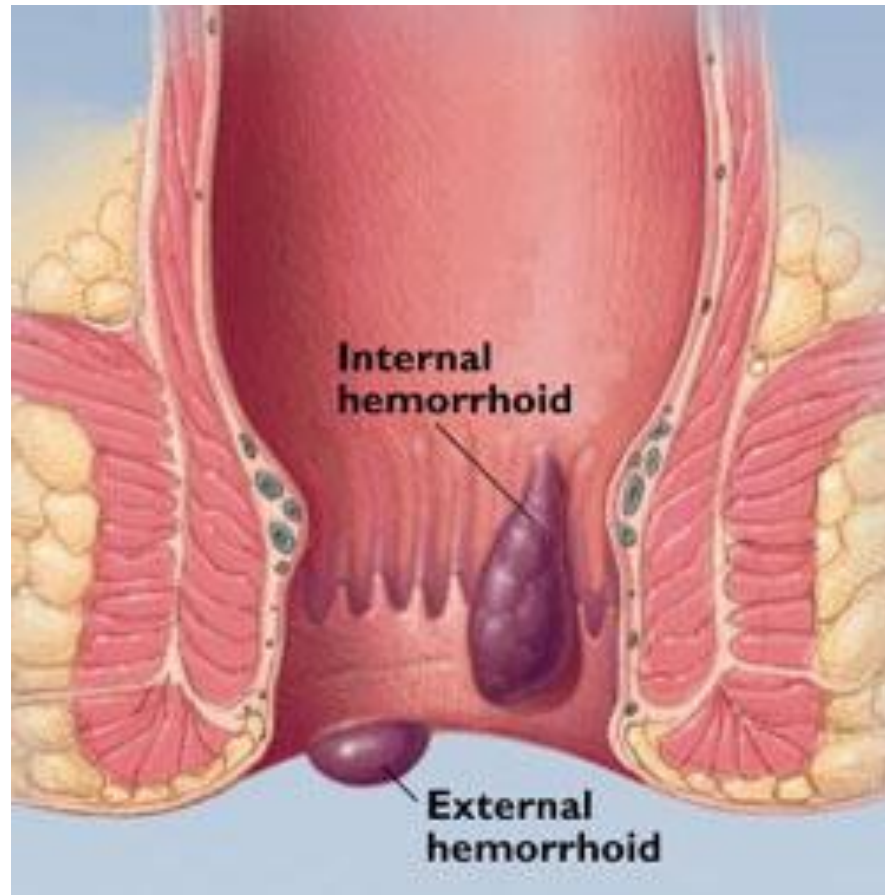

**Femoral
hernia**

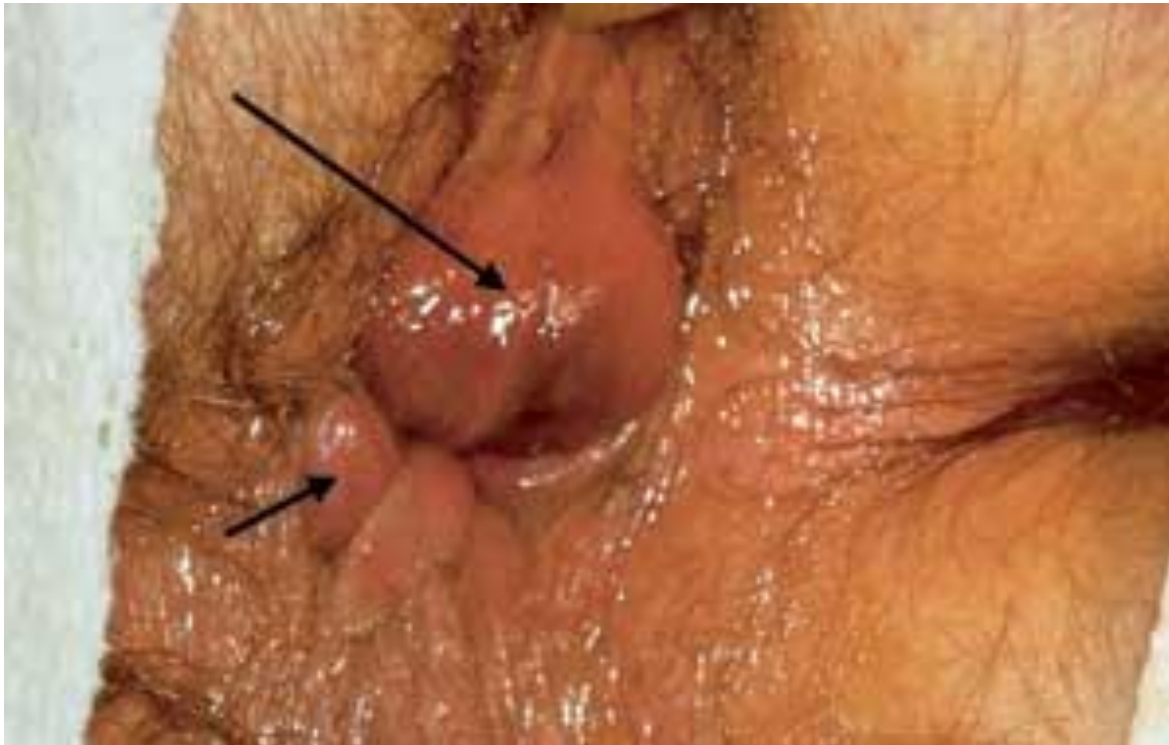



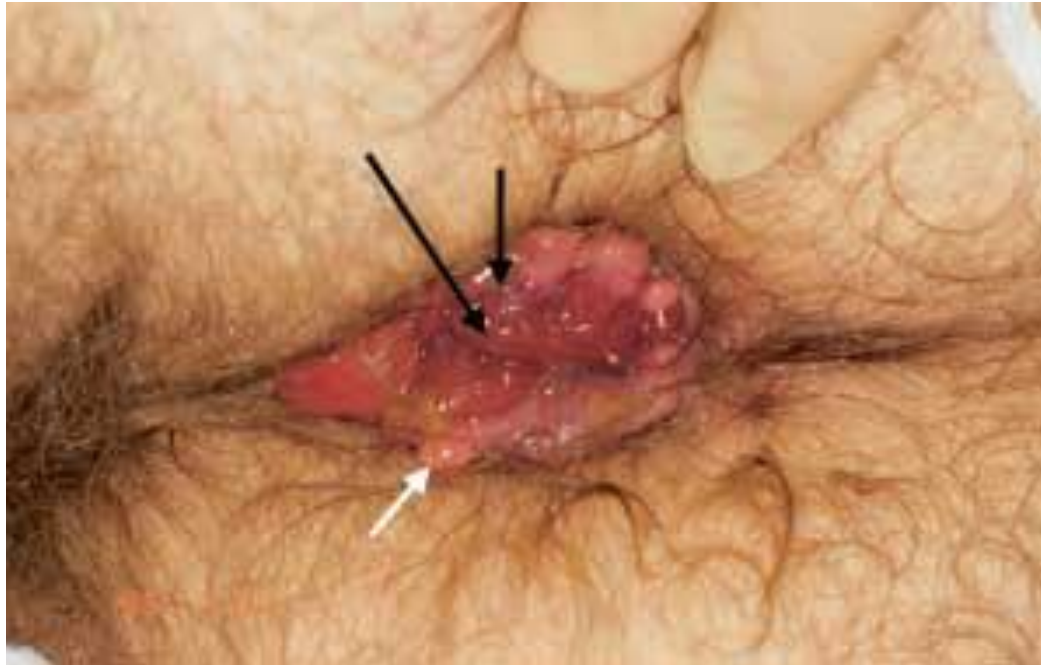ASSESSING COSTOVERTEBRAL ANGLE TENDERNESS



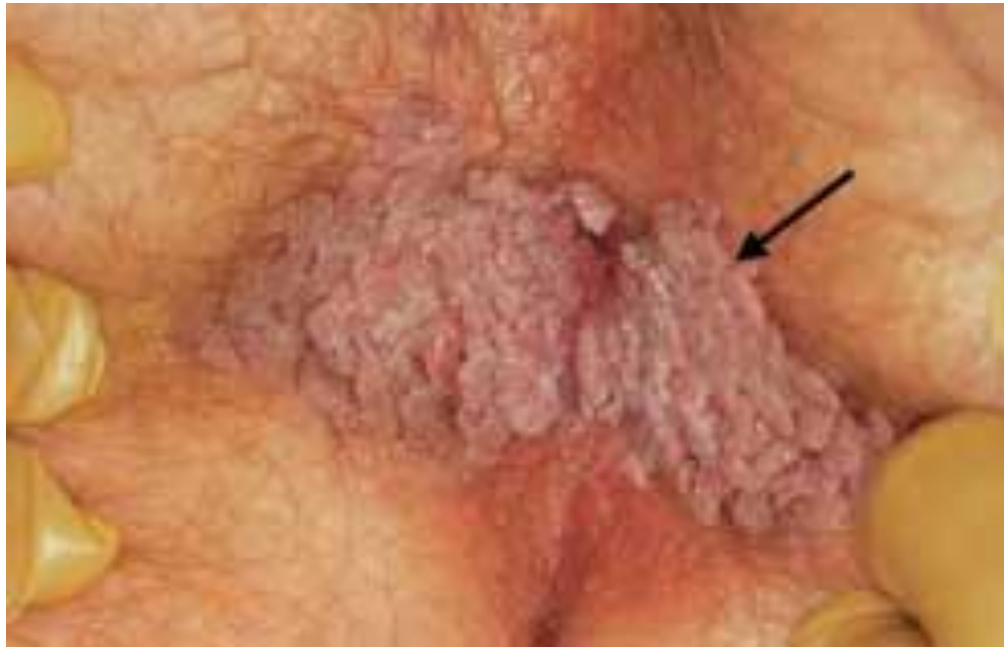



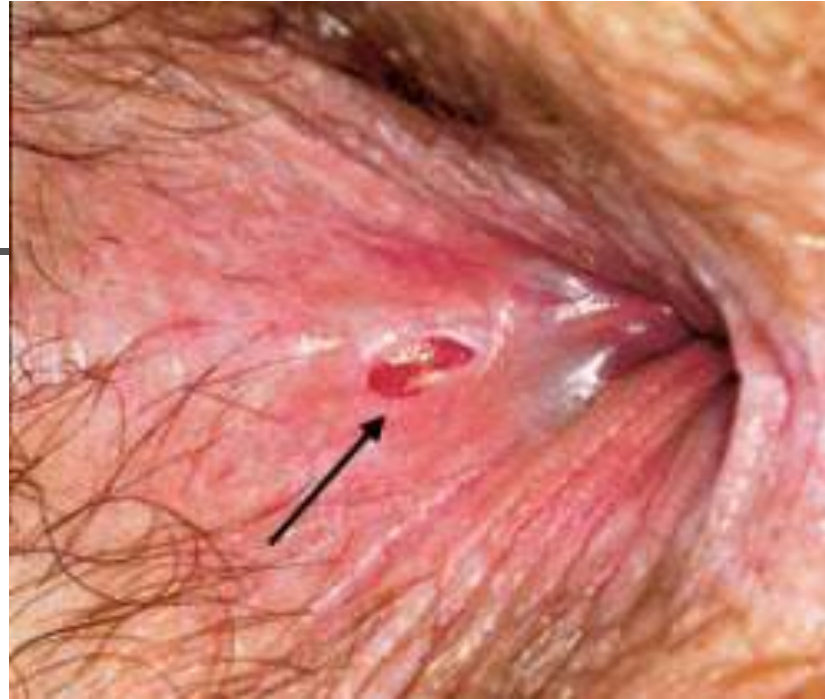Thrombosed external hemorrhoids (*long arrow*) and perianal tags from "old" disease (*short arrow*).



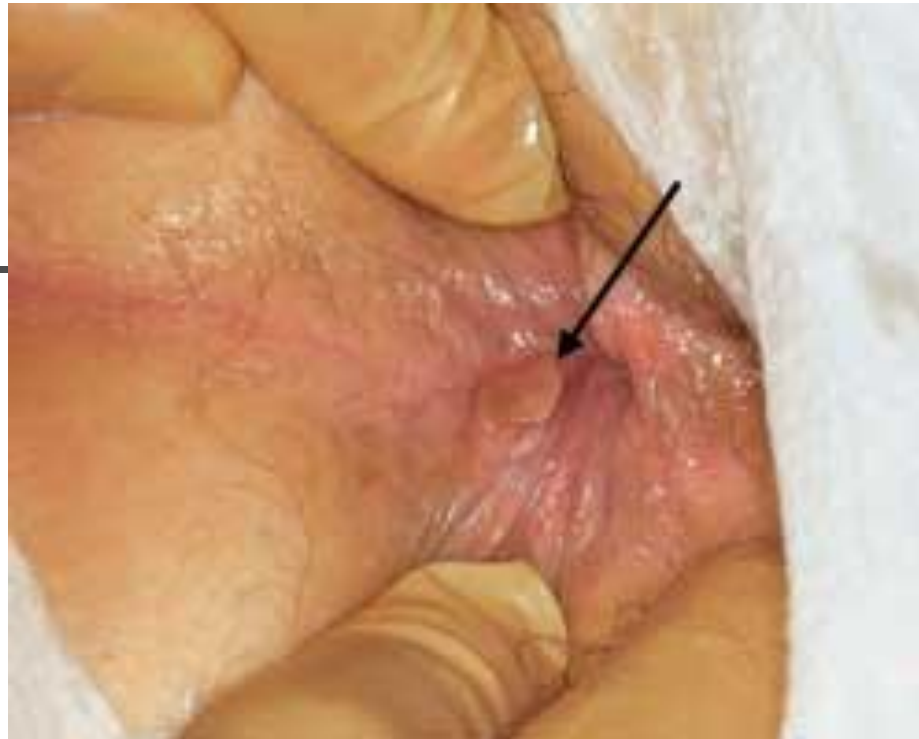Prolapsed internal hemorrhoids, grade IV (*long black arrow*). The dentate line (*short black arrow*) is indicated, and a small polyp (*white arrow*) is visible.



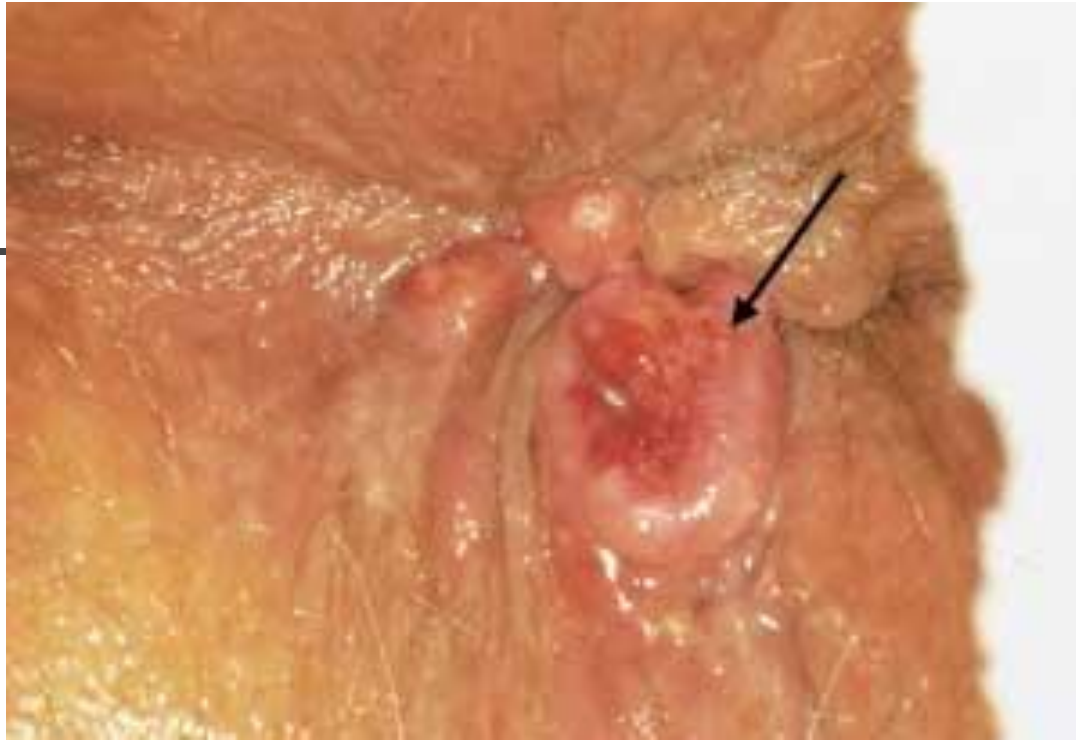Extensive perianal condyloma acuminata (*arrow*). This condition is generally caused by infection with human papillomavirus 6 or 11.



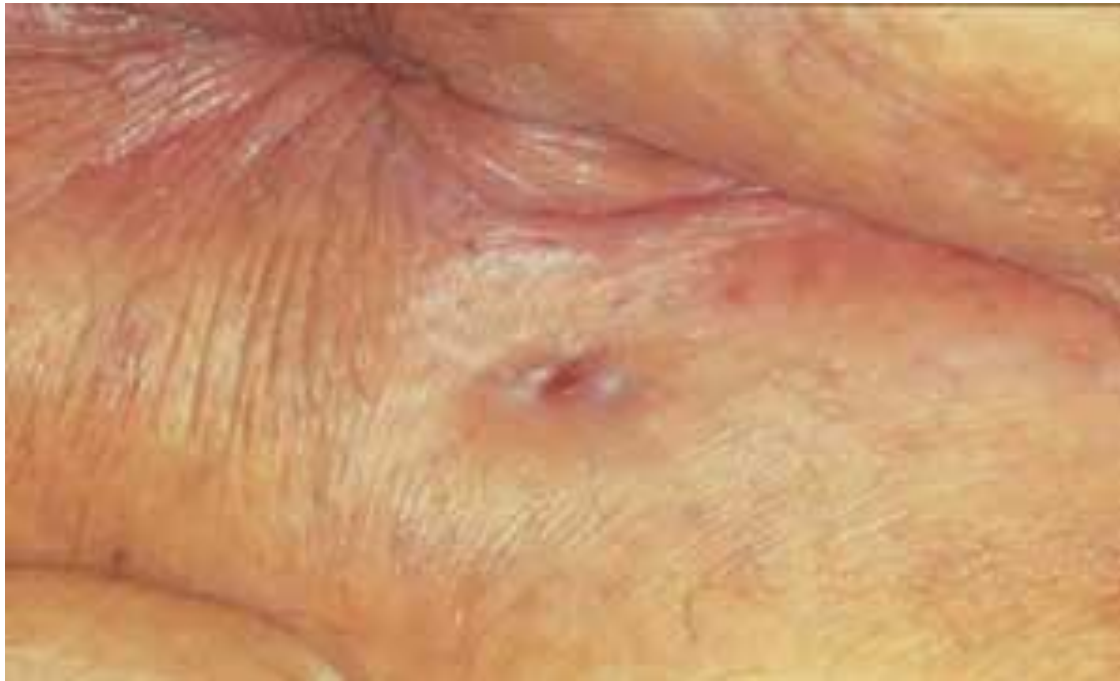Acute posterior fissure (*arrow*). Anterior and posterior fissures are most common. Fissures can often be identified by merely spreading the glutei but generally require anoscopy. When fissures are found laterally, syphilis, tuberculosis, occult abscesses, leukemic infiltrates, carcinoma, herpes, acquired immunodeficiency syndrome (AIDS) or inflammatory bowel disease should be considered as causes.



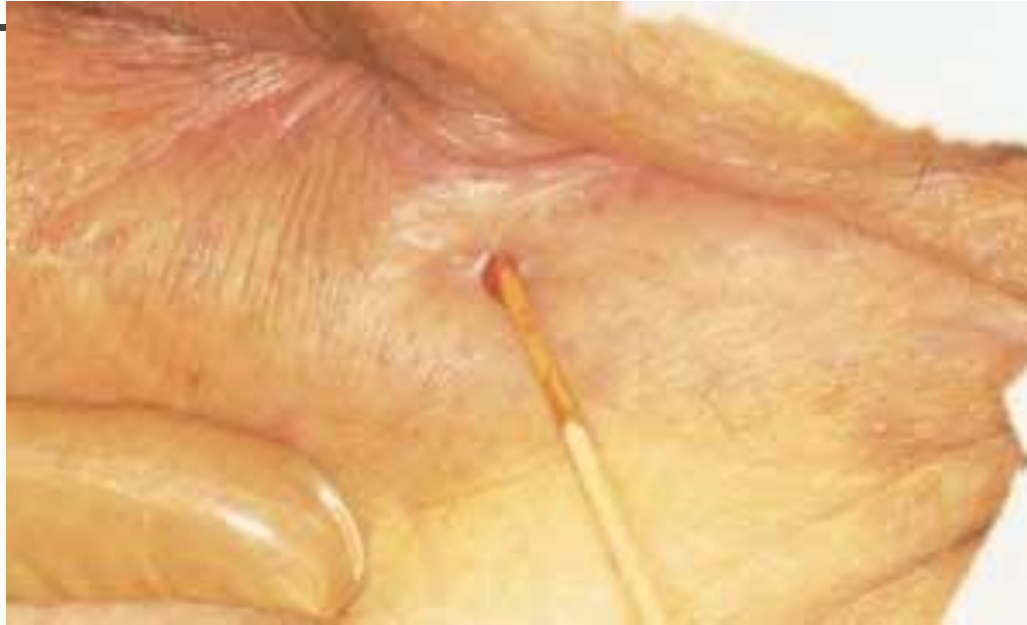Anal tag (*arrow*). Anal tags should be removed or a biopsy should be obtained to confirm the etiology. Anoscopy may enable the physician to identify the cause or find other lesions.



Anal cancer (*arrow*). This anal cancer had been treated for three months with steroid suppositories although the patient had never had a physical examination. Simple inspection of the external anal area allowed the physician to identify this aggressive tumor.



External site of perianal fistula. This patient presented with "just a little blood when I wipe."



The wooden end of a cotton-tipped applicator was inserted 3 cm (see *Figure 5*), confirming a fistula. Blood on the end of a cotton-tipped applicator being withdrawn from a fistula that could easily have been missed.