

- ## • Enviromental

- Usability of the horse
- Enviromental conditio in stable
- Food quality
- Dentsity of animals in stable
- New animal in stable
- Vaccination
- Transport
- participation in competitions

- History of the disease



- General examination

- Heart rate, breath rate, lymph nodes, membrane mucus, temperature

- Detail examination of:

- Type o breath,
- Nasal discharge
- Cough
- Auscultation of the larynx, trachea, and chest
- Percussion

- Aditional tests

- Endoscopy (BAL, TW)
- USG
- X- ray
- Endoskopy during exercise

[REDACTED]

- [REDACTED]

- [REDACTED]

- [REDACTED]

- [REDACTED]

- [REDACTED]

- [REDACTED]

- [REDACTED]

- [REDACTED]

- [REDACTED]

- [REDACTED]

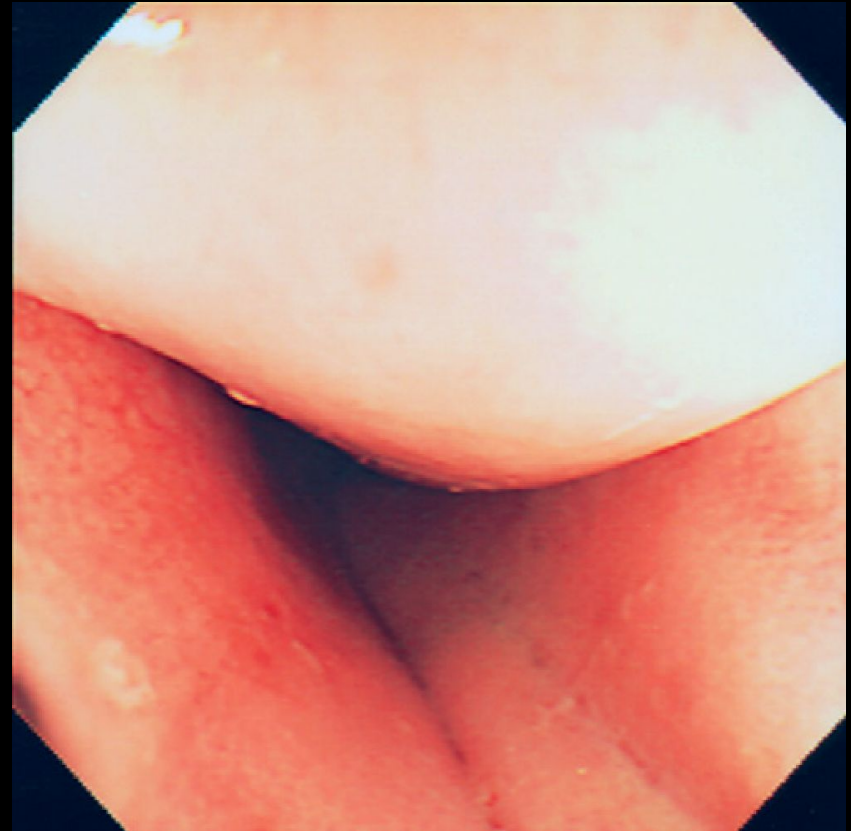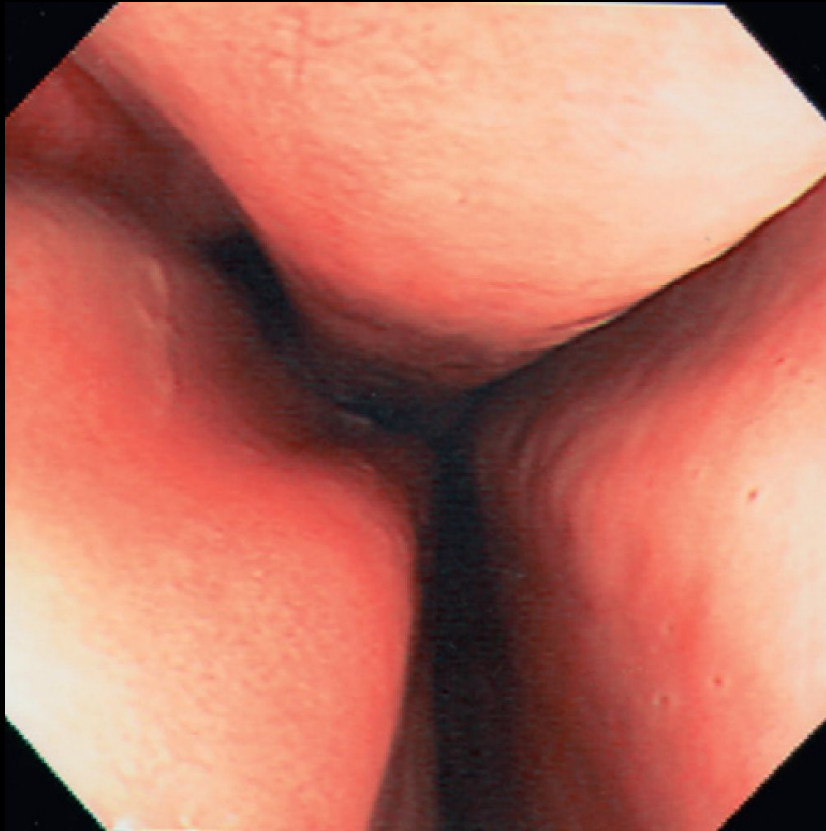- [REDACTED]

- [REDACTED]

- [REDACTED]

- [REDACTED]

Nasal cavity



do prezentacji użyto zdjęć z Atlas of Equine
Endoscopy N.M.Slovis wyd Mosby

[REDACTED]

[REDACTED]

[REDACTED]

[REDACTED]

[REDACTED]

[REDACTED]

[REDACTED]

[REDACTED]

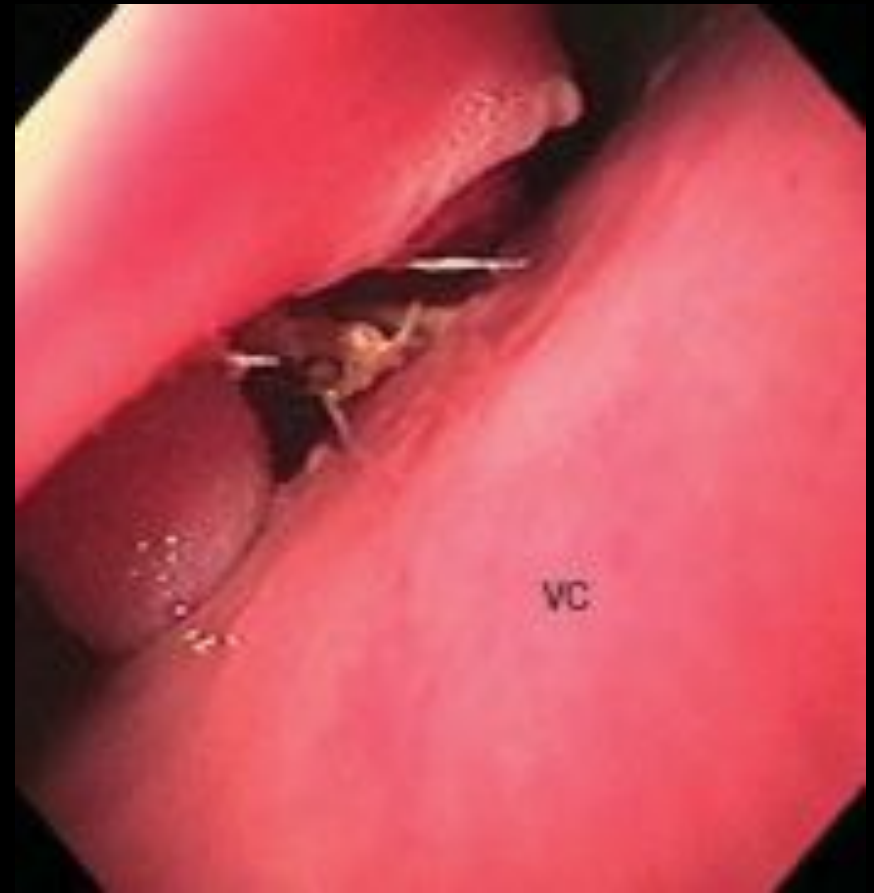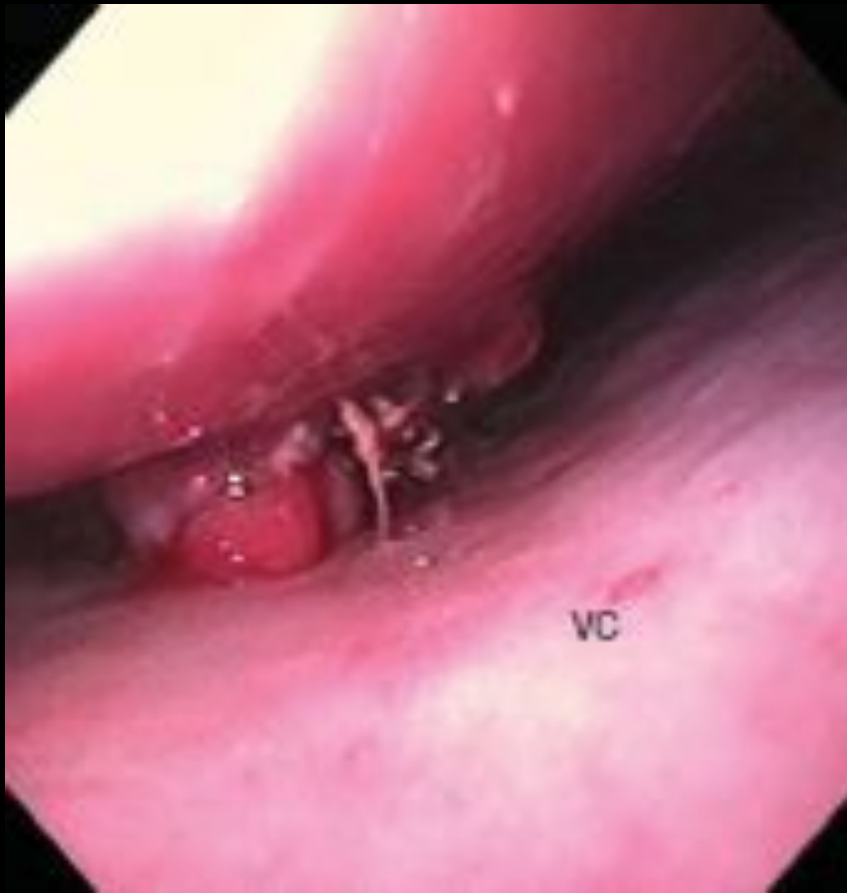[REDACTED]

[REDACTED]

[REDACTED]

[REDACTED]

Foreign body in the nasal cavity



[REDACTED]

[REDACTED]

[REDACTED]

[REDACTED]

[REDACTED]

[REDACTED]

[REDACTED]

[REDACTED]

[REDACTED]

[REDACTED]

[REDACTED]

[REDACTED]

[REDACTED]

[REDACTED]

[REDACTED]

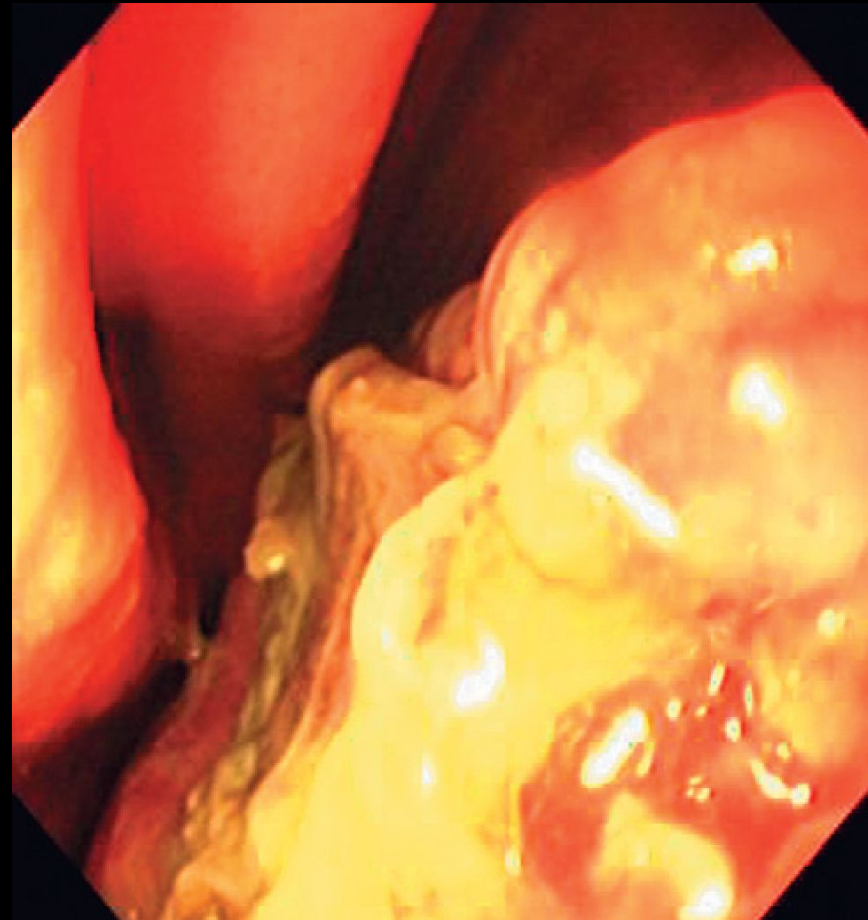
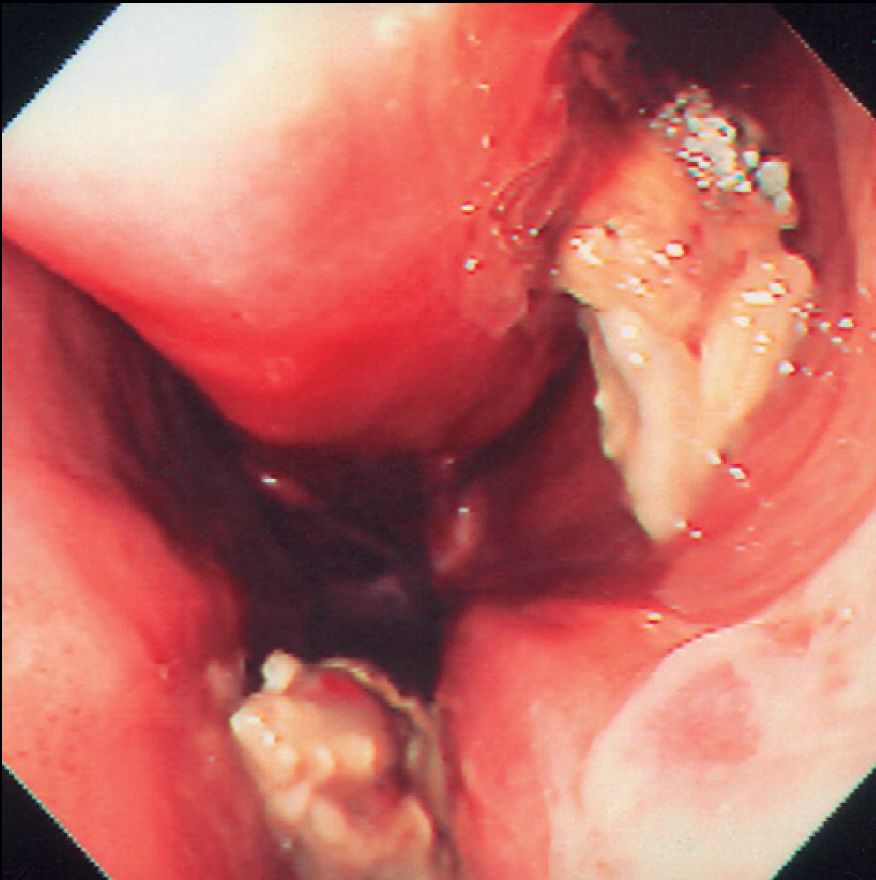
[REDACTED]

[REDACTED]

[REDACTED]

[REDACTED]

Fungal plaques typical of infection of the nasal cavities with *Aspergillus* spp.



[Redacted]

[Redacted]

- [Redacted]

[Redacted]

- [Redacted]

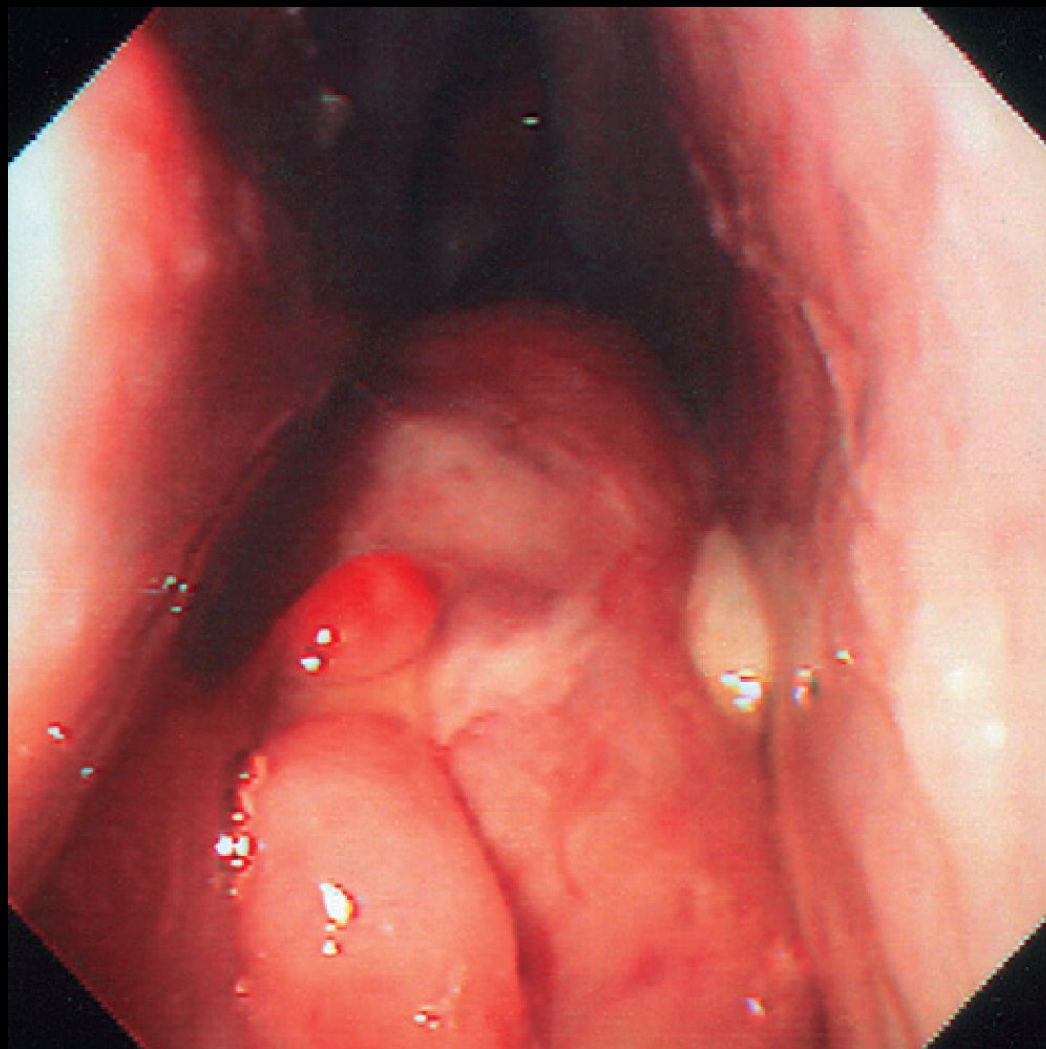
[Redacted]

- [Redacted]

[Redacted]

- [Redacted]

Polyps



do prezentacji użyto zdjęć z Atlas of Equine
Endoscopy N.M.Slovis wyd Mosby

[Redacted]

[Redacted]

[Redacted]

[Redacted]

[Redacted]

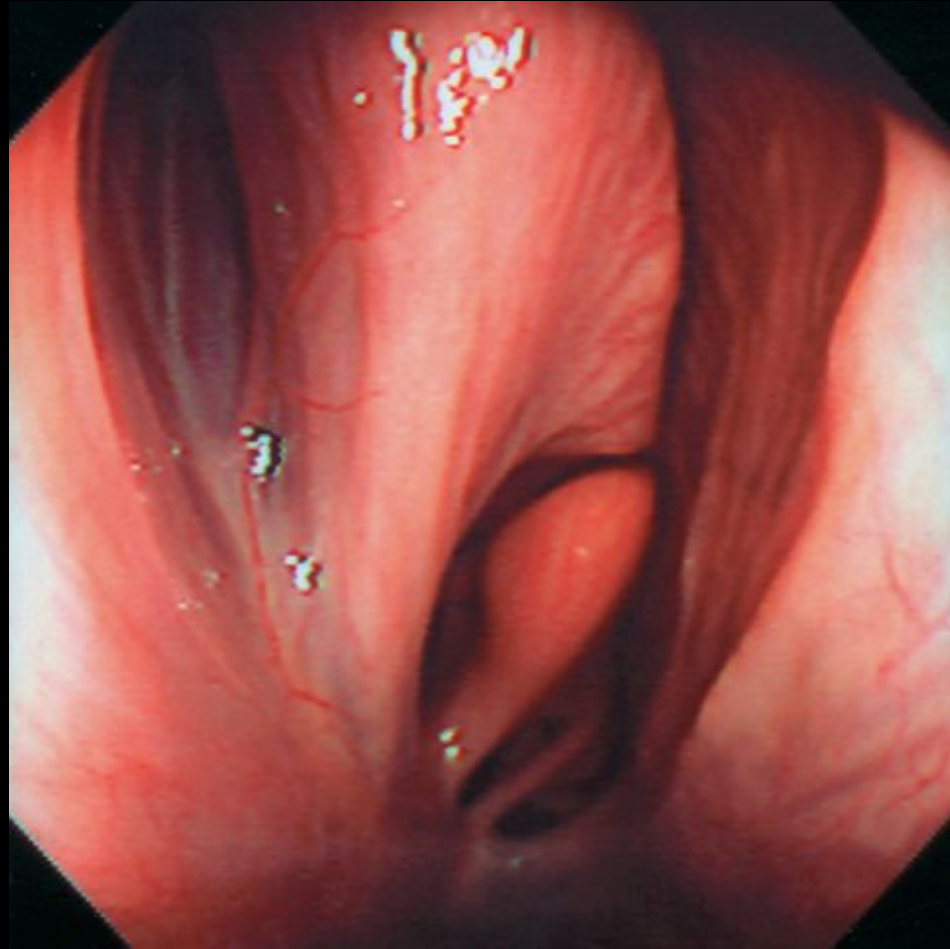
[Redacted]

[Redacted]

[Redacted]

[Redacted]

Ethmoid conchae



do prezentacji użyto zdjęć z Atlas of Equine
Endoscopy N.M.Slovis wyd Mosby

[Redacted]

[Redacted]

- [Redacted]

- [Redacted]

- [Redacted]

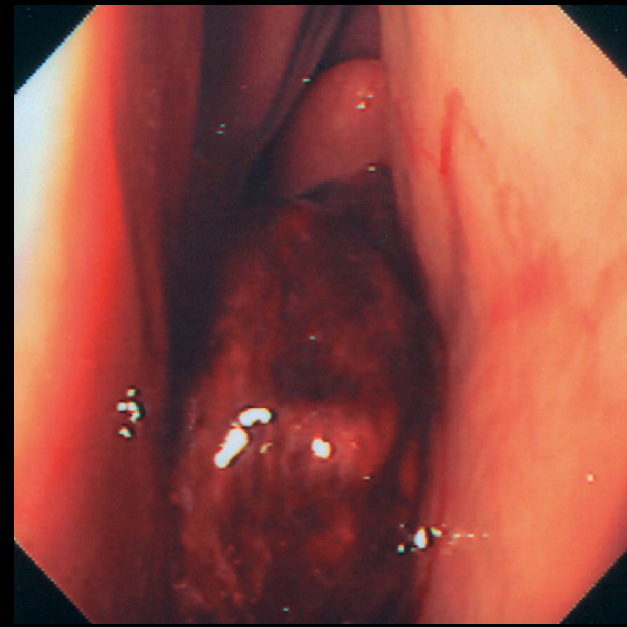
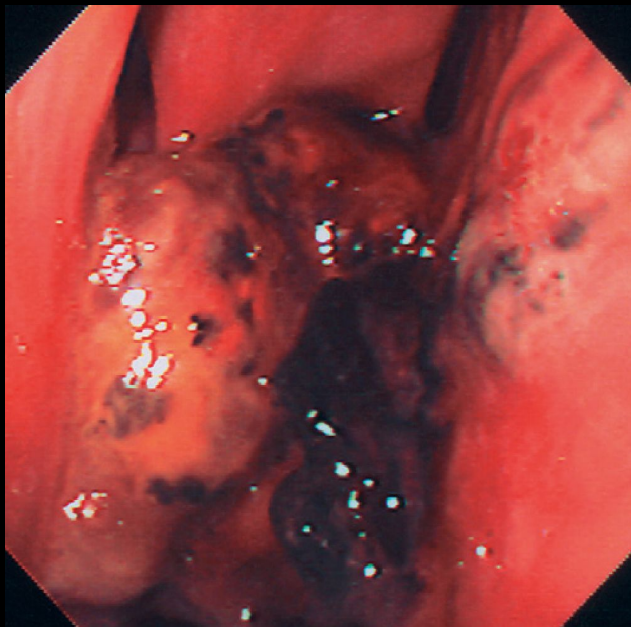
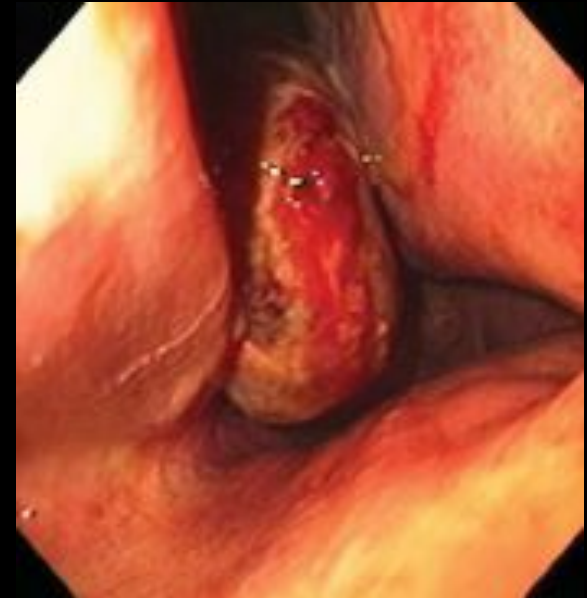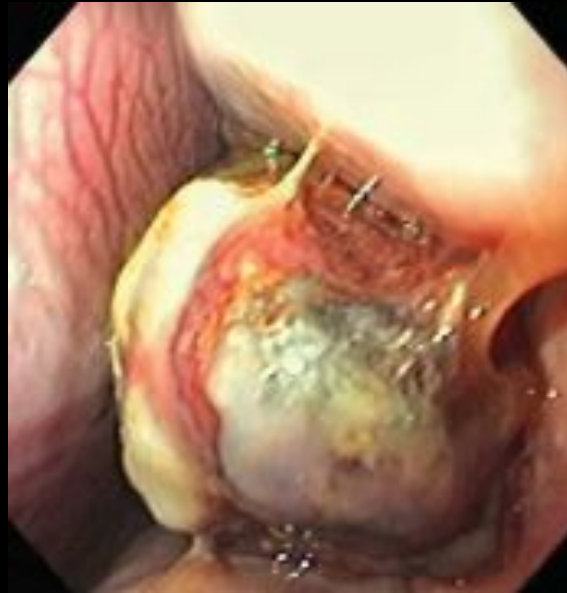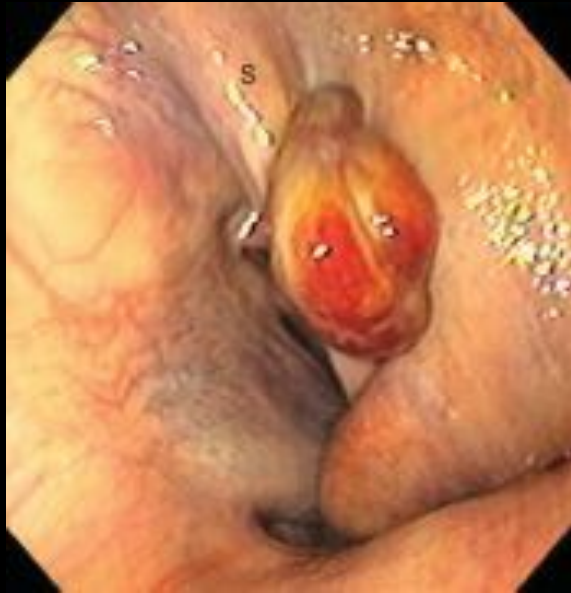- [Redacted]

- [Redacted]

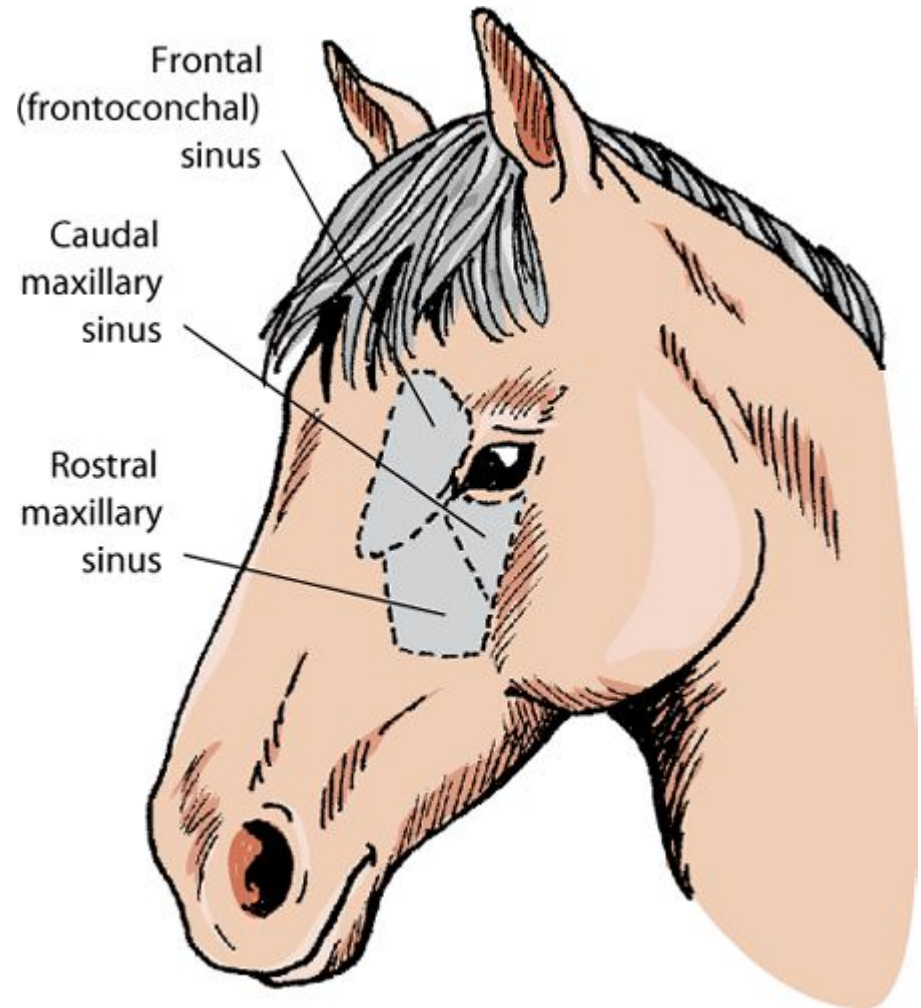
- [Redacted]

- [Redacted]

Ethmoidal haematoma



do prezentacji użyto zdjęć z Atlas of Equine
Endoscopy N.M.Slovis wyd Mosby



[Redacted]

[Redacted]

- [Redacted]

- [Redacted]

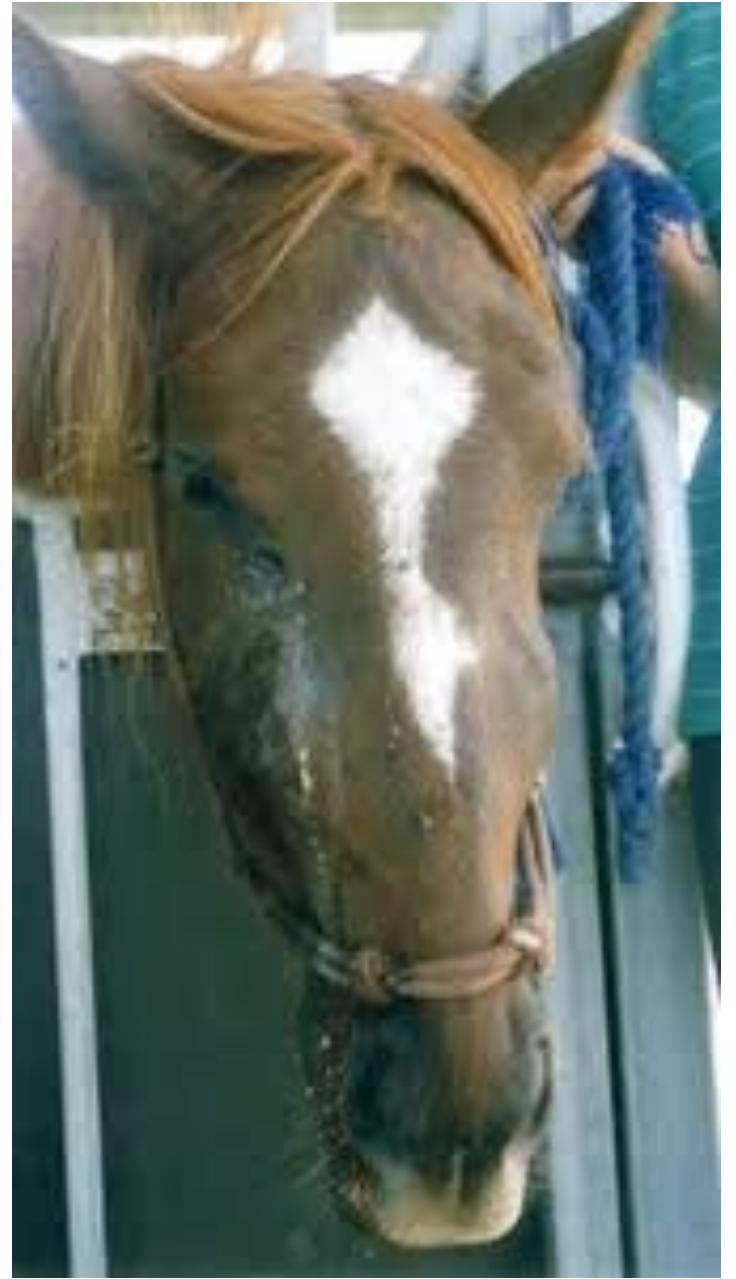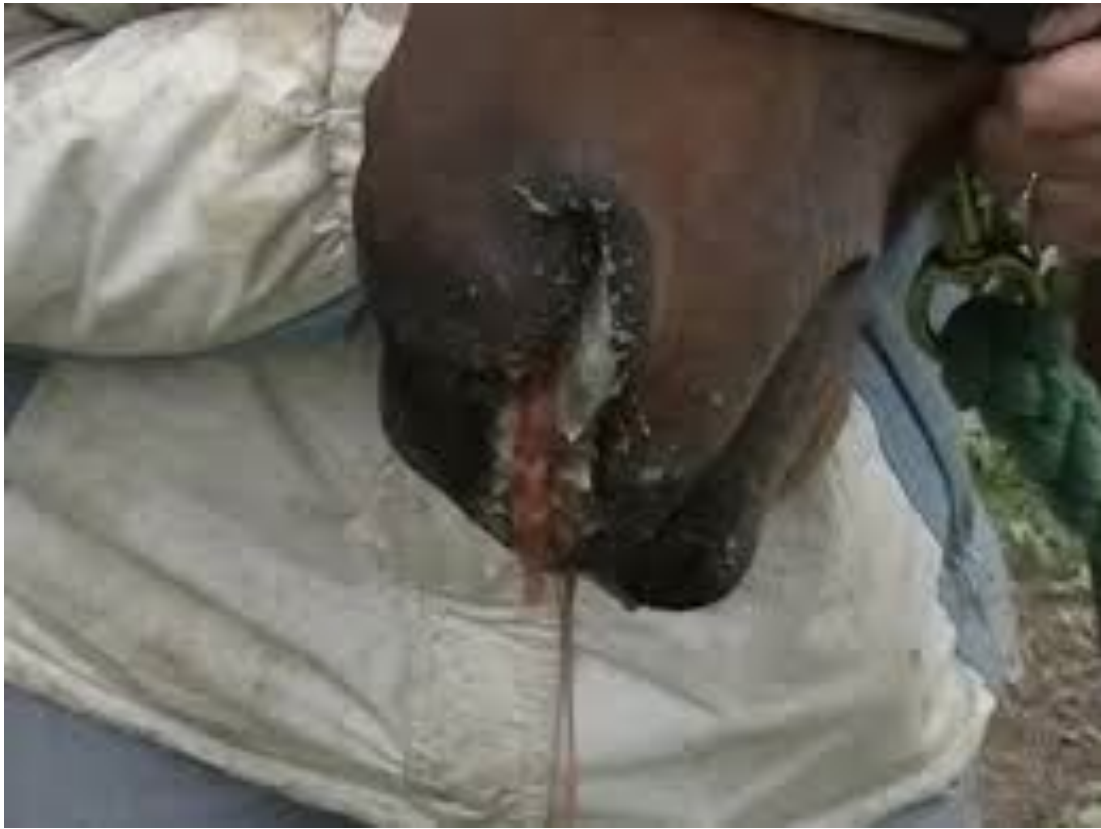- [Redacted]

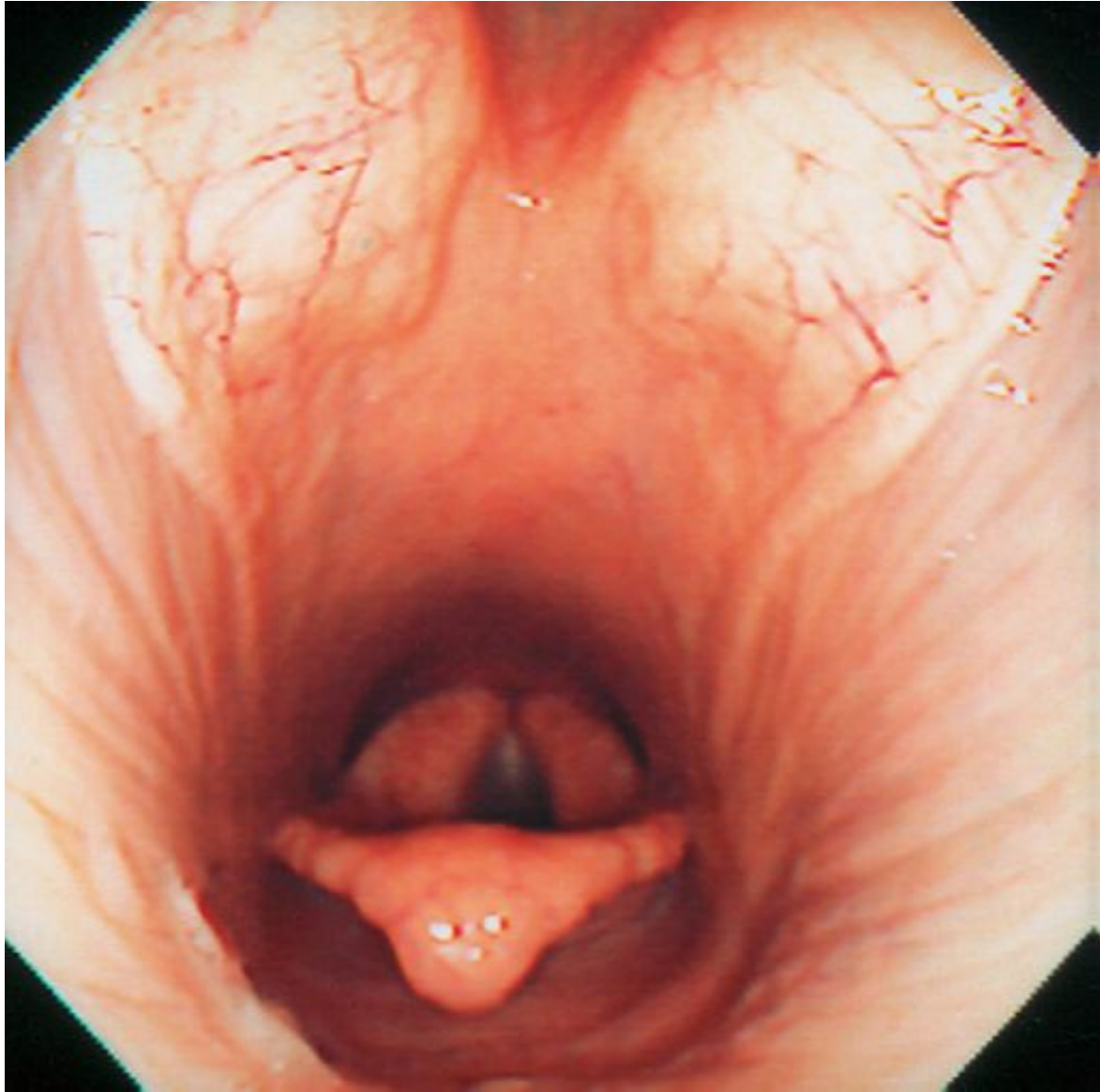
- [Redacted]

- [Redacted]

- [Redacted]

- [Redacted]





[REDACTED]

[REDACTED]

- [REDACTED]

- [REDACTED]

- [REDACTED]

[Redacted]

[Redacted]

- [Redacted]

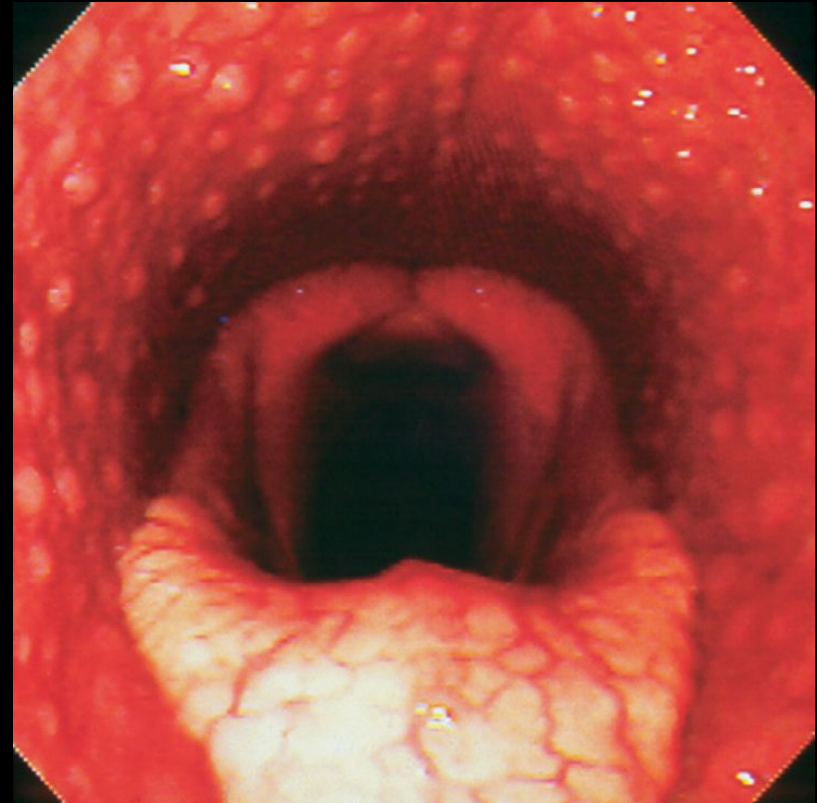
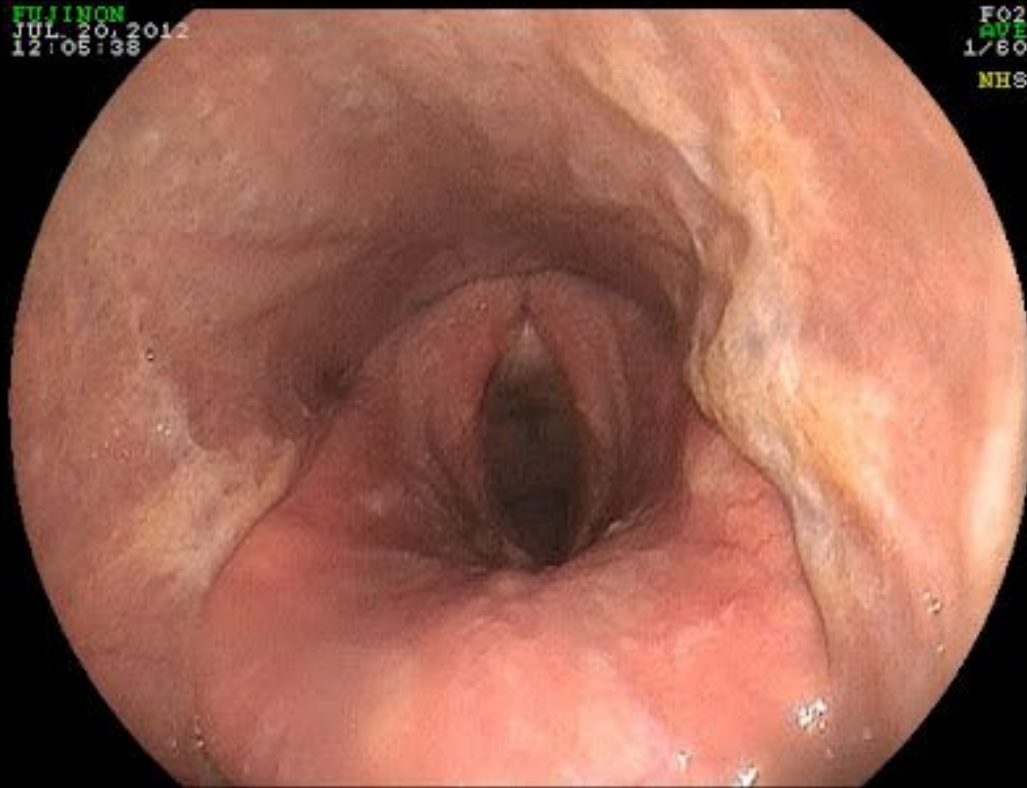
- [Redacted]

- [Redacted]

- [Redacted]

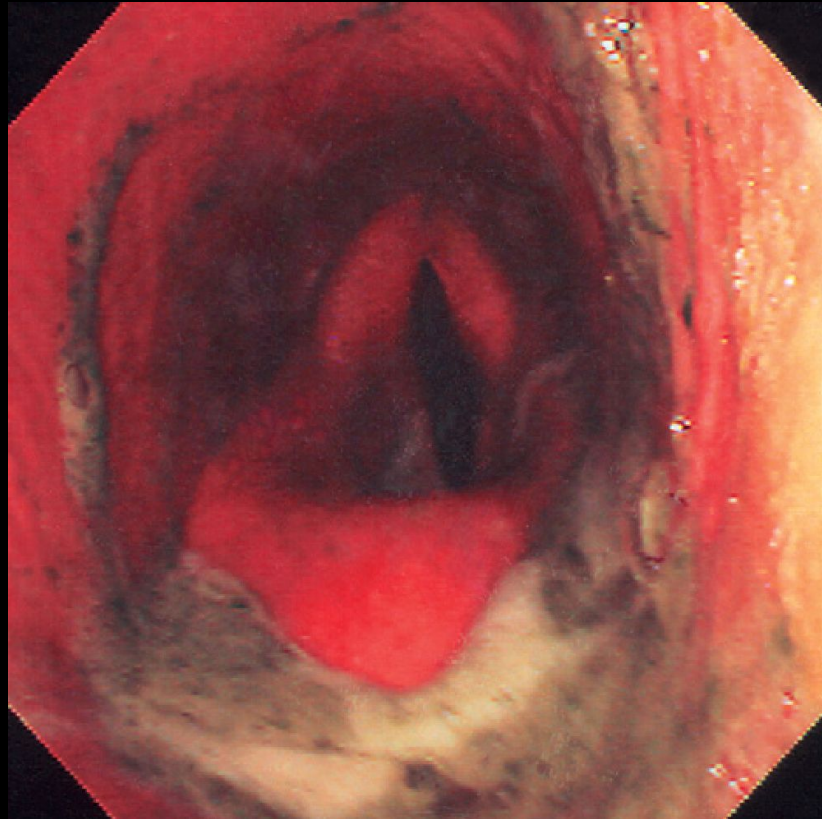
- [Redacted]

Pharyngitis



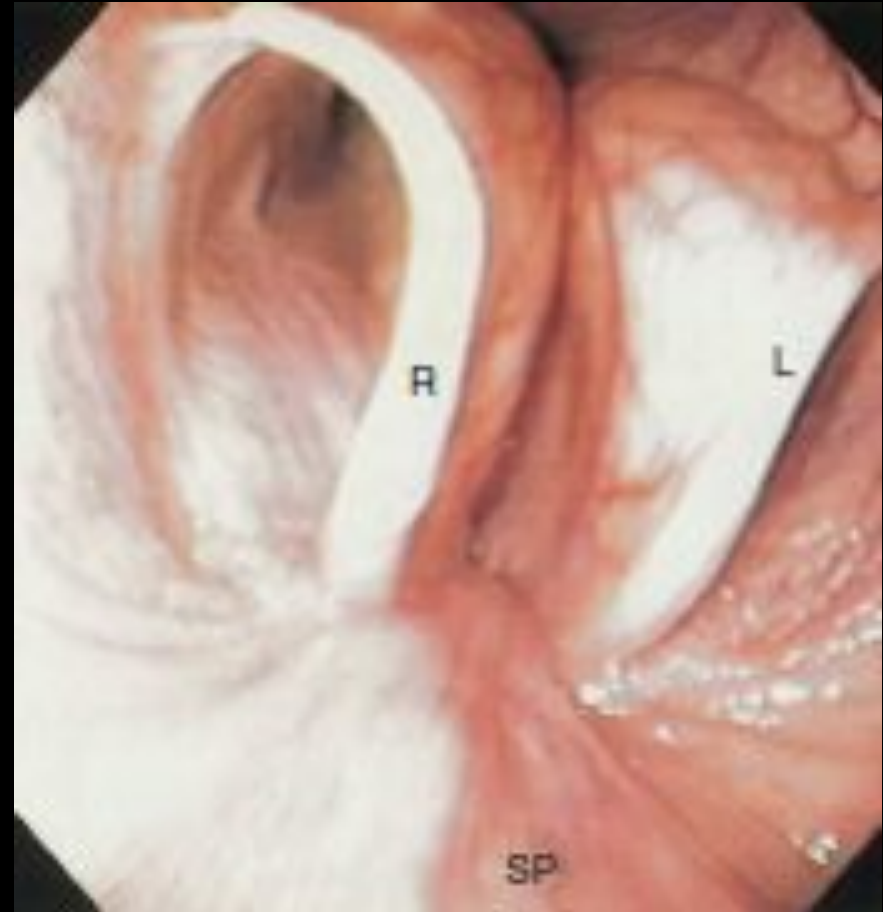
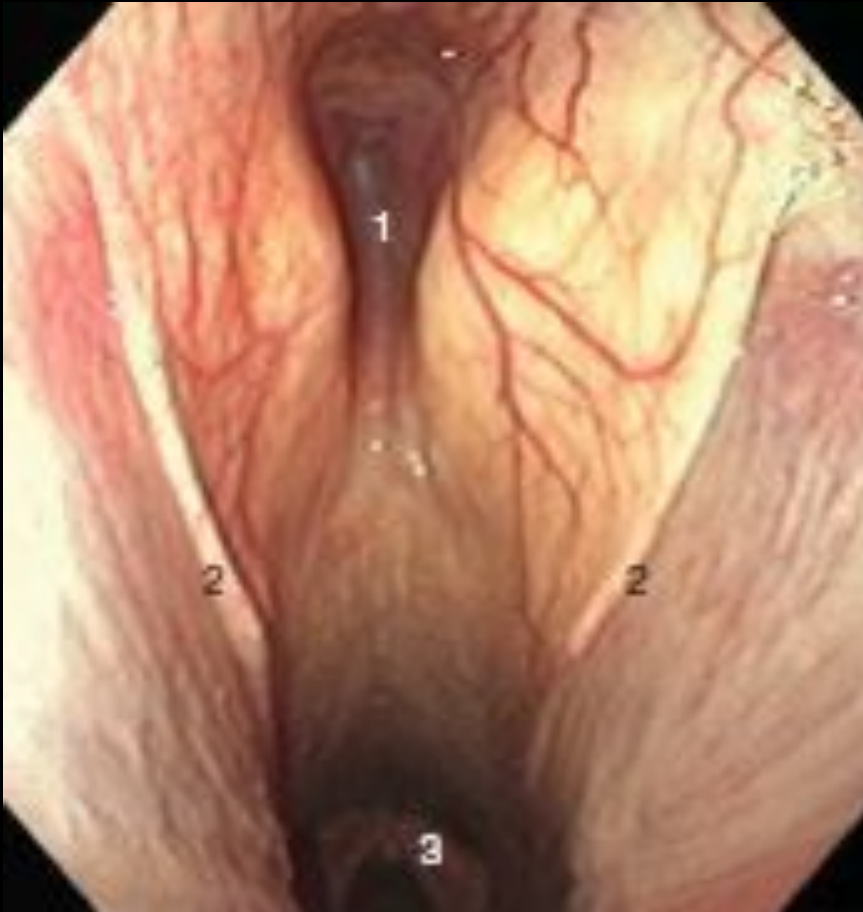Pharyngeal lymphoid hyperplasia

Pharyngeal paralysis



do prezentacji użyto zdjęć z Atlas of Equine
Endoscopy N.M.Slovis wyd Mosby

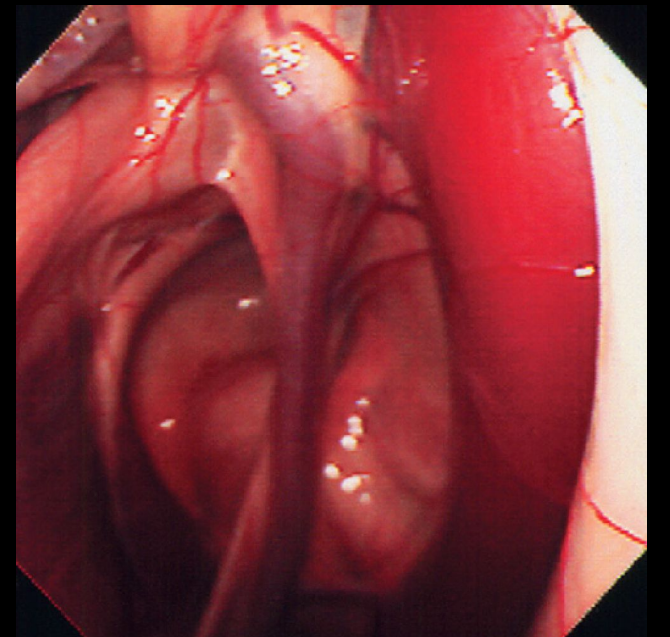
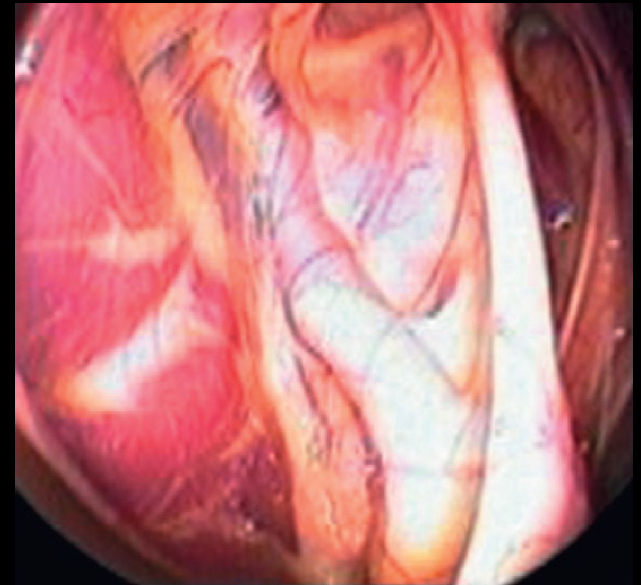
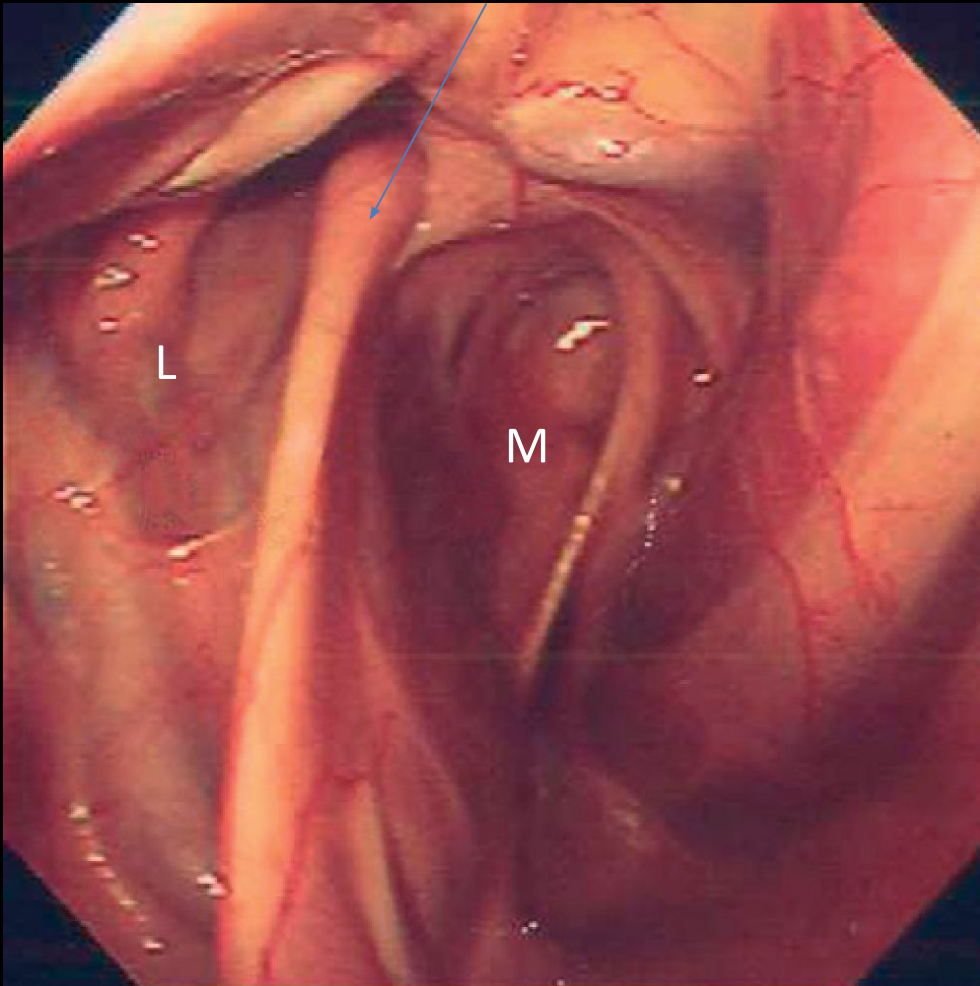
Guttural pouch



do prezentacji użyto zdjęć z Atlas of Equine
Endoscopy N.M.Slovis wyd Mosby

Guttural pouches

Stylohyoid bone



do prezentacji użyto zdjęć z Atlas of Equine
Endoscopy N.M.Slovis wyd Mosby

[REDACTED]

[REDACTED]

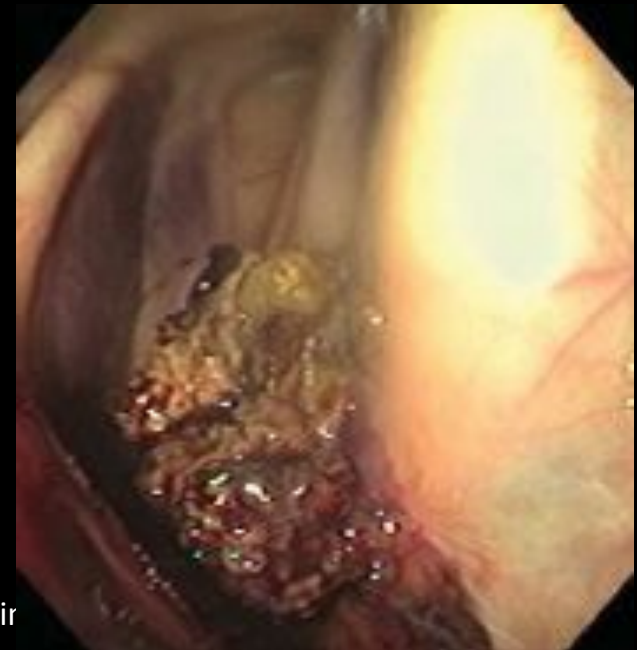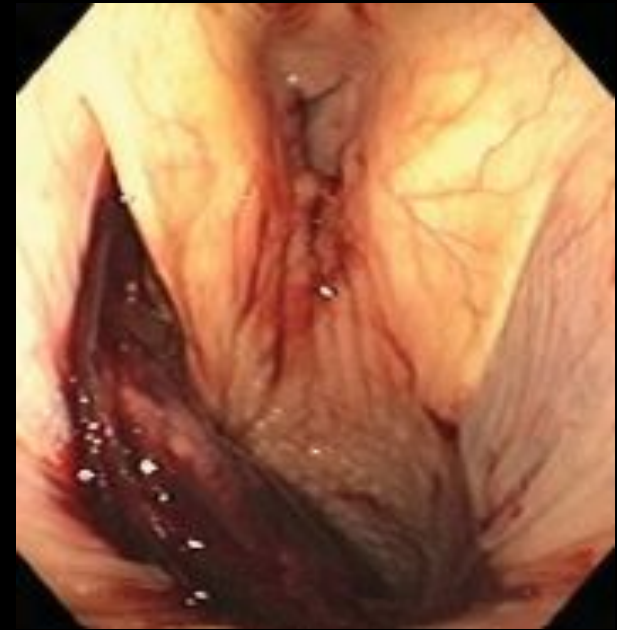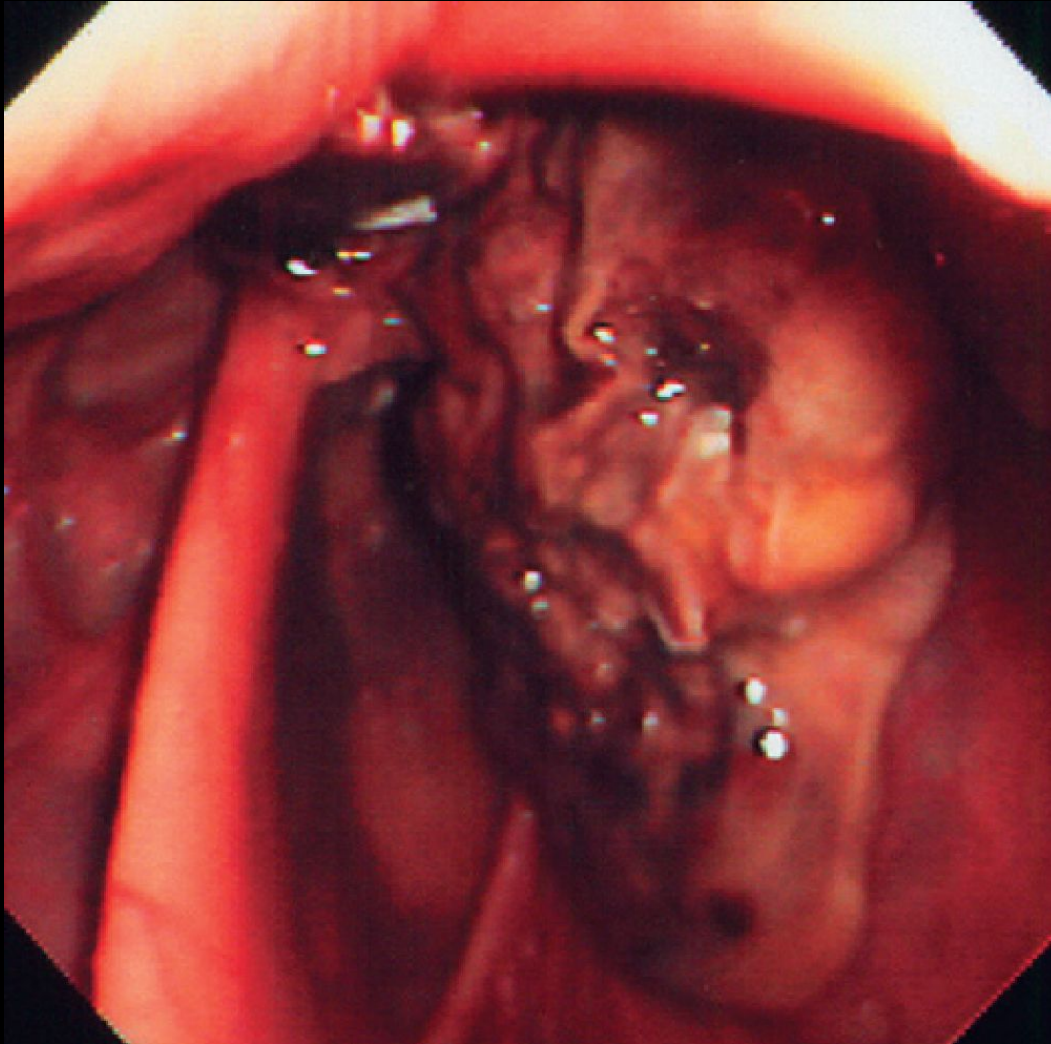
- [REDACTED]

- [REDACTED]

- [REDACTED]

- [REDACTED]

Mycosis of the guttural pouches



do prezentacji użyto zdjęć z Atlas of Equir
Endoscopy N.M.Slovis wyd Mosby

[Redacted]

[Redacted]

- [Redacted]

- [Redacted]

- [Redacted]

- [Redacted]

- [Redacted]

- [Redacted]

- [Redacted]

[Redacted]

[Redacted]

- [Redacted]

- [Redacted]

- [Redacted]

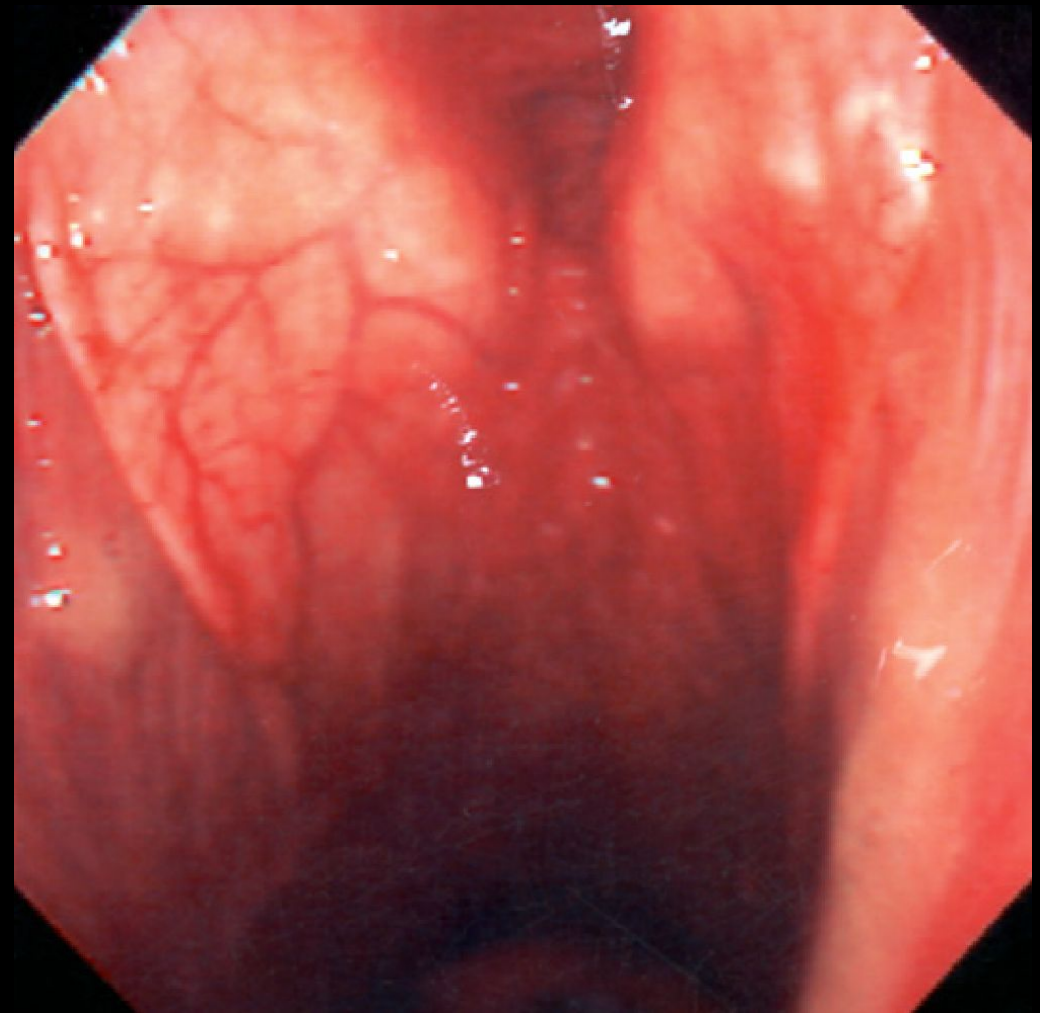
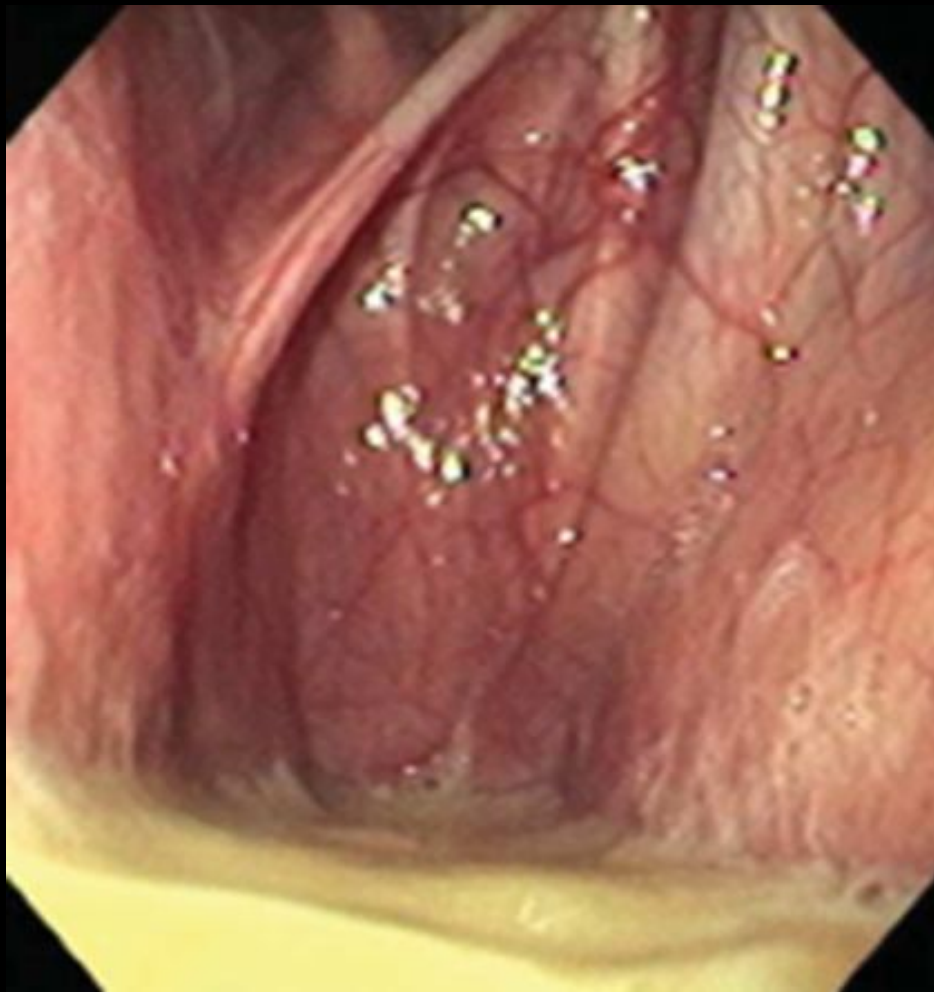- [Redacted]

- [Redacted]

- [Redacted]

- [Redacted]

Purulent inflammation of the guttural pouch



[Redacted]

[Redacted]

- [Redacted]

- [Redacted]

- [Redacted]

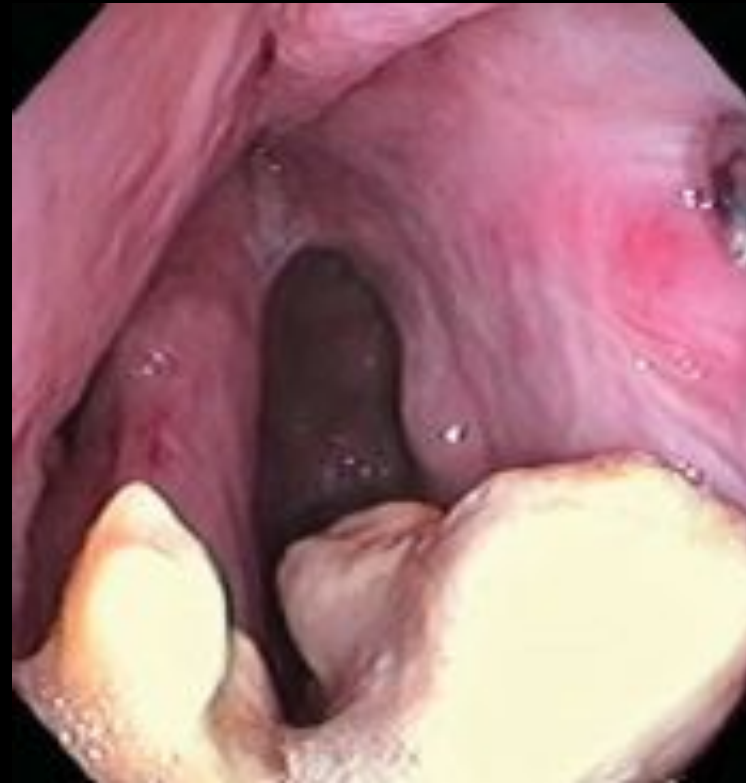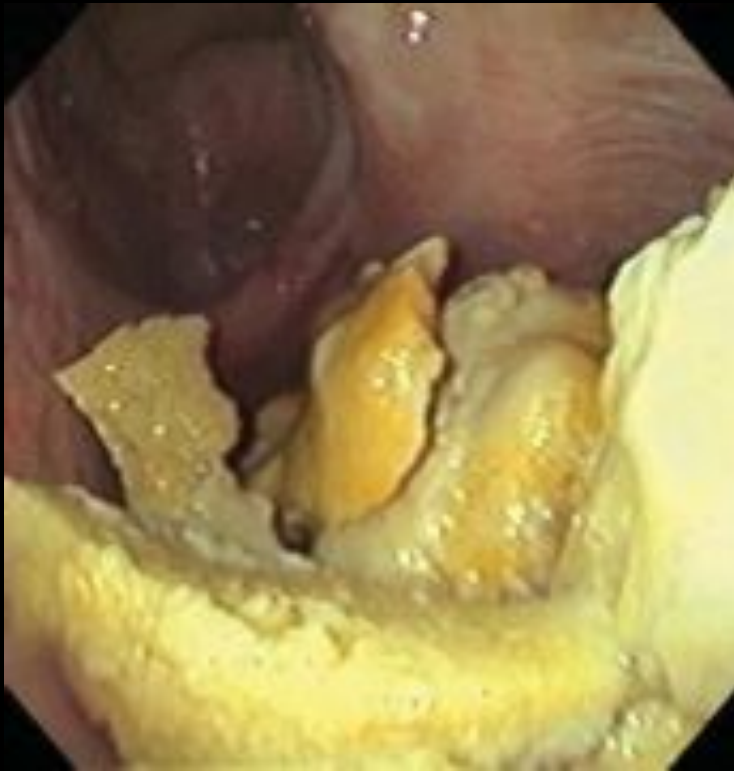- [Redacted]

- [Redacted]

- [Redacted]

- [Redacted]

Chondroids of the guttural pouch



do prezentacji użyto zdjęć z Atlas of Equine
Endoscopy N.M.Slovis wyd Mosby

[Redacted]

[Redacted]

- [Redacted]

- [Redacted]

- [Redacted]

- [Redacted]

- [Redacted]

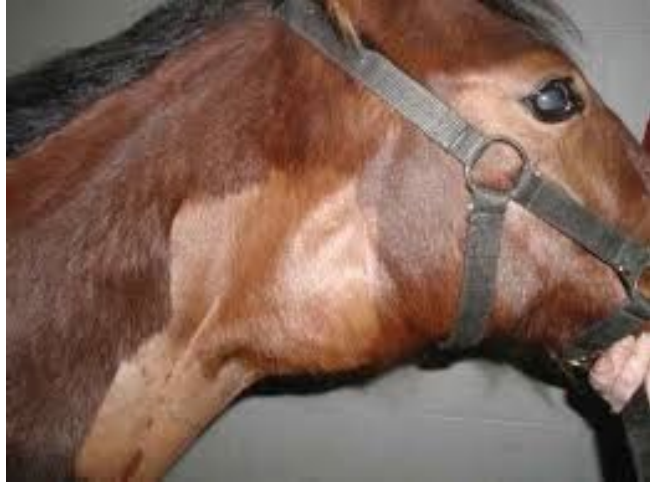- [Redacted]

- [Redacted]

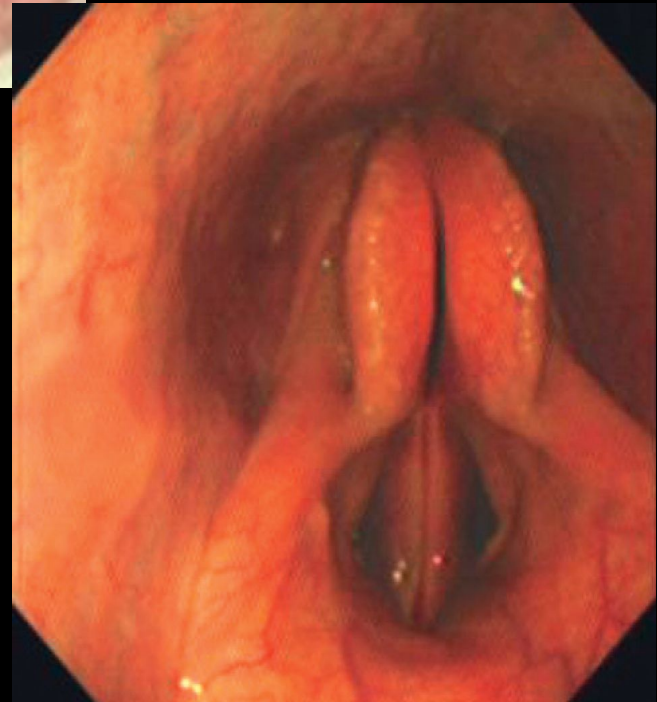
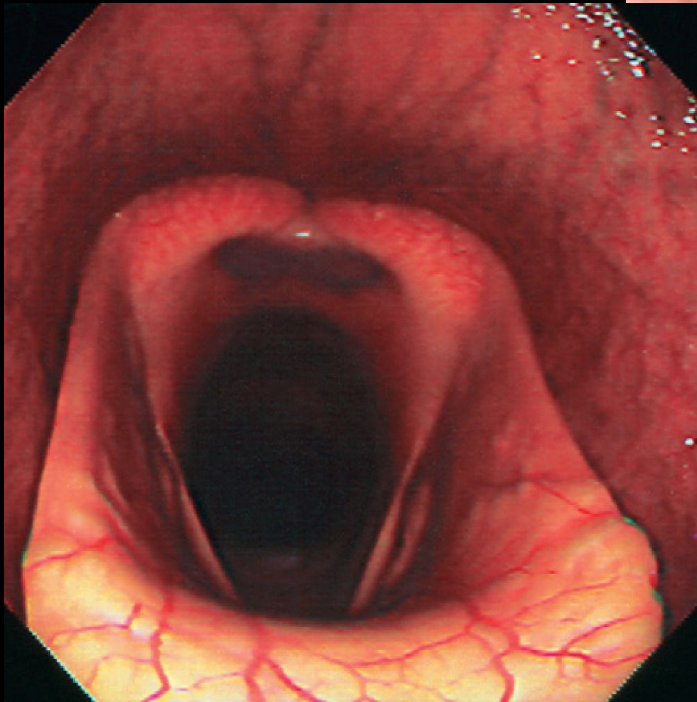
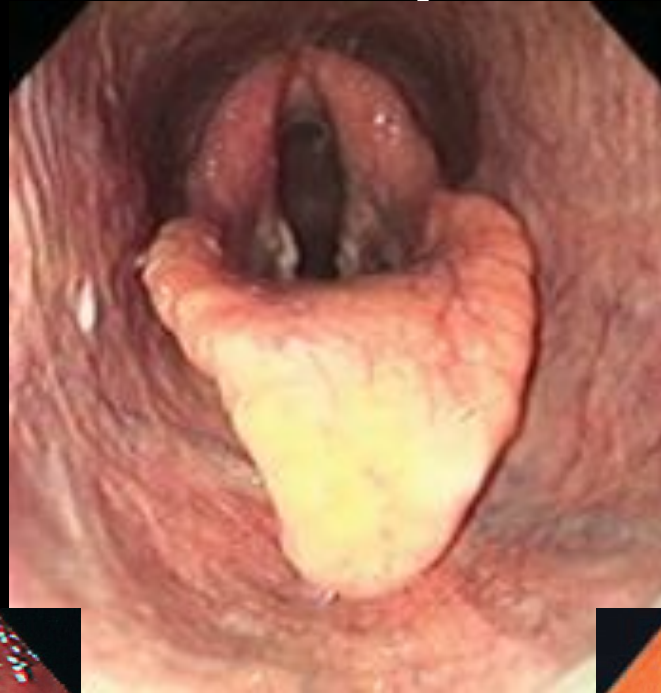- [Redacted]

- [Redacted]

[Redacted]



Larynx



do prezentacji użyto zdjęć z Atlas of Equine
Endoscopy N.M.Slovis wyd Mosby

[Redacted]

- [Redacted]

- [Redacted]

- [Redacted]

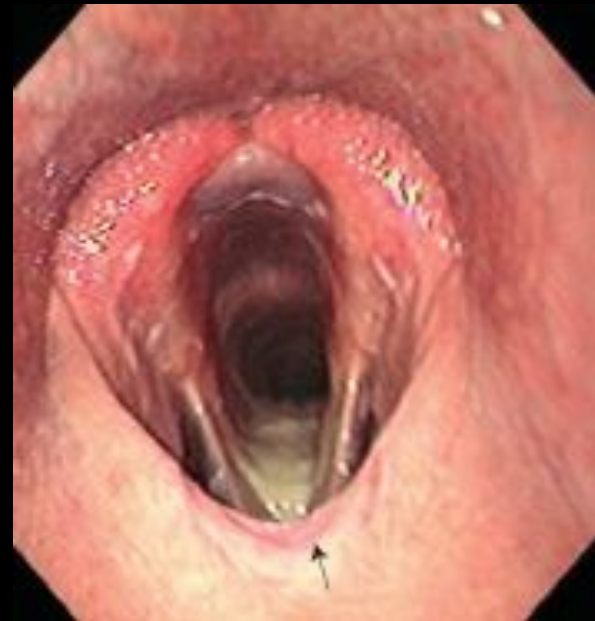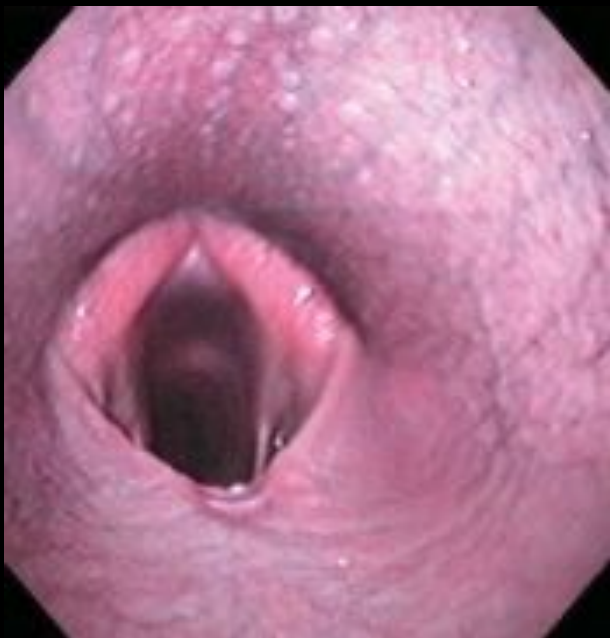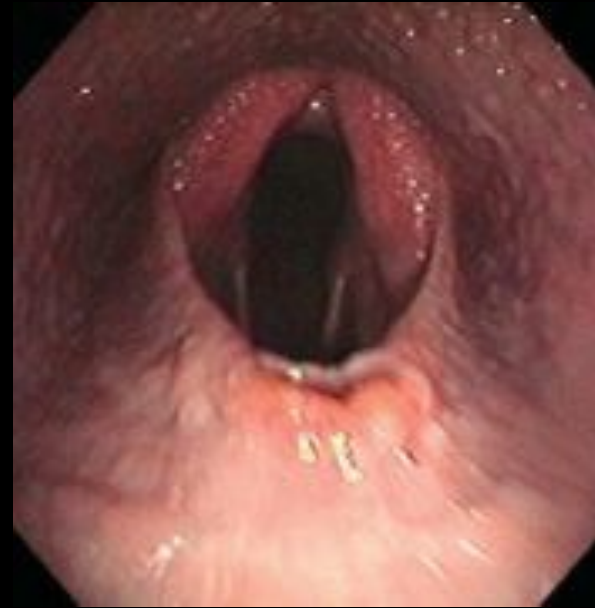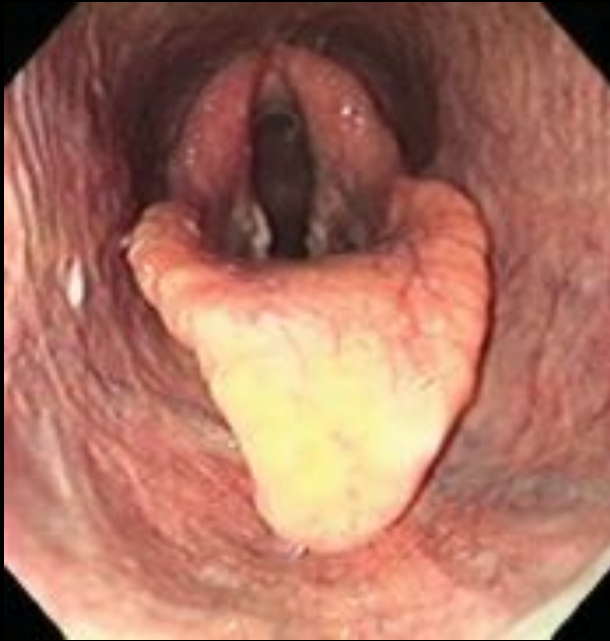- [Redacted]

- [Redacted]

- [Redacted]

- [Redacted]

Soft palate displacement



do prezentacji użyto zdjęć z Atlas of Equine
Endoscopy N.M.Slovis wyd Mosby

[Redacted]

[Redacted]

- [Redacted]

- [Redacted]

- [Redacted]

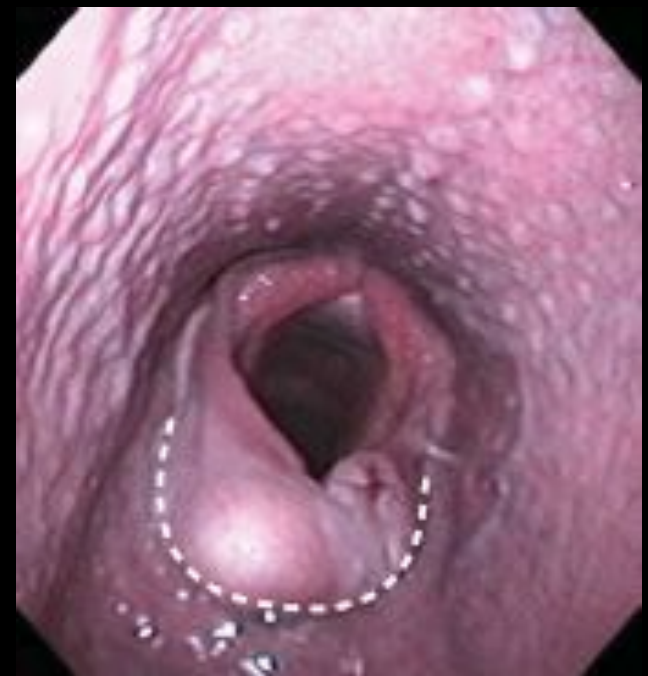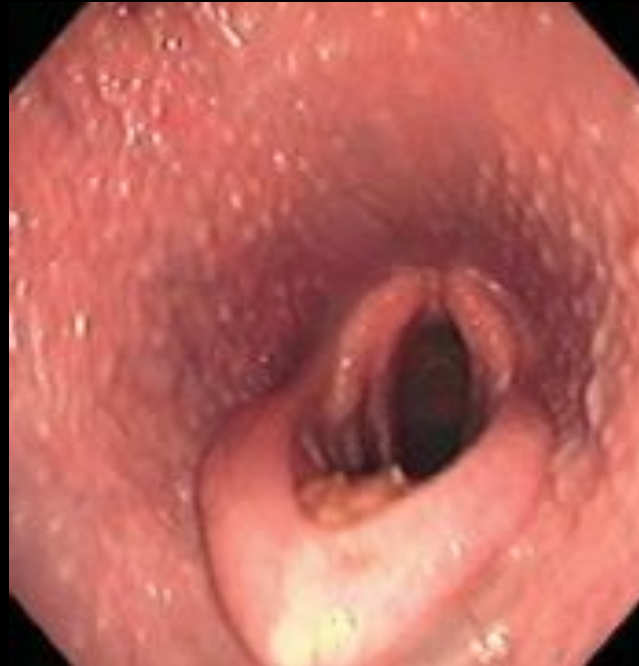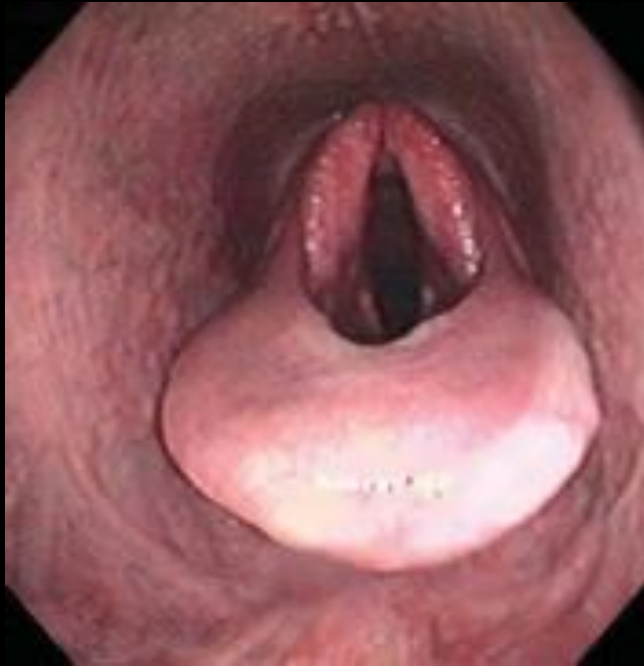- [Redacted]

- [Redacted]

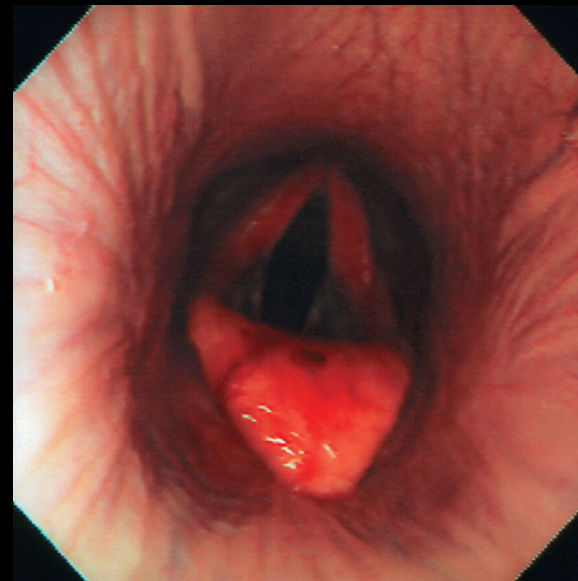
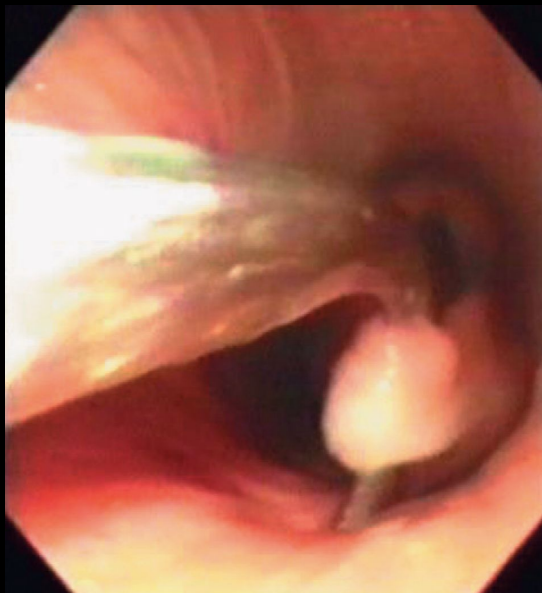
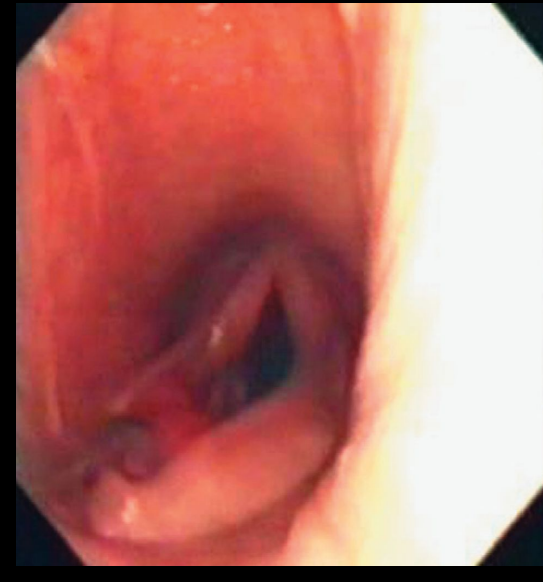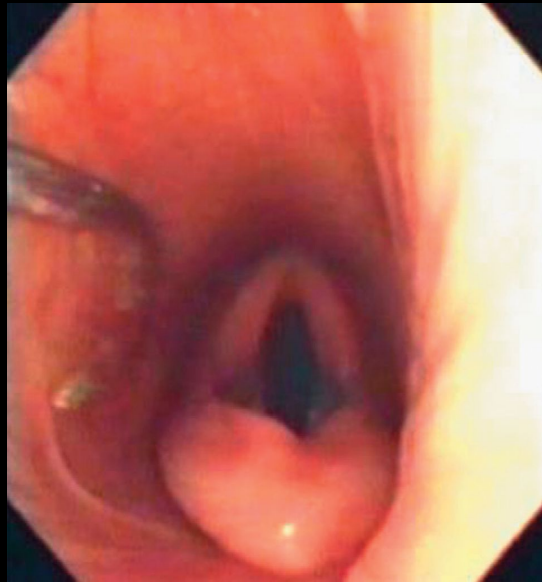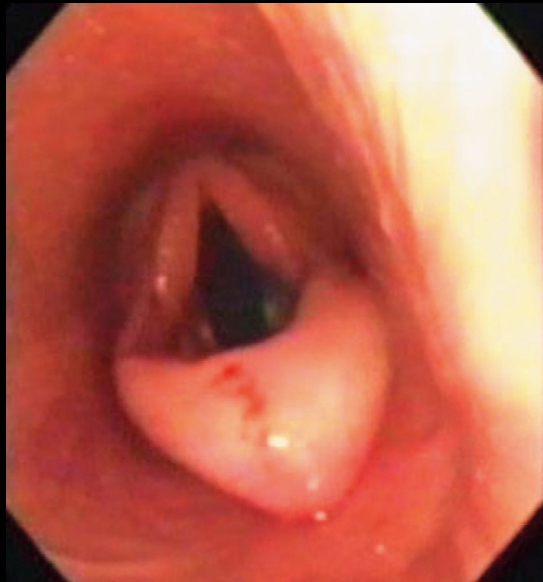
- [Redacted]

- [Redacted]

Epiglottic entrapment



Epiglottic entrapment



do prezentacji użyto zdjęć z Atlas of Equine
Endoscopy N.M.Slovis wyd Mosby

[Redacted]

[Redacted]

- [Redacted]

- [Redacted]

- [Redacted]

[Redacted]

- [Redacted]

[Redacted]

- [Redacted]

[Redacted]

[Redacted]

[Redacted]

[Redacted]

[Redacted]

[Redacted]

[Redacted]

[Redacted]

[Redacted]

[Redacted]

[Redacted]

[Redacted]

[Redacted]

- [Redacted]

- [Redacted]

- [Redacted]

- [Redacted]

- [Redacted]

- [Redacted]

- [Redacted]

[Redacted]

[Redacted]

- [Redacted]

- [Redacted]

- [Redacted]

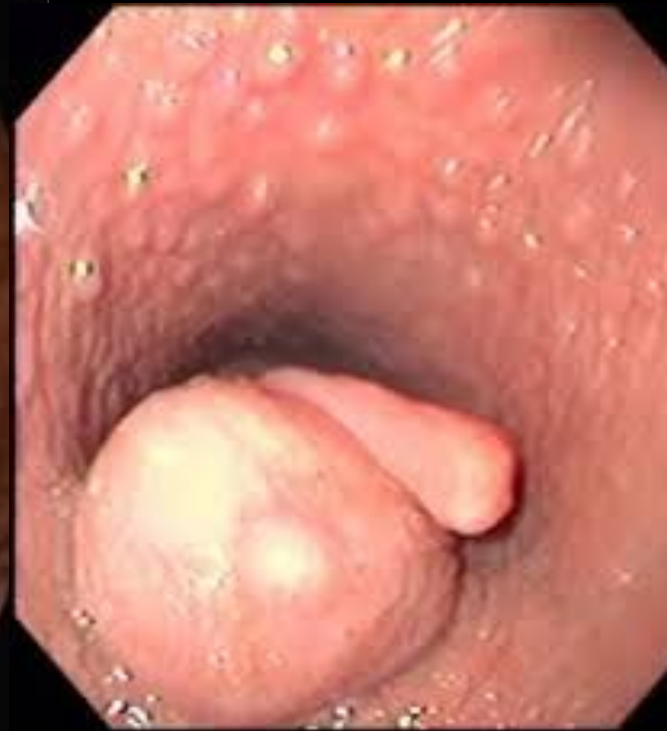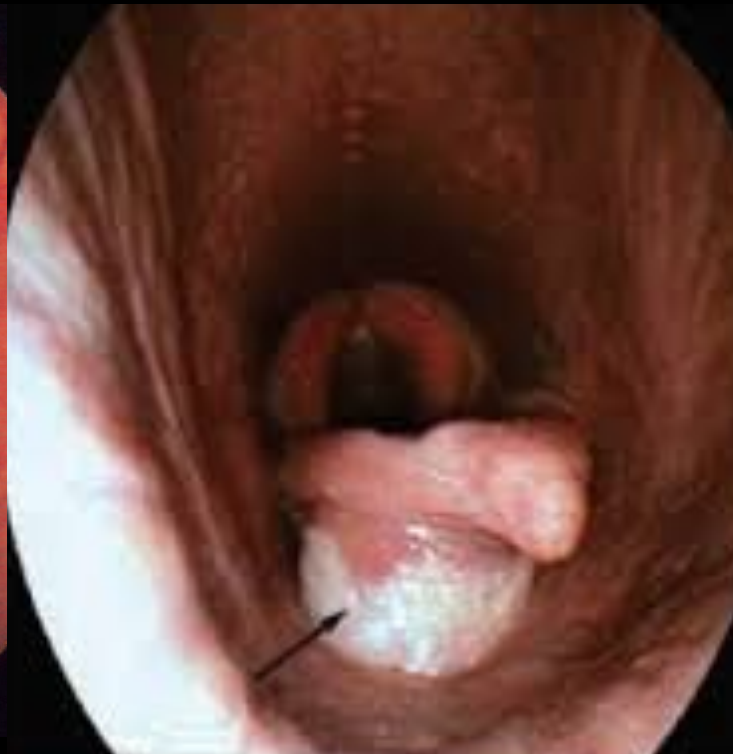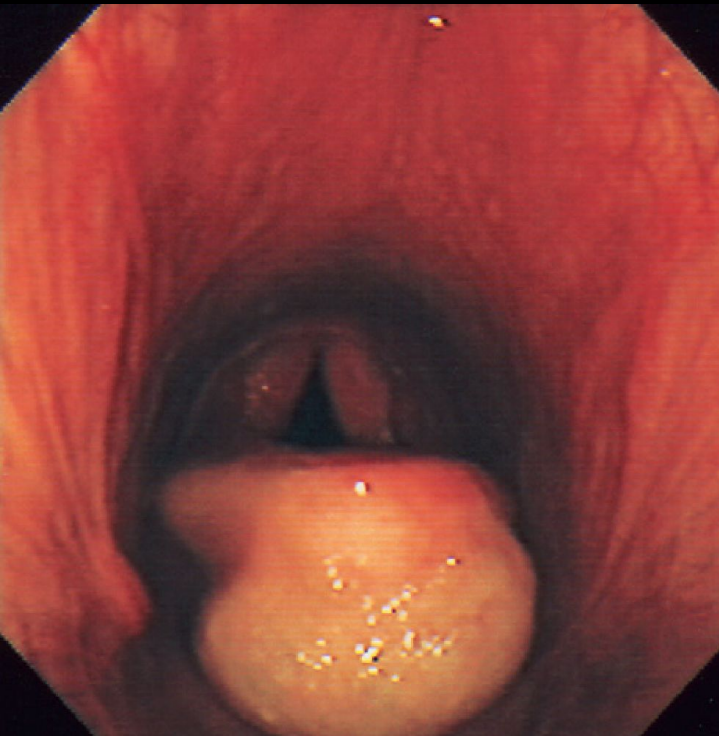
- [Redacted]

- [Redacted]

- [Redacted]

- [Redacted]

Laryngeal cysts



do prezentacji użyto zdjęć z Atlas of Equine
Endoscopy N.M.Slovis wyd Mosby

[Redacted]

[Redacted]

- [Redacted]

- [Redacted]

- [Redacted]

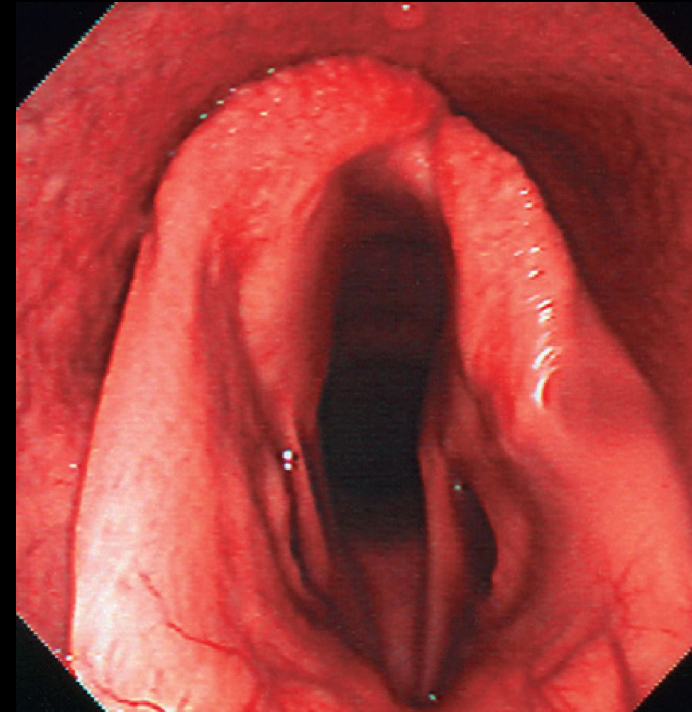
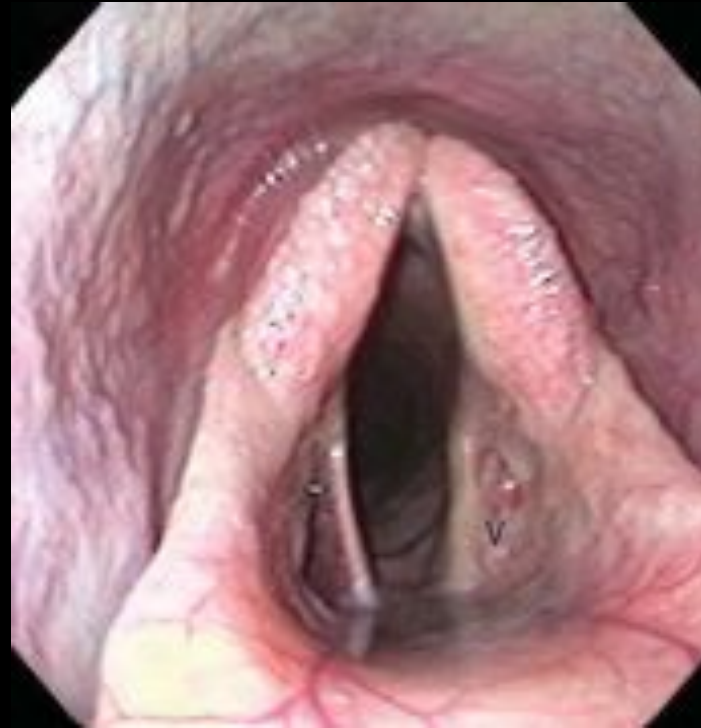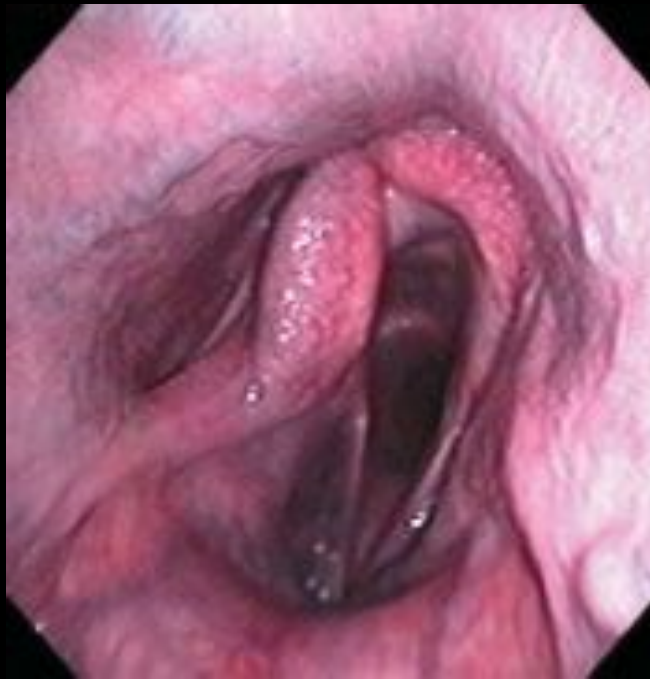- [Redacted]

- [Redacted]

- [Redacted]

- [Redacted]

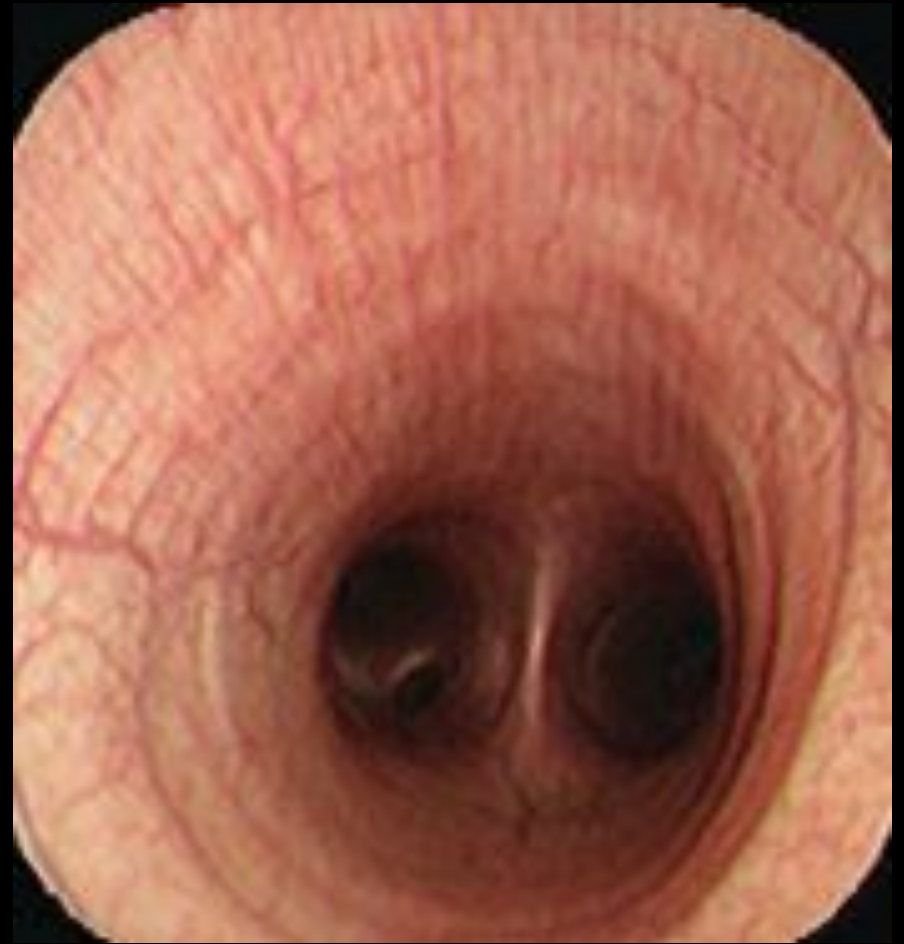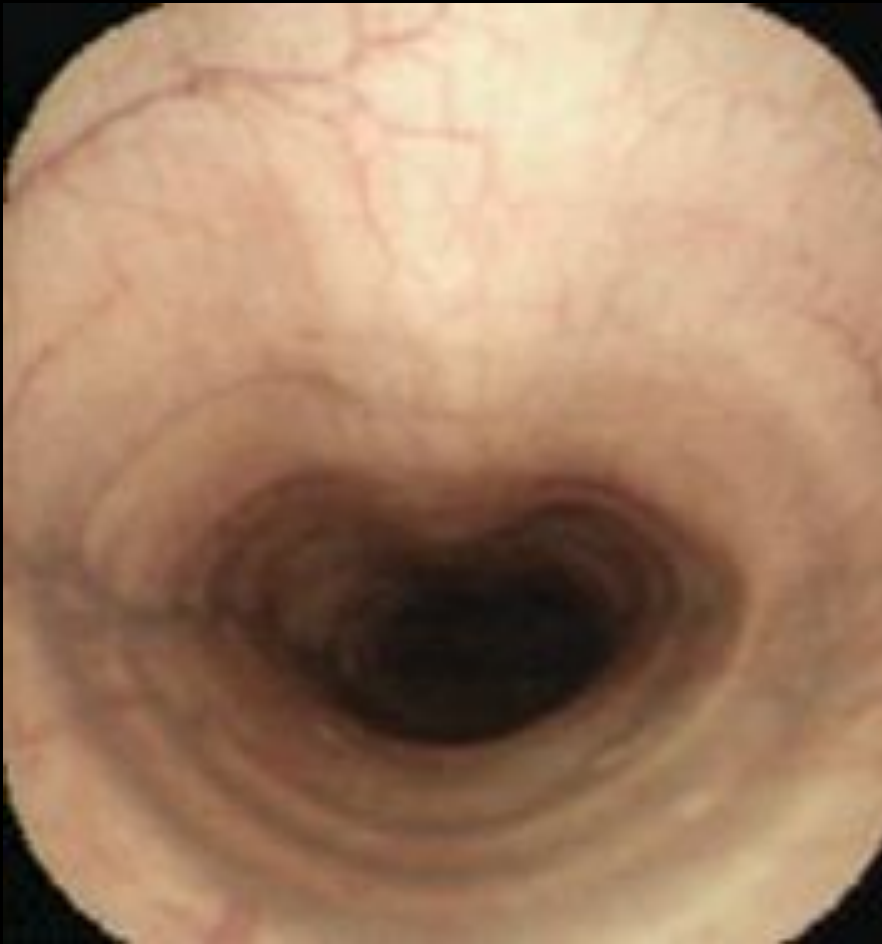
Laryngeal hemiplegia



do prezentacji użyto zdjęć z Atlas of Equine
Endoscopy N.M.Slovis wyd Mosby

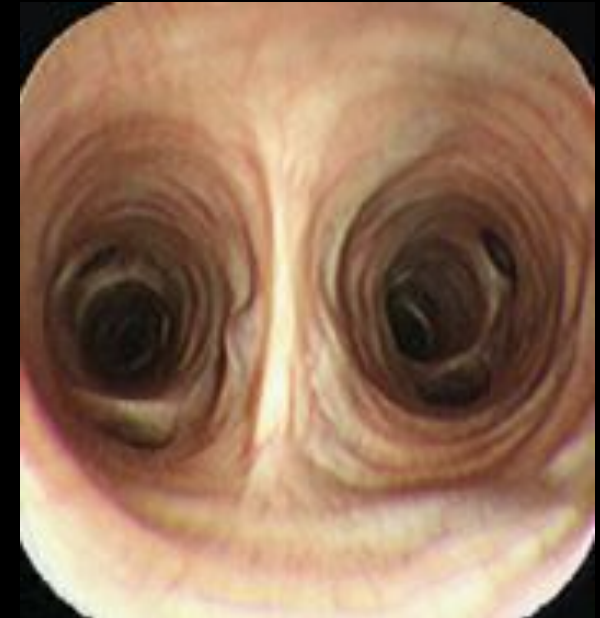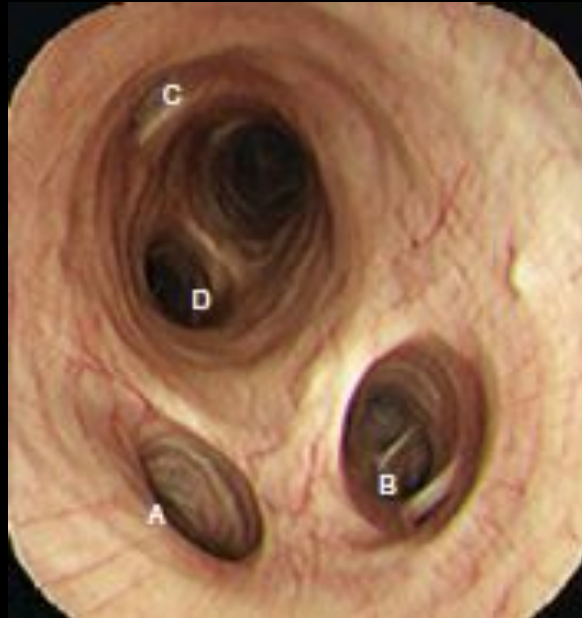
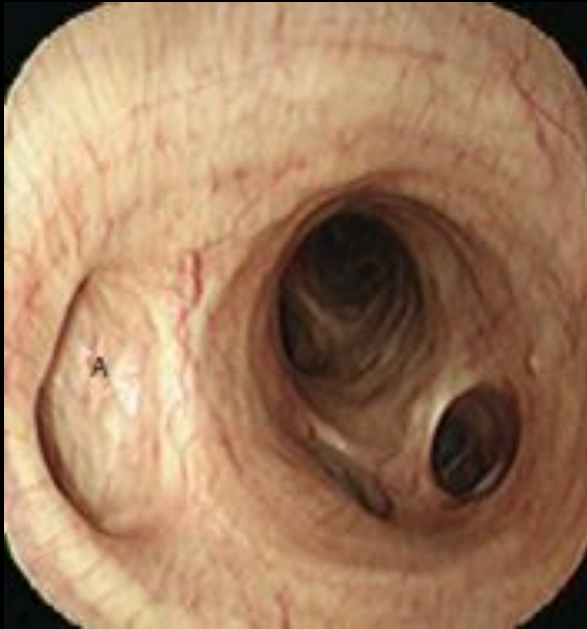Trachea

Bifurcation of the
trachea

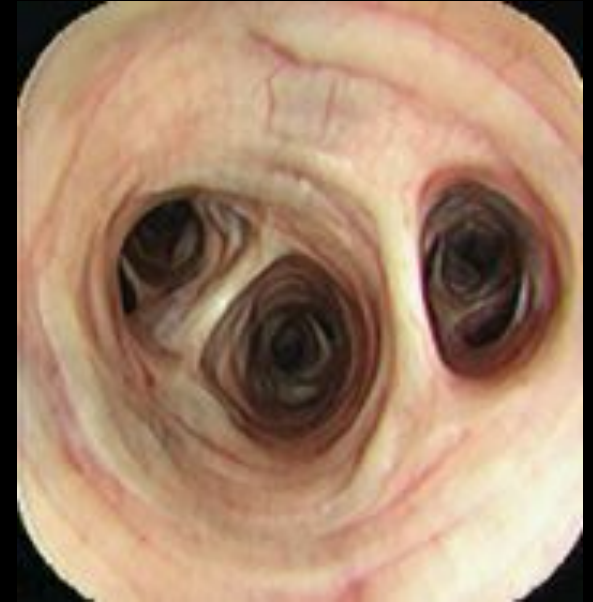
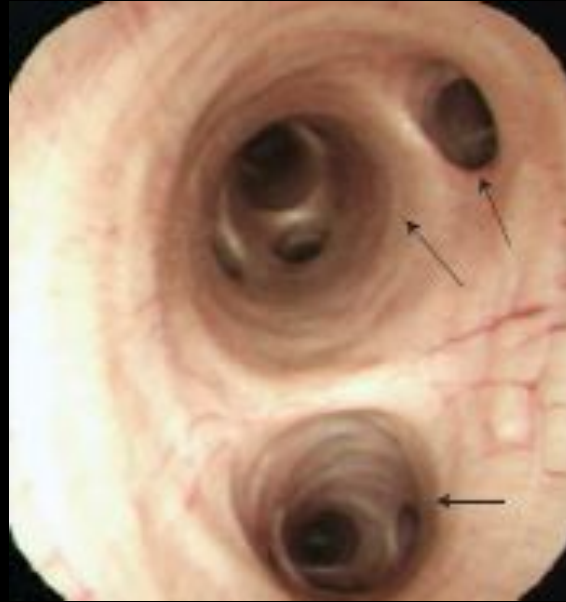
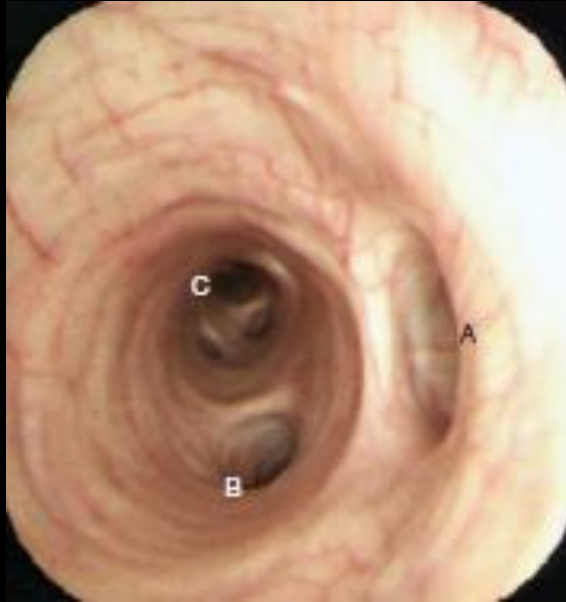do prezentacji użyto zdjęć z Atlas of Equine
Endoscopy N.M.Slovis wyd Mosby

Right bronchus



Left bronchus



[Redacted]

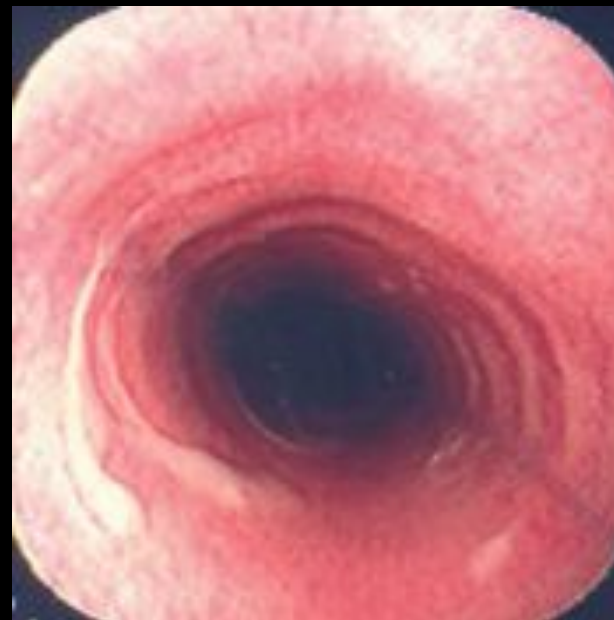
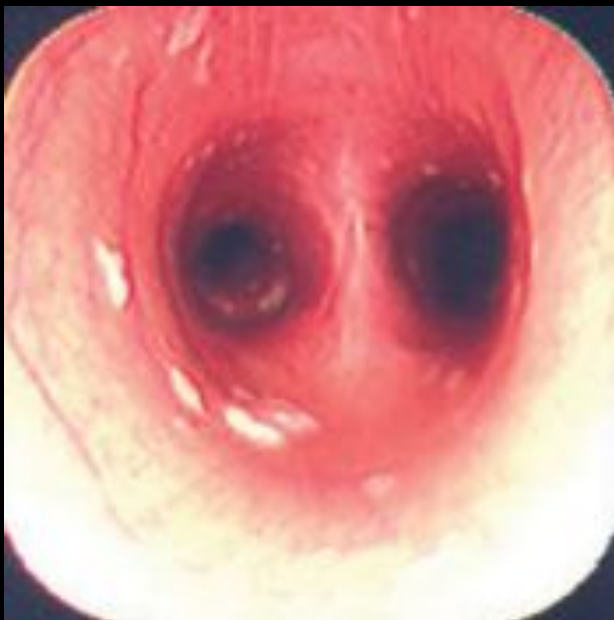[Redacted]

- [Redacted]

[Redacted]

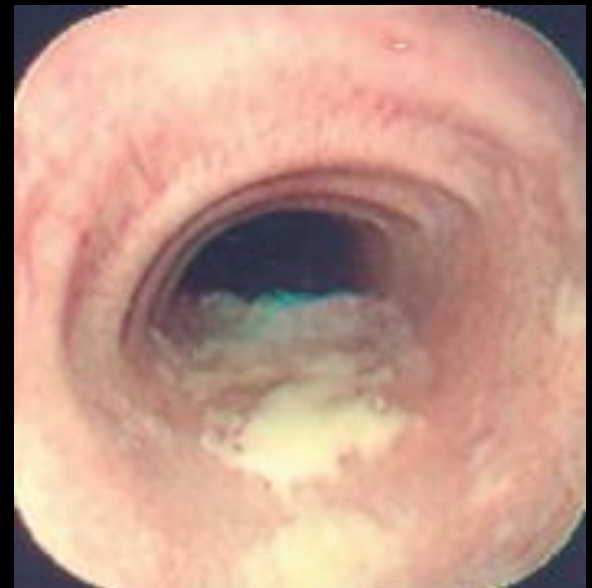
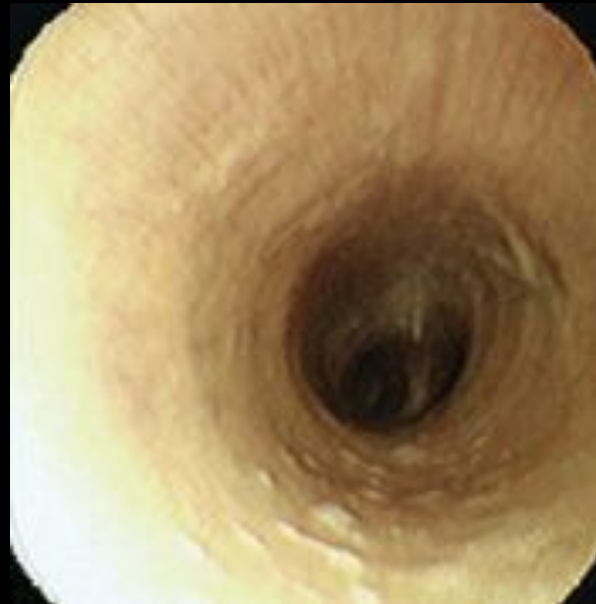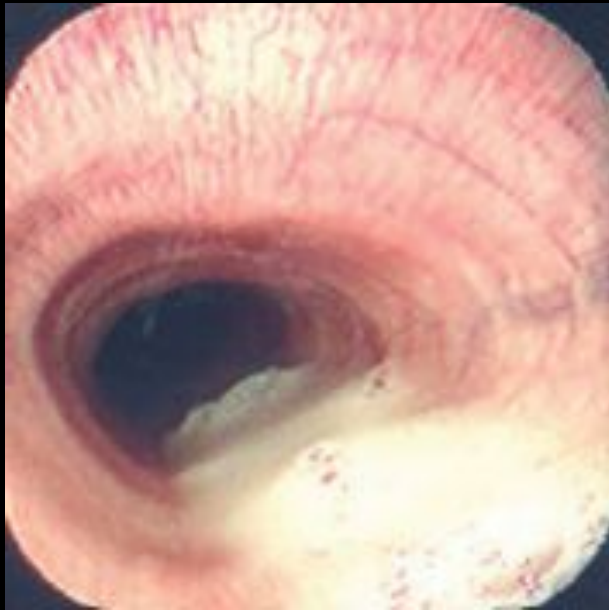- [Redacted]

Tracheitis



do prezentacji użyto zdjęć z Atlas of Equine
Endoscopy N.M.Slovis wyd Mosby

Exudates in tracheitis



do prezentacji użyto zdjęć z Atlas of Equine
Endoscopy N.M.Slovis wyd Mosby

[Redacted]

[Redacted]

- [Redacted]

- [Redacted]

- [Redacted]

- [Redacted]

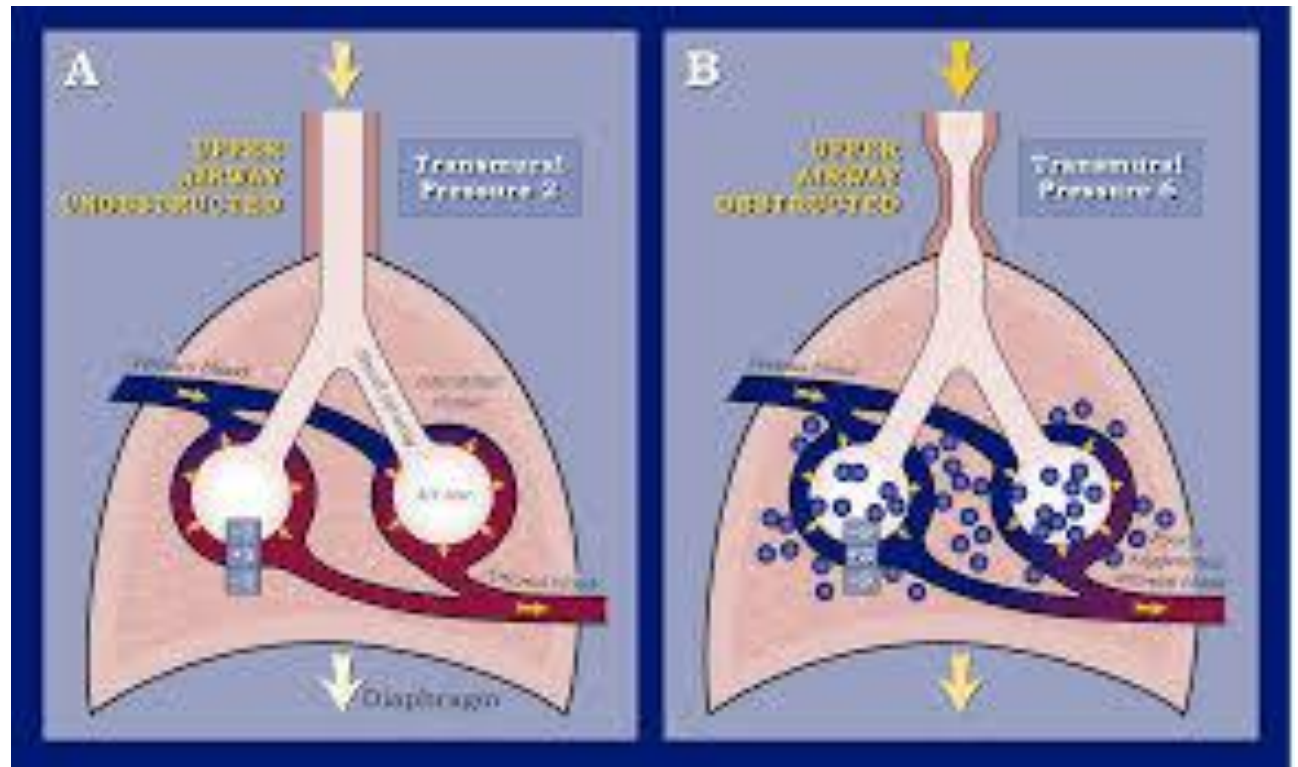
- [Redacted]

- [Redacted]

[Redacted]

- [Redacted]

- [Redacted]



- [Redacted]
- [Redacted]
- [Redacted]
- [Redacted]

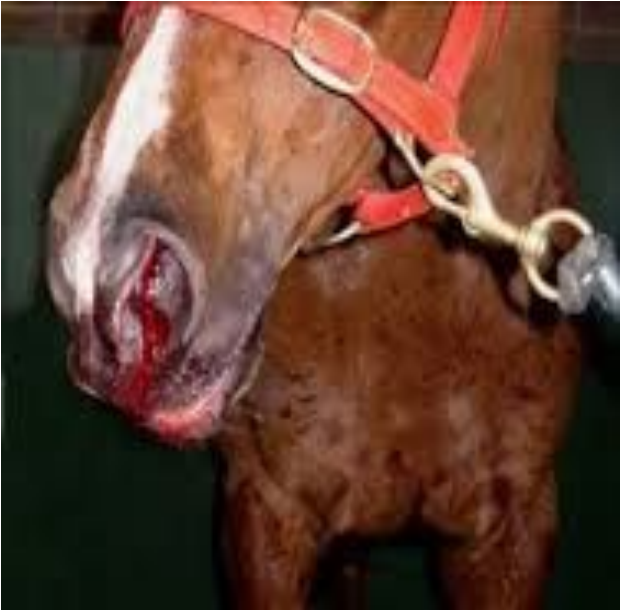[Redacted text block]

- [Redacted text]

- [Redacted text]

- [Redacted text]

- [Redacted text]



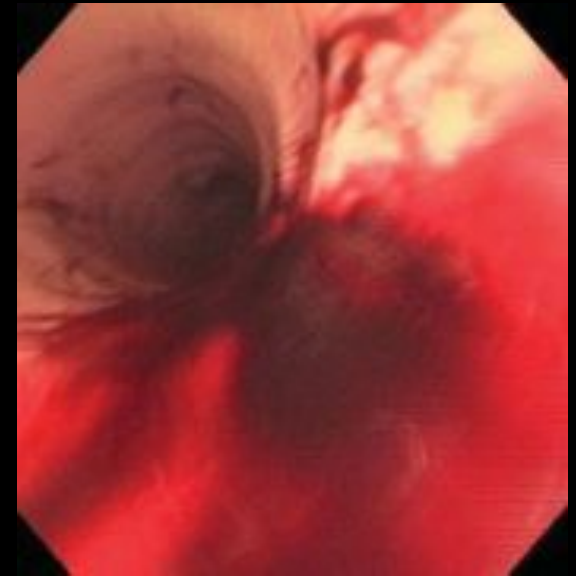
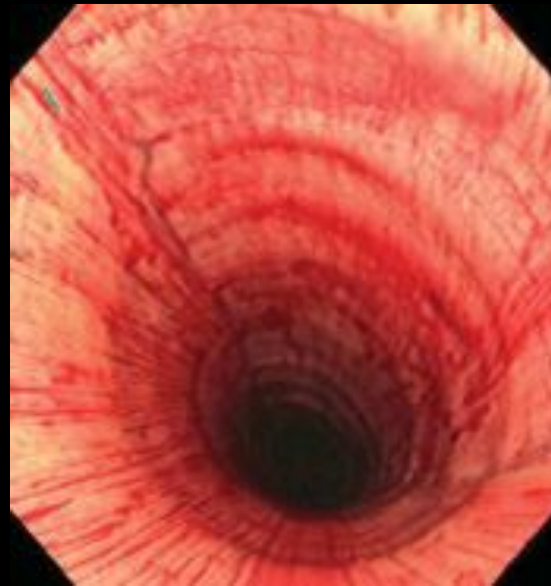
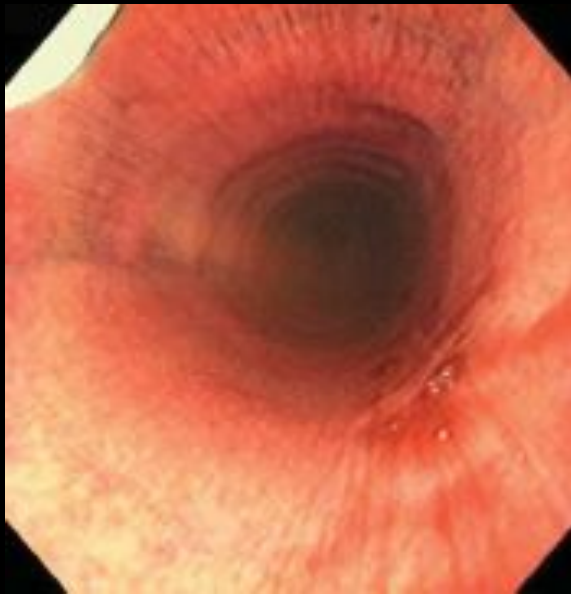
- [Redacted text]

- [Redacted text]

- [Redacted text]

Exercise induced pulmonary hemorrhage



do prezentacji użyto zdjęć z Atlas of Equine
Endoscopy N.M.Slovis wyd Mosby

[Redacted]

[Redacted]

[Redacted]

•

[Redacted]

•

[Redacted]

•

[Redacted]

•

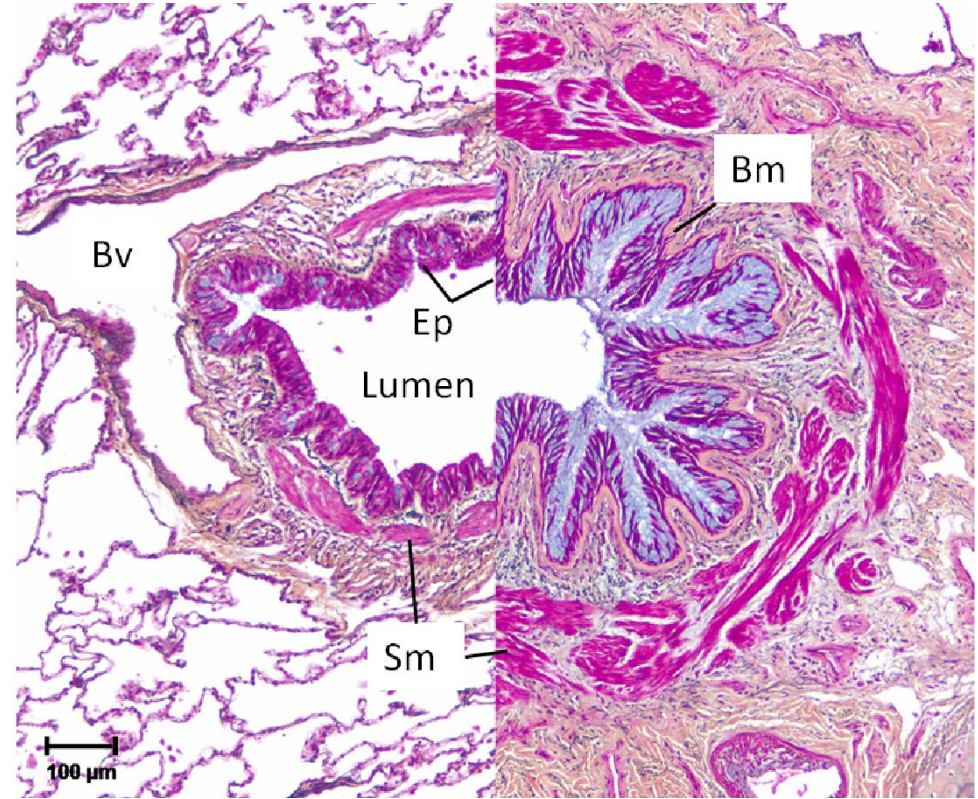
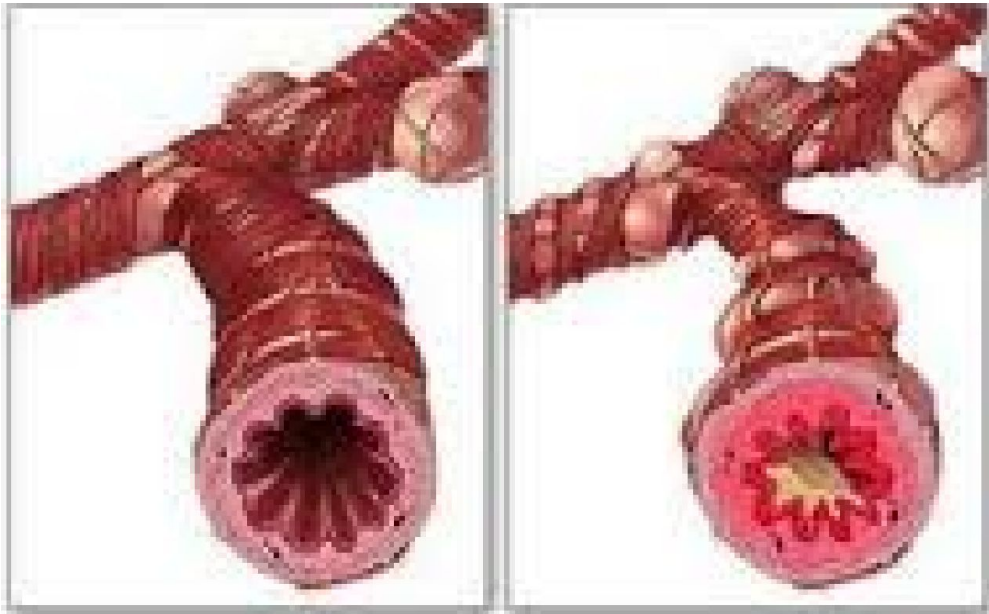[REDACTED]

[REDACTED]

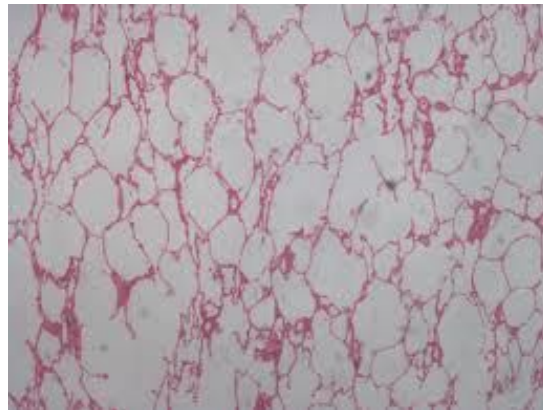
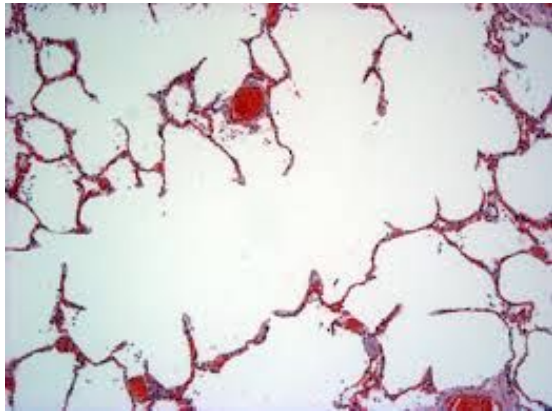- [REDACTED]

- [REDACTED]

- [REDACTED]



- Lungs emphysema



[Redacted]

[Redacted]

[Redacted]

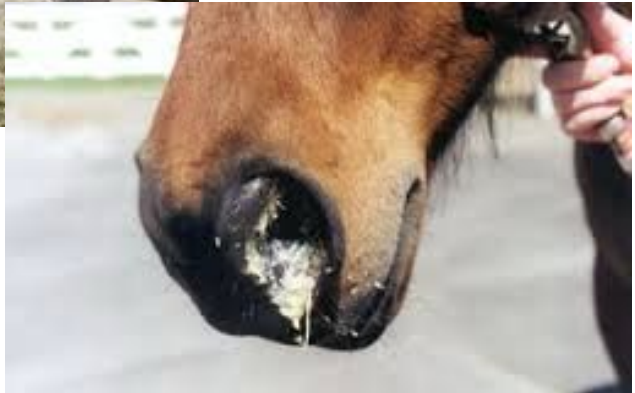- [Redacted]

- [Redacted]

- [Redacted]

- [Redacted]

- [Redacted]



[Redacted]

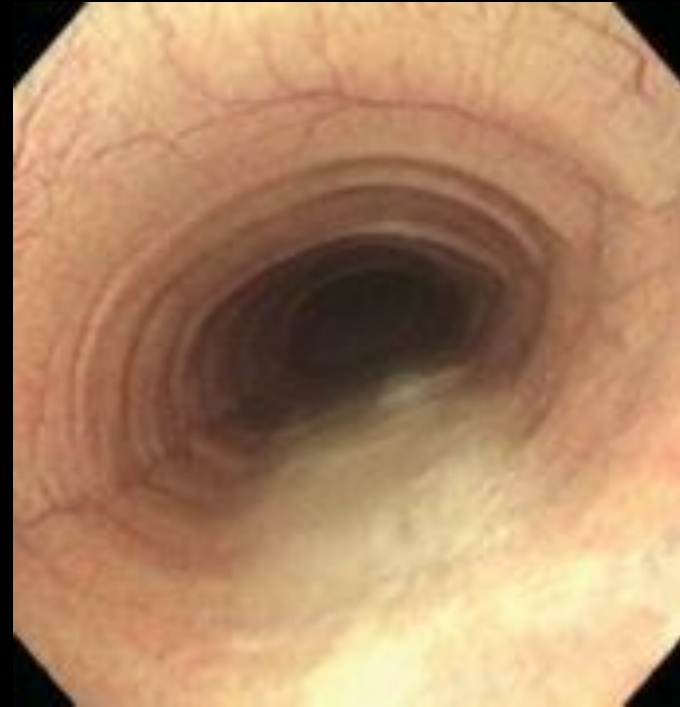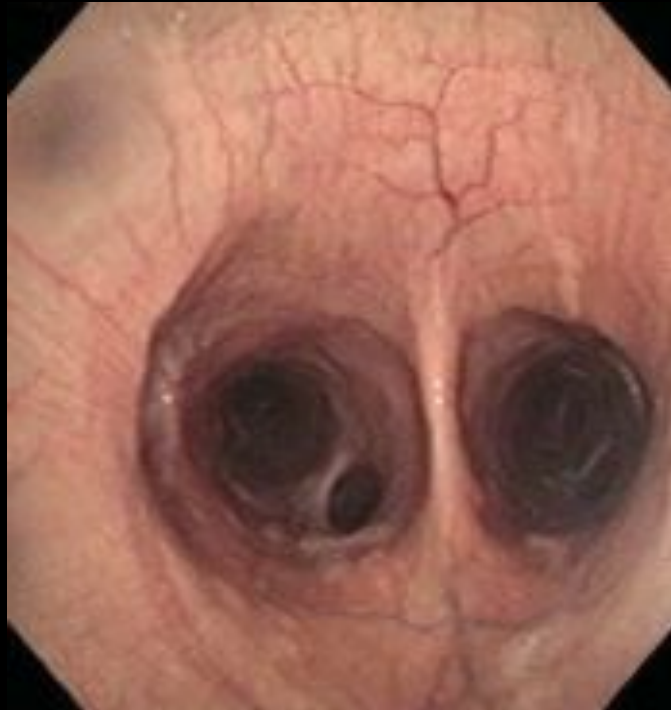[Redacted]

- [Redacted]

- [Redacted]

- [Redacted]

Heaves



do prezentacji użyto zdjęć z Atlas of Equine
Endoscopy N.M.Slovis wyd Mosby

[Redacted]

[Redacted]

[Redacted]

- [Redacted]

- [Redacted]

- [Redacted]

- [Redacted]

[Redacted]

- [Redacted]

[Redacted]

[Redacted]

[Redacted]