

General Musculoskeletal Screening: Upper Extremities

Gregory Crovetti, M.D.
Sports Medicine Program
West Suburban Health Care
Trinity Orthopaedics

General Approach

- History
- Inspection
- Range of Motion (ROM)
- Palpation
- Muscular and neurological exams

History

- An accurate history is essential
- Will give you diagnosis 80-90% of time
- How symptoms started (mechanism of injury)?
- Duration of complaint?
- Location, nature of pain, or symptoms?
- Exacerbating or relieving maneuvers?

General Inspection

- Observe how the patient moves as they go into the room or move from chair to table
- General appearance
- Body proportions

Inspection of Specific Area

- Look for asymmetry between sides
- Swelling
- Deformities
- Atrophy
- Erythema

Range of Motion (Active)

- Have patient range the joints
- Watch for decreased or increased movement of the joint compared to the other side as well as the norm
- Watch for pain with movement
- Listen for crepitus or “popping”
- Watch for abnormal movements

Range of Motion (Passive)

- Next range the joints passively, comparing the end points to the active
- Again note any decreased or increased movement
- Pain with the movement
- Crepitus or “popping”

Palpation

- When palpating a structure, you need to know the anatomy of that structure
- Palpate for swelling
- Palpate for warmth
- Palpate each area of the structure in turn evaluating for pain, and abnormalities as compared to the other side

Muscular and Neurological

- Check the following comparing one side to the other:
 - Grade strength (0-5)
 - Grade reflexes (0-4)
 - Sensory exam

Generalized Screening Exam

- Each joint is:
 - Inspected (look for abnormalities)
 - Palpated
 - Examined
- If any abnormalities, a more thorough exam of the joint needs to be done.

Neck: Active Range of Motion

- Chin to chest (flexion)
- “look at ceiling” (extension)
- Chin to each shoulder (lateral rotation)
- Ear to each shoulder (lateral flexion, i.e., head tilt)

Special Tests for the Neck

- Dekleyn test: head and neck rotation with extension. Tests for vertebral artery compression.
- Spurlin's: (foraminal compression test): patient extends rotates head to side, the examiner then applies axial load to the head. Positive test is when there is pain radiating into arm. Indicates Pressure on a nerve root.
- Elvey test: (upper limb tension tests): tests designed to put stress on the neurological structures of the upper limb.
 - A. Median nerve C5,6,7
 - B. Median nerve, axillary nerve
 - C. Radial nerve
 - D. Ulnar nerve C8, T1

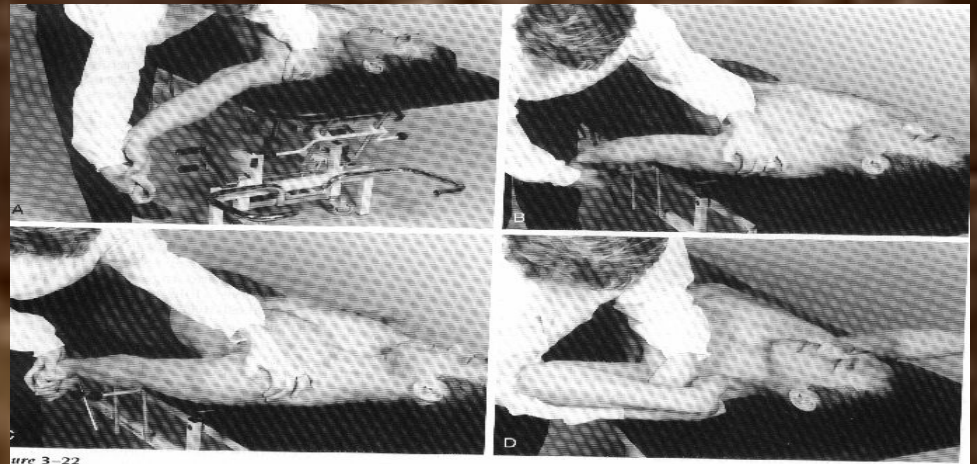


Figure 3-22

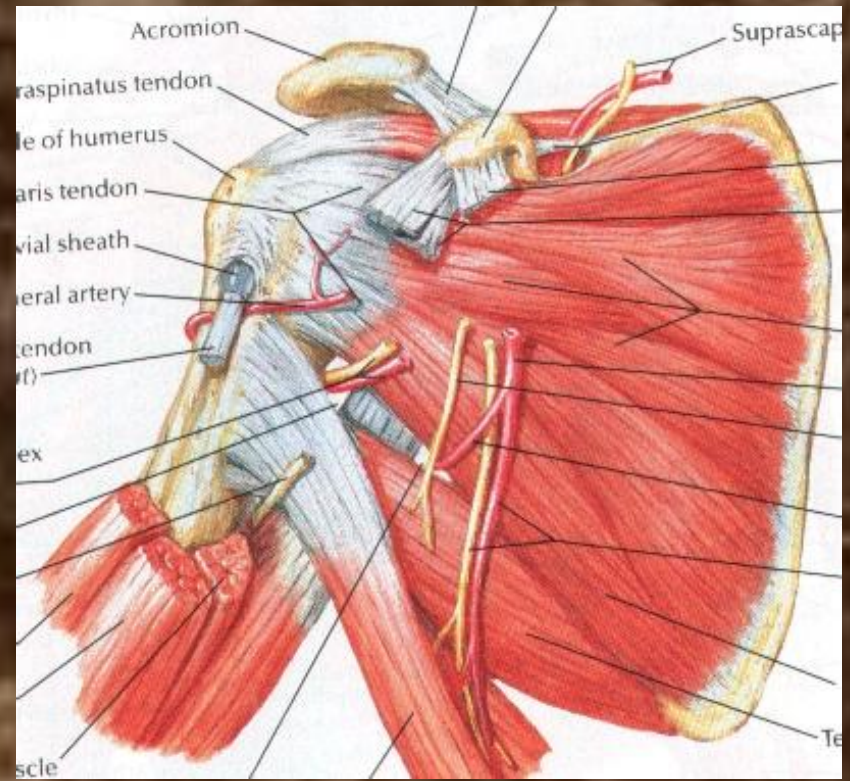
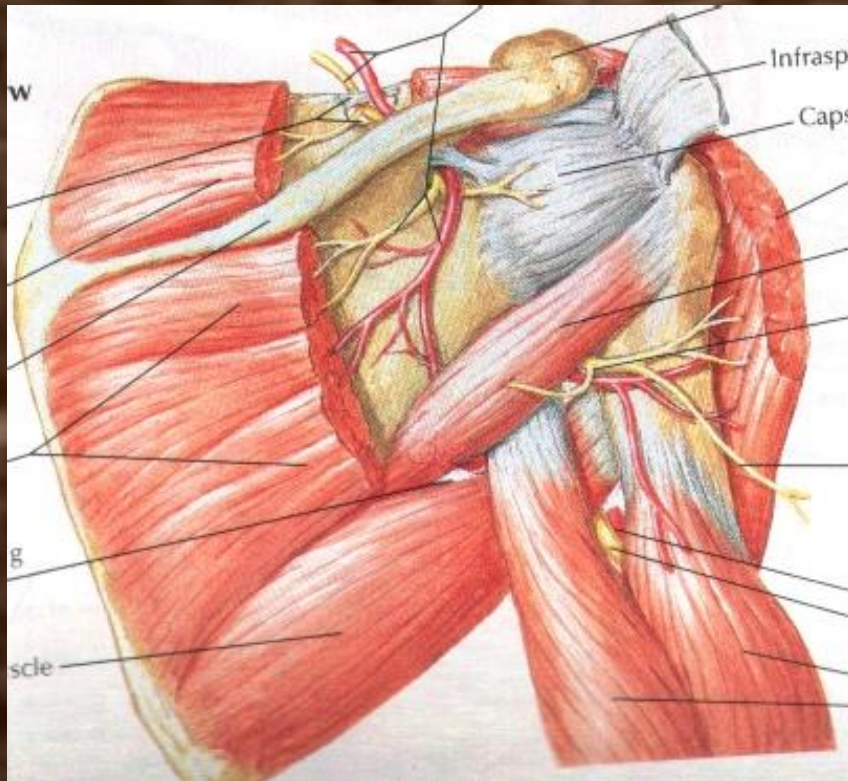
Shoulder Exam

- Inspection
- Palpation
- Passive Range of Motion
- Active Range of Motion
 - Appley scratch test for internal/external rotation
- Impingement Signs
- Bicep Tendinitis/Crossarm adduction/apprehension
- Neck exam: compression test
- Adson's manuever

The Shoulder

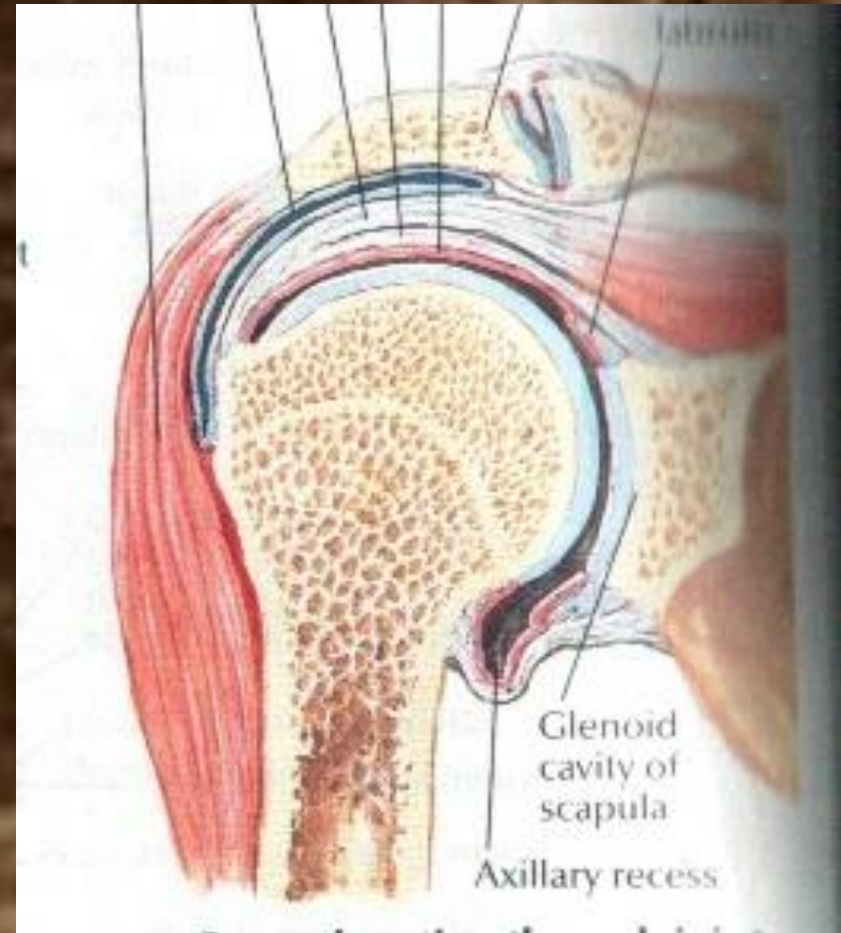
- Joints of the shoulder
 - Glenohumeral
 - Sternoclavicular
 - Acromioclavicular
 - Scapular thoracic (not a true joint)

Glenohumeral Joint



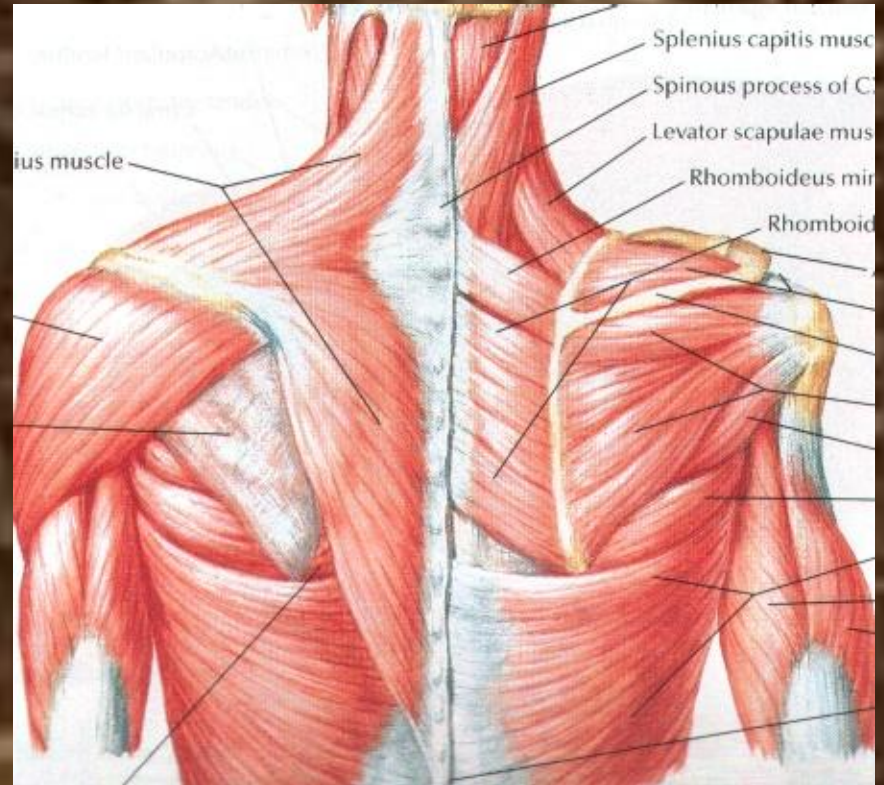
Glenoid Labrum

- Glenoid labrum: a fibrocartilaginous rim to increase the contact area and depth of the glenoid
- Triangular on cross-section and three sides which face the humeral head, joint capsule, and glenoid surface respectively
- An intact labrum increases humeral contact area by 75% in vertical and 56% in transverse directions



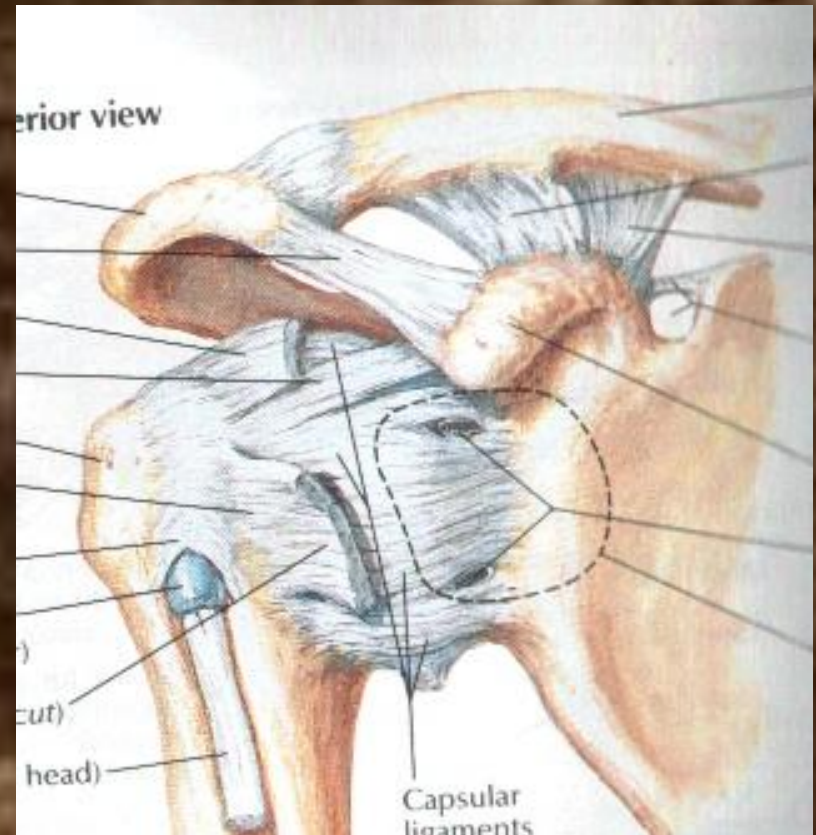
Scapulothoracic

- Scapular stabilizing muscles:
 - Trapezius (all three portions)
 - Serratus anterior
 - Rhomboids
 - Levator scapulae
 - Pectoralis Minor



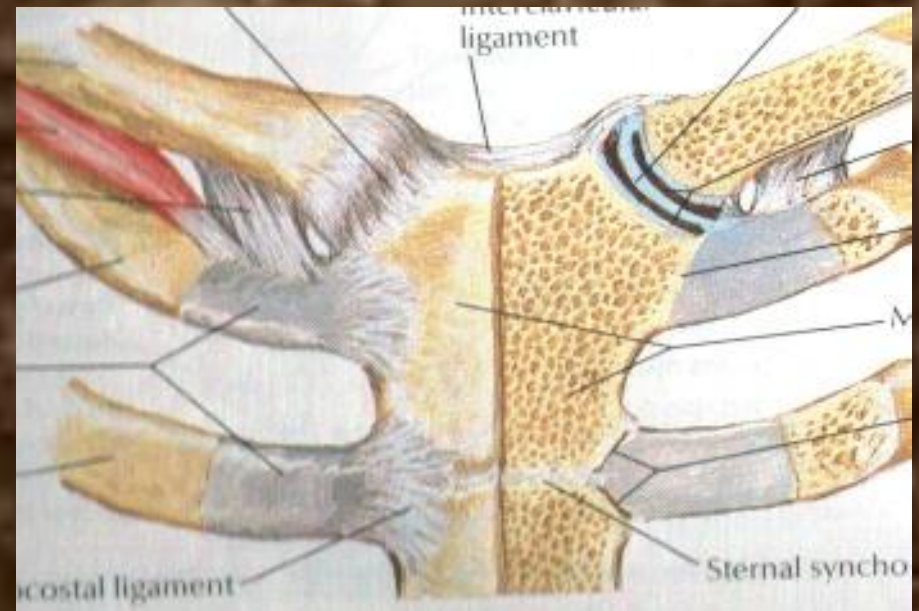
Acromioclavicular Joint

- **Acromioclavicular ligament:** resists axial rotation and posterior translation
- **Trapezoid:** is anterolateral, resists axial compression of the distal end of the clavicle
- **Conoid:** is posteromedial, resists anterior and superior translation



Sternoclavicular Joint

- These structures still allow for 35 degrees of elevation, 35 degrees of translation, and 50 degrees of rotation at the sternoclavicular joint



Shoulder

- Palpation of the shoulder includes:
 - Sternoclavicular joint
 - Acromioclavicular joint
 - Subacromial area
 - Bicipital groove
 - Muscles of the Scapula
- Have patient place each hand:
 1. Behind head (external rotation and abduction)
 2. Up the small of the back (internal rotation)

Shoulder

- Rotator cuff:
 - Supraspinatus
 - Infraspinatus
 - Teres Minor
 - Subscapularis

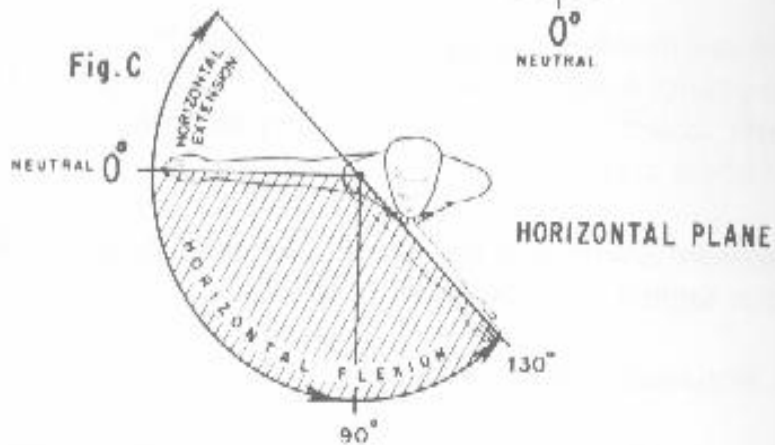
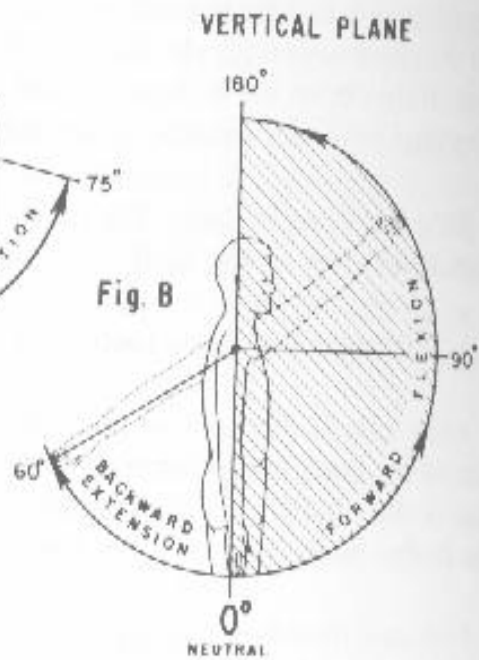
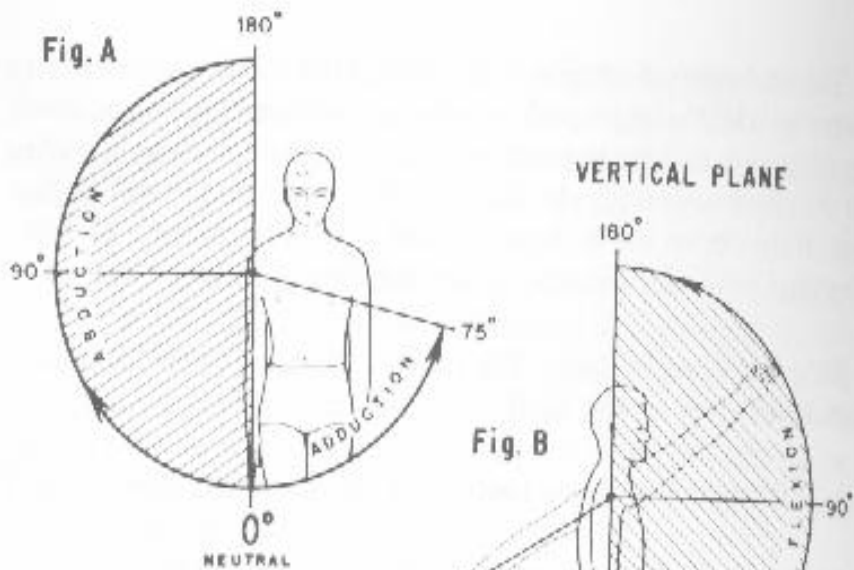


Fig. 103 Shoulder motions

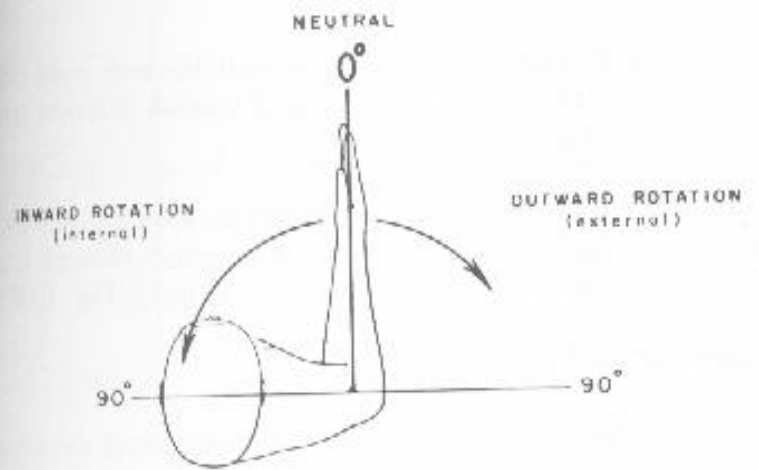


Fig. A ROTATION WITH ARM AT SIDE

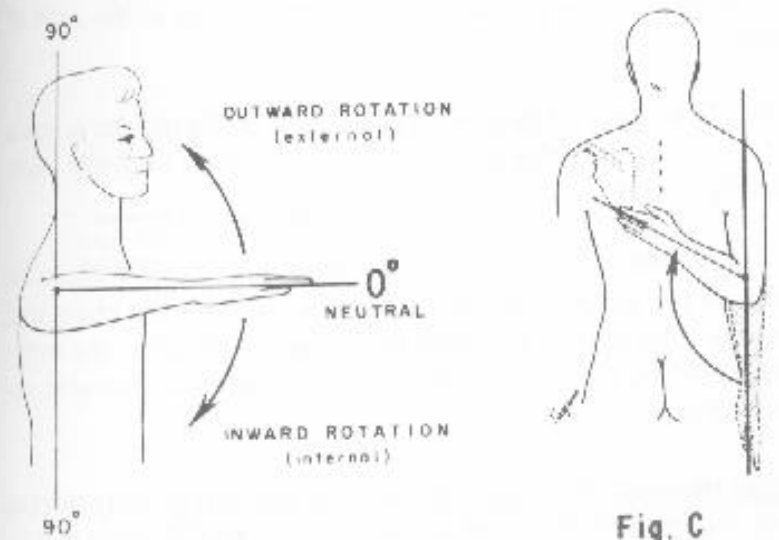


Fig. B ROTATION IN ABDUCTION

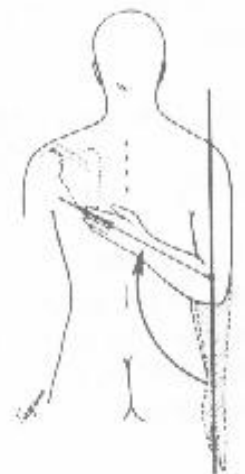


Fig. C INTERNAL ROTATION POSTERIORLY

Special Tests for the Shoulder

- Apprehension (crank) test: The arm is abducted to 90 degrees and laterally rotated. Positive test is when the patient has feeling as if the shoulder may "come out."
- Jobe relocation test: A posterior stress placed to the shoulder in the above position will cause relief of pain and apprehension if positive.
- Rockwood test for anterior instability: Similar positioning as the crank test, but the shoulder is laterally rotated at 0, 45, 90, and 120 degrees.
- Rowe test for anterior instability: Patient supine with hand behind head. Examiners clenched fist placed behind the humeral head and a downward force is applied to the arm.
- Fulcrum test: Patient supine arm abducted to 90 degrees, examiners hand under the glenoid and the arm is laterally rotated.
- Anterior and posterior drawer: 0-25% translation (normal), 25-50% (Grade I), >50% but spontaneously reduces (Grade II), >50% remains dislocated (Grade III)

Special Tests for the Shoulder

- Feagin test: arm abducted to 90 elbow straight arm on examiner's shoulder, adduction and forward pressure is applied. Positive if apprehension and presence of anteroinferior instability.
- Clunk test: Patient supine, examiner hand on the posterior aspect of the shoulder, other hand hold the humerus above the elbow and abducts the arm over the head. Then pushing anteriorly with the hand under the shoulder and rotating the humerus laterally with the other hand, feel for a grind or clunk which may indicate a tear of the labrum.
- Compression rotation test: Patient supine, elbow flexed and abducted 20 degrees, the examiner pushes up on the elbow and rotates the humerus medially and laterally. Snapping or catching is positive for labral tear.
- Scapular thoracic glide tests: To determine the stability of the scapula during glenohumeral movements.
- Speed's test: forearm supinated, elbow extended and resistance to forward flexion of the shoulder. Positive if tenderness in the bicipital groove indicating bicipital tendinitis.

Special Tests for the Shoulder

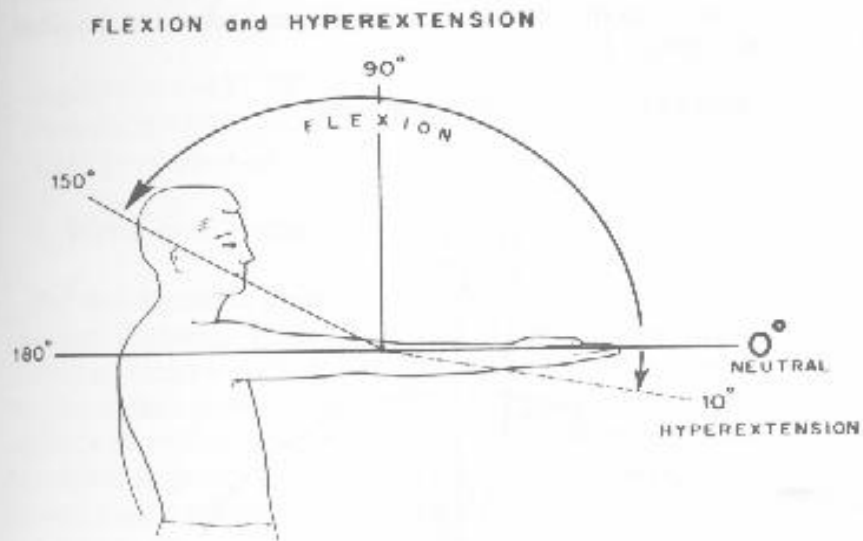
- Yergason's test: Elbow flexed to 90 degrees, forearm pronated, resistance to supination is applied as the patient also laterally rotates the arm. Positive if pain in the bicipital groove and indicates bicipital tendinitis.
- Supraspinatus (empty can/ Jobes) test: The shoulder is forward flexed at 30 degrees, arms straight and thumbs pointing to ground, a downward force is applied to the arms. Tests for tear or weakness of the supraspinatus.
- Codman's (drop arm) test: shoulder is abducted to 90 degrees and patient asked to lower the arm slowly. If drops or is painful, it is positive and indicates tear in the rotator cuff.
- Neer impingement test: Arm is elevated through forward flexion, positive if painful.
- Hawkins-Kennedy impingement test: Arm is forward flexed to 90 then internally rotated, positive if painful.

Special Tests for the Shoulder

- Impingement test: Arm is abducted to 90 and full lateral rotation, positive if painful.
- Military brace (Costoclavicular Syndrome) test: Palpate the radial pulse as the shoulder is drawn down and back. Positive if a decreased pulse and indicates possible thoracic outlet syndrome.
- Adson Maneuver: radial pulse palpated as arm is rotated laterally and elbow is extended as the patient extends and rotates head to test shoulder.
- Allen test: Elbow is flexed to 90, shoulder abducted and laterally rotated and patient rotates head away for the test side.
- Halstead maneuver: Radial pulse felt as arm is pulled down as the patients neck is hyperextended and rotated to the opposite side.

The Elbow

- Palpation: lateral and medial epicondyles, olecranon, radial head, groove on either side of the olecranon
- Inspect the carrying angle, and any nodules or swelling



MEASUREMENT of LIMITED MOTION

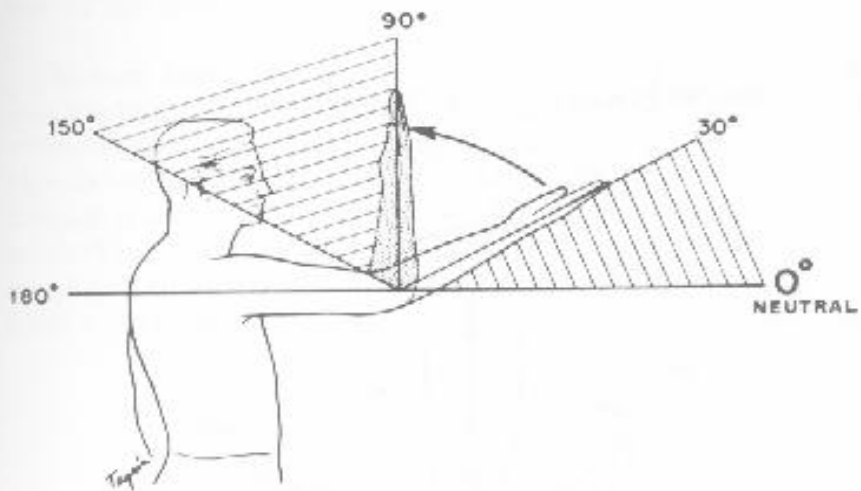
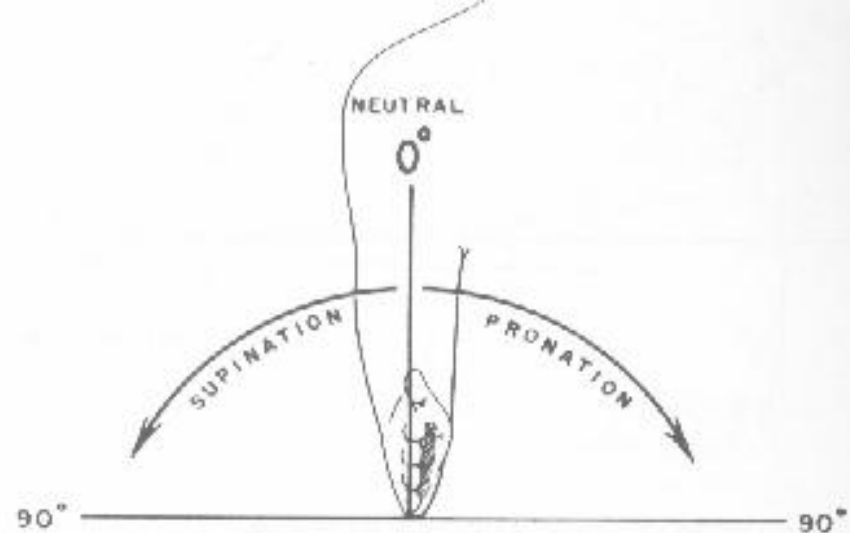


Fig. 109 Elbow motion



MEASUREMENT of LIMITED MOTION

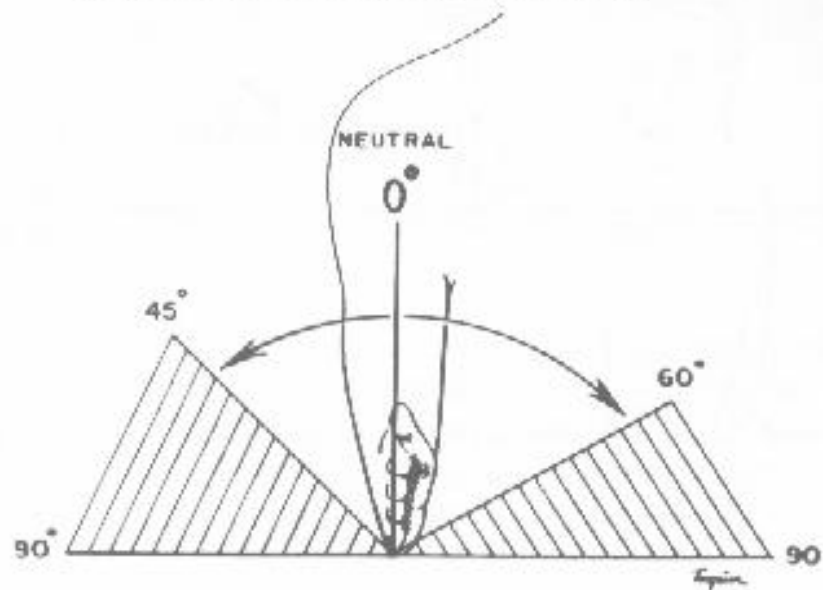


Fig. 110 Pronation and Supination

Special Tests for the Elbow

- Varus test: Tests for ligamentous stability of the lateral collateral ligament
- Valgus test: Tests the medial collateral ligament
- Cozen's test: (Lateral Epicondylitis / Tennis elbow test) Patient makes fist and pronates the forearm radially deviates and extends the wrist against resistance. Positive if pain in the lateral epicondyle area.
- Golfer's elbow test: While palpating the medial epicondyle, the forearm is supinated and the elbow and wrist are extended. Positive if pain over the medial epicondyle.
- Tinel's of the elbow: Percussion of the ulnar nerve in the groove. Positive if radiating sensation down arm into hand.

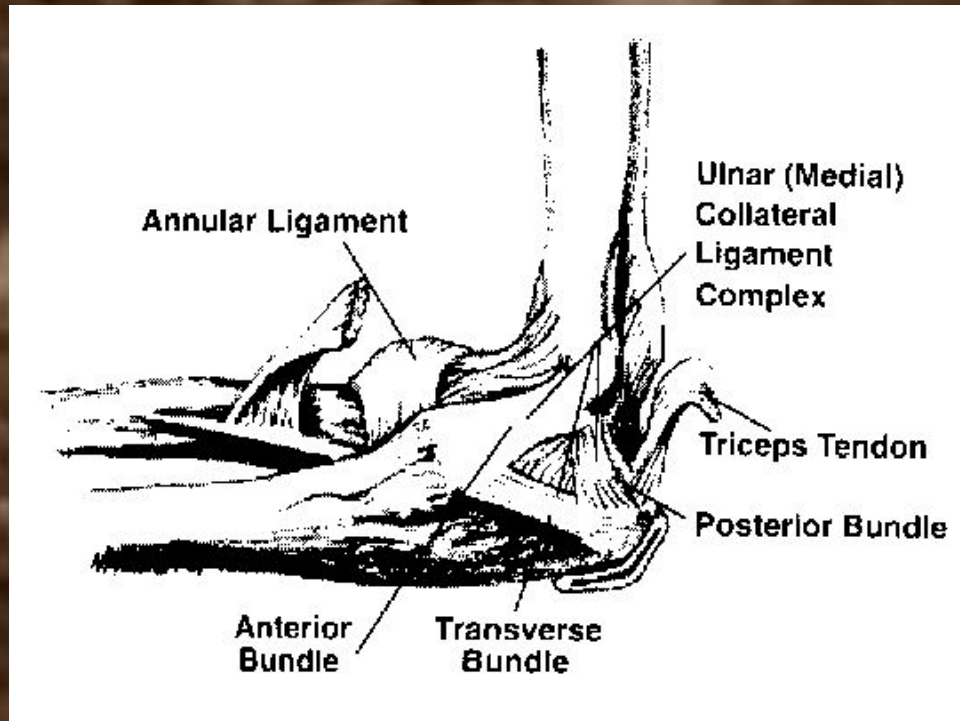
Wrist and Hand

- Inspect for swelling or deformities
- Palpate: anatomic snuff box, volar and dorsal aspects of the wrist, all joints of the fingers
- Flexion, extension, ulnar and radial deviation of the wrist
- Have patient make a fist and extend and spread the fingers.

Bones of the Wrist

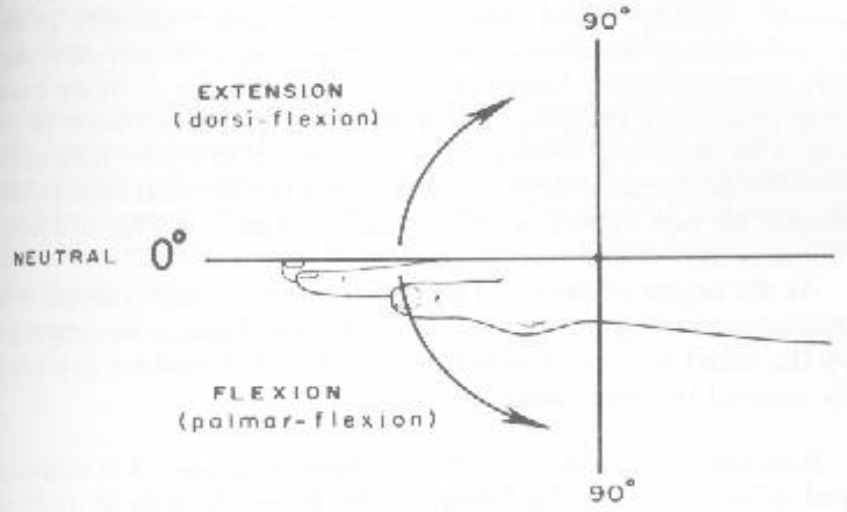
- Scaphoid
- Lunate
- Triquetrum
- Pisiform
- Trapezium
- Trapezoid
- Capitate
- Hamate

Anatomy of the Elbow



Nerves of the Hand

- Ulnar
- Radial
- Median
- Palmar branch of the median



RADIAL and ULNAR DEVIATION

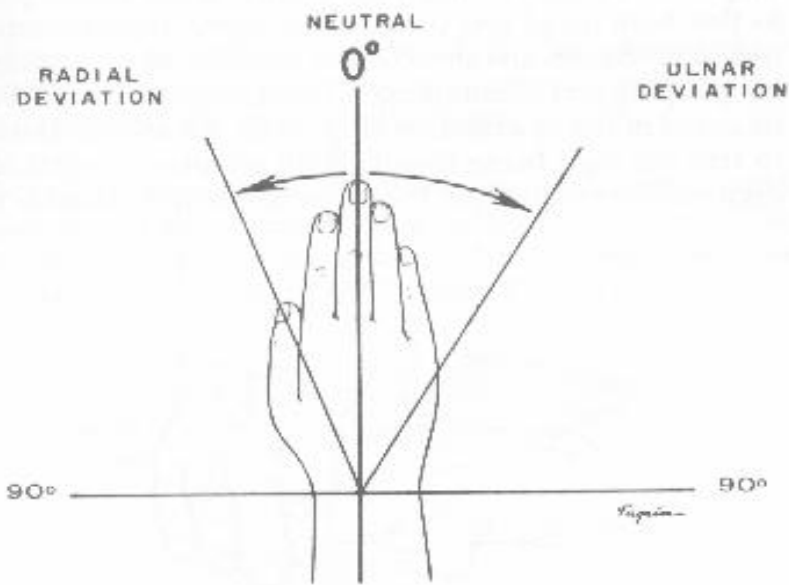


Fig. 112 Wrist motions

ZERO STARTING POSITION



ABDUCTION at right angle to the plane of the palm.



EXTENSION parallel to the plane of the palm.

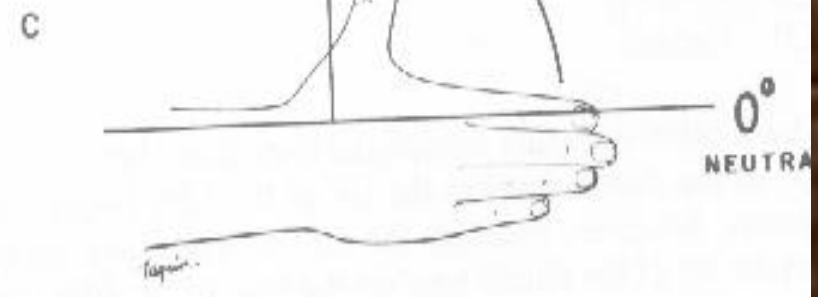


Fig. 120 Motions of the thumb

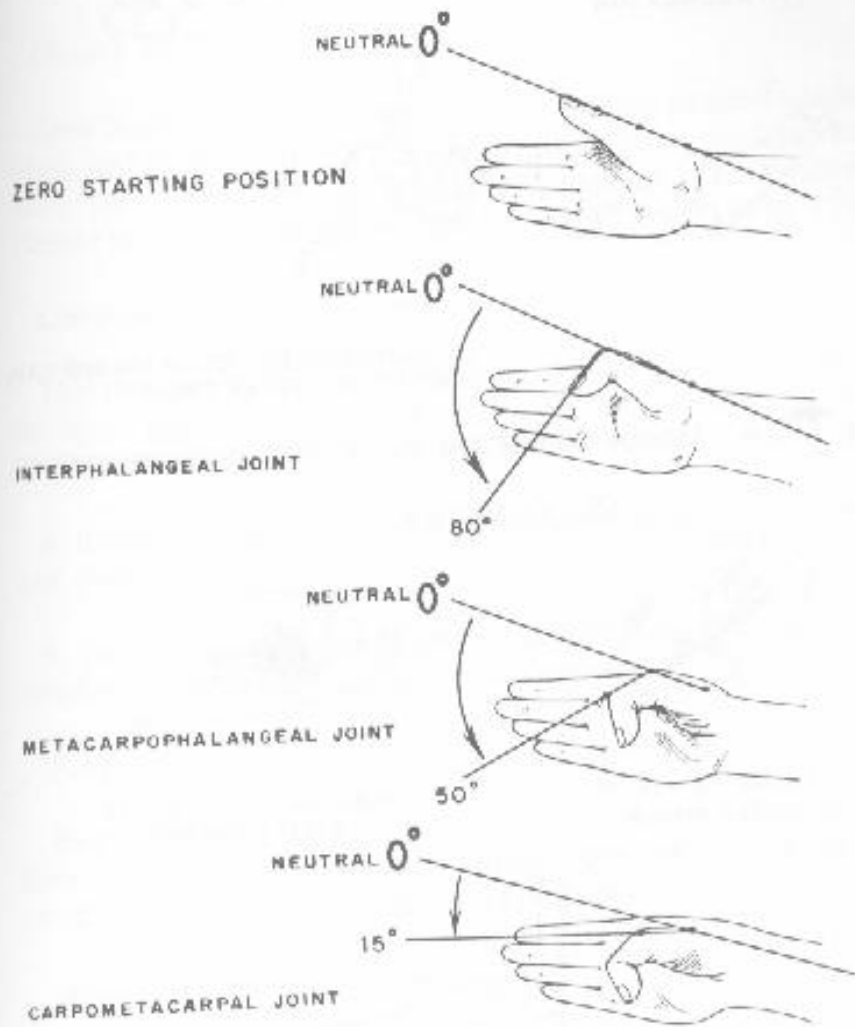


Fig 121 Flexion of the thumb

Fig. A

THE FINGERS
(FLEXION)

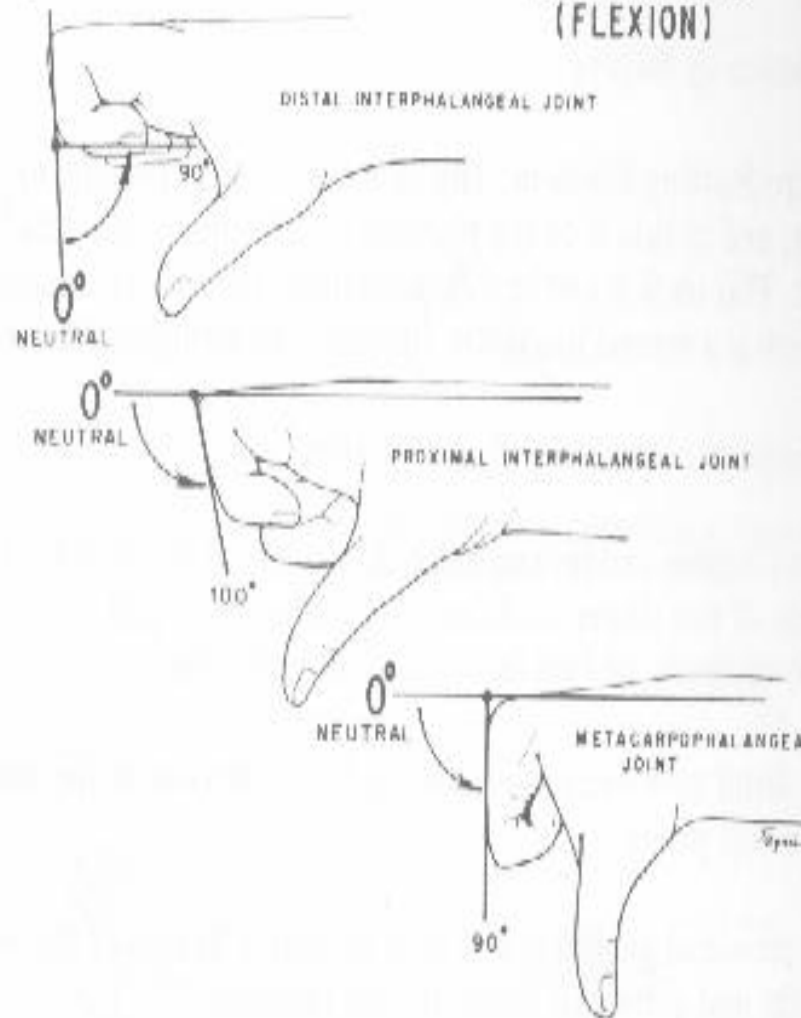


Fig. B COMPOSITE MOTION of FLEXION

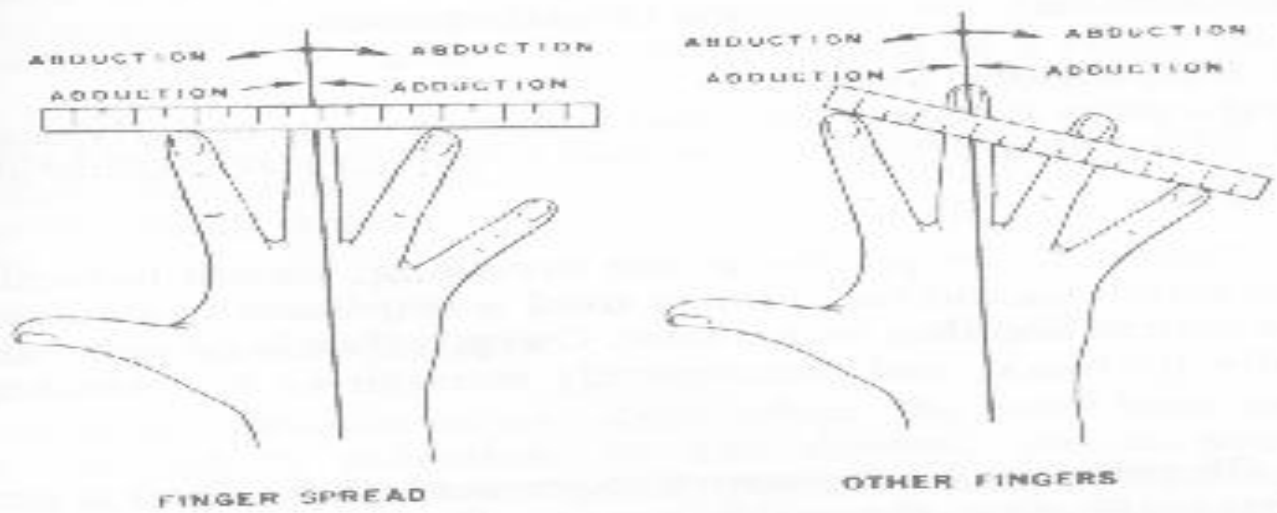
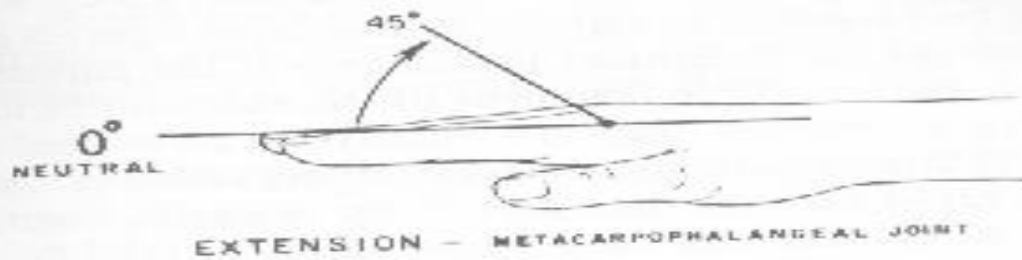


Fig. 124 Finger extension, abduction-adduction

Special Tests of Hand and Wrist

- Cascade sign: Patient flexes the fingers, the tips should all converge toward the scaphoid tubercle. If they do not, it may indicate a fracture in that finger.
- Boutonniere deformity: Extension of the MCP and DIP joints and flexion of the PIP joint. This is due to a rupture of the central tendinous slip of the extensor hood.
- Swan-neck deformity: Flexion of the MCP and DIP joints, with extension of the PIP joint. This is due to contracture of the intrinsic muscles. Seen after trauma or in RA.
- Ulnar drift: Ulnar deviation of the digits most commonly due to RA.
- Dupuytren's contracture: This is due to contracture of the palmar fascia. Most common in the ring finger or little finger, men more than women, ages 50-70.
- Claw fingers: This deformity is a form a combination of a ulnar and median nerve palsy. This causes loss of intrinsic muscle function and over action of the extrinsic extensors. This causes hyperextension of the MCP joints and flexion of the PIP and DIP joints. If the intrinsic function of the hand is lost, it is then called an intrinsic minus hand.

Special Tests of Hand and Wrist

- Trigger finger: Results from a thickening of the flexor tendon sheath, causing sticking of the tendon. At later stages the finger can become stuck in flexion, needing to be passively extended. Associated with RA.
- Bishop's Hand: (Benediction Hand) Secondary to ulnar nerve palsy. There is wasting of the hypothenar, interossei, and the two medial lumbrical muscles. Flexion of the 4th and 5th fingers is the most noticeable deformity.
- "Z" deformity of the thumb: May be secondary to RA or heredity. The thumb is flexed at the MCP and hyperextended at the IP joint.
- Drop-wrist: Secondary to radial nerve palsy.
- Mallet finger: The distal phalanx remains in flexion when the finger is extended. This is the result of rupture or avulsion of the extensor tendon from the distal phalanx.
- Clubbing: Can be caused by many medical problems such as pulmonary or cardiac diseases, as well as genetic.
- Heberden's nodes: Swelling of the DIP joints secondary to OA.
- Bouchard's nodes: Swelling of the PIP joints secondary to RA.

Special Tests of Hand and Wrist

- Ganglion cyst: Localized swelling usually on the dorsum of the hand.
- Thumb ulnar collateral ligament test: (test for gamekeeper's or skier's thumb) Valgus stress applied to the MCP joint, if 10-20 degrees there is most likely a partial tear
- Carpal Compression test: Pressure applied directly to the carpal tunnel for 30 seconds. If positive, indicates carpal tunnel syndrome.
- Froment's sign: Patient holds piece of paper between the thumb and index paper. If the distal phalanx flexes, it is a positive test and indicates ulnar nerve palsy. If the MCP joint hyperextends, it is a positive Jeanne's sign and also indicates ulnar nerve palsy.
- Allen test: Tests for competency of the ulnar and radial arteries.
- Anatomic snuffbox: Lies between the extensor pollicis longus and extensor pollicis brevis tendons. The scaphoid bone is palpated inside the box as well as the radial styloid. Pain in the box should indicate scaphoid fracture until proven otherwise.

Special Tests of Hand and Wrist

- Guyon's canal: (pisohamate) Through this canal runs the ulnar nerve. If compression of the canal occurs, there is sensation loss to the fingers and muscle weakness in the hand of ulnar distribution.
- >35 degrees indicates a torn ulnar and accessory collateral ligaments.
- Murphy's sign: Patient makes a fist, if the head of the third metacarpal is level with the second and fourth metacarpals, it is a sign of a lunate dislocation.
- Retinacular ligament test: Test for the structures around the PIP joint. The patient is passive, the PIP joint is held in extension and the DIP is flexed. If the DIP does not flex, the retinacular ligaments (collateral) or capsule is tight. The PIP joint is flexed, if the DIP now flexes easily, the retinacular ligaments are tight and the capsule is normal.
- Lunatotriquetral Ballottement (Reagan's test): The triquetrum is grasped between the thumb and second finger of one hand and the lunate between the thumb and second finger of the other hand. The lunate is then moved up and down, if any laxity, crepitus or pain it indicates a positive test for Lunatotriquetral instability.

Special Tests of Hand and Wrist

- Watson (scaphoid shift) test: The patient's hand is taken into full ulnar deviation and slight extension. With the other hand the thumb is pressed against the distal pole of the scaphoid to prevent it from moving. The patient's hand is then moved radially and slightly flexed. If the dorsal pole of the scaphoid subluxes over the dorsal rim of the radius and there is pain, it is a positive test for scaphoid and lunate instability.
- Scaphoid stress test: Modification of Watson test in which the patient actively radial deviates the wrist while scaphoid pressure is applied. If there is pain and a clunk, it is a positive test.
- "Piano Key" test: Patient's arms are in pronation. Using the index finger while stabilizing the hand with the other hand the distal ulna is pushed down. The test is positive if there is pain and difference in mobility compared to the other side. This indicates distal radioulnar joint instability.
- Axial load test: Axial load to the thumb or fingers, if pain or crepitation it is a positive test for metacarpal or adjacent carpal bone fracture or joint arthrosis.
- Grind test: Grabbing the thumb below the metacarpophalangeal joint, an axial load is applied with rotation. If there is pain the test is positive and indicates DJG of the metacarpophalangeal or metacarpotrapezial joints.

Special Tests of Hand and Wrist

- Finkelstein test: Tests for De Quervain's or Hoffmann's disease. A positive test indicates a tenosynovitis of the abductor pollicis longus and extensor pollicis brevis tendons.
- Sweater finger sign: When patient makes a fist, if one of the distal phalanx (most often the ring finger) does not flex, the test is positive. It indicates a ruptured flexor digitorum profundus tendon.
- Bunnel-Littler test: (Finochietto-Bunnel test) The patient is passive during the test. The test is for structures around the MCP joint. The MCP joint is held in extension, while the PIP is flexed. If unable to flex the PIP, the test is positive and indicates tight intrinsic muscle or contracture of the joint capsule. The MCP is then slightly flexed, if the PIP now flexes easily it indicates tight intrinsic muscles and that the capsule is normal. If the PIP still does not flex it indicates a tight joint capsule.
- Tinel's sign: Positive if tingling into the fingers of the median nerve distribution, indicating carpal tunnel syndrome.
- Phalen's test: Position must be held for one minute. If positive indicates carpal tunnel syndrome. The dorsal aspect of the hands is pushed together to maximal flexion of the wrists.

Case

- 75-year old man comes in for yearly physical.
- History of hypertension, elevated lipids, and mild obesity
- He has taken your advise and started an exercise program, and now has a complaint of right shoulder pain.
- What do you want to know?
- What do you do next?