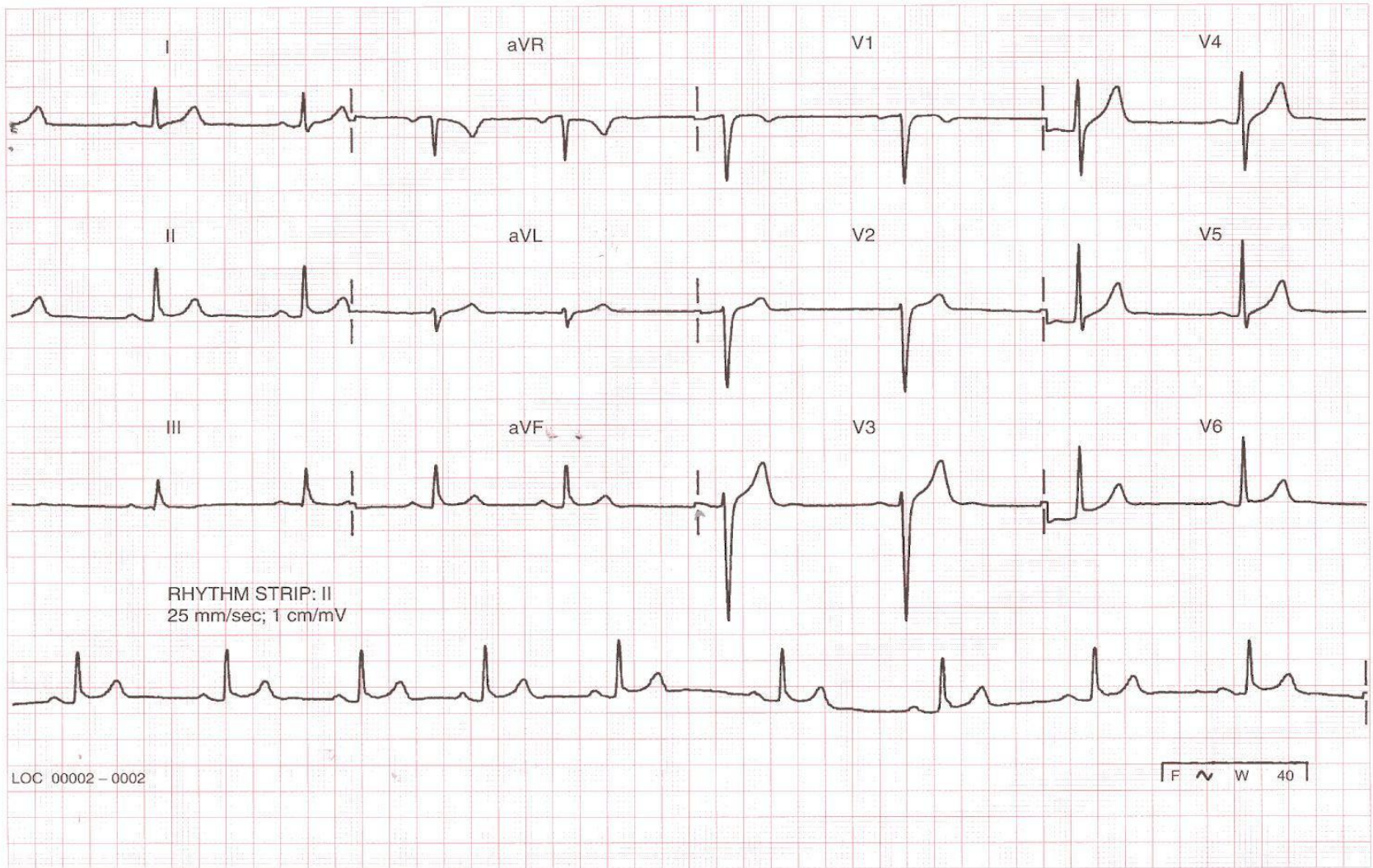
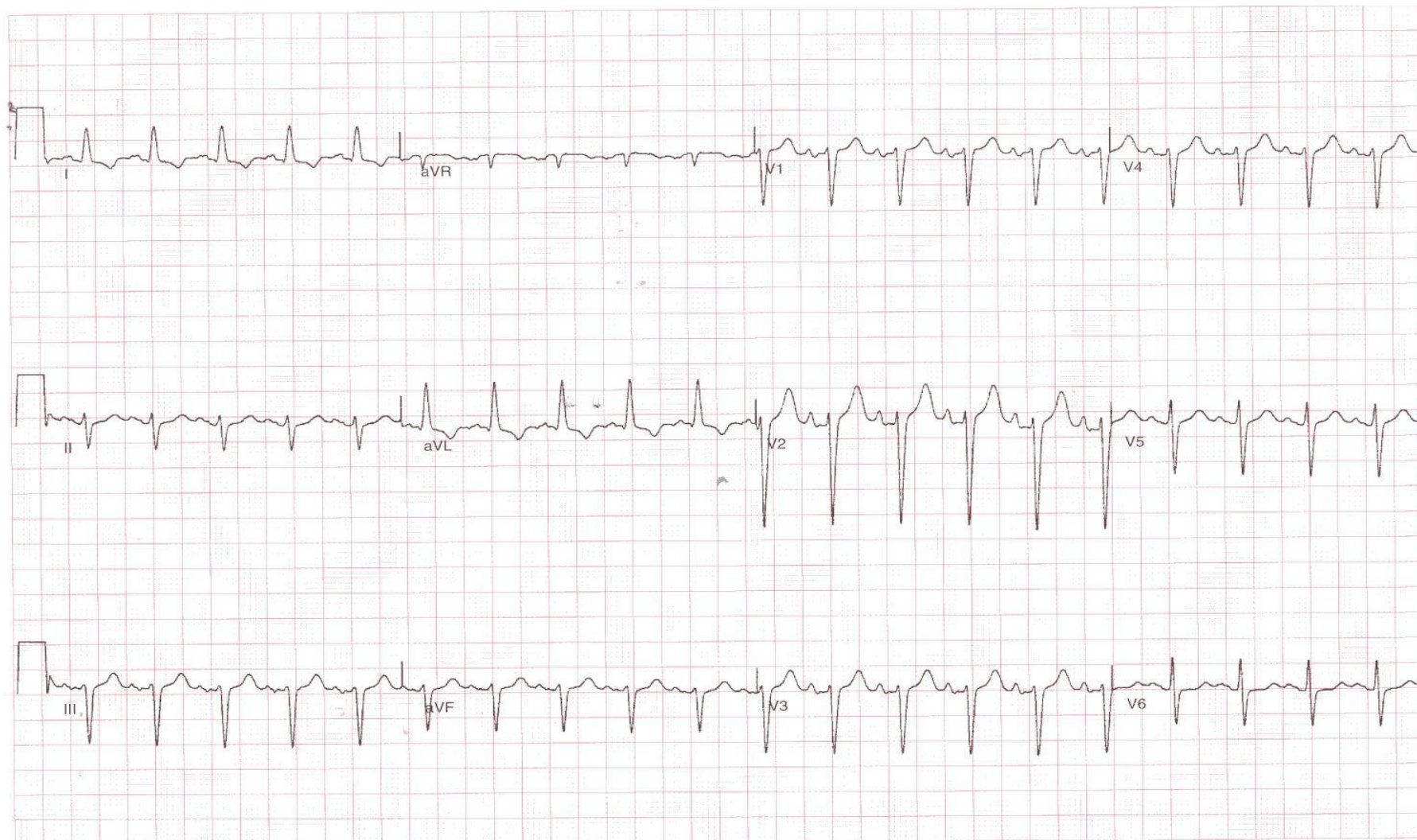


ЭКГ на ИГА

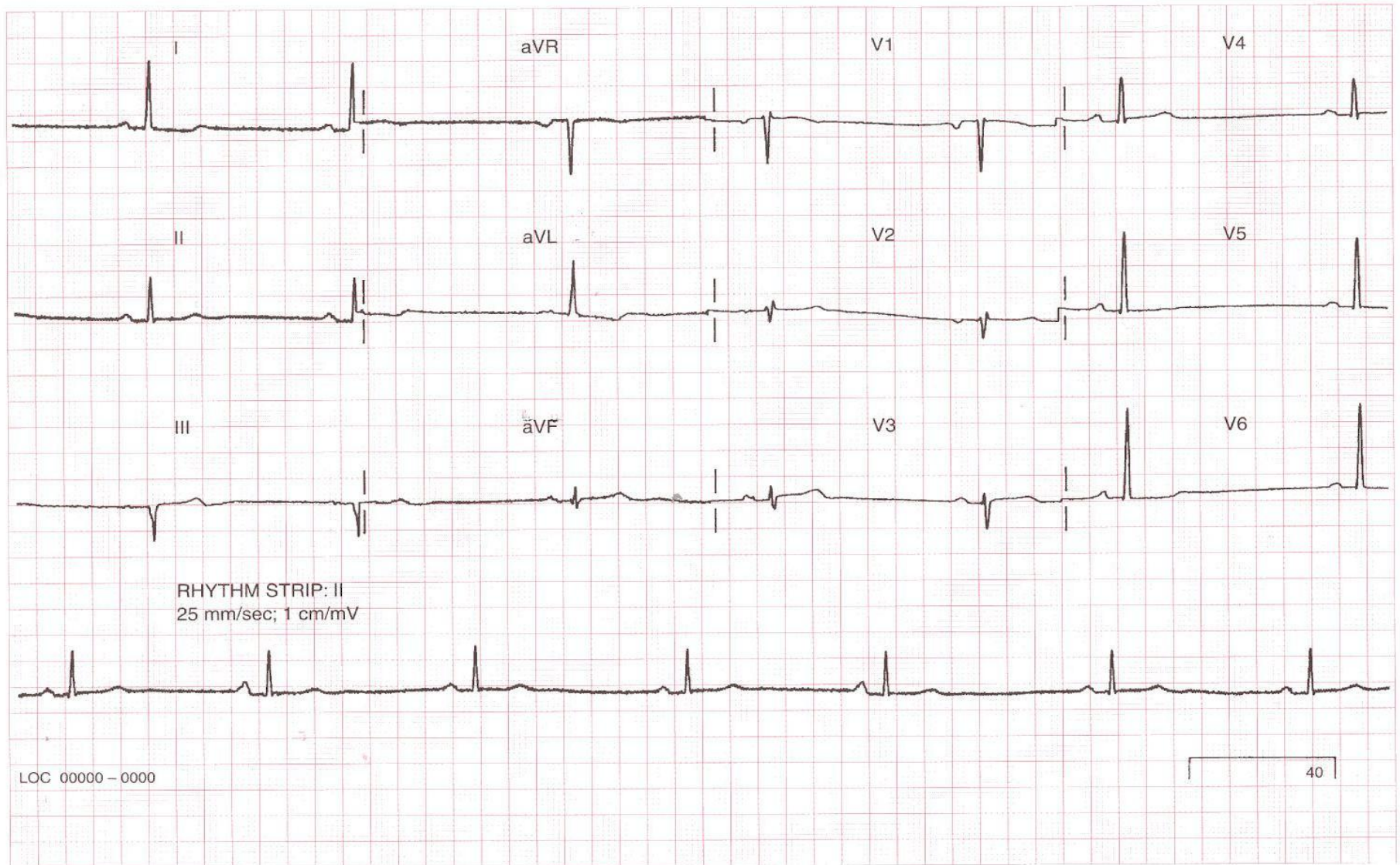
# 1



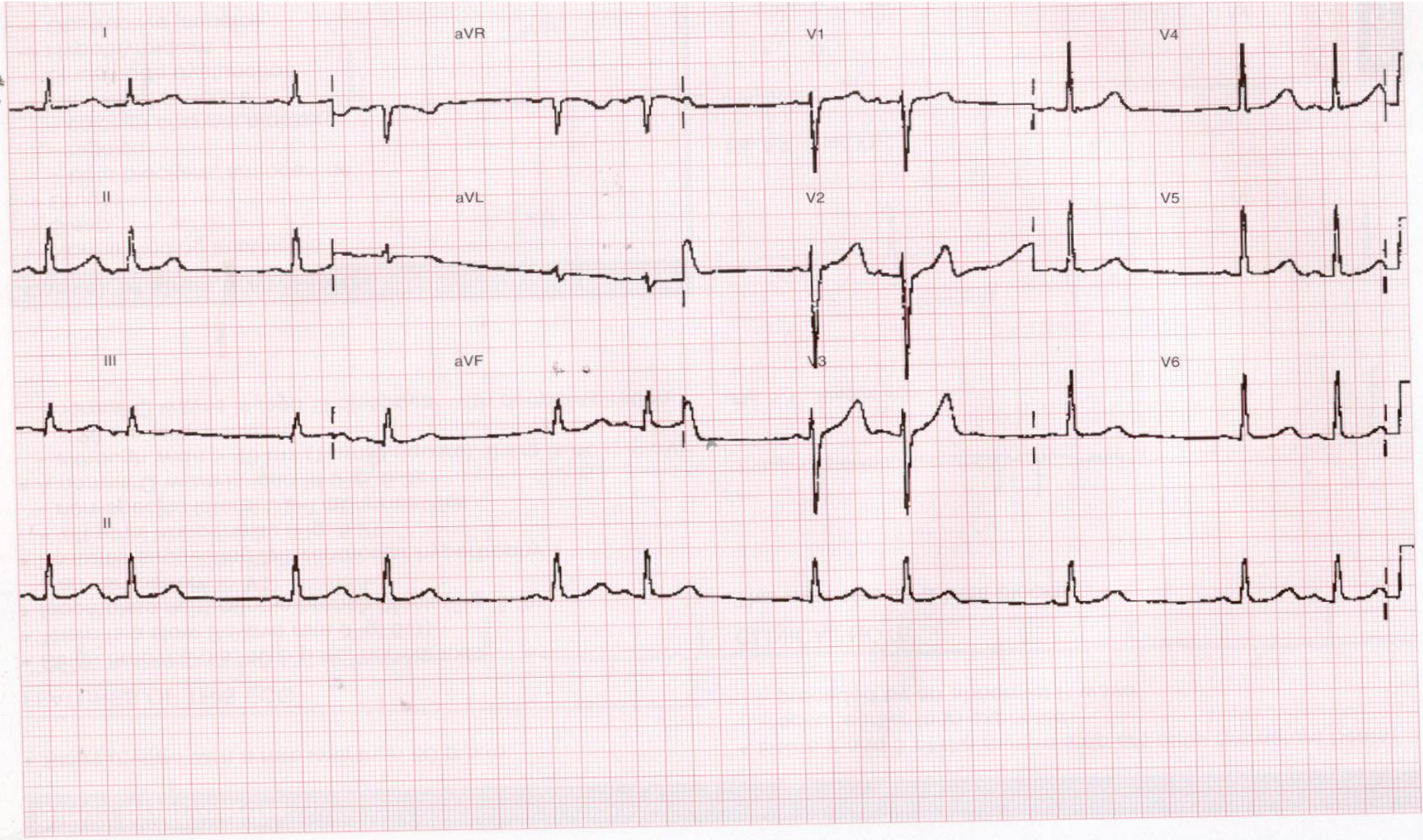
2



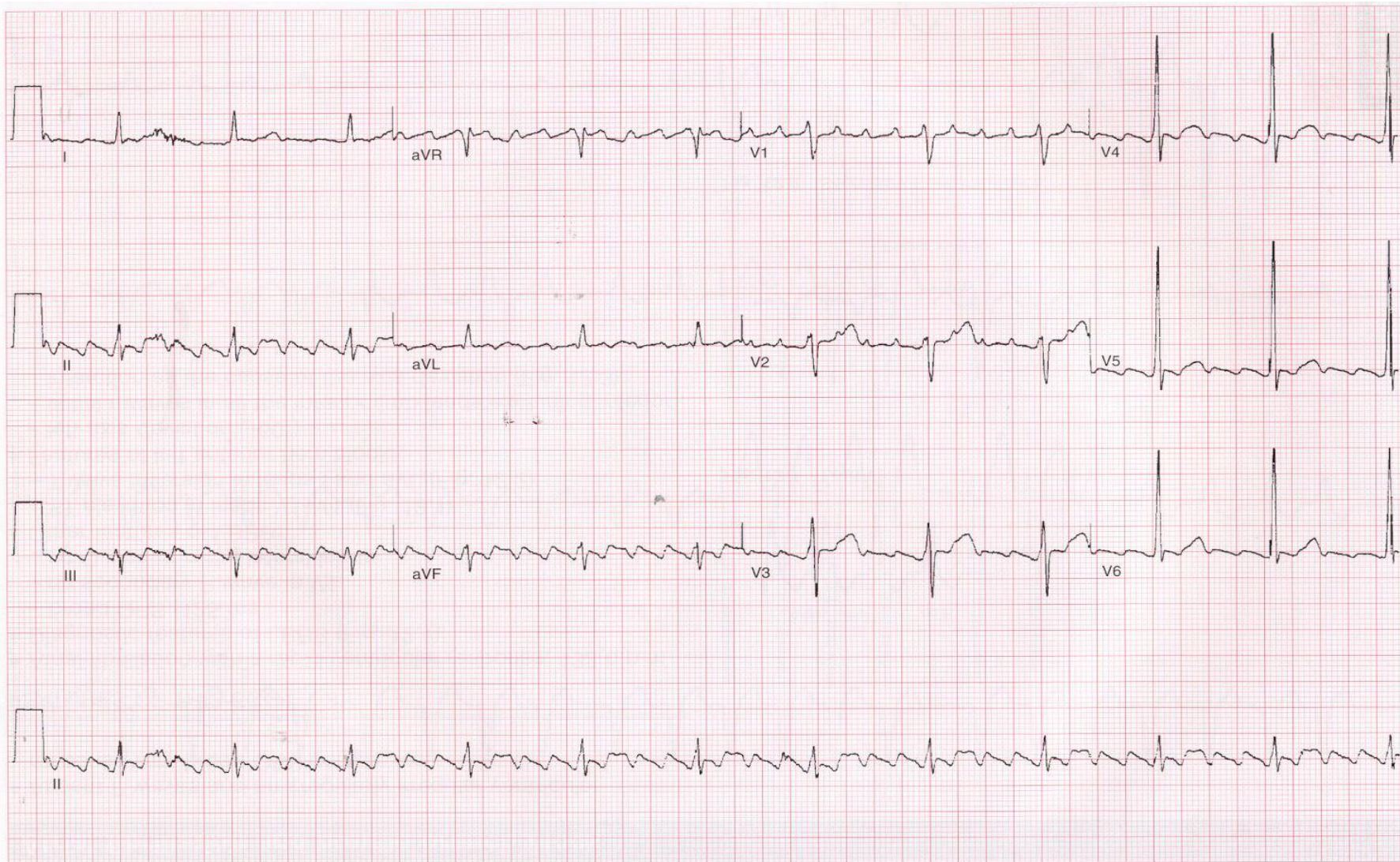
3



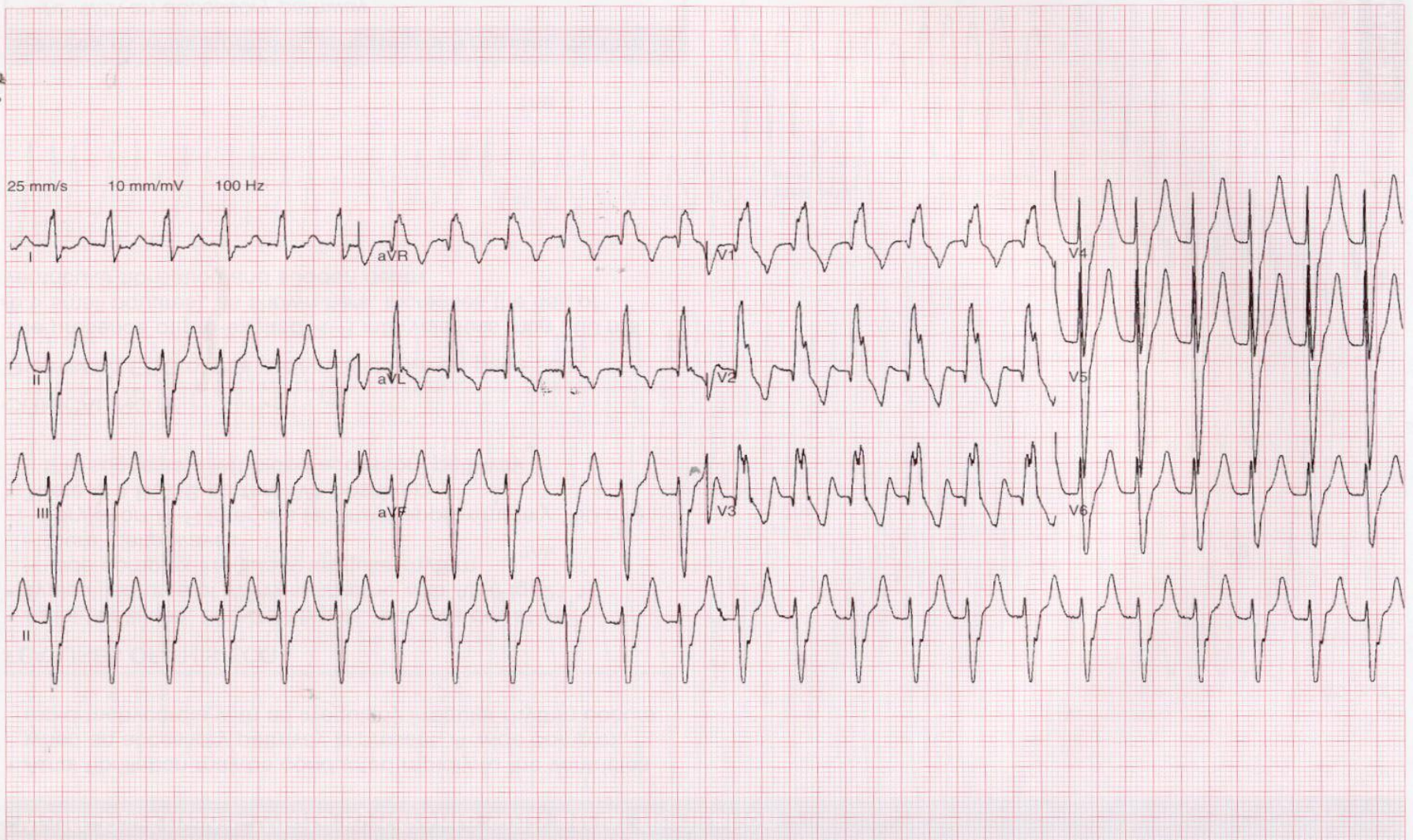
4



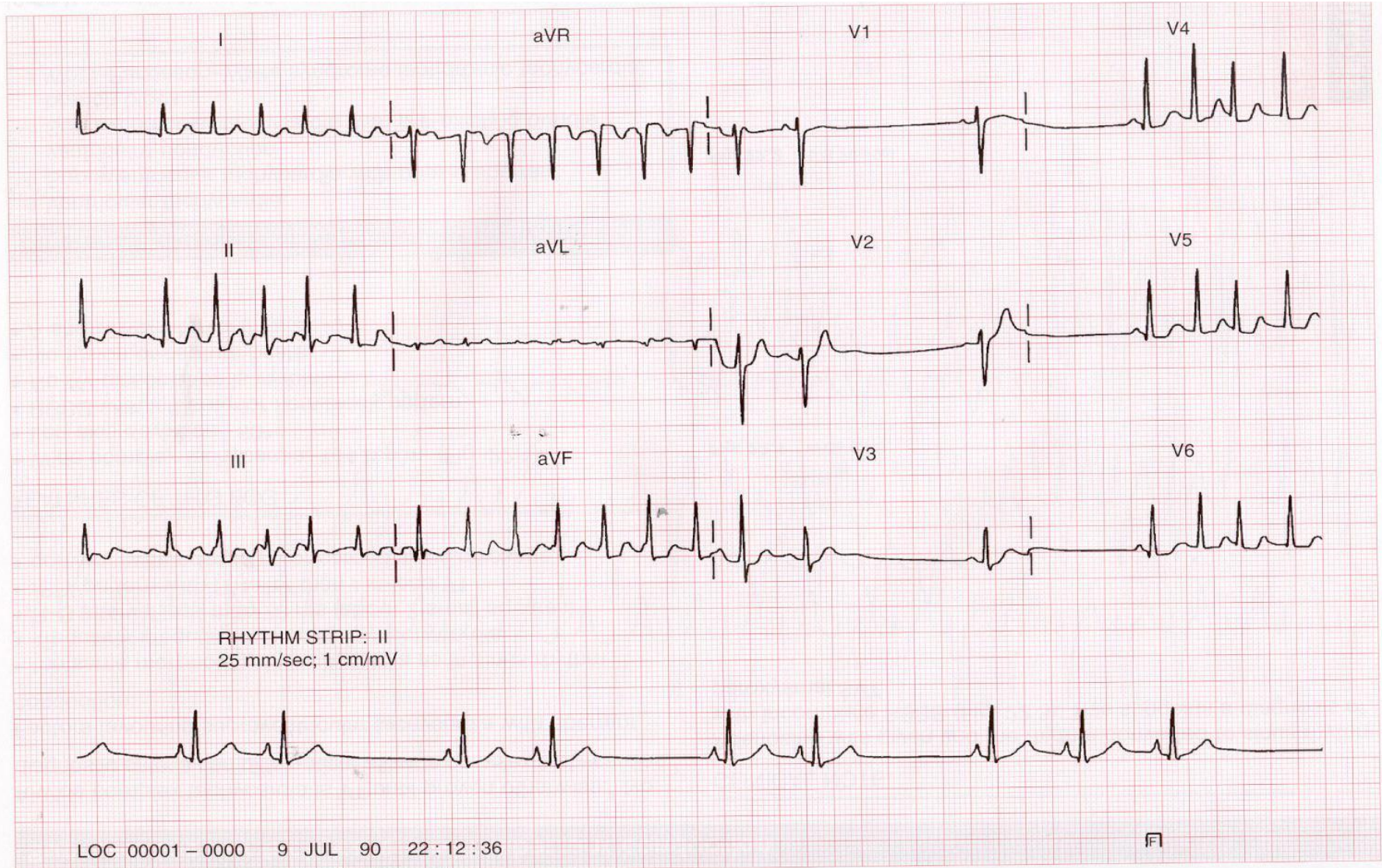
5



6

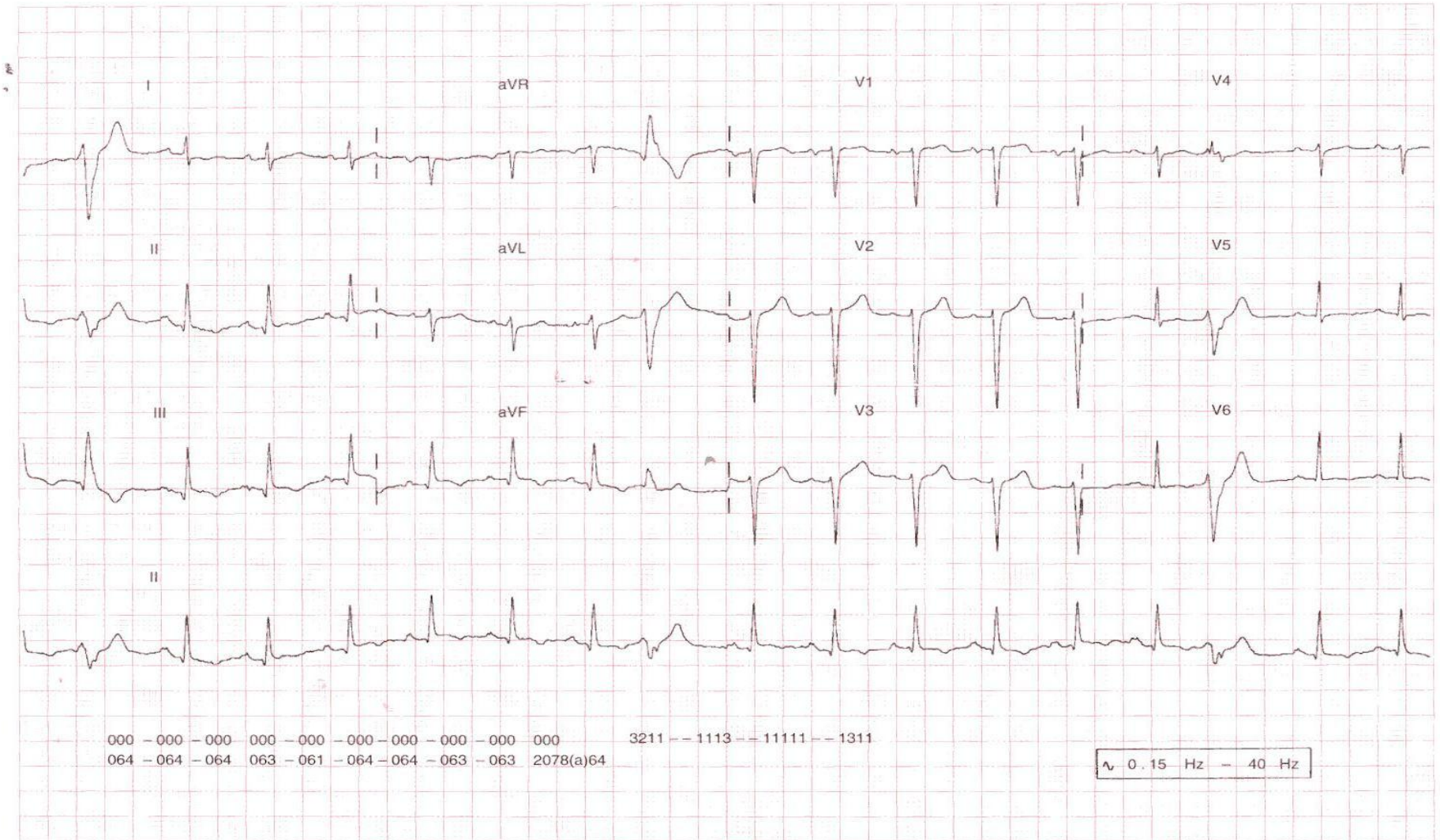


7

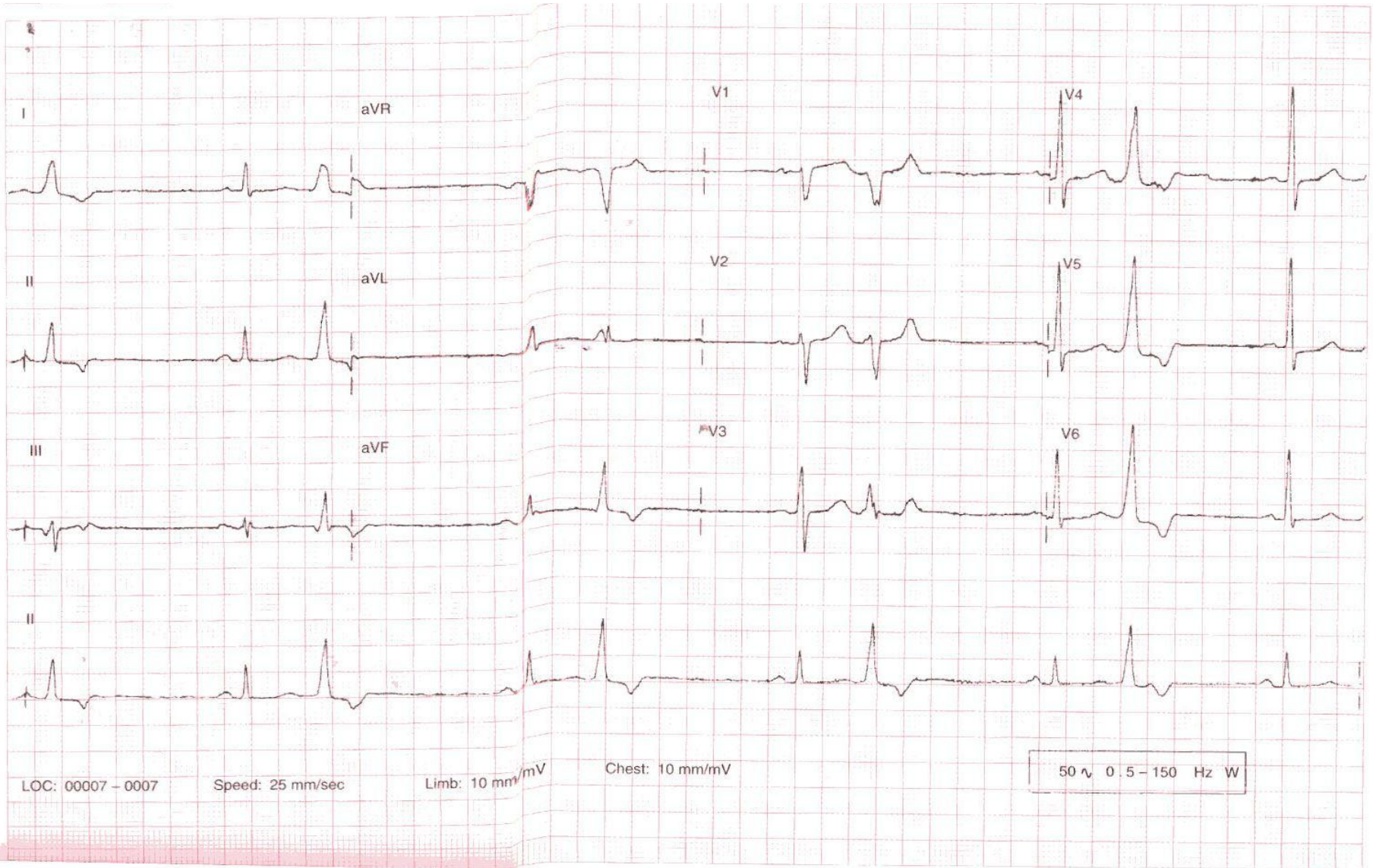




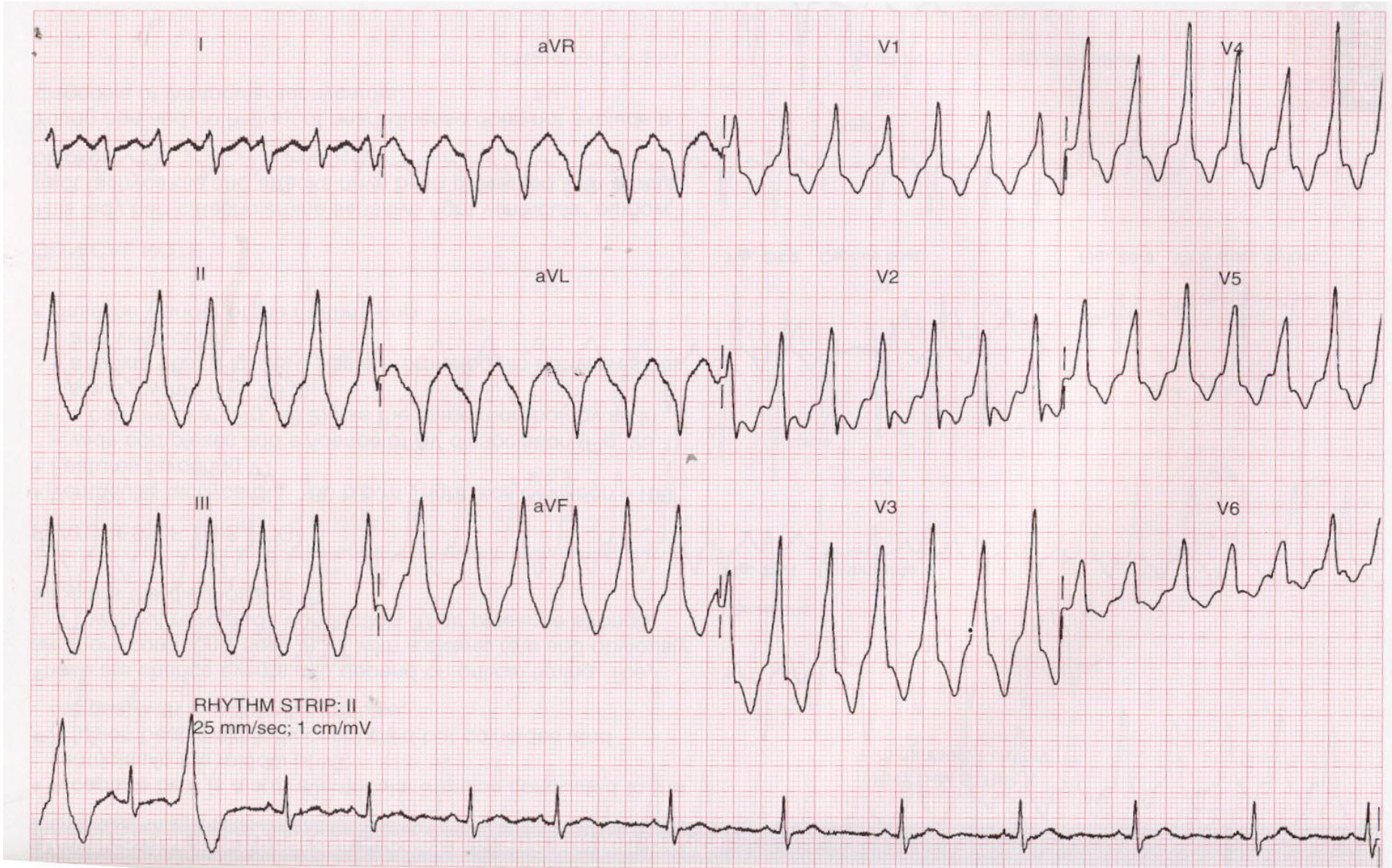
8



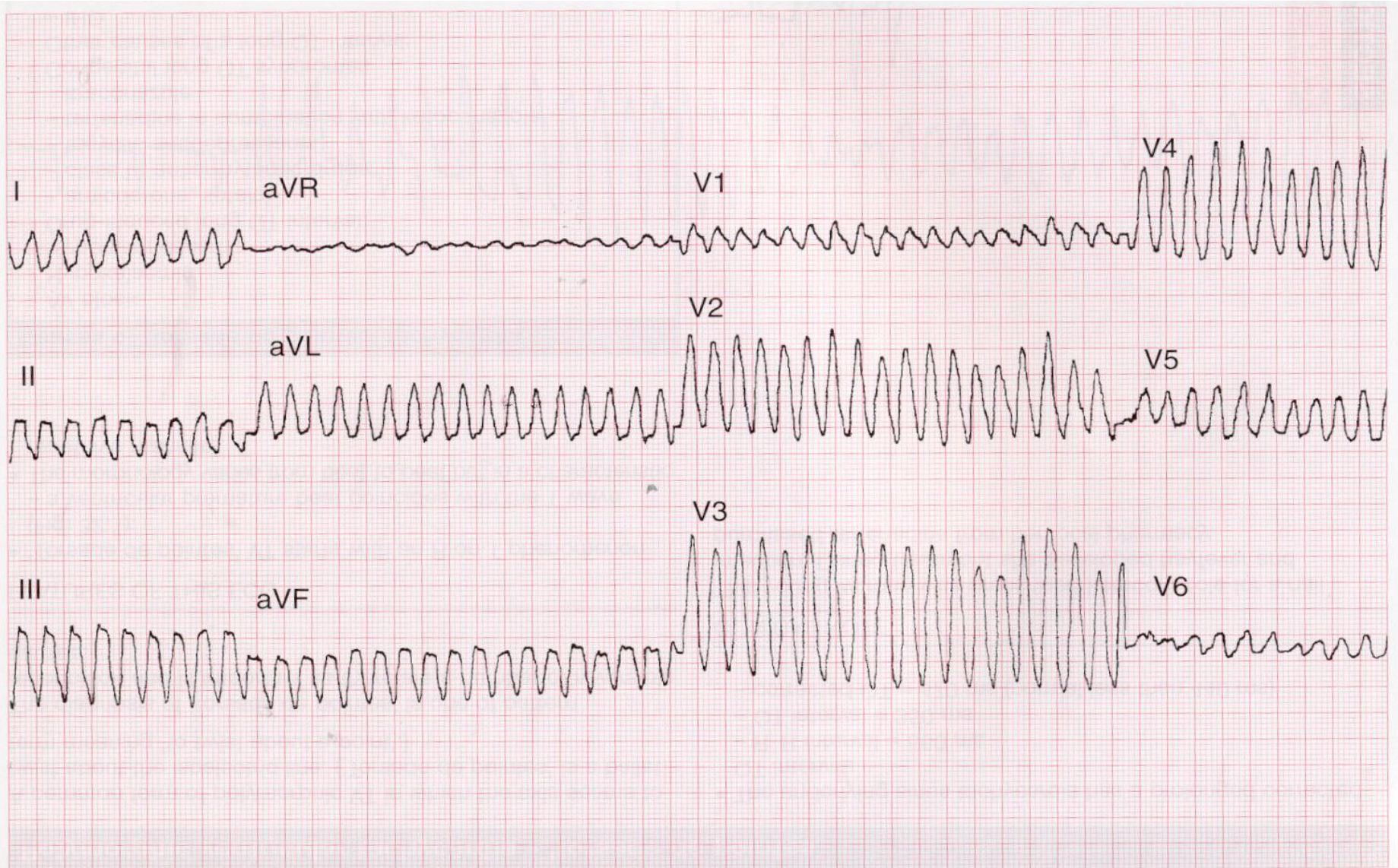
9



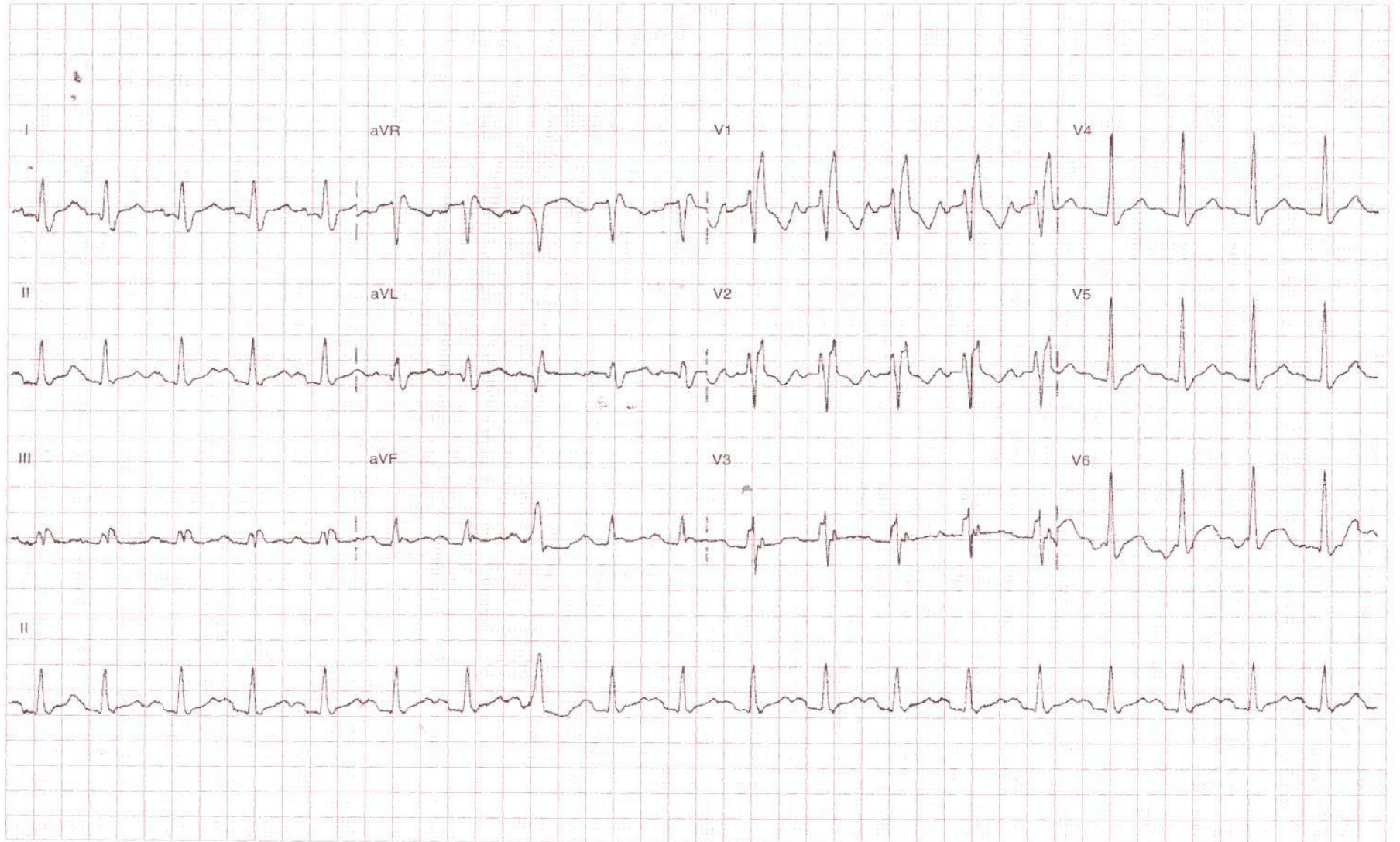
# 10



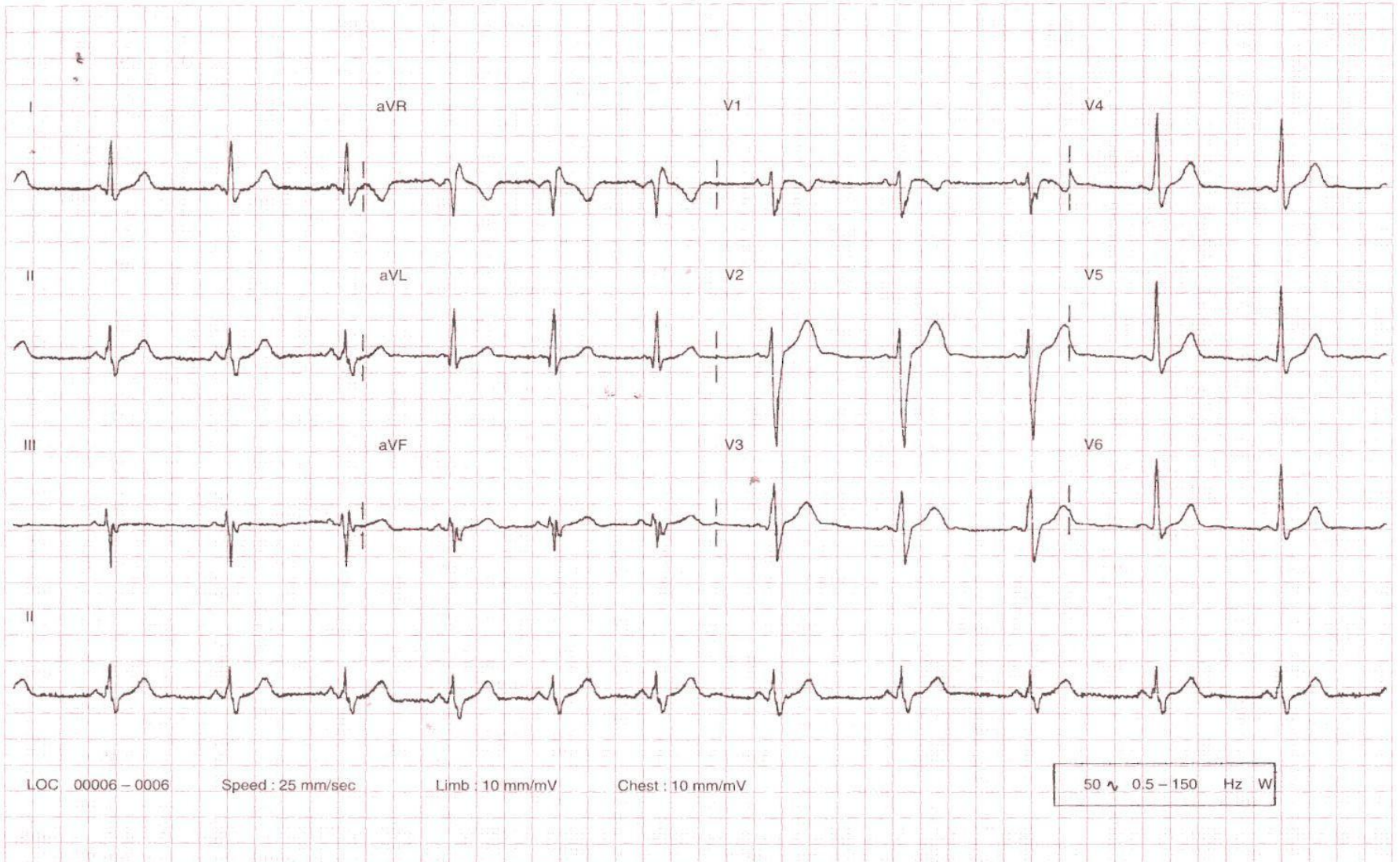
# 11



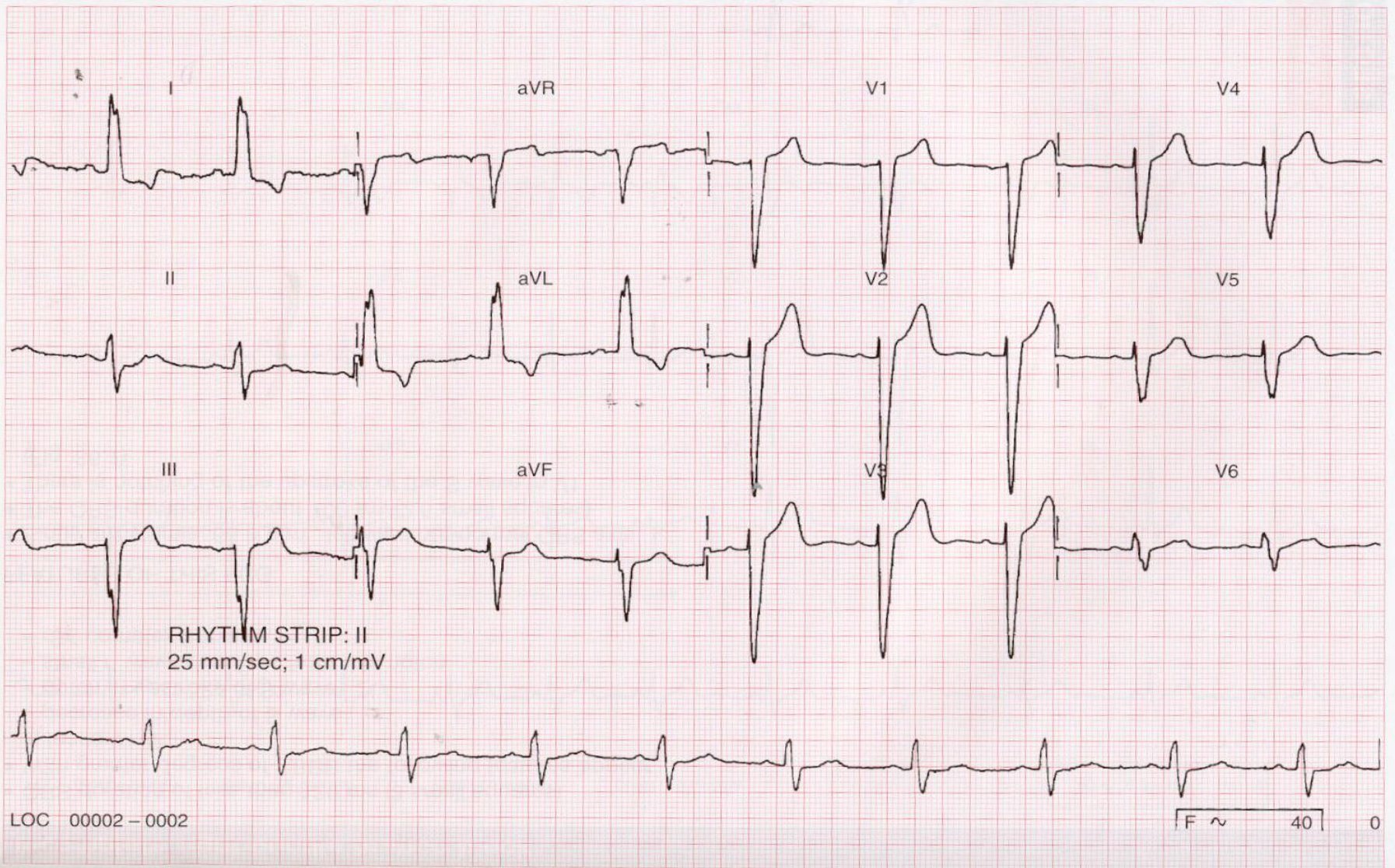
# 12



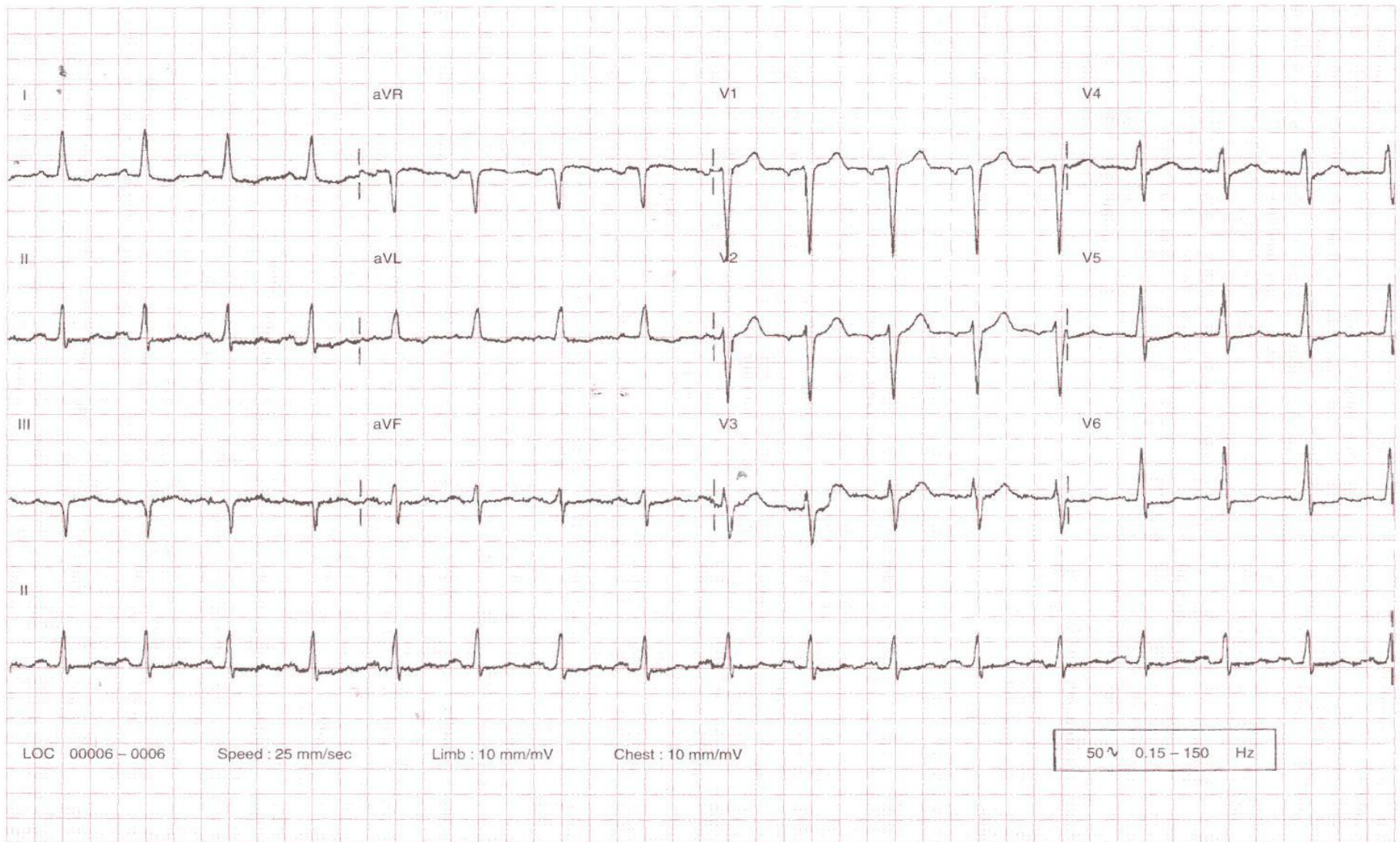
# 13



# 14

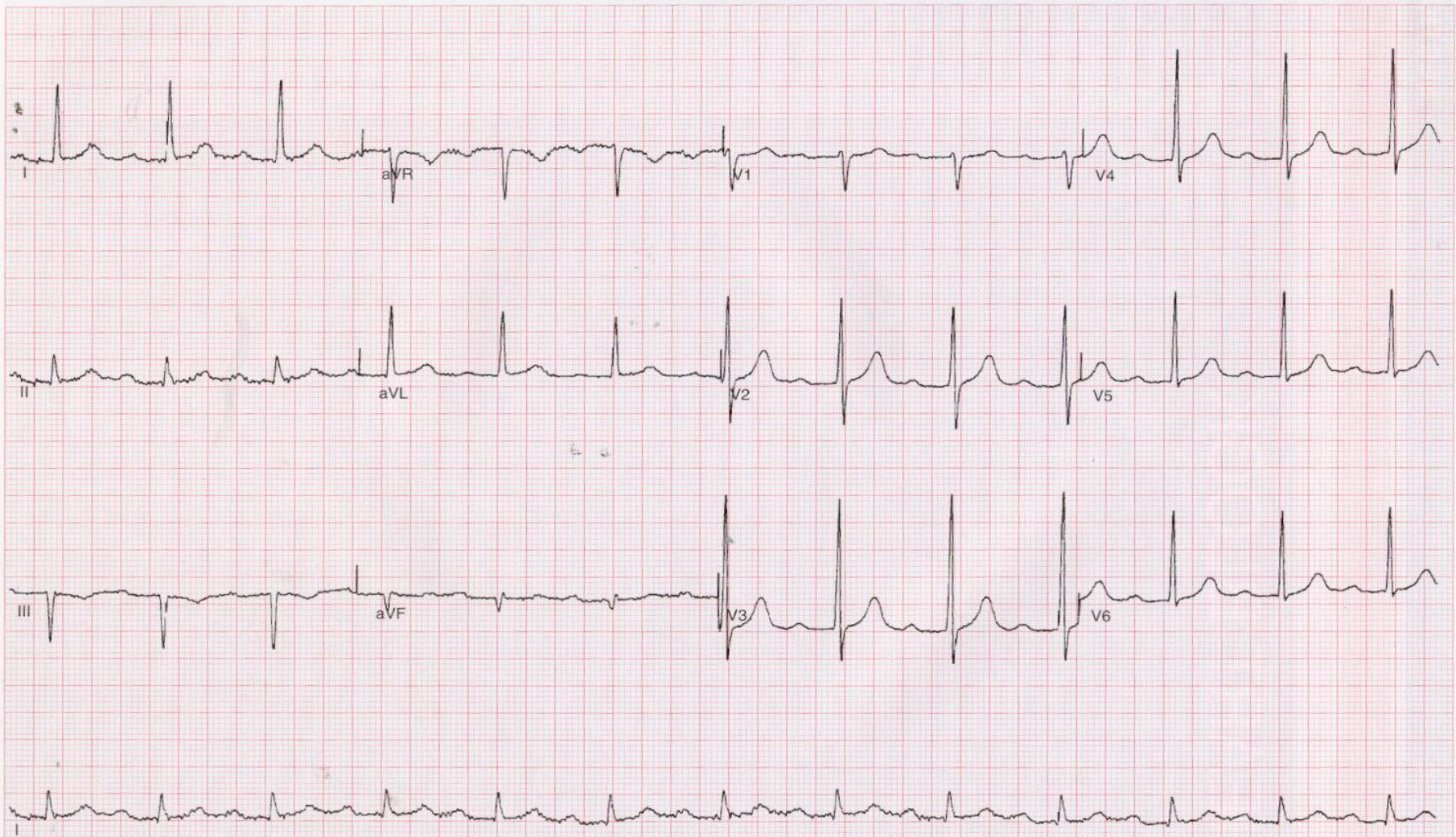


# 15

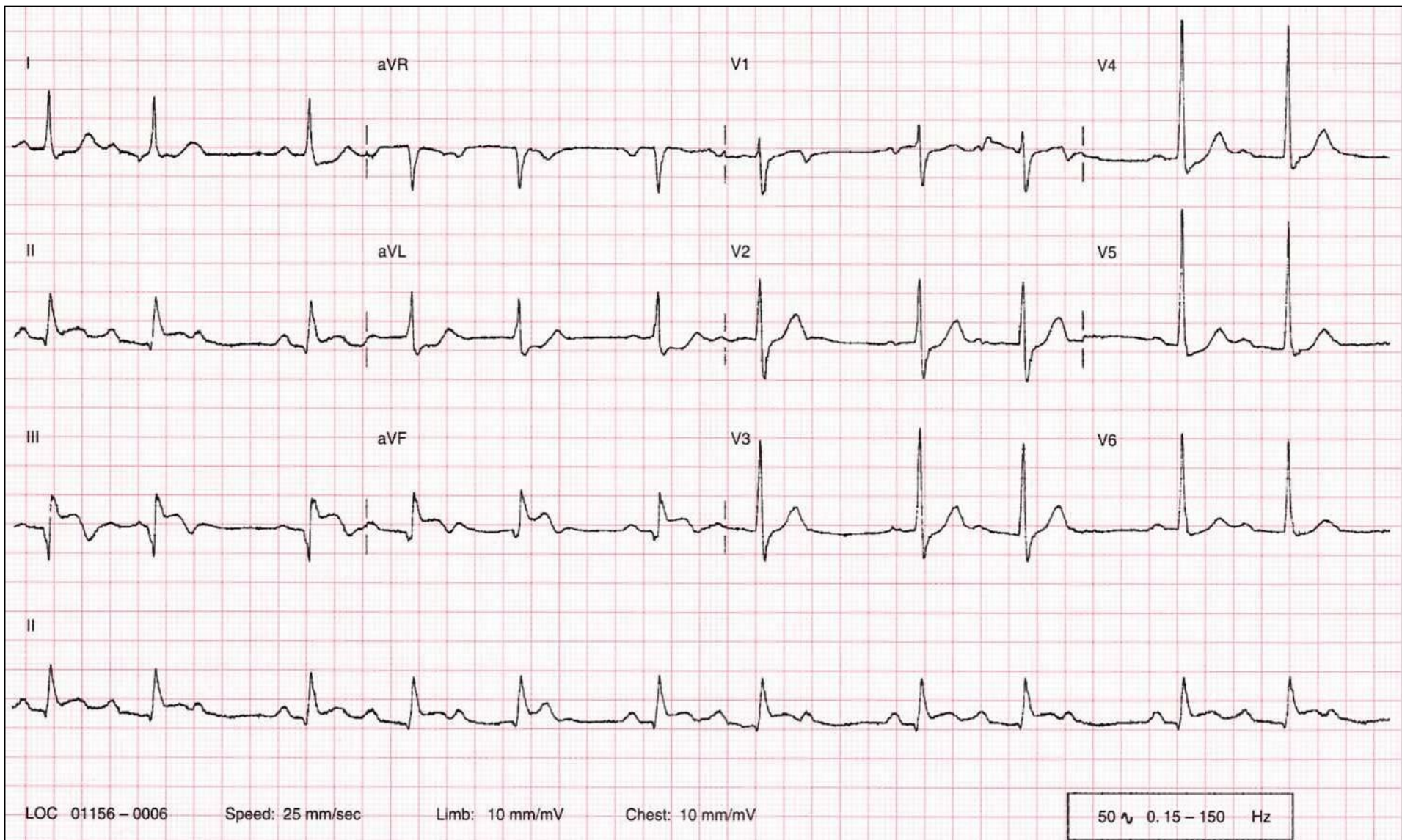




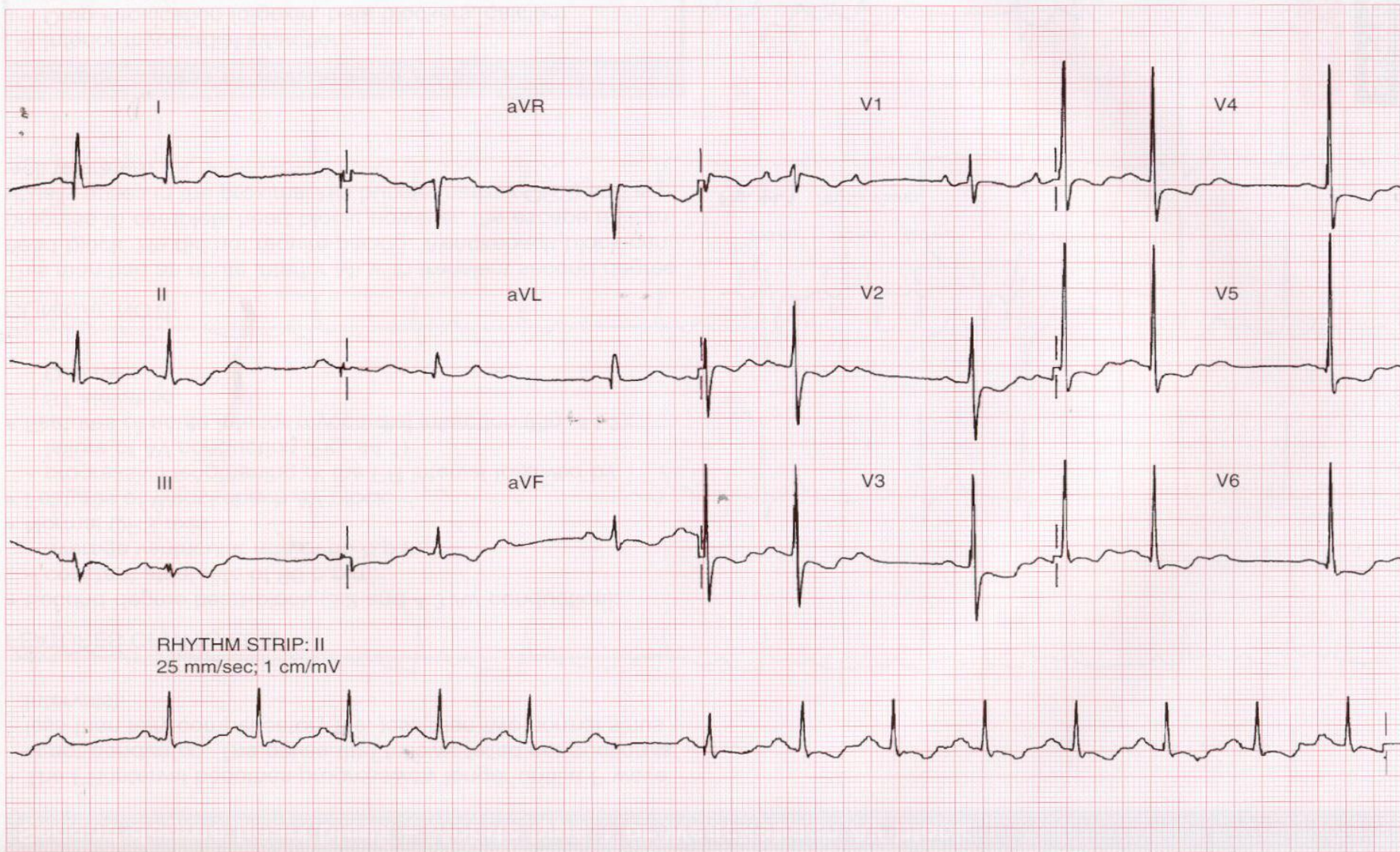
16



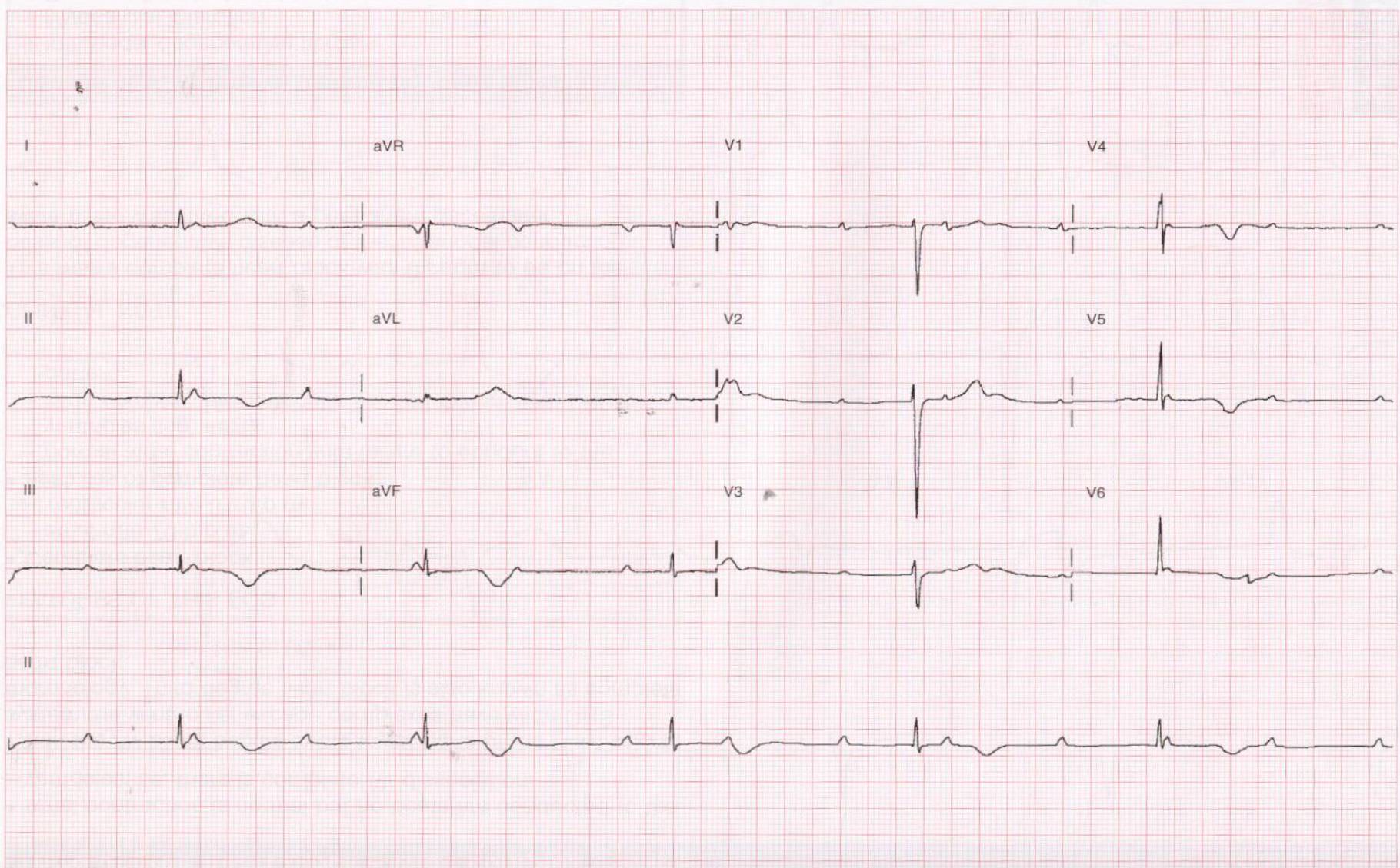
# 17



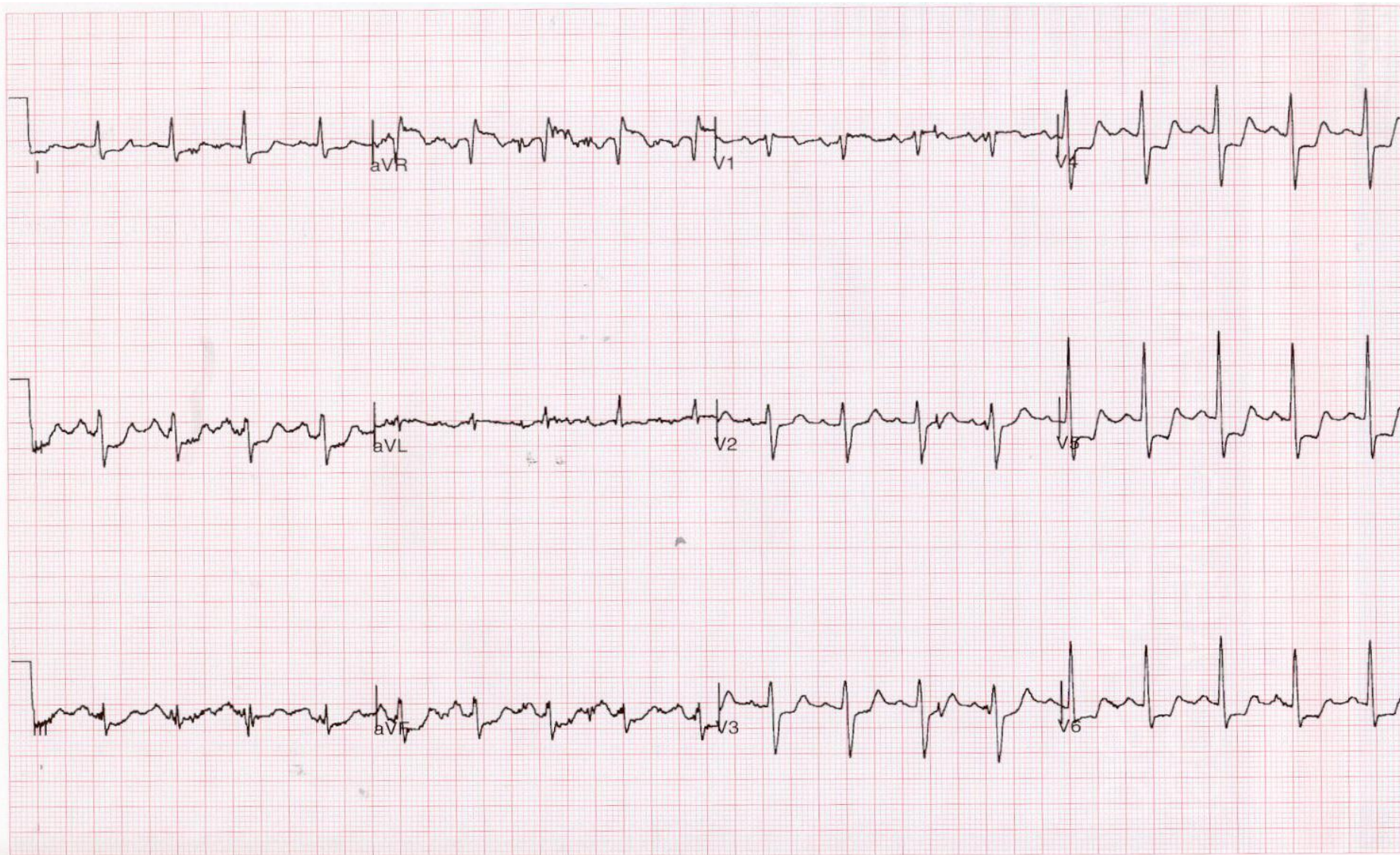
# 18



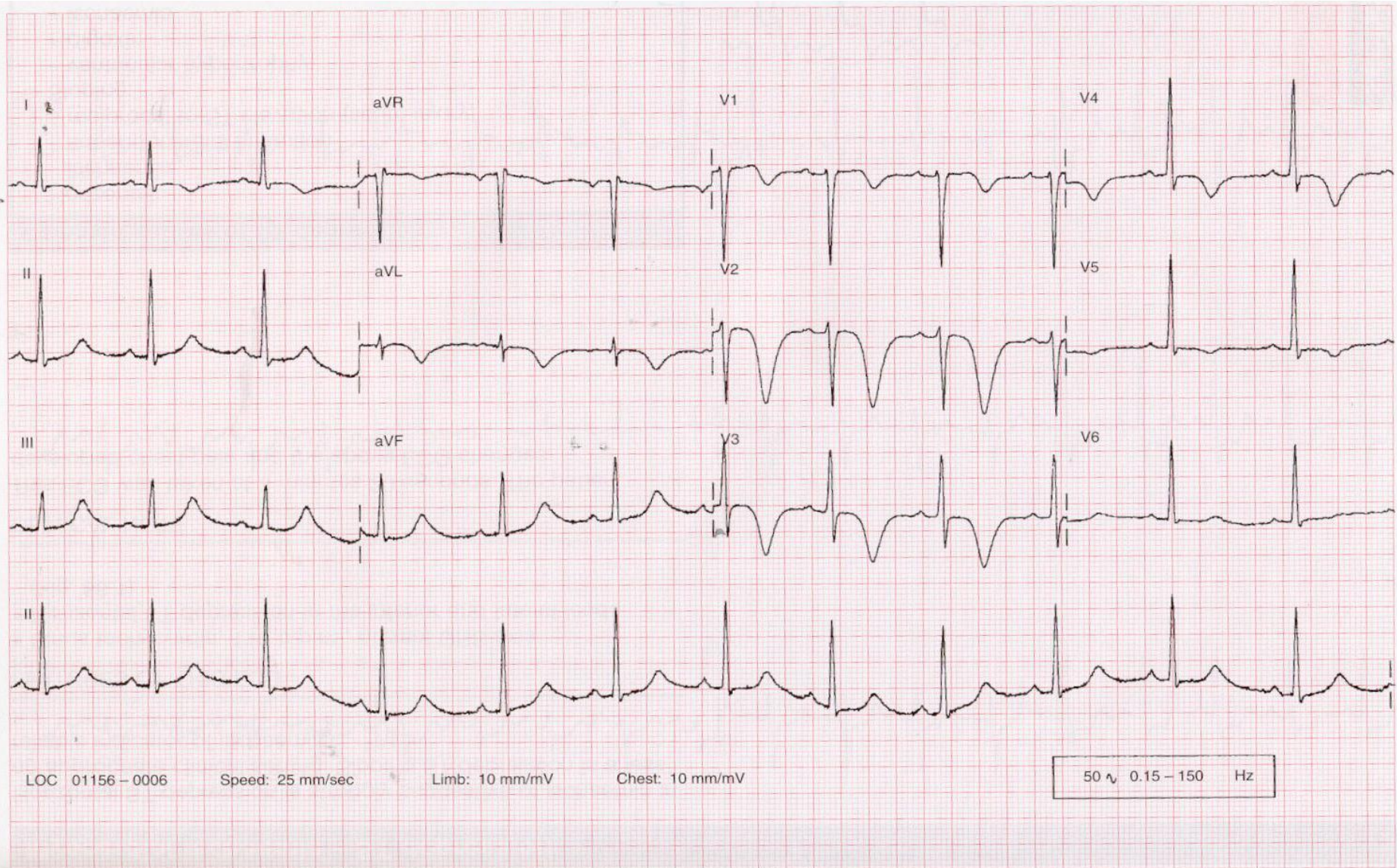
# 19



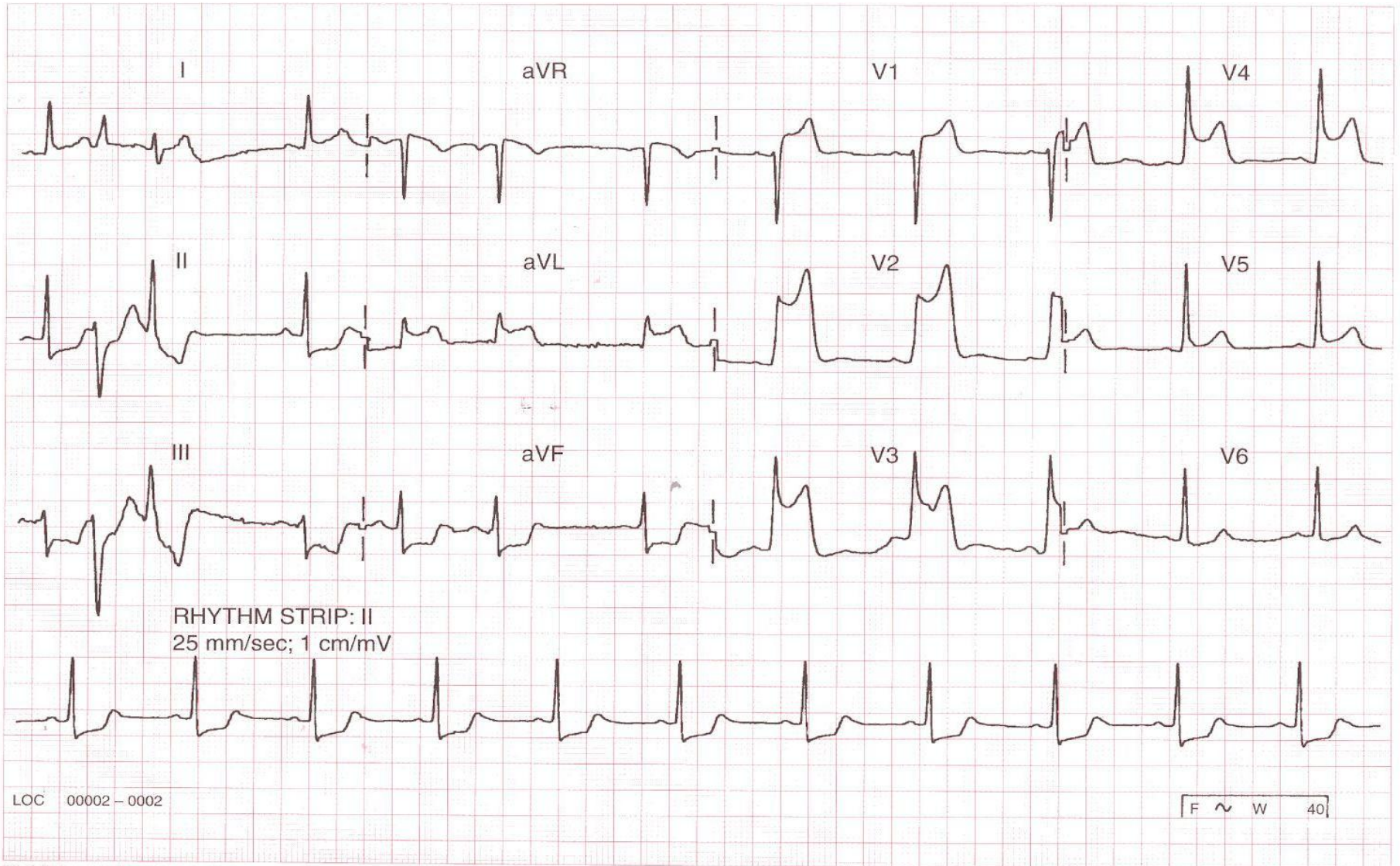
20



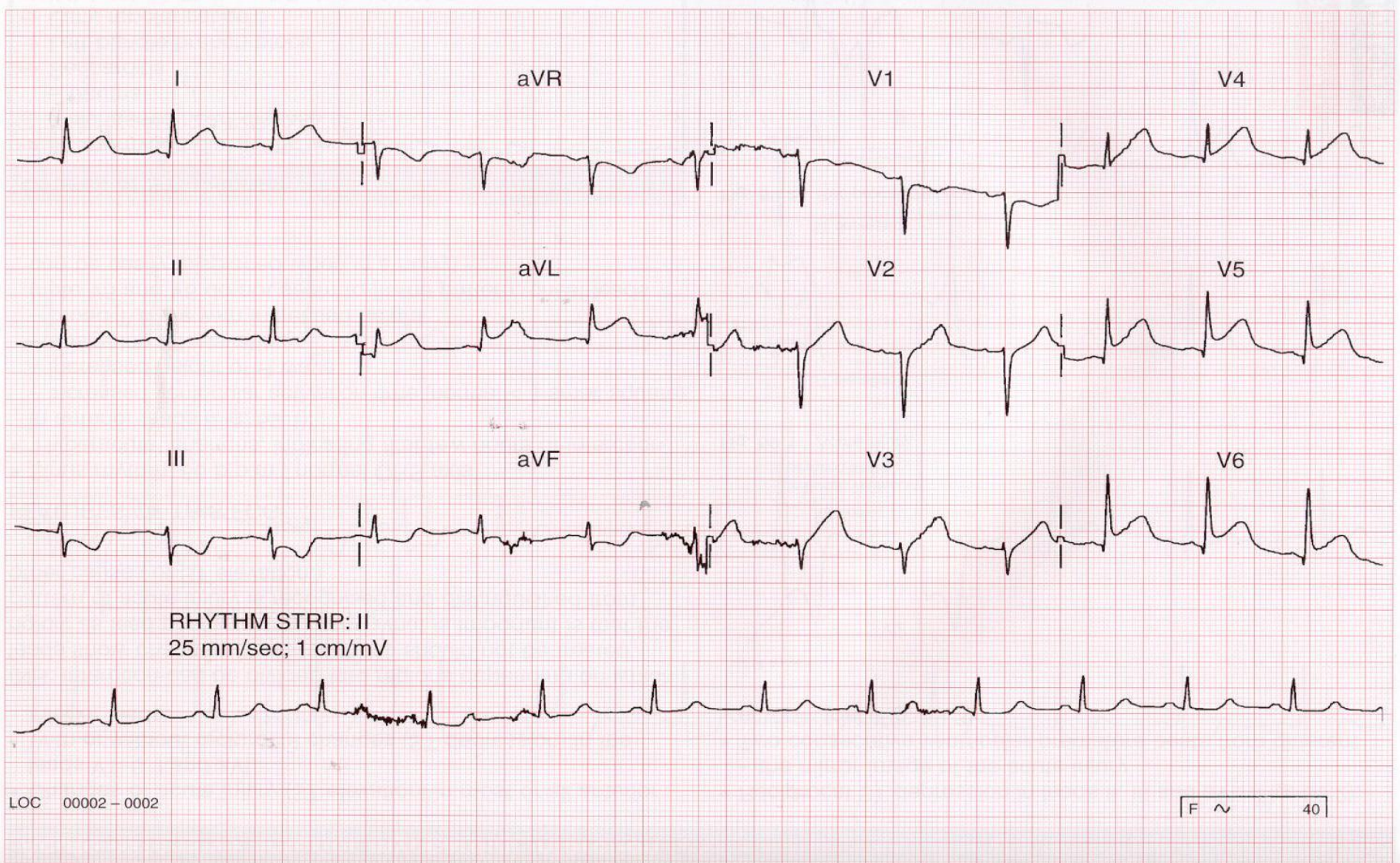
# 21



# 22

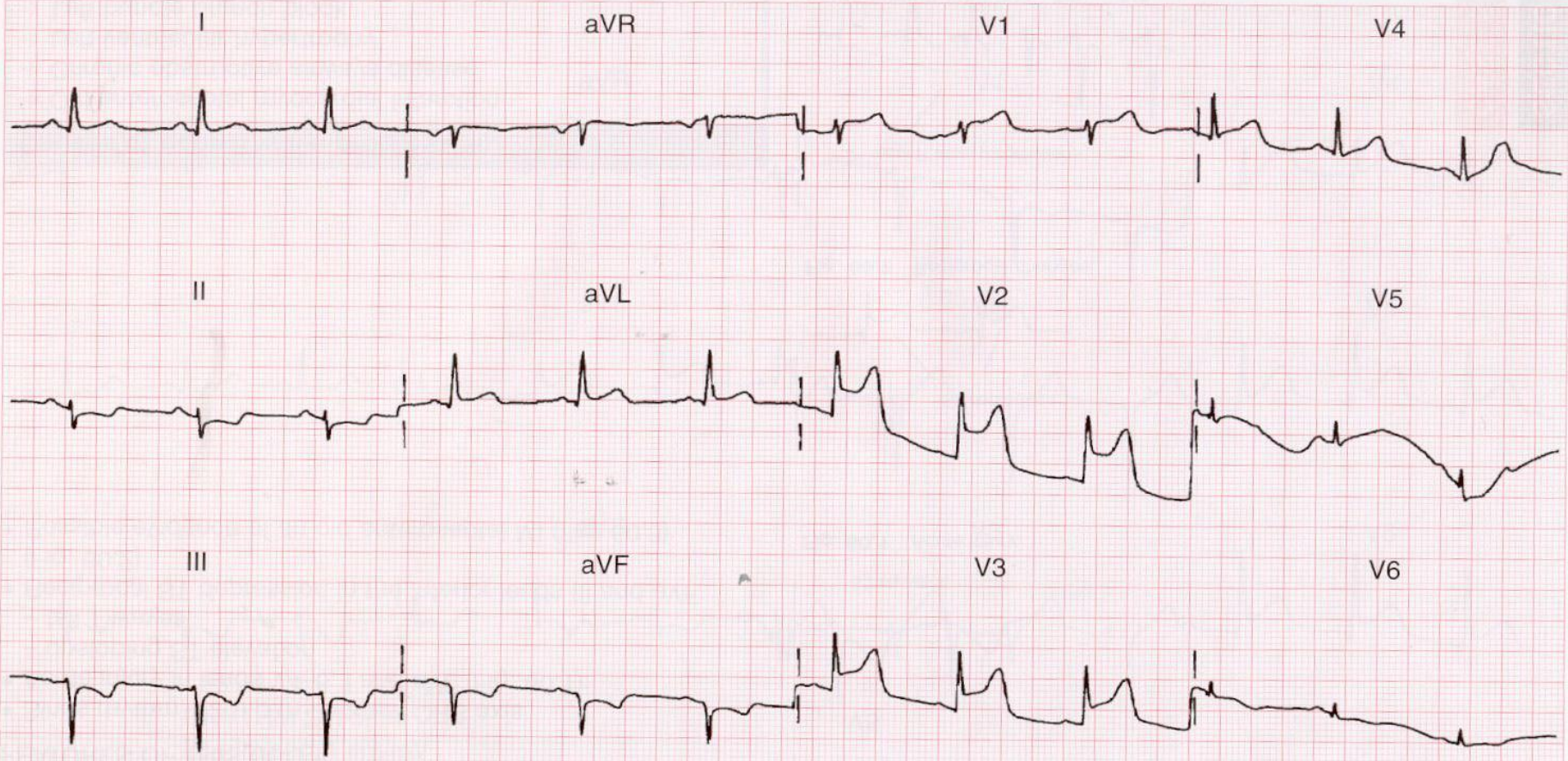


# 23

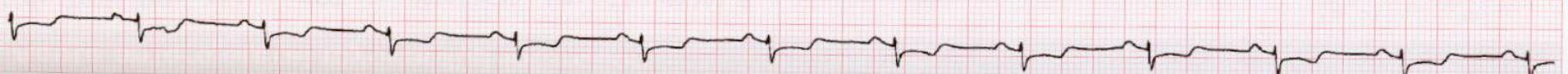



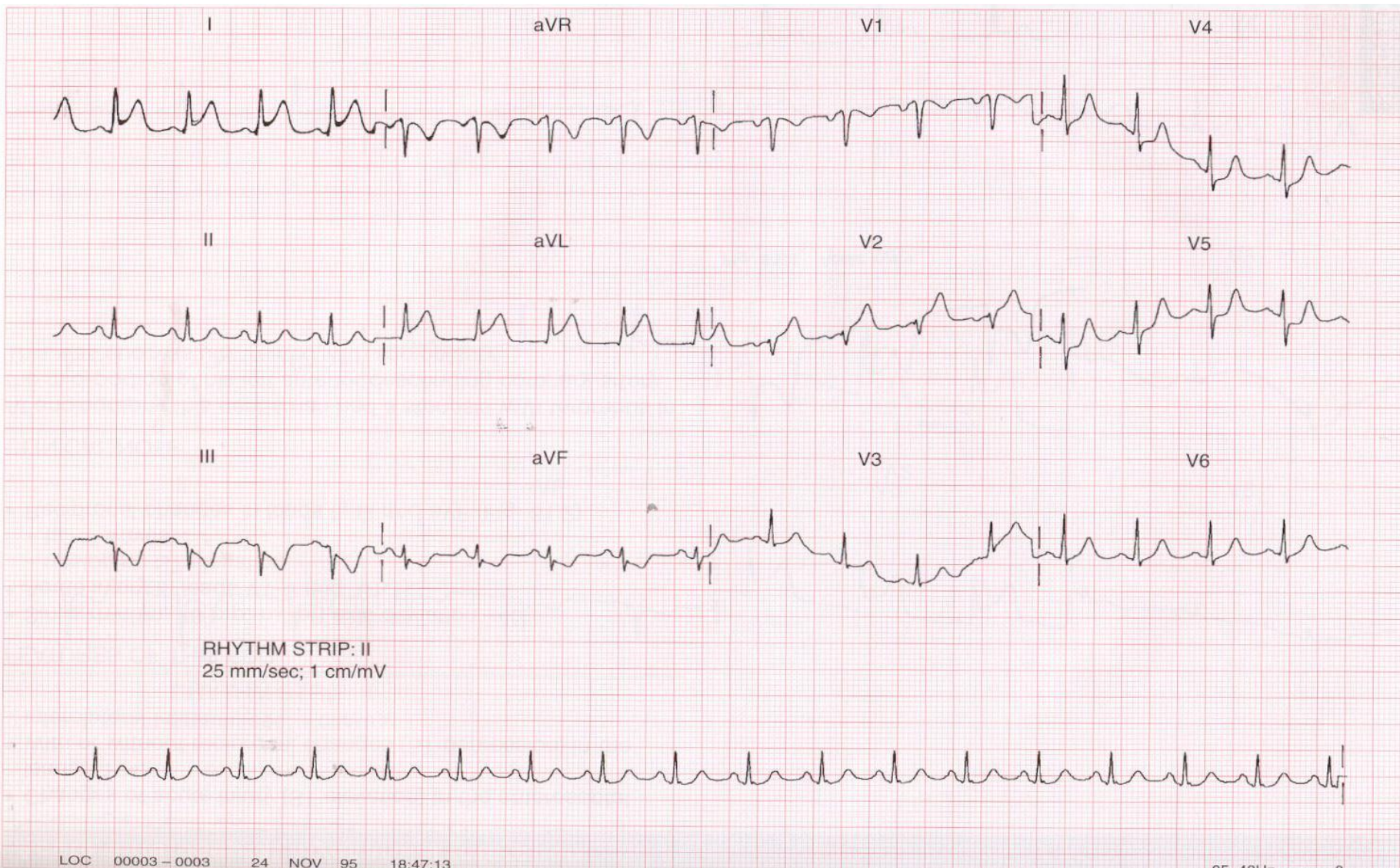
# 24



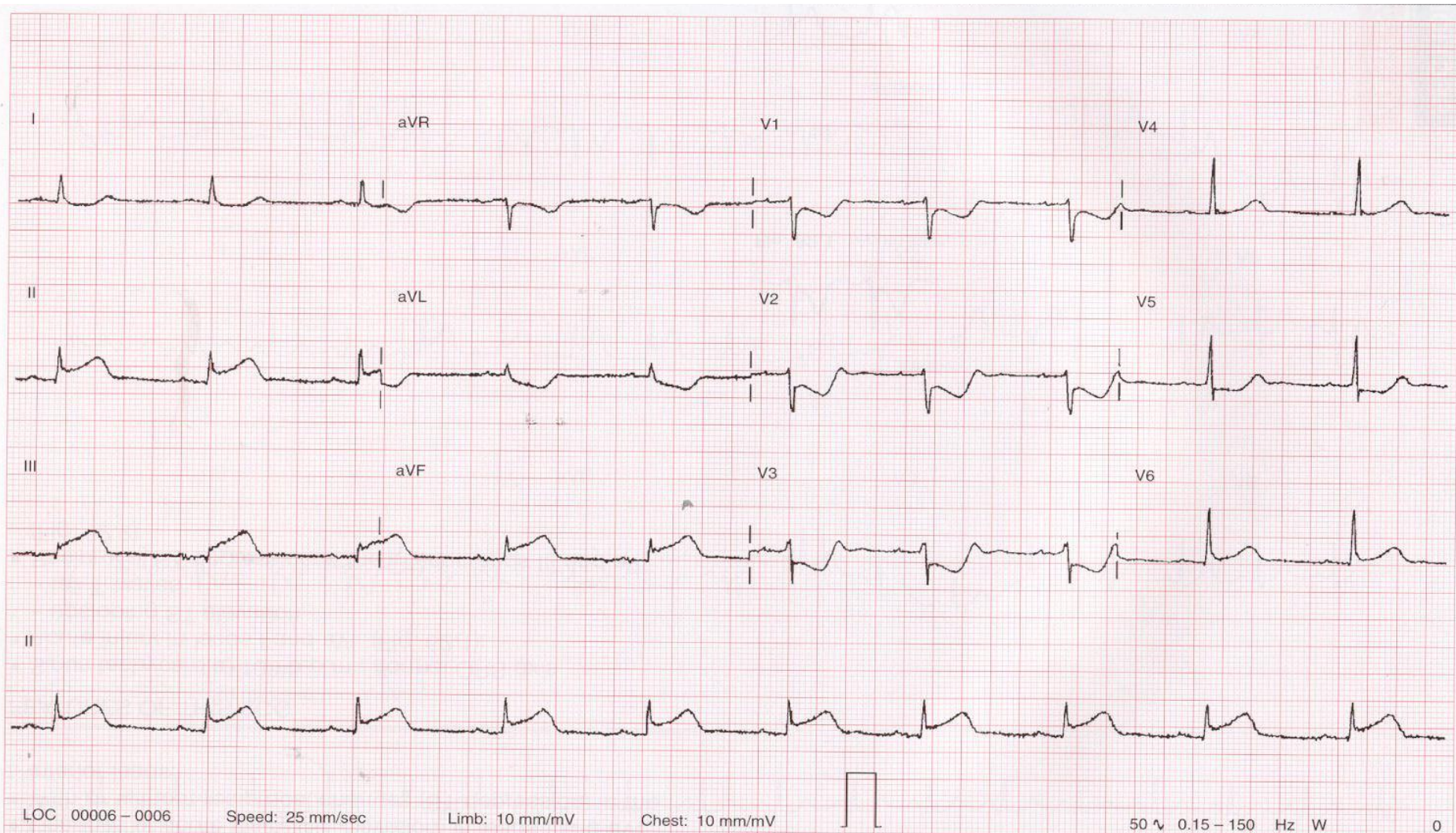
RHYTHM STRIP: II  
25 mm/sec; 1 cm/mV



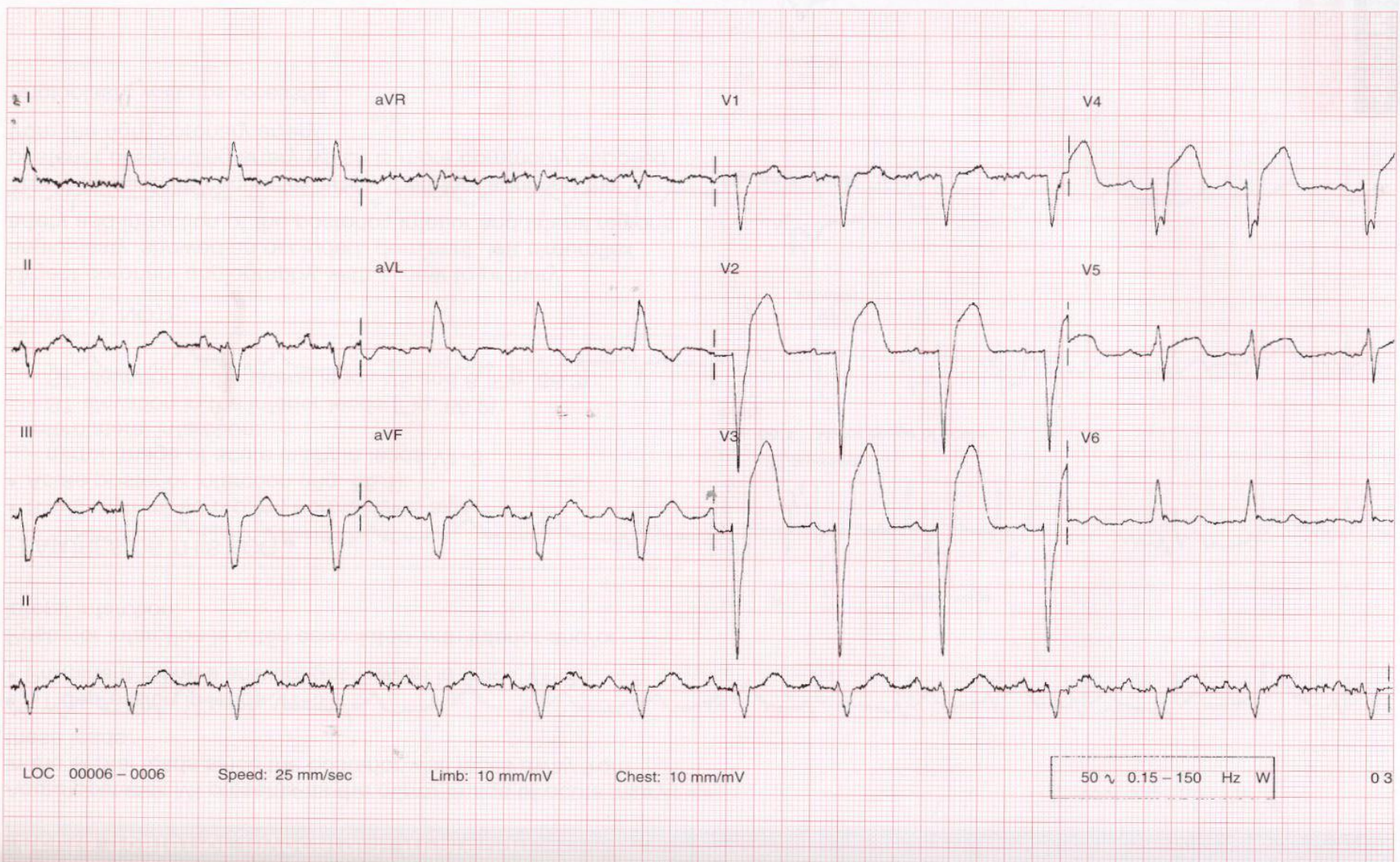
# 25



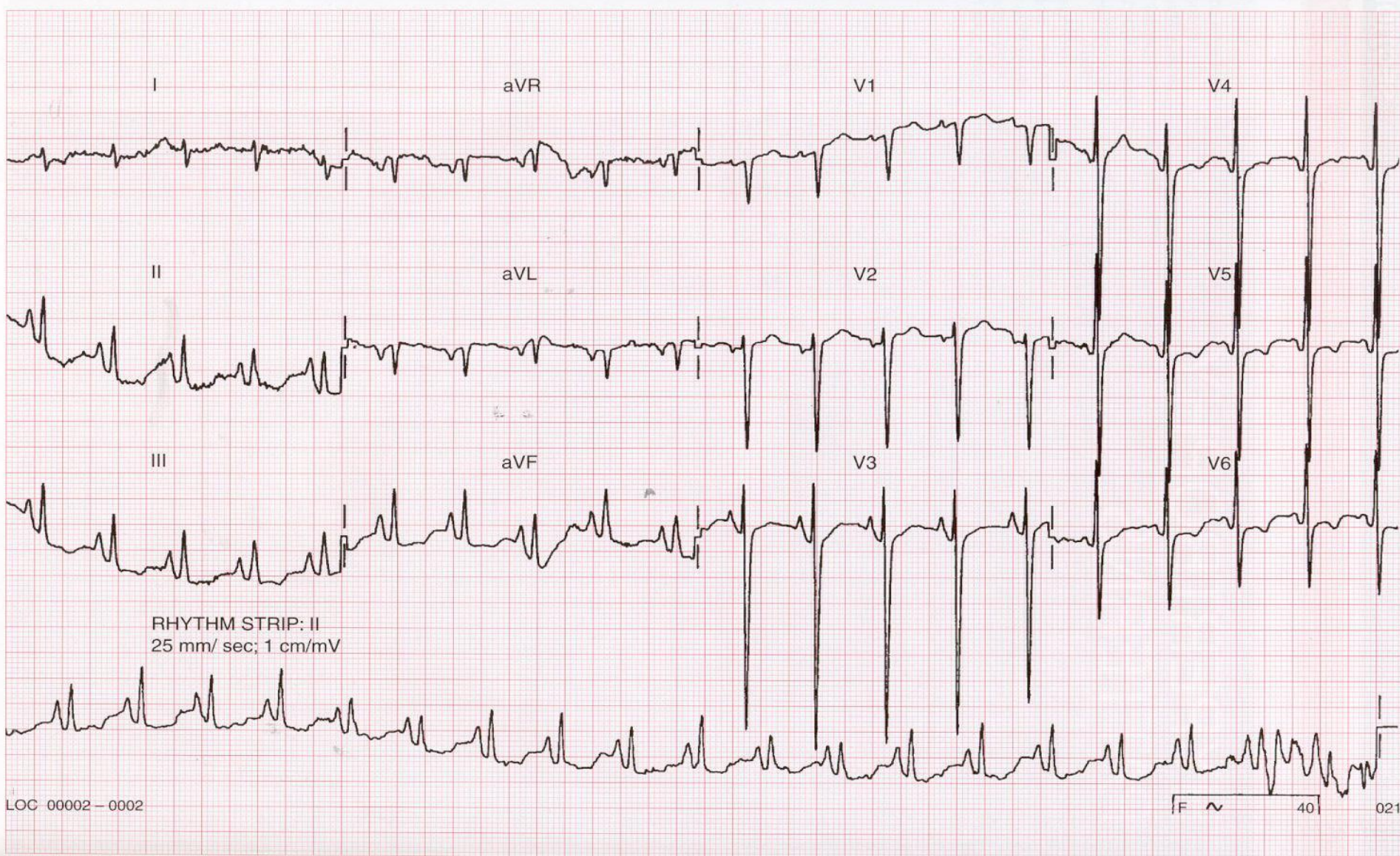
# 26



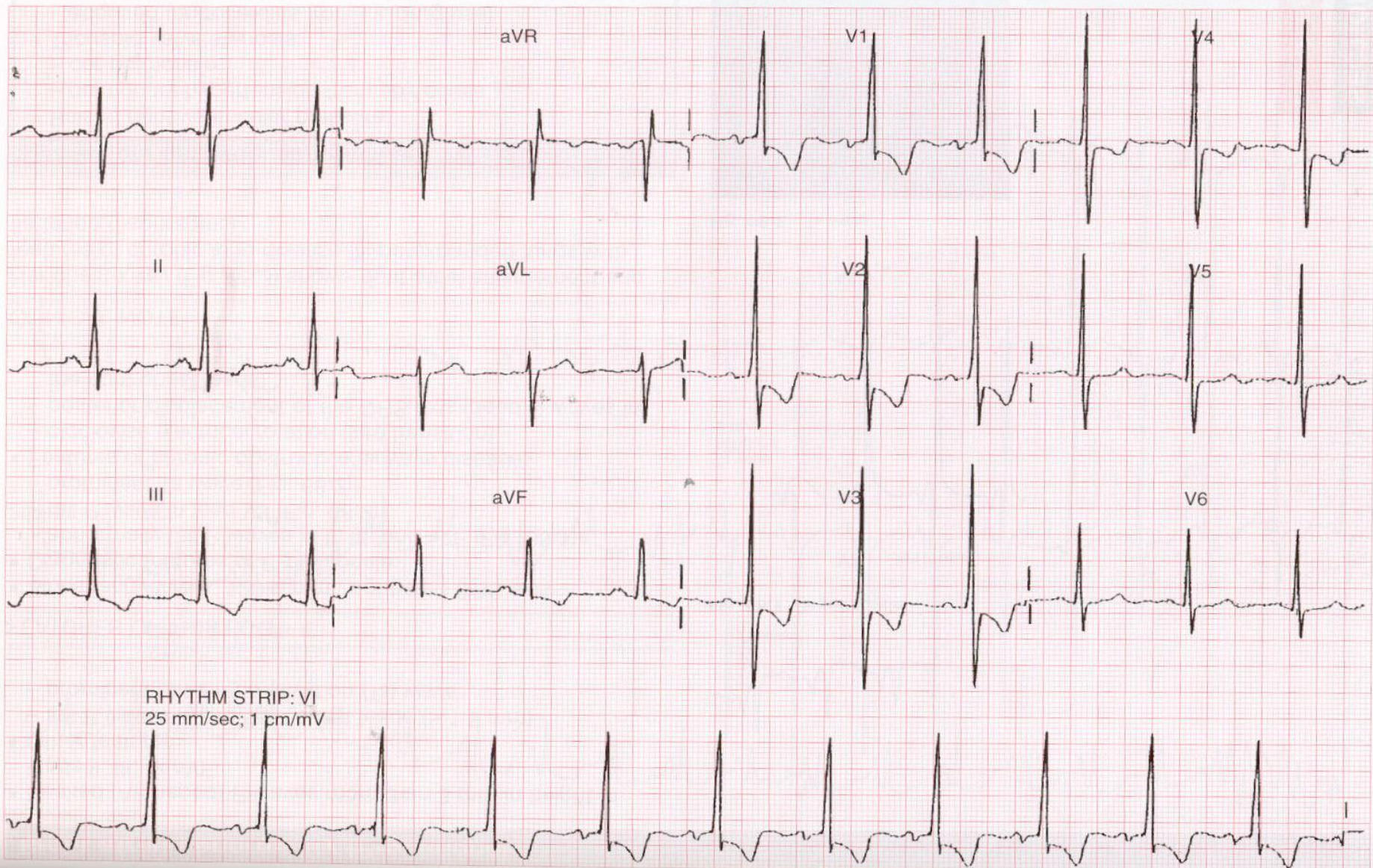
27



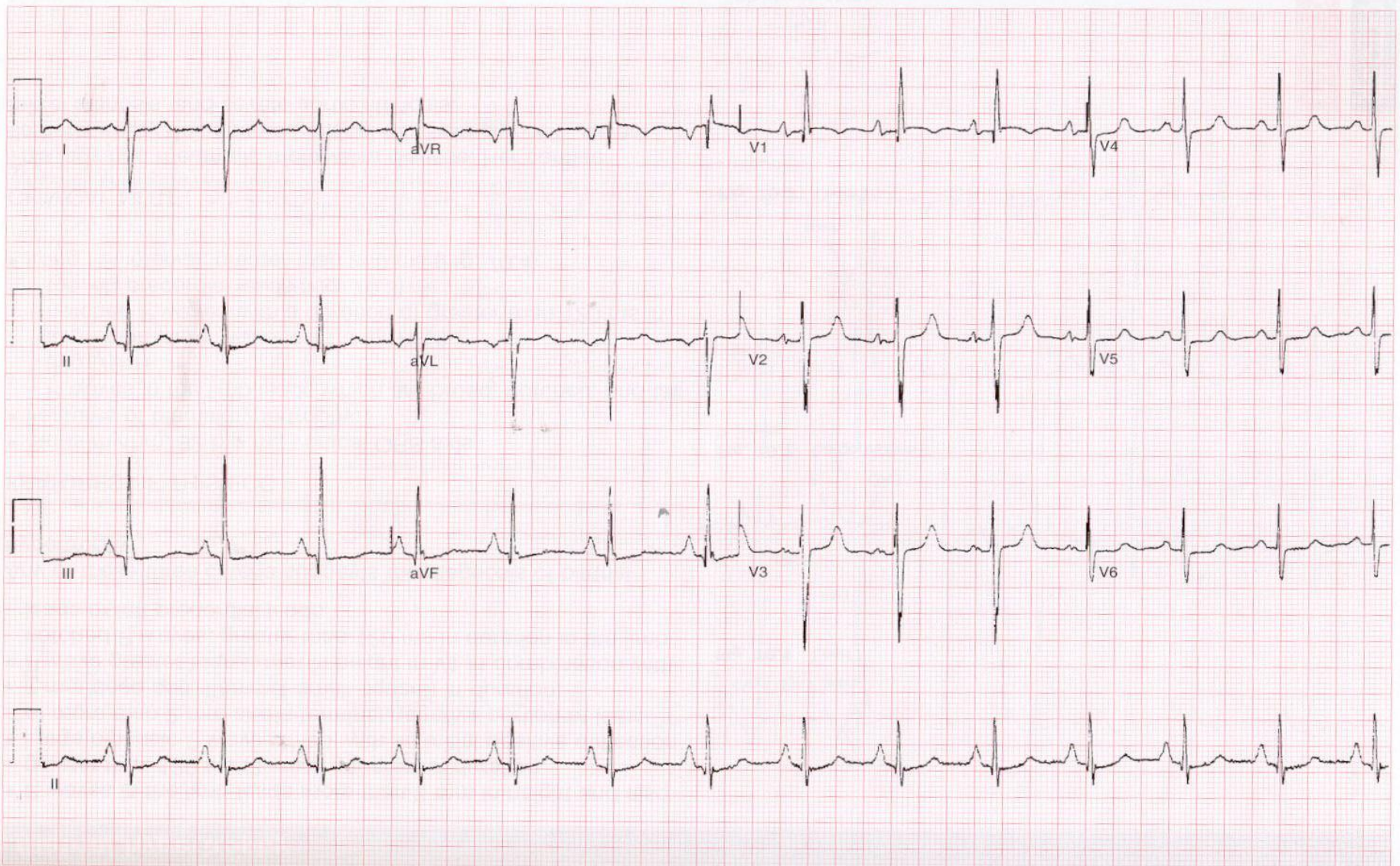
28



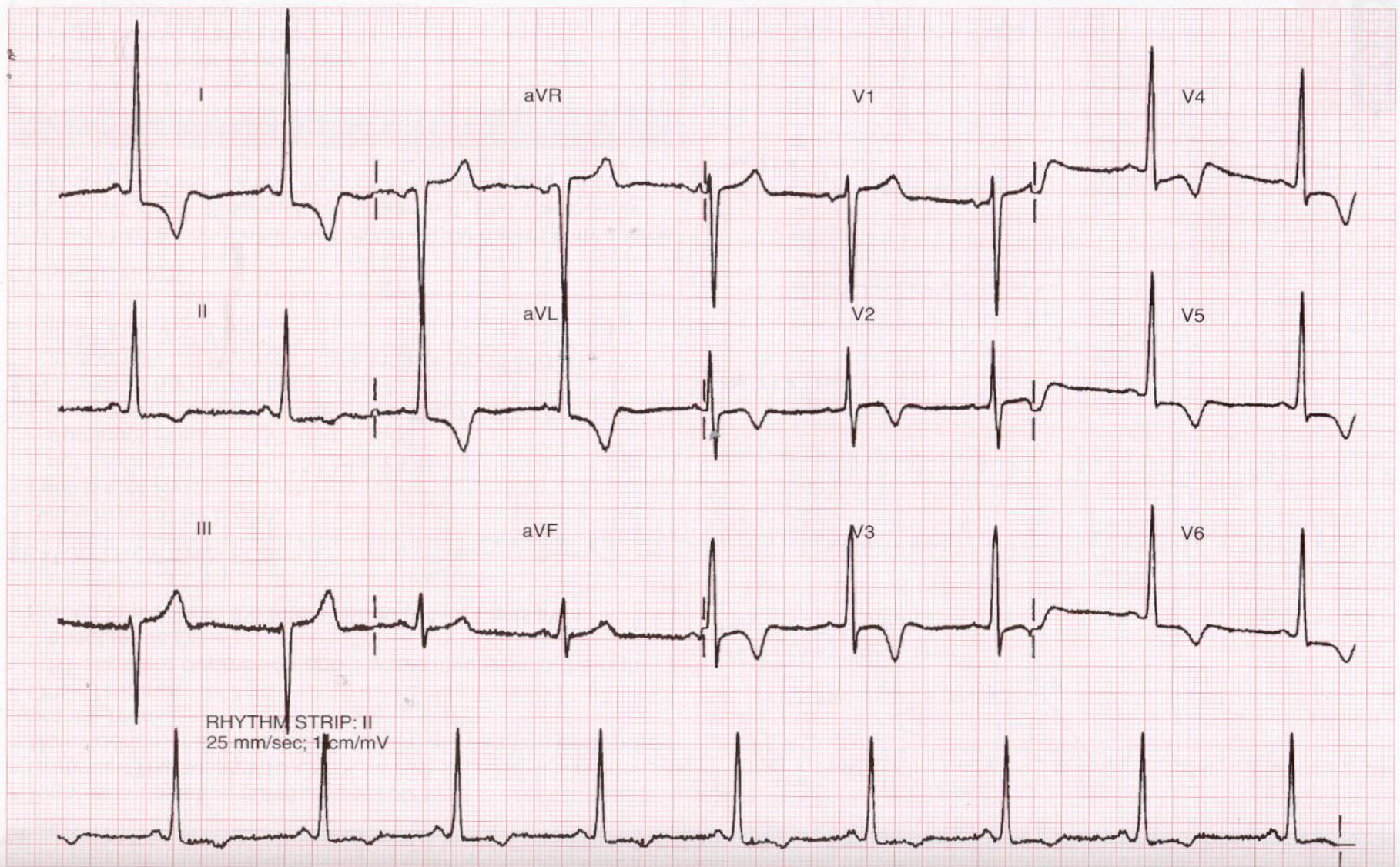
# 29



30

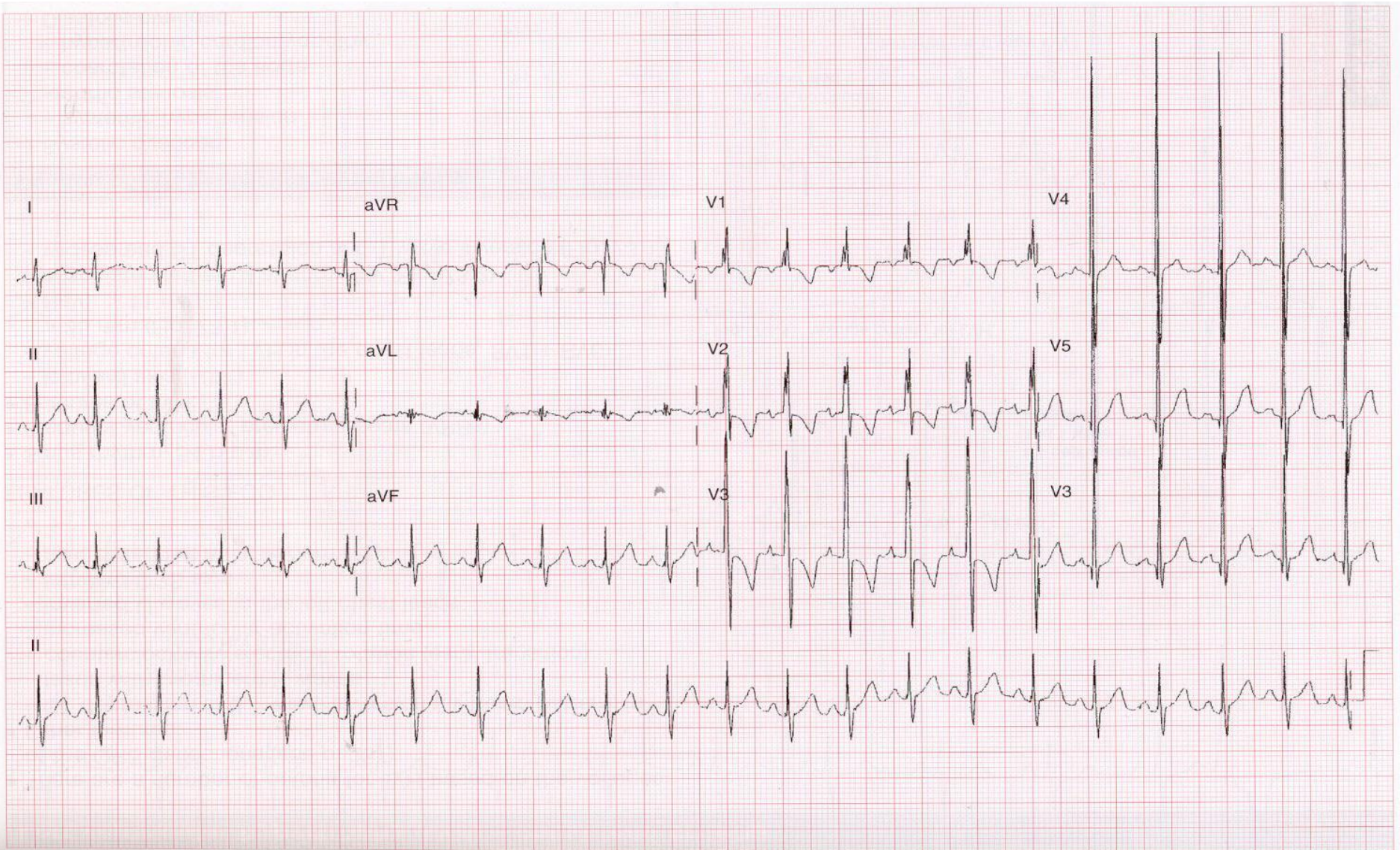


# 31

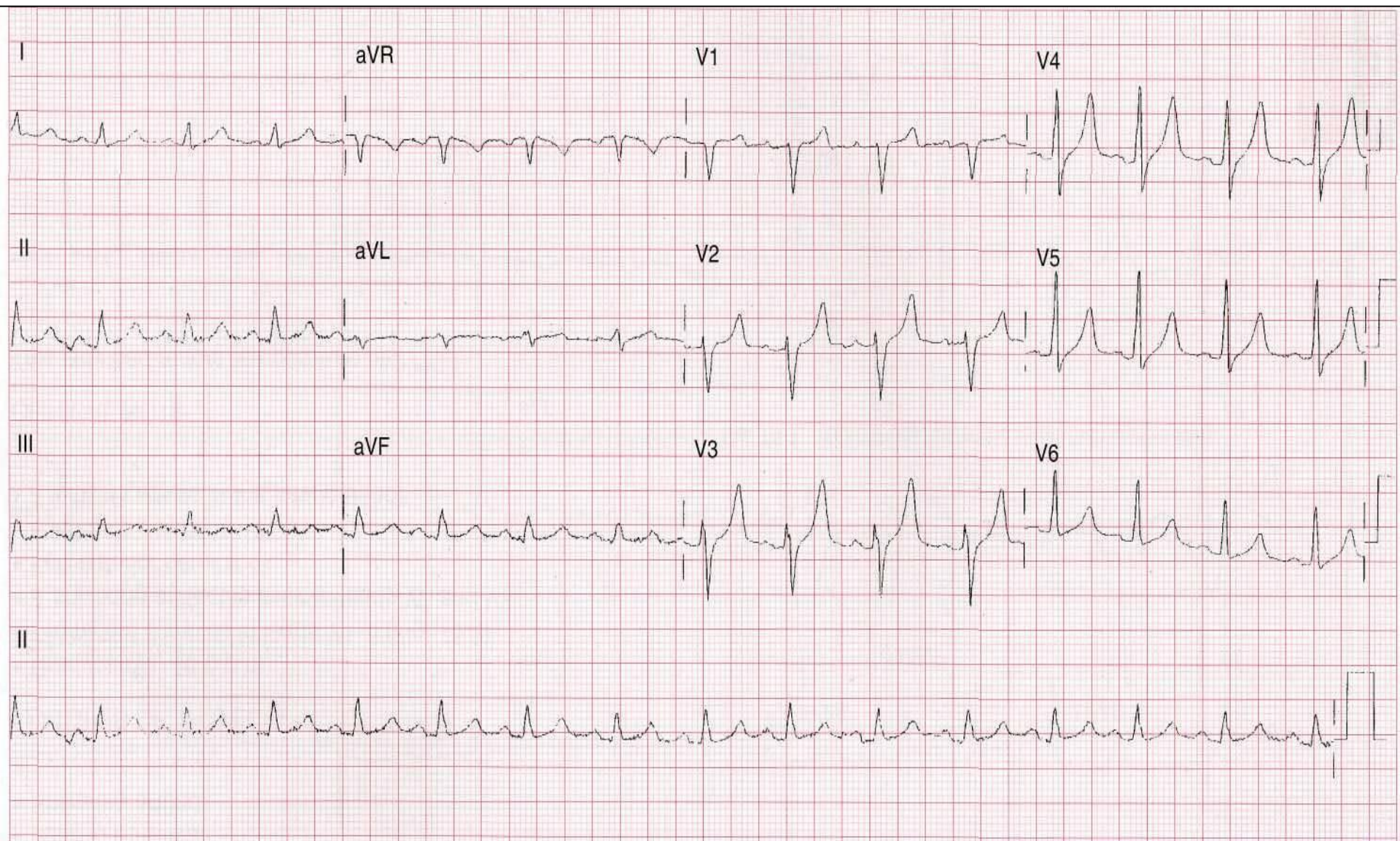




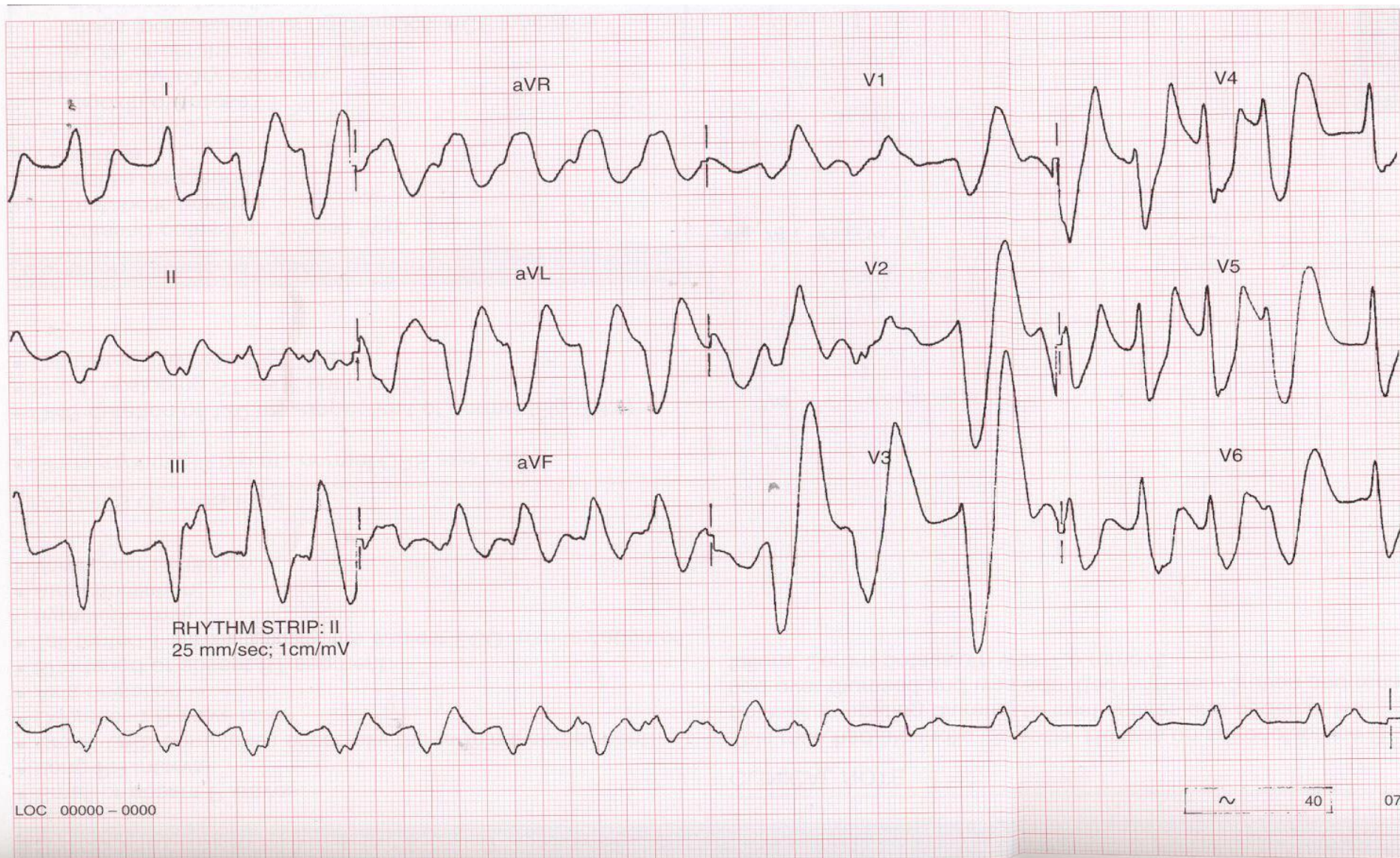
32



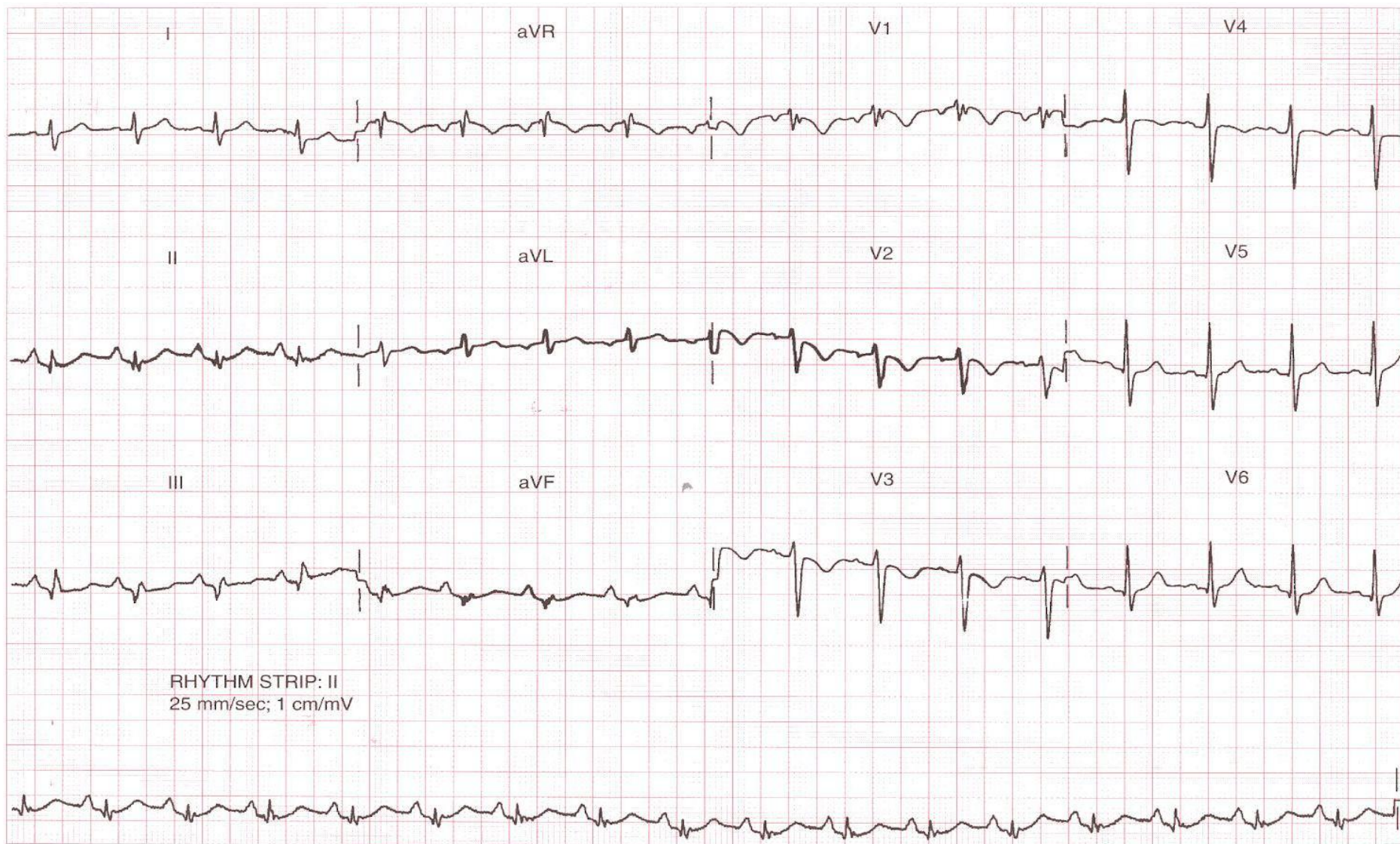
33



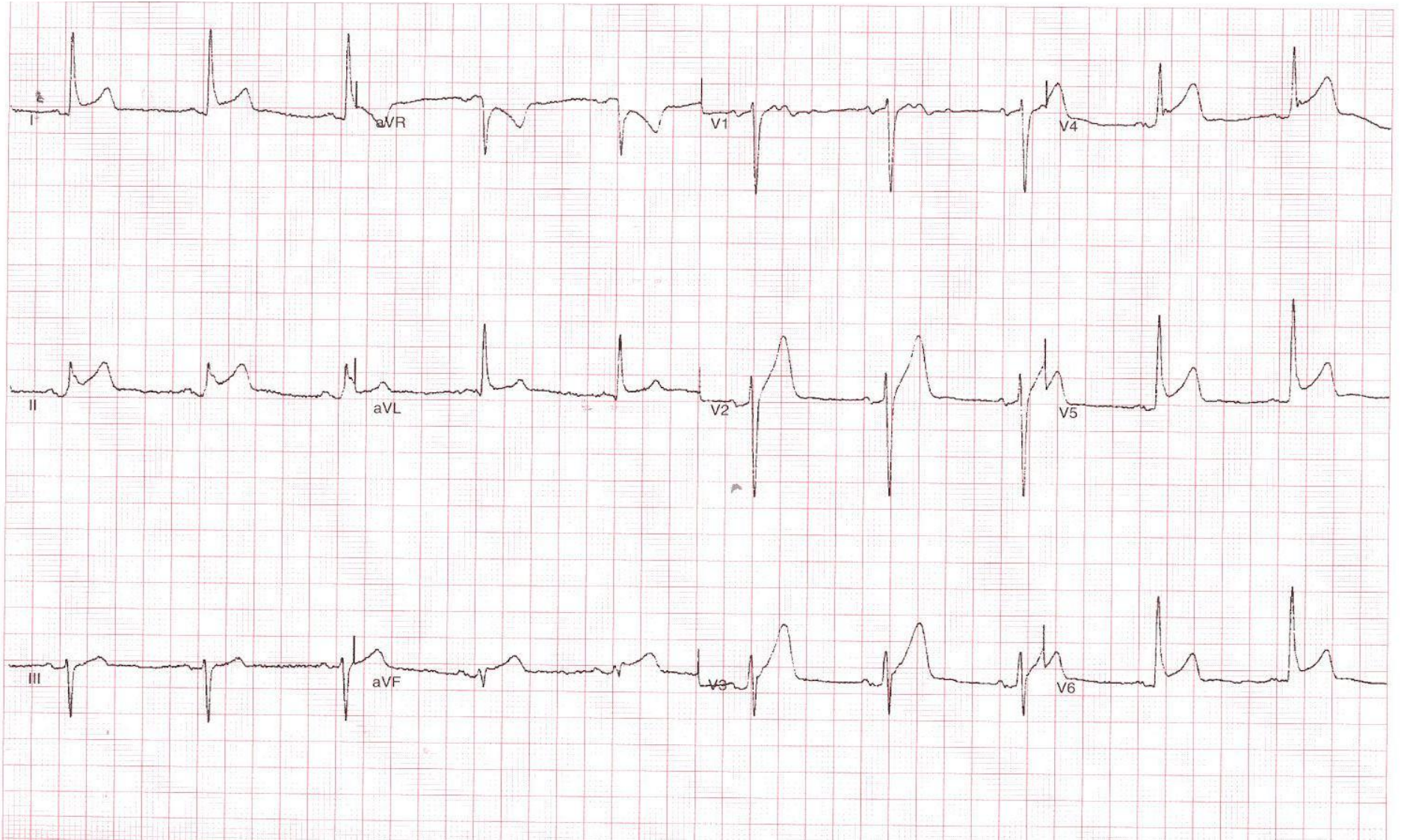
# 34



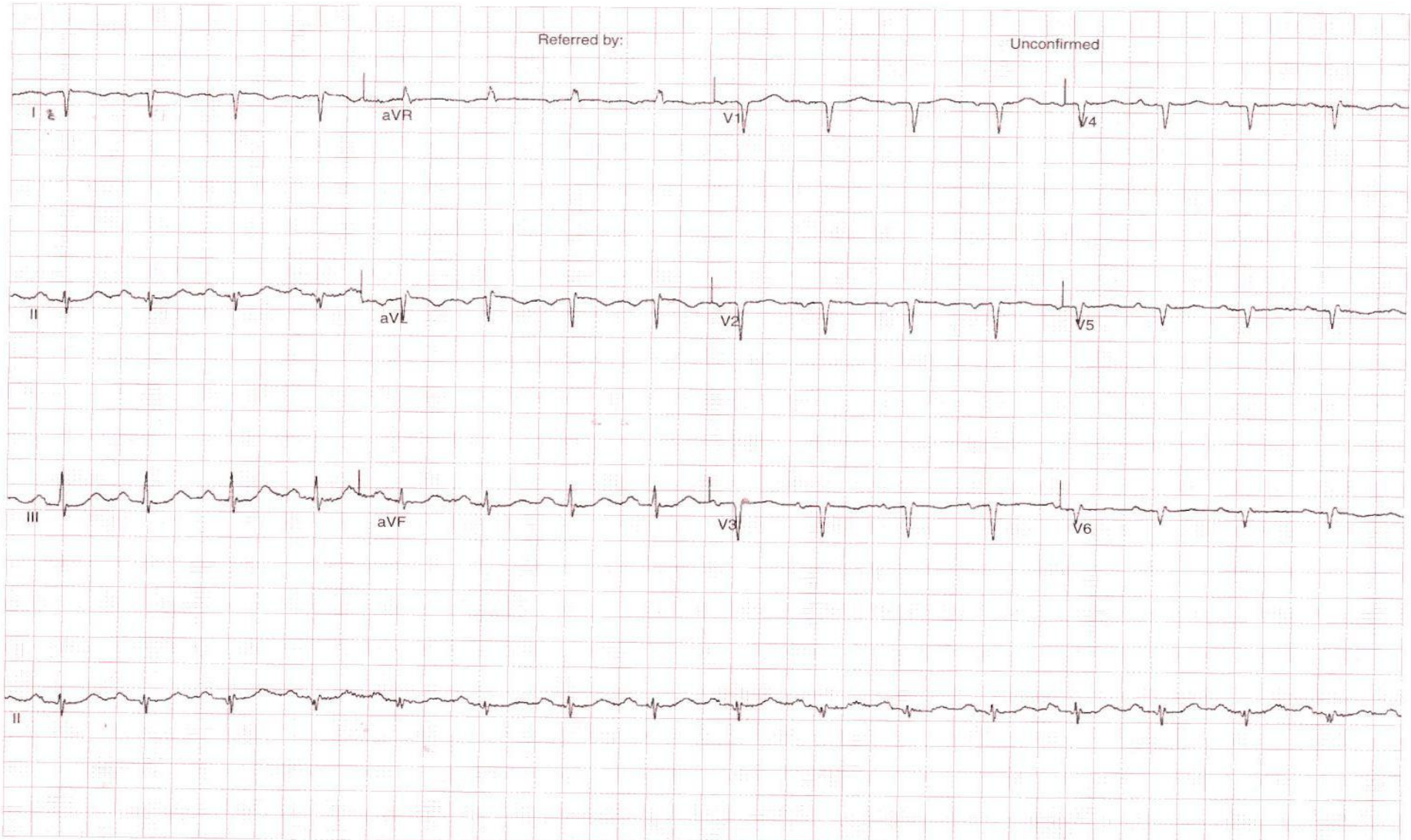
# 35



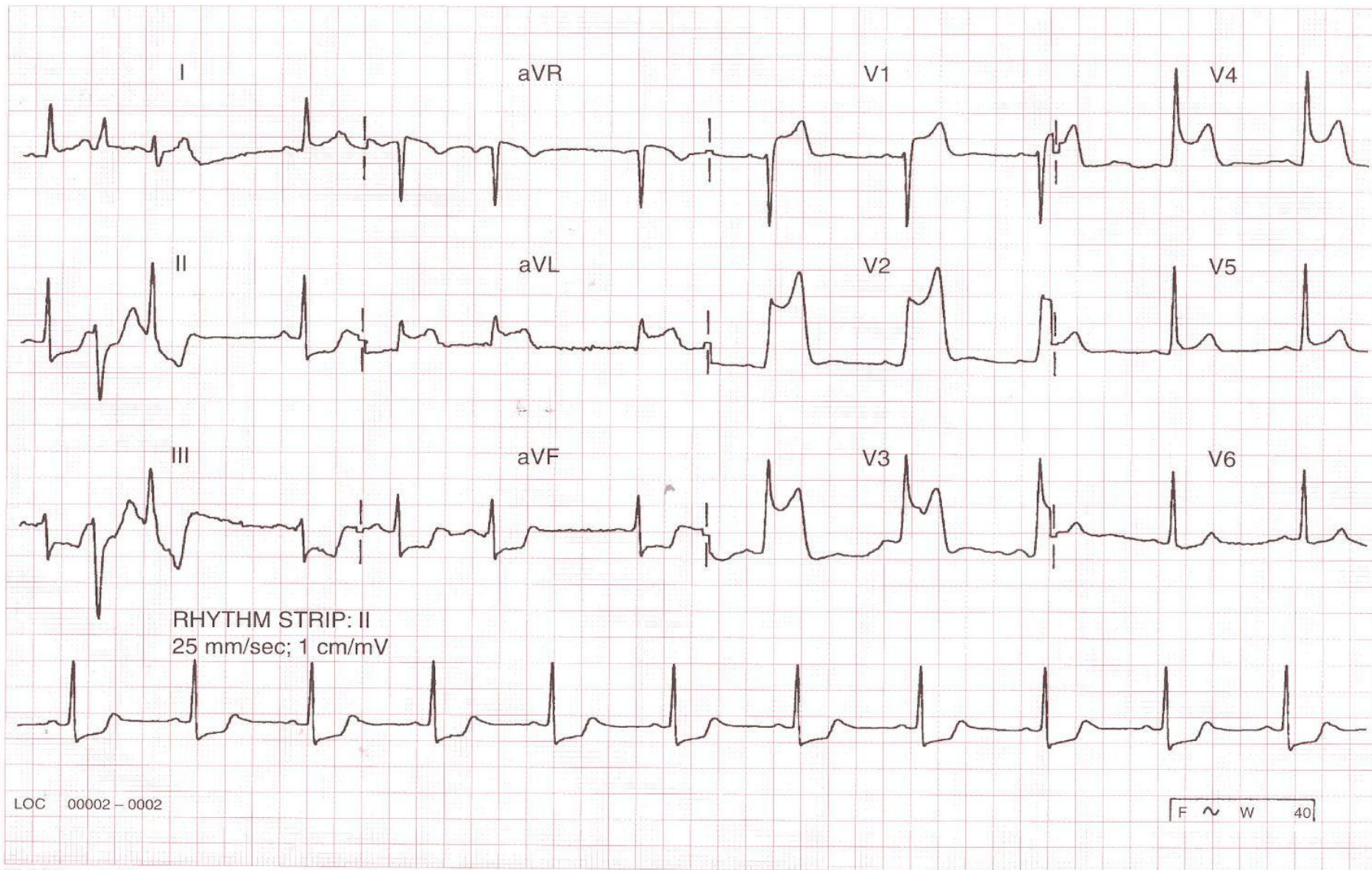
36



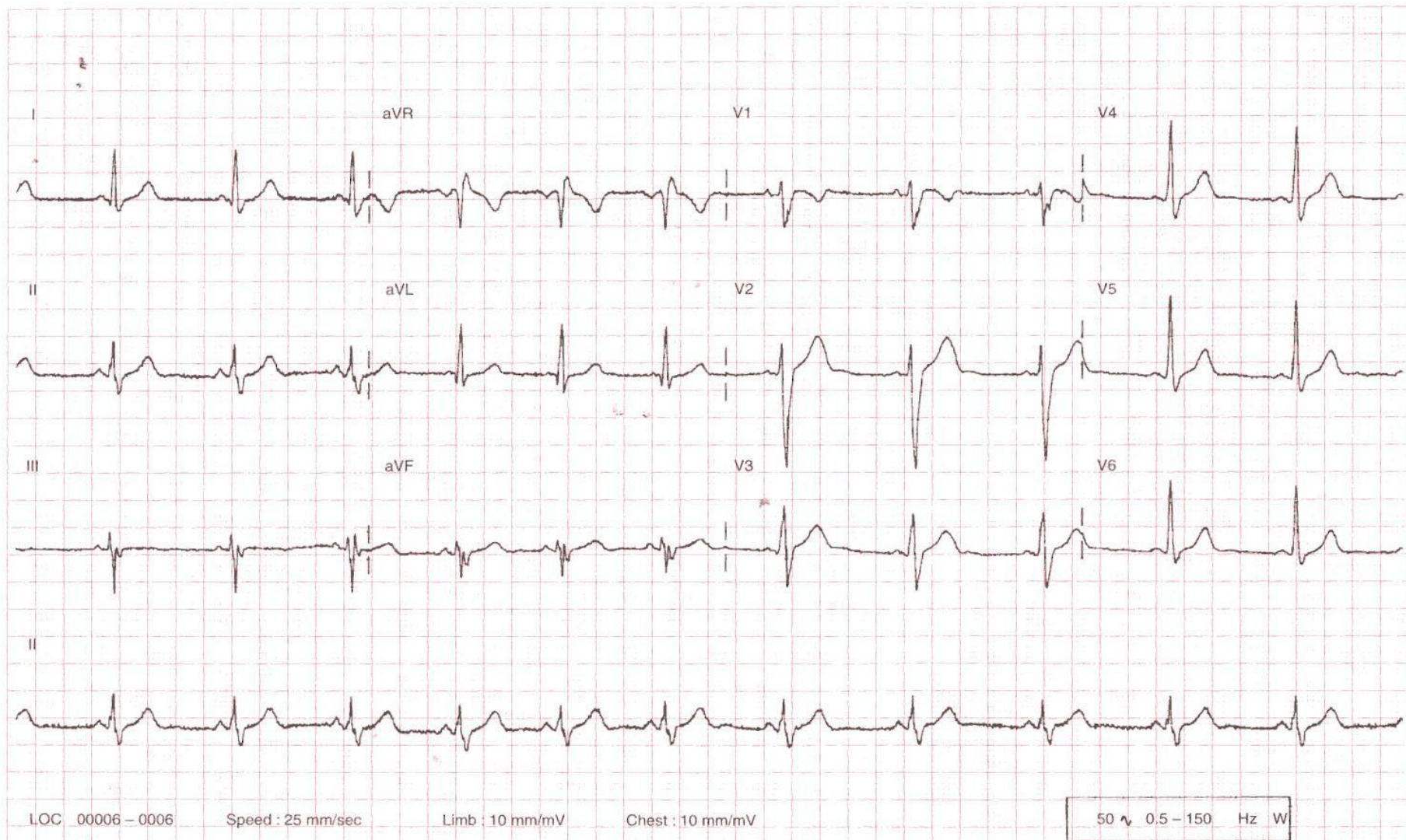
37



# 38

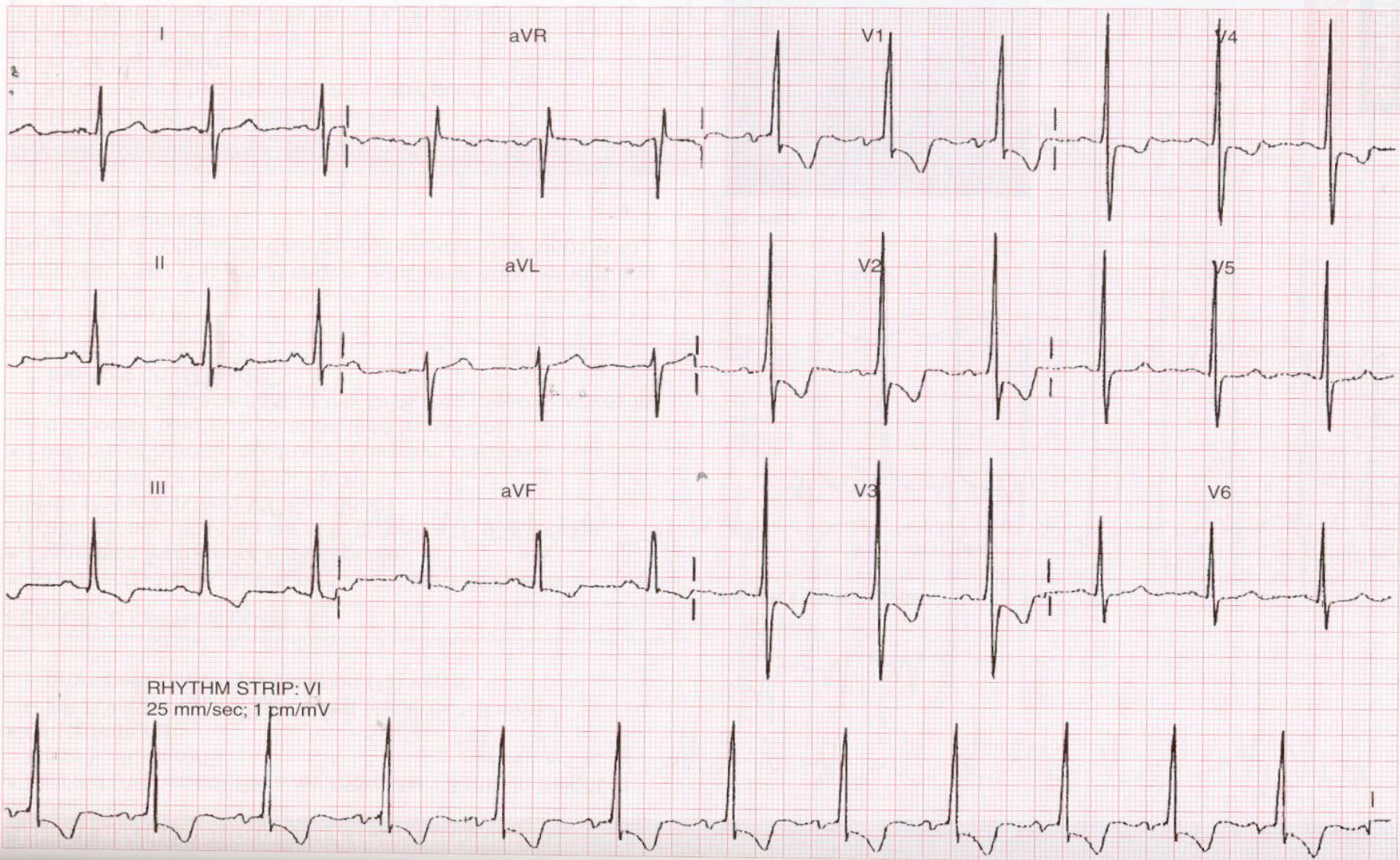


# 39

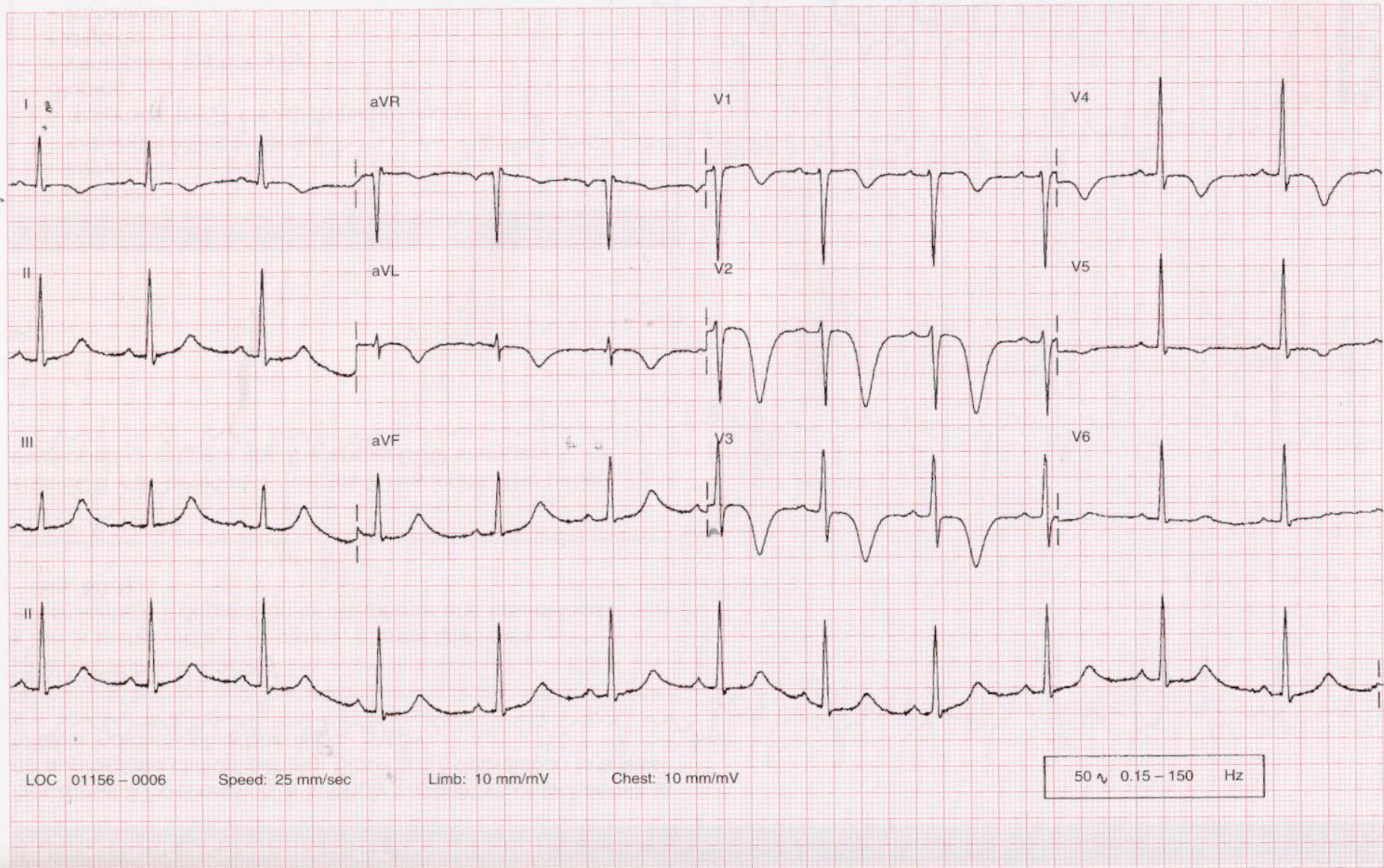




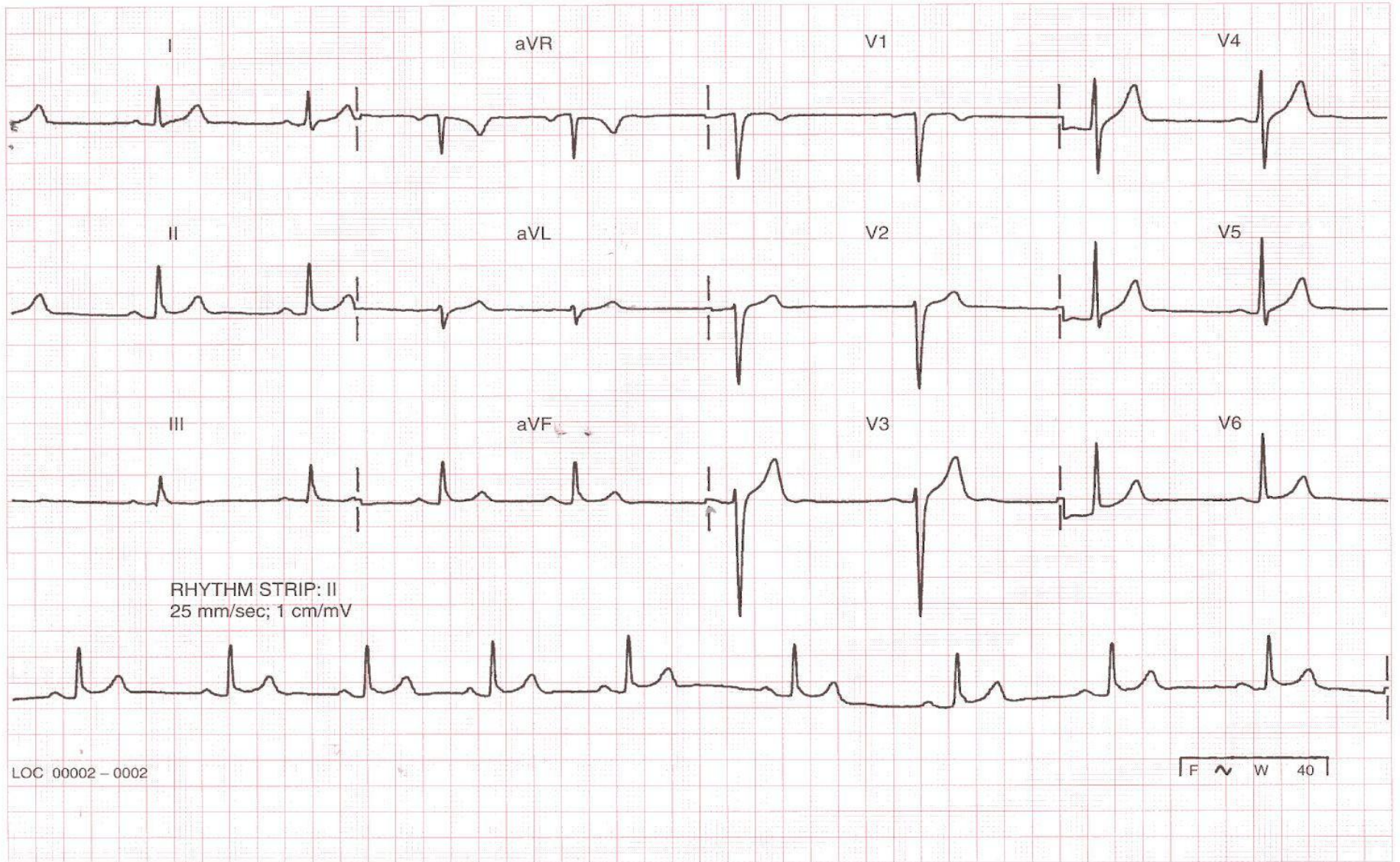
# 40



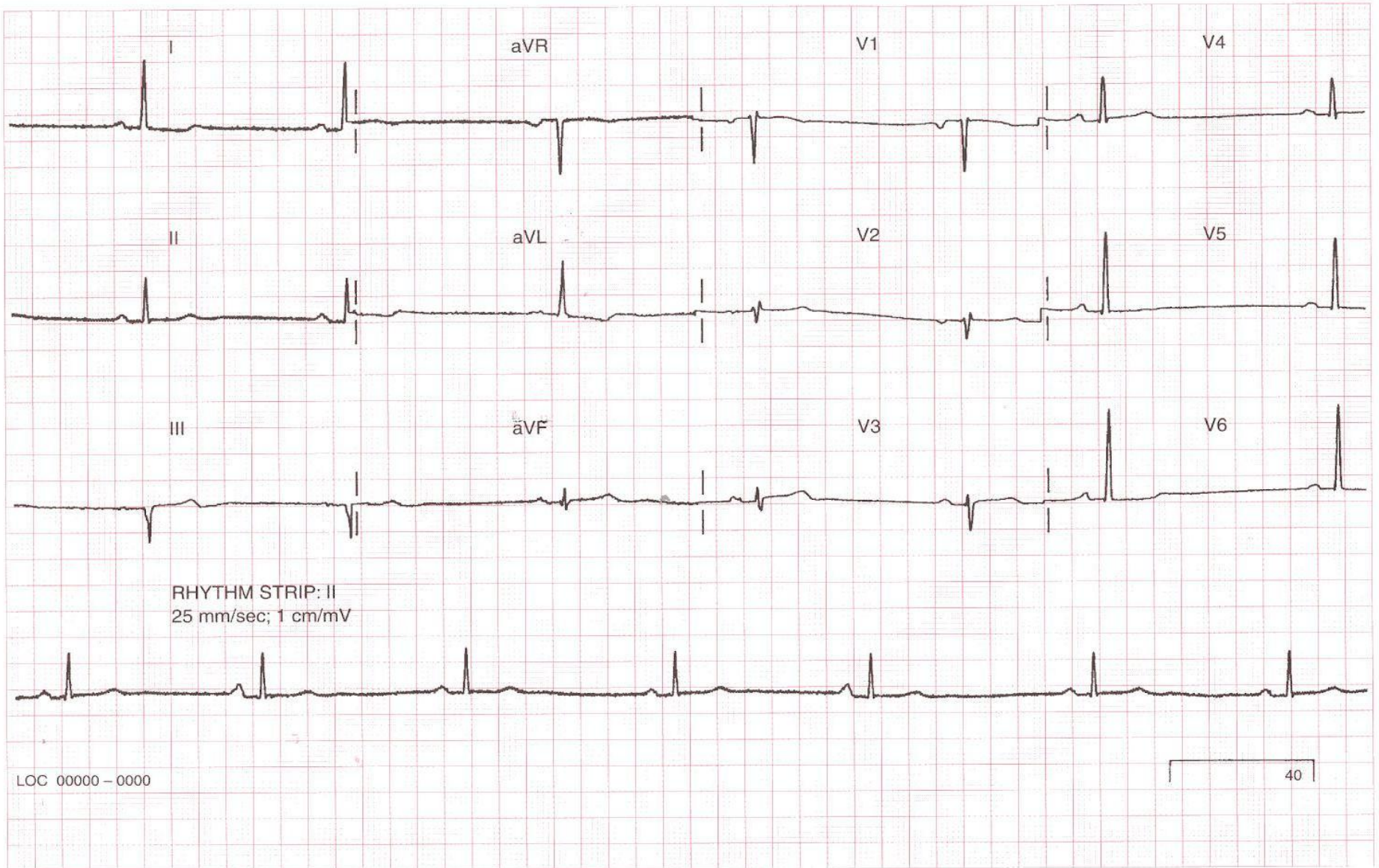
# 41



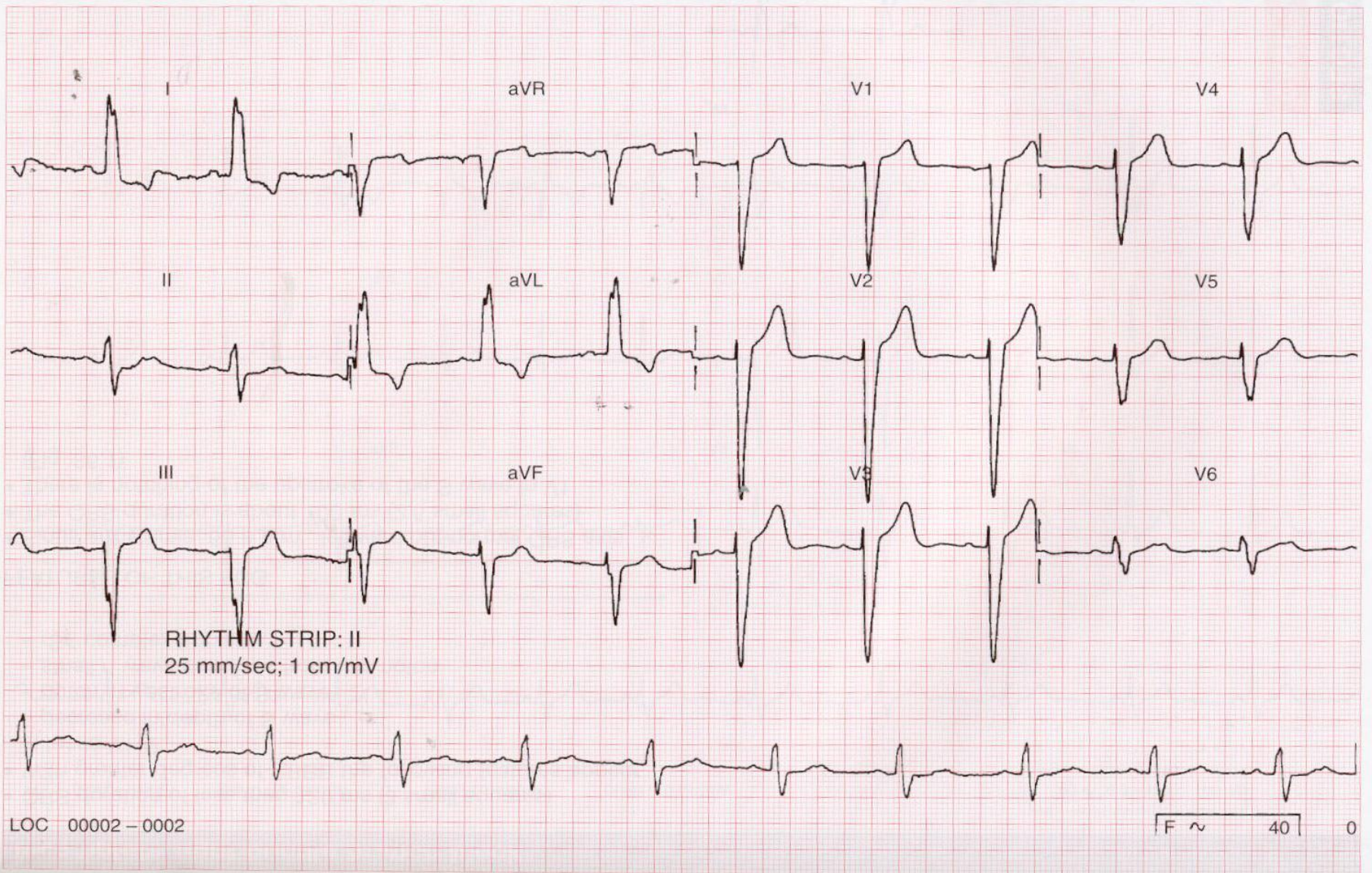
# 42



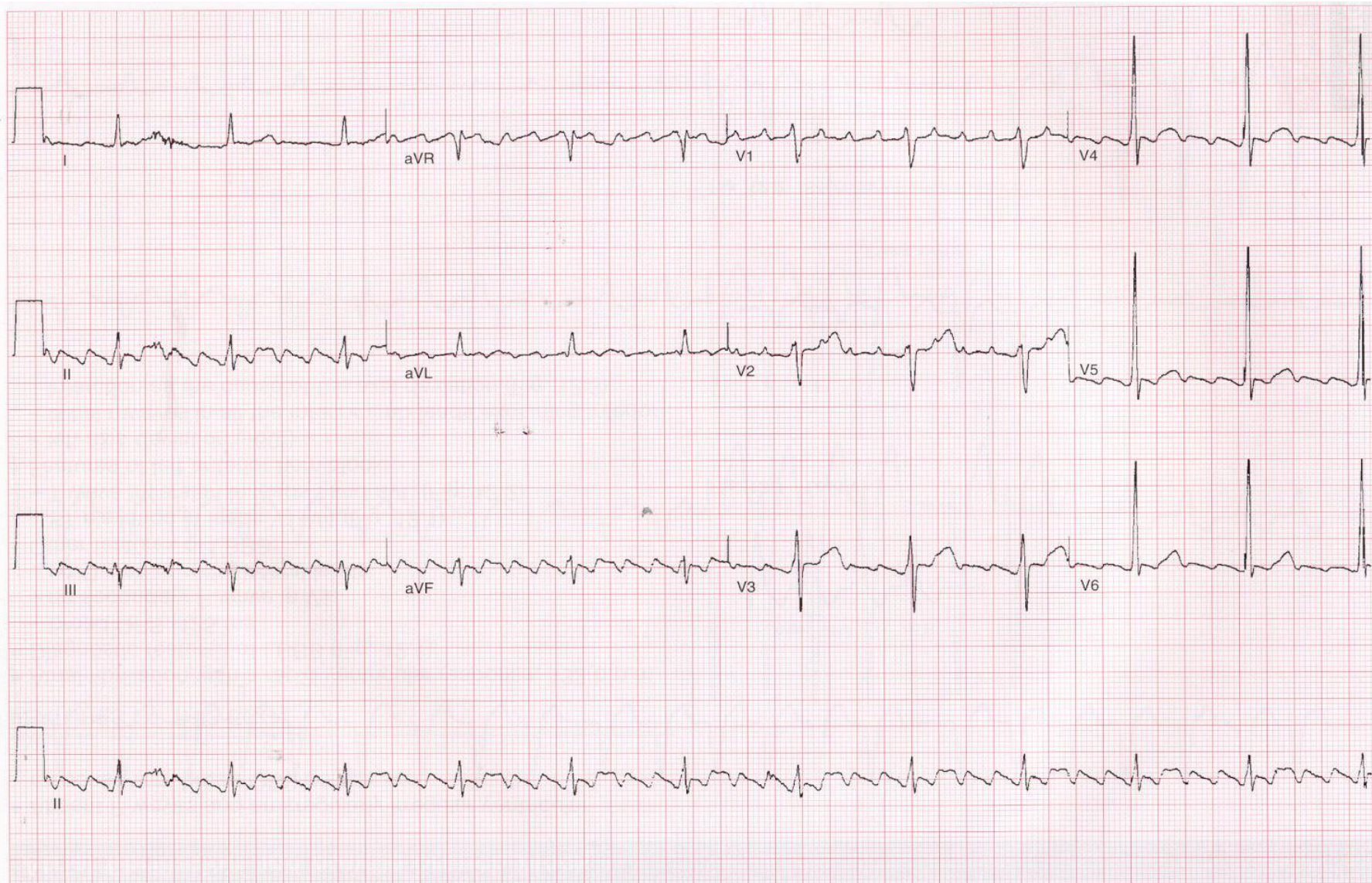
# 43



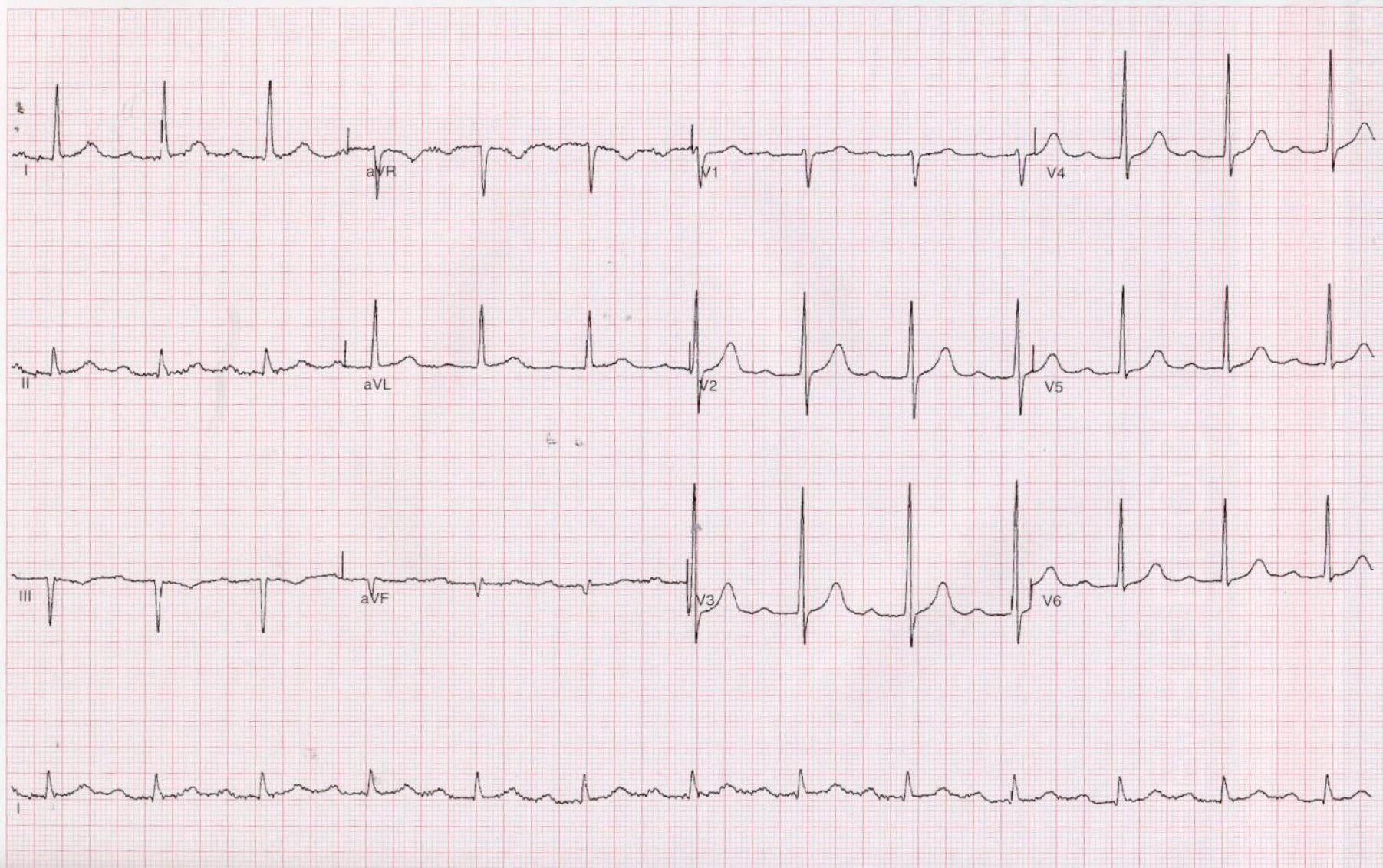
44



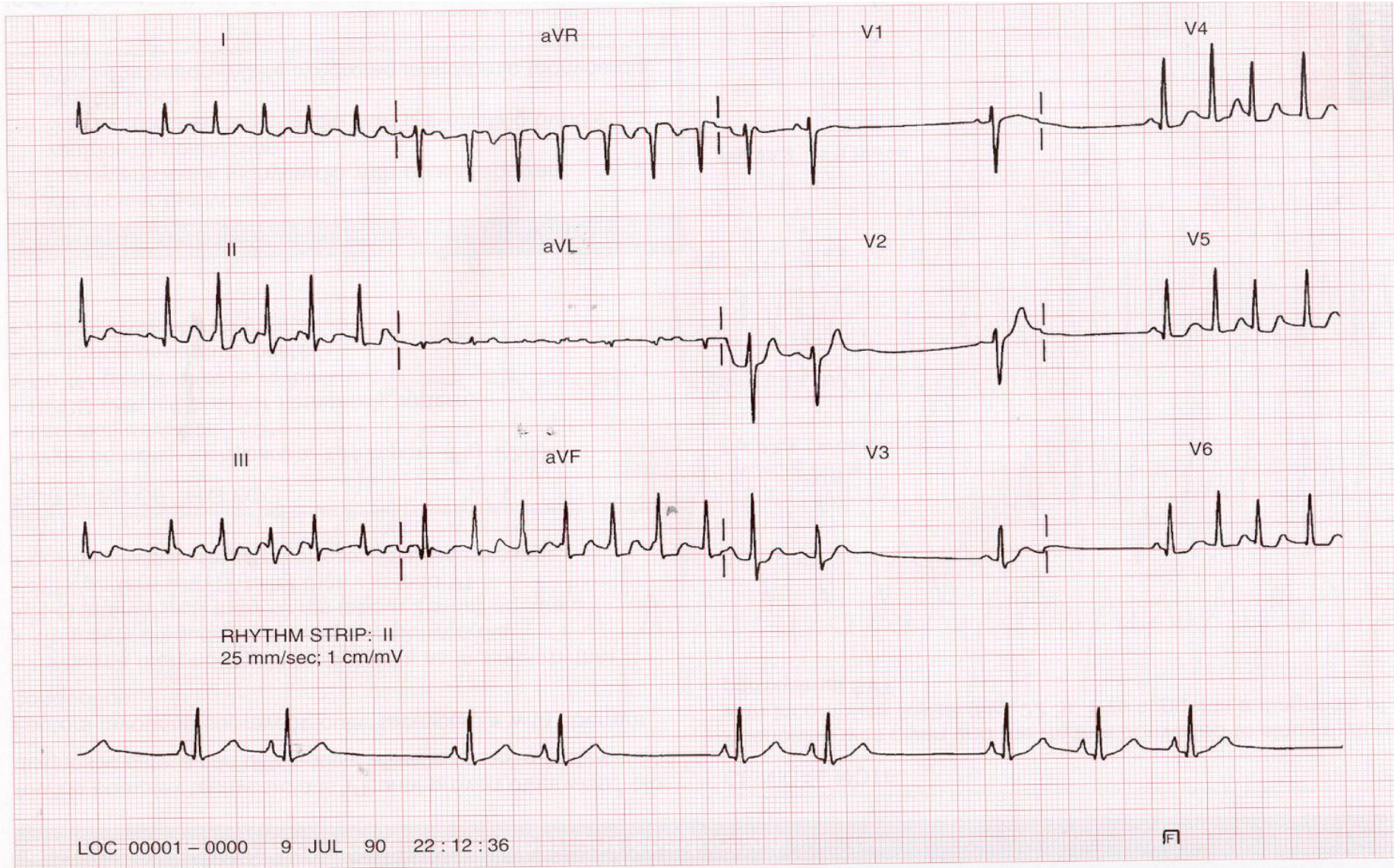
45



46

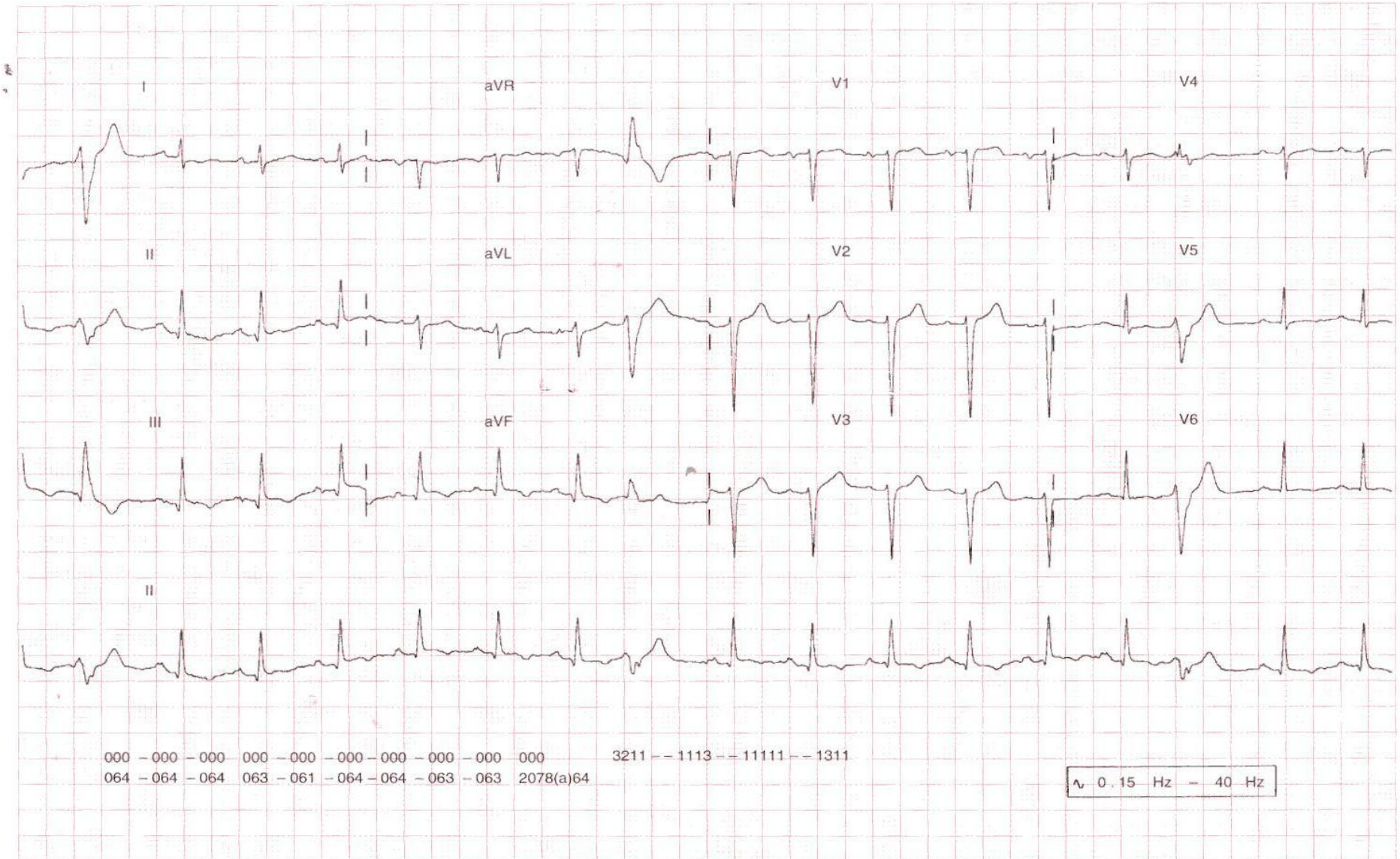


# 47

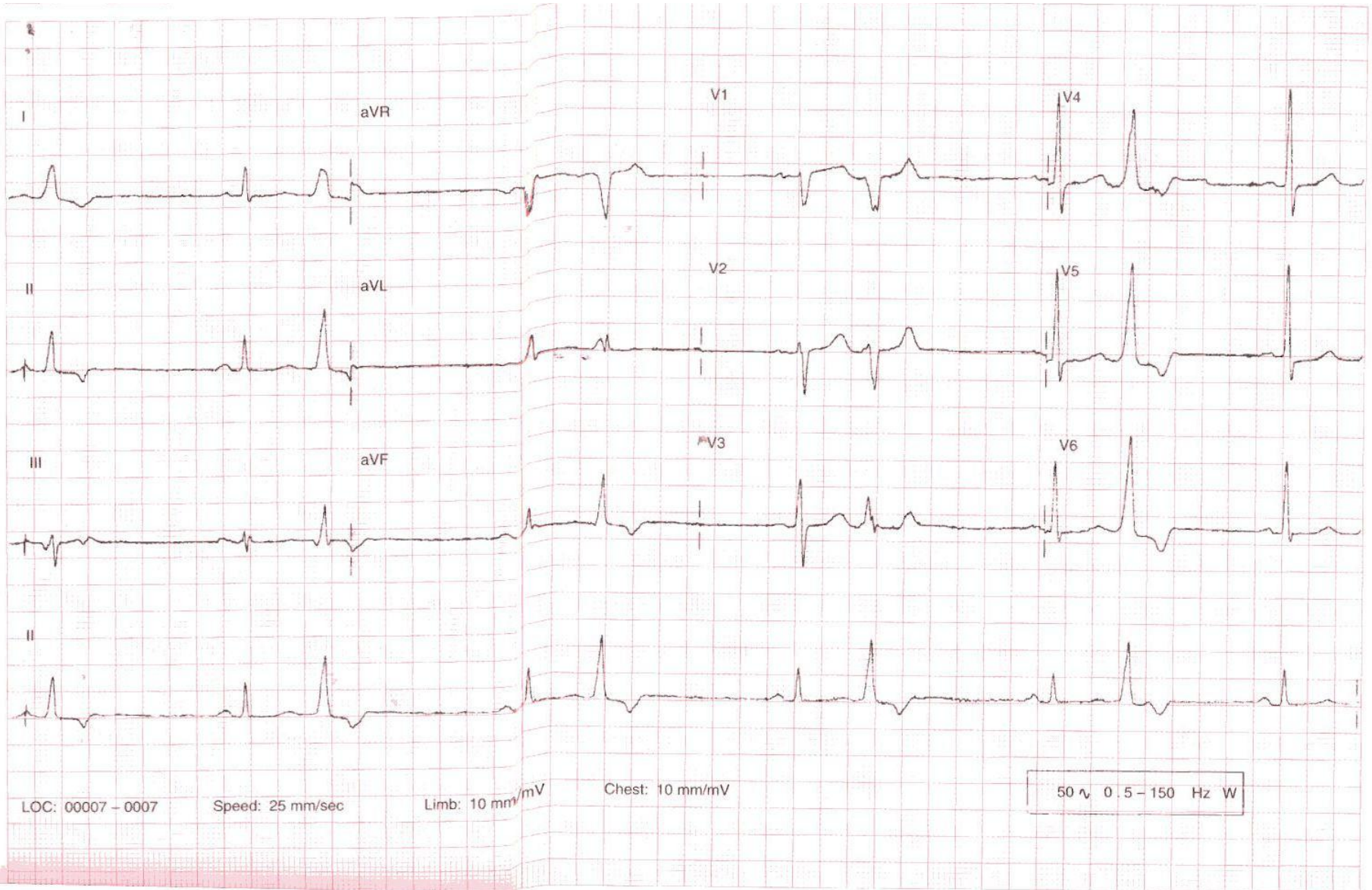




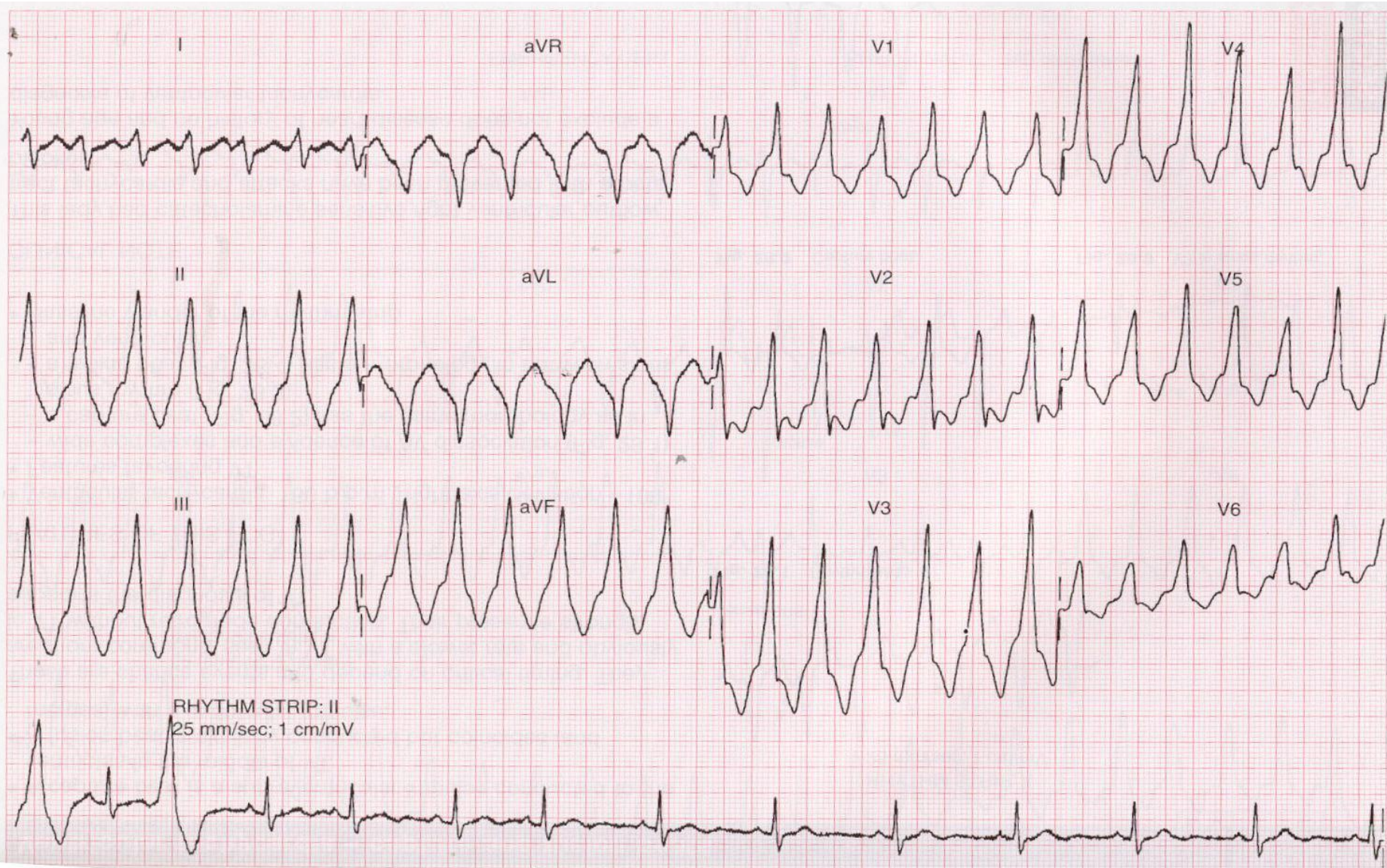
# 48



# 49

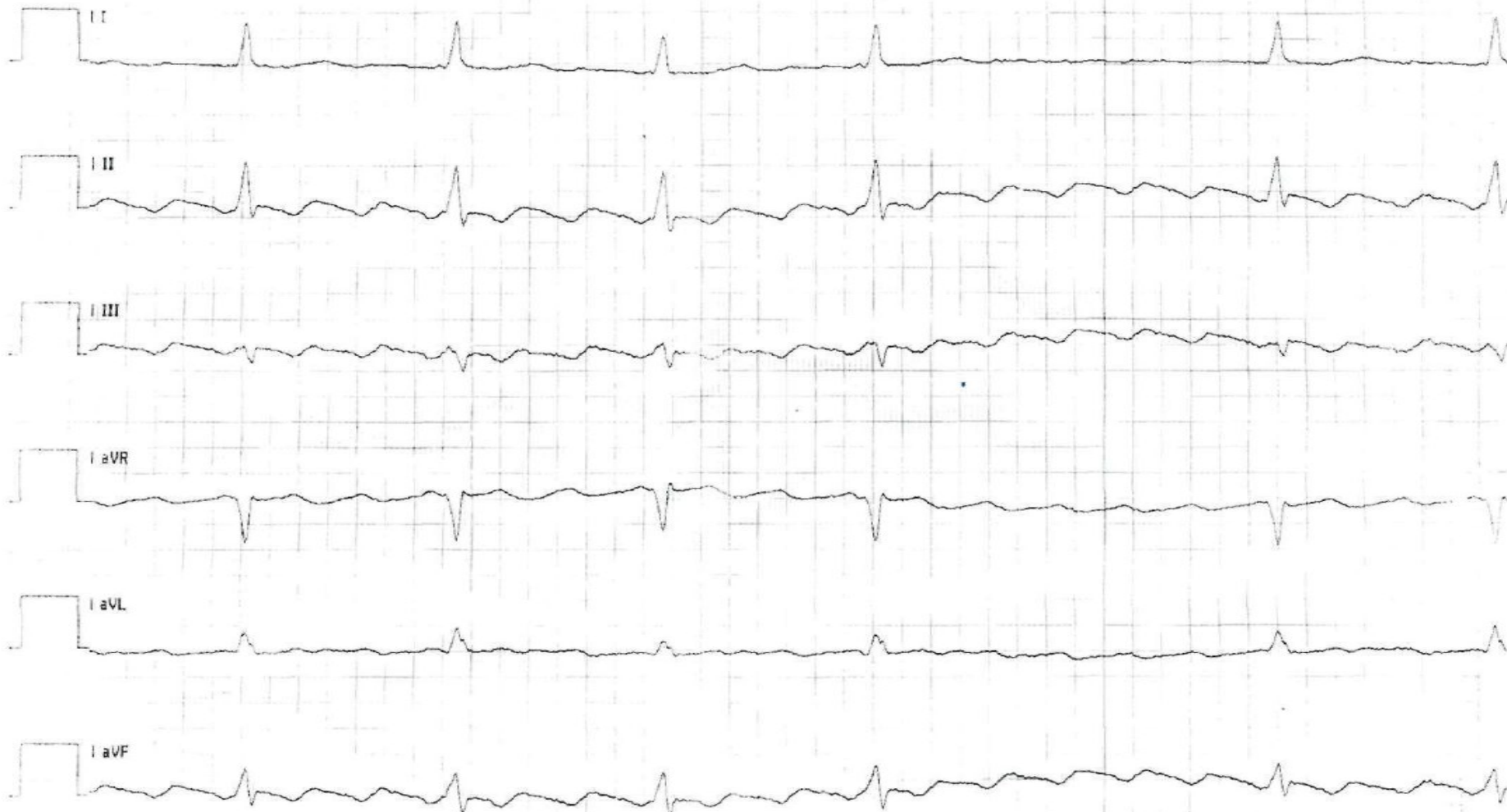

50



# 51

Reviewed by:

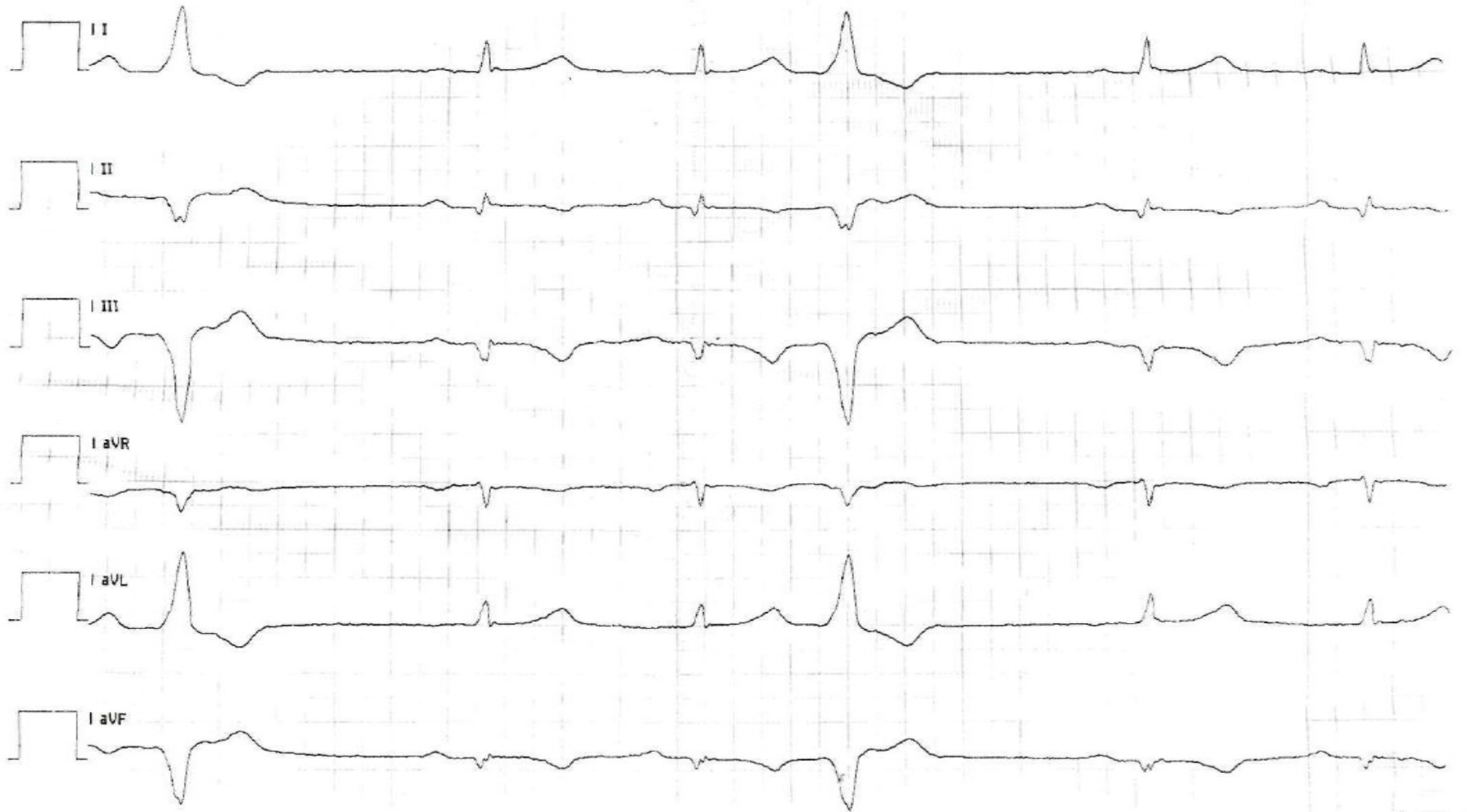


# 52

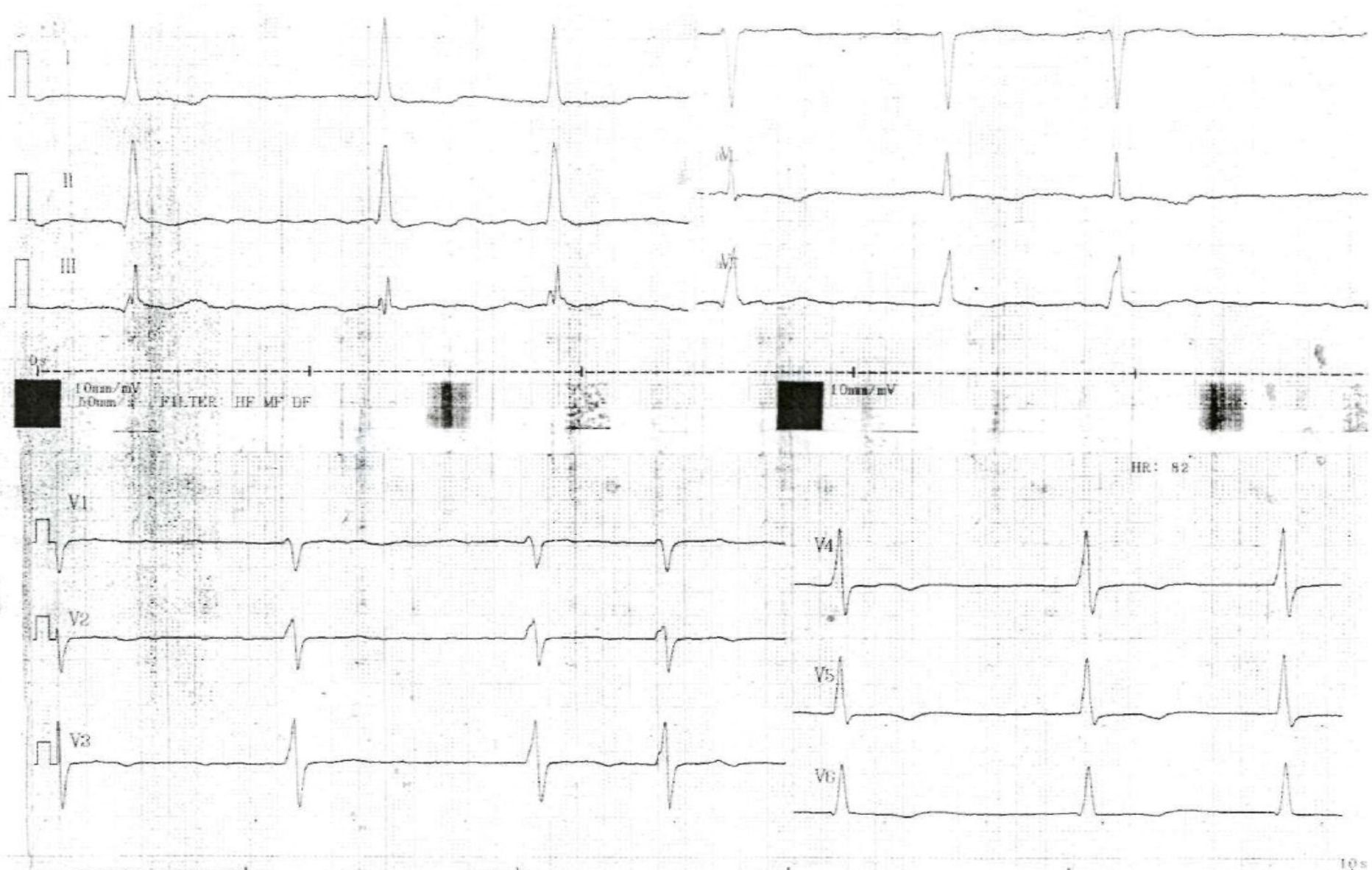
?yr ?cm ?kg

Meds:  
Location:

PR int:  
QRS dur:  
QT/QTc:  
P-QRS-T axes:  
Reviewed by:



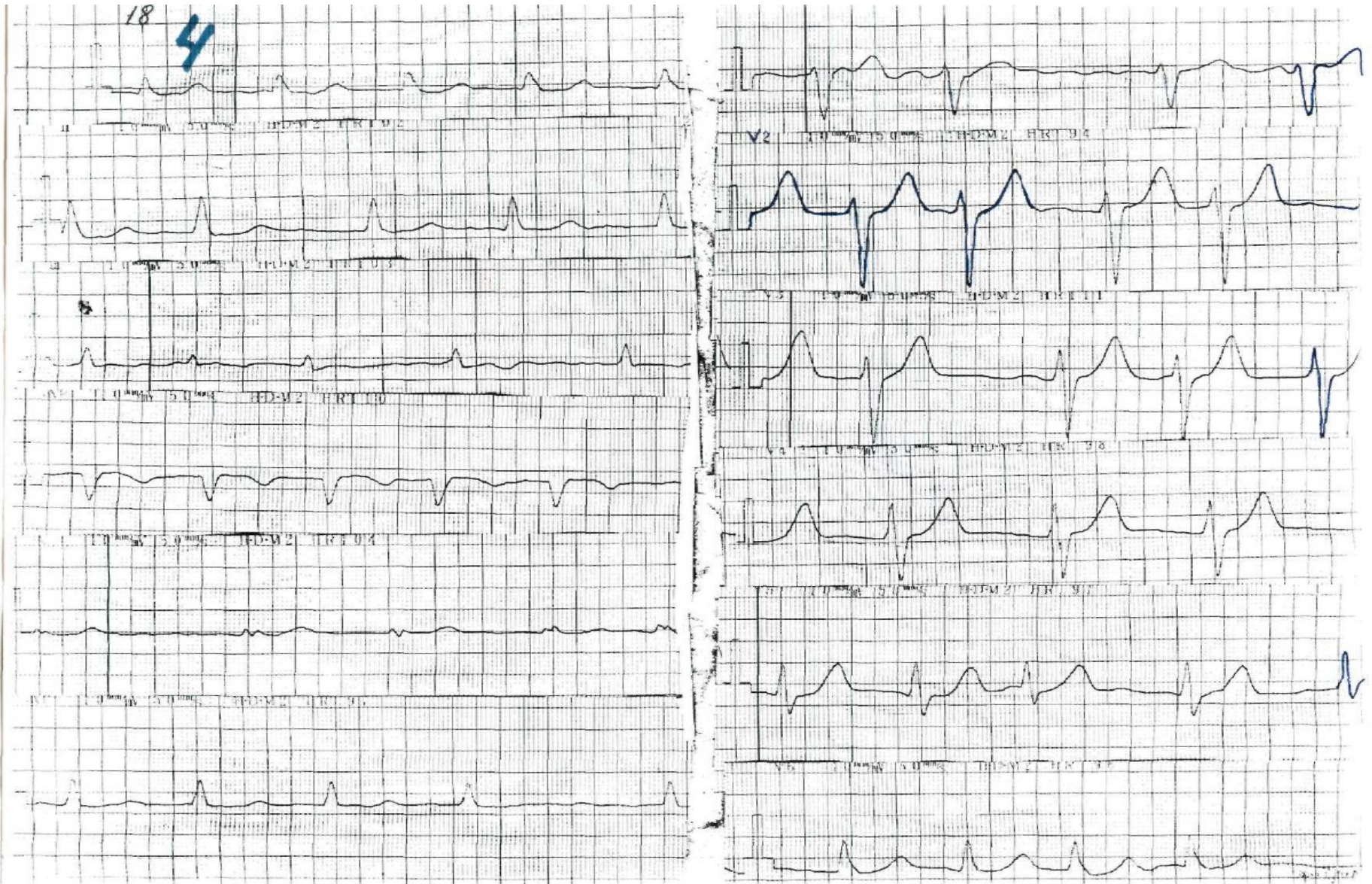
# 53

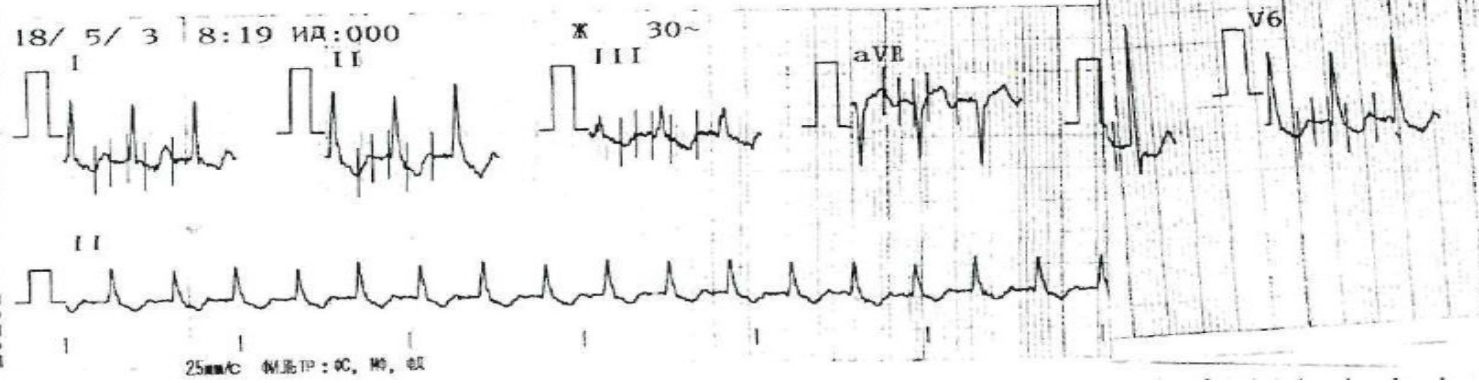
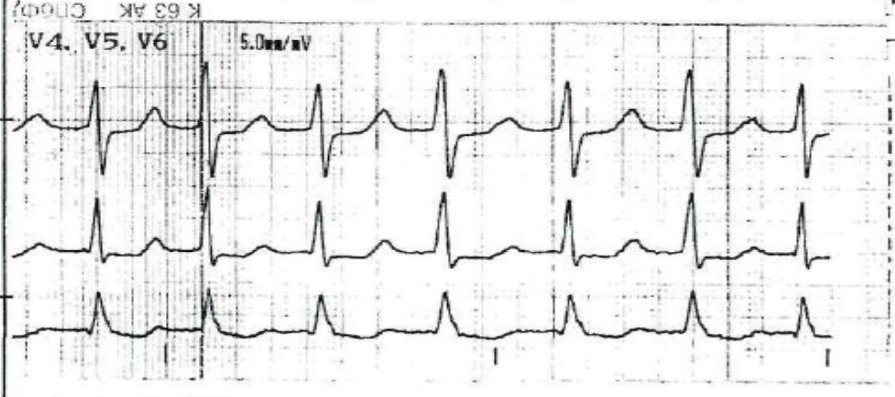
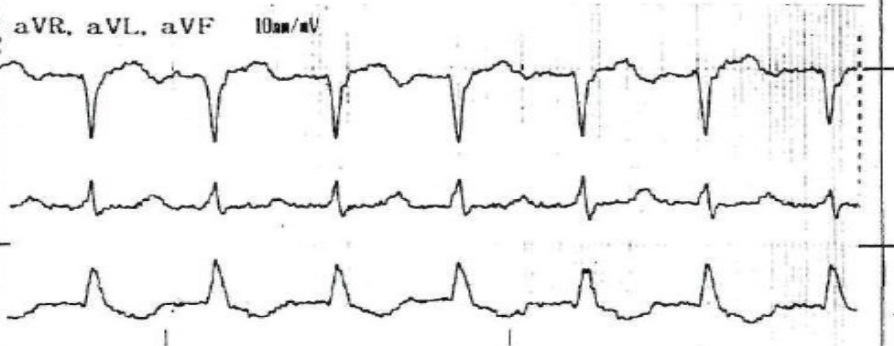
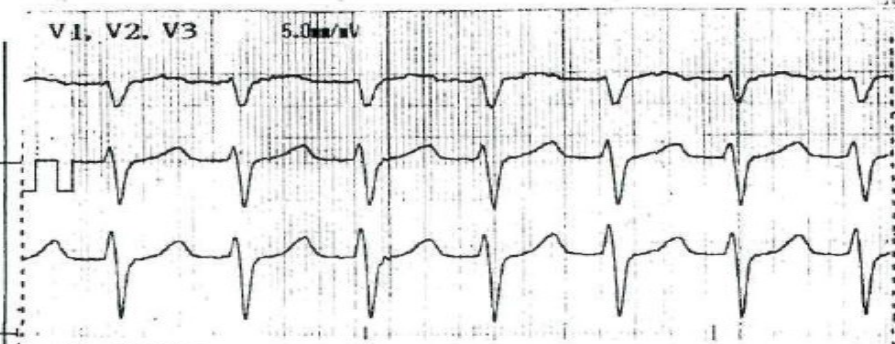
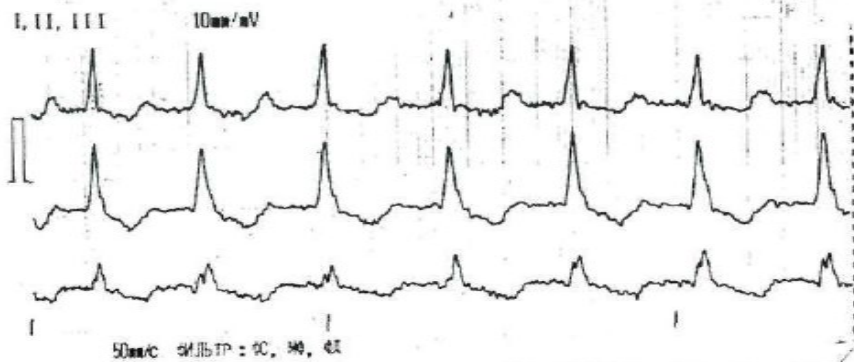


54

18

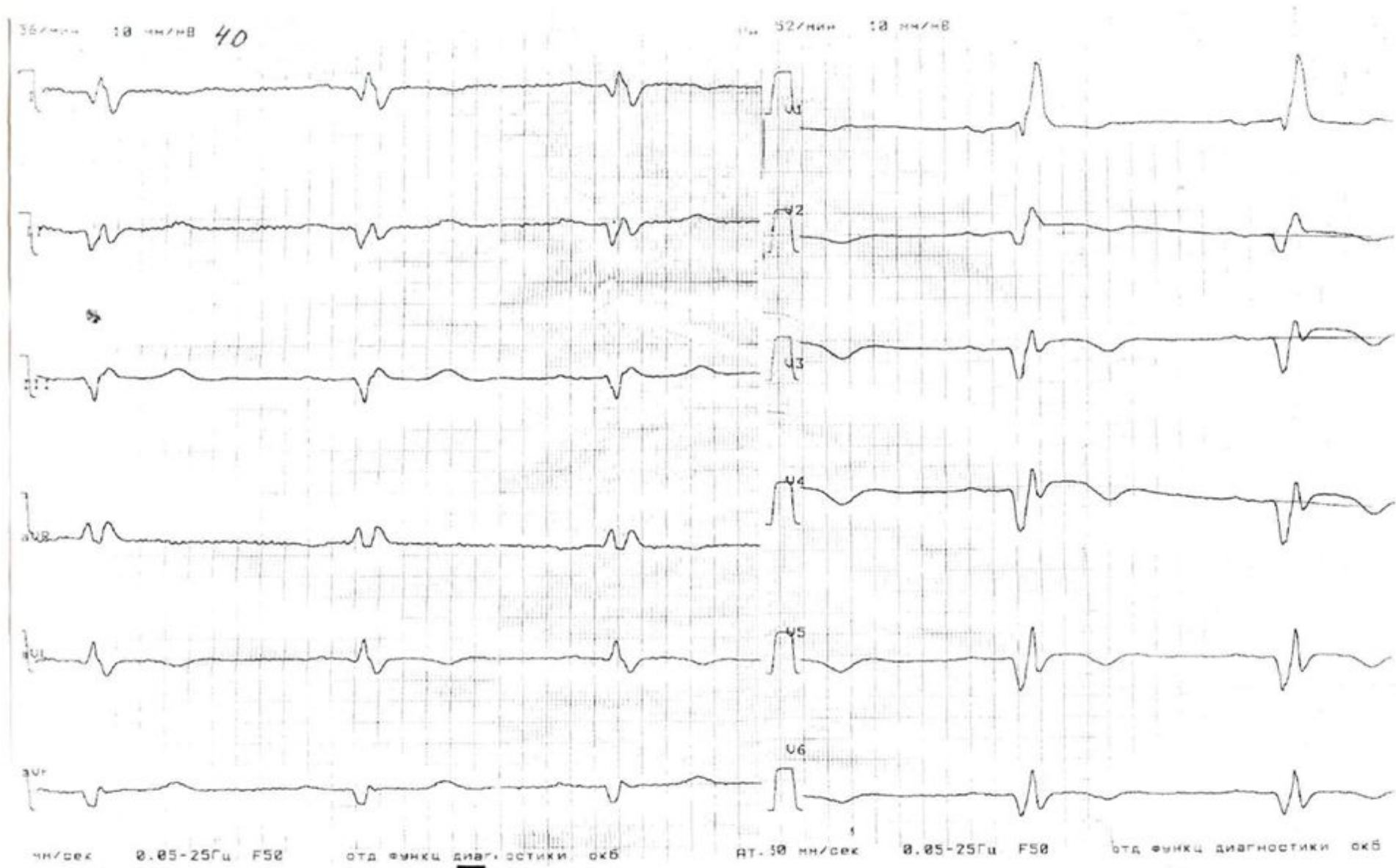4



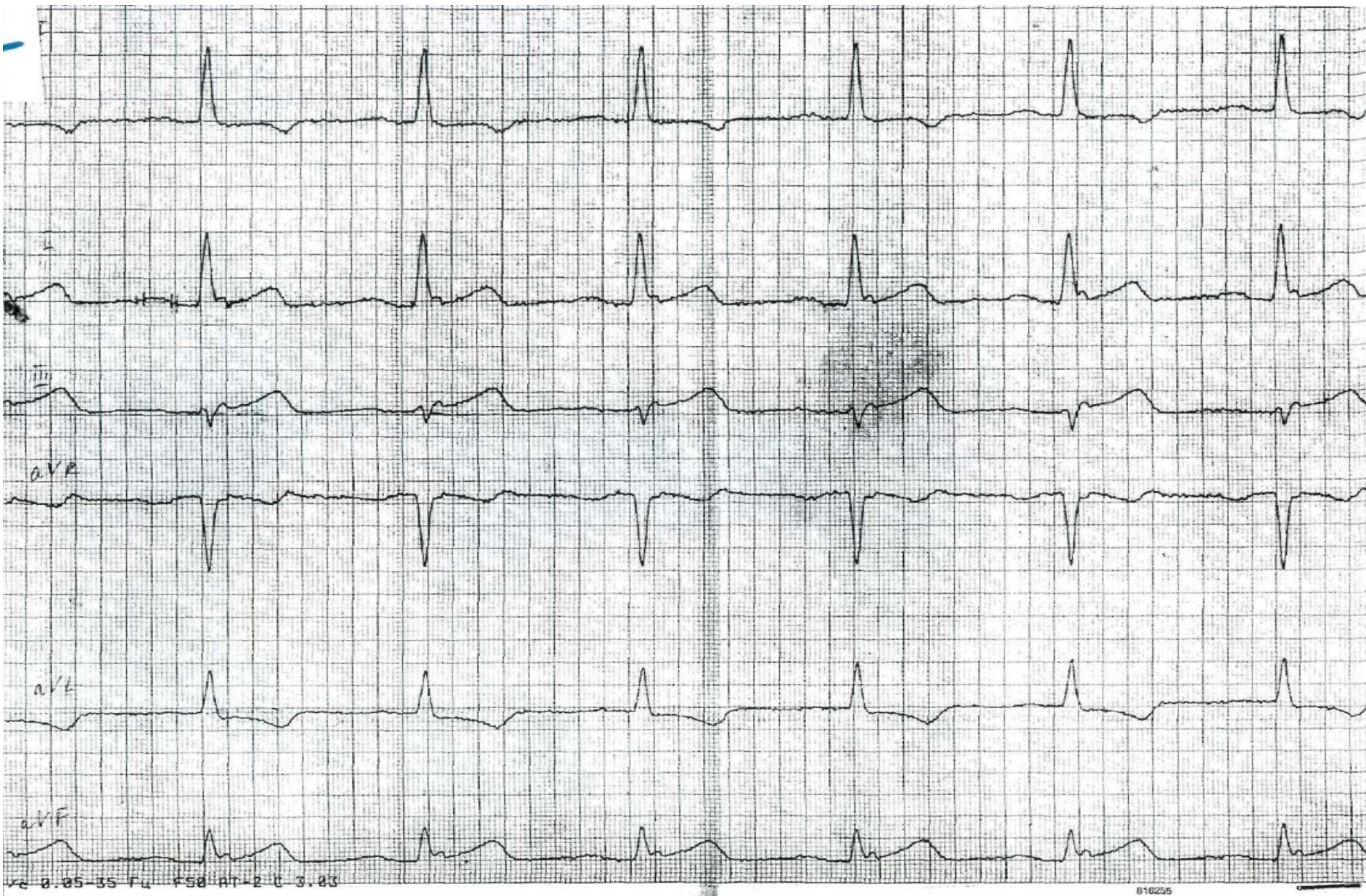




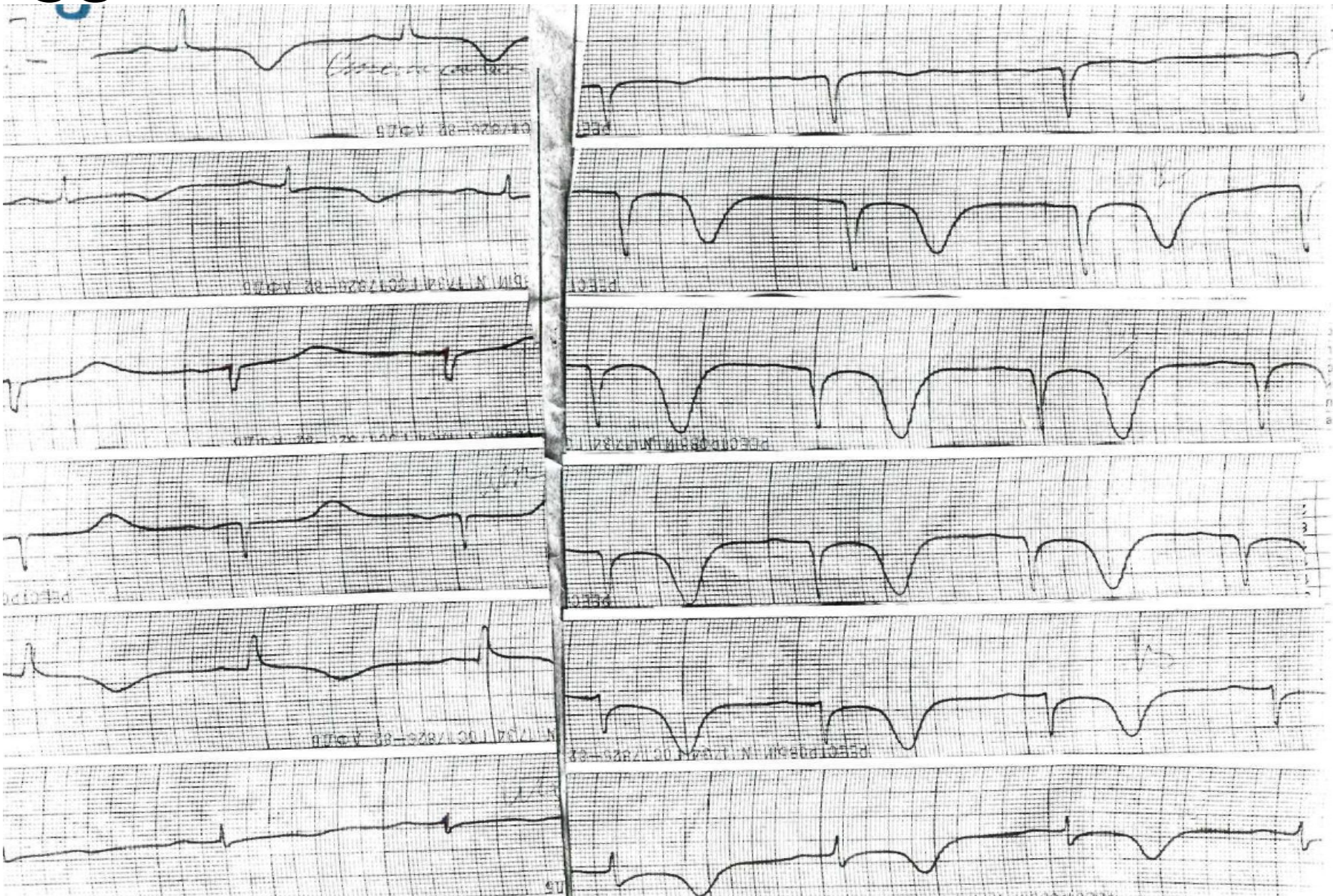
56



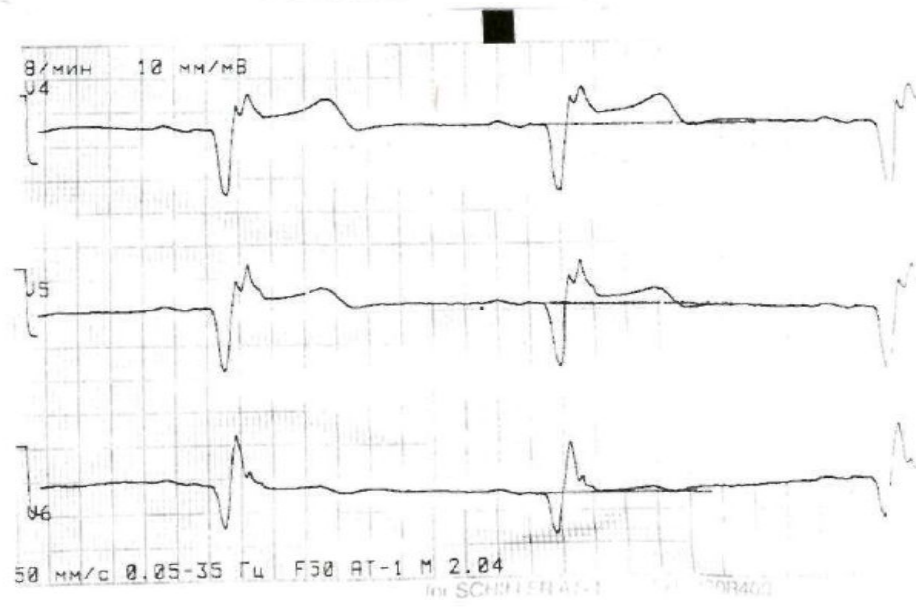
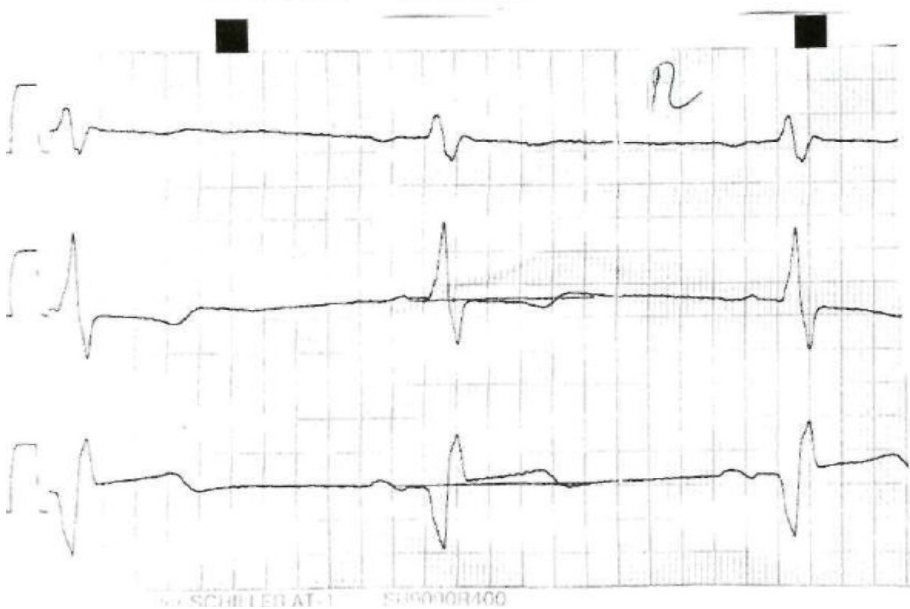
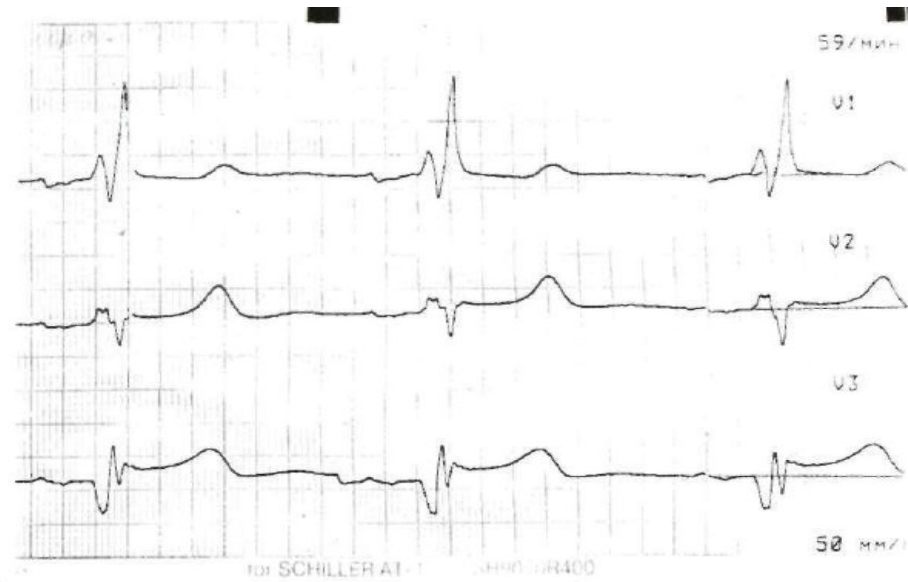
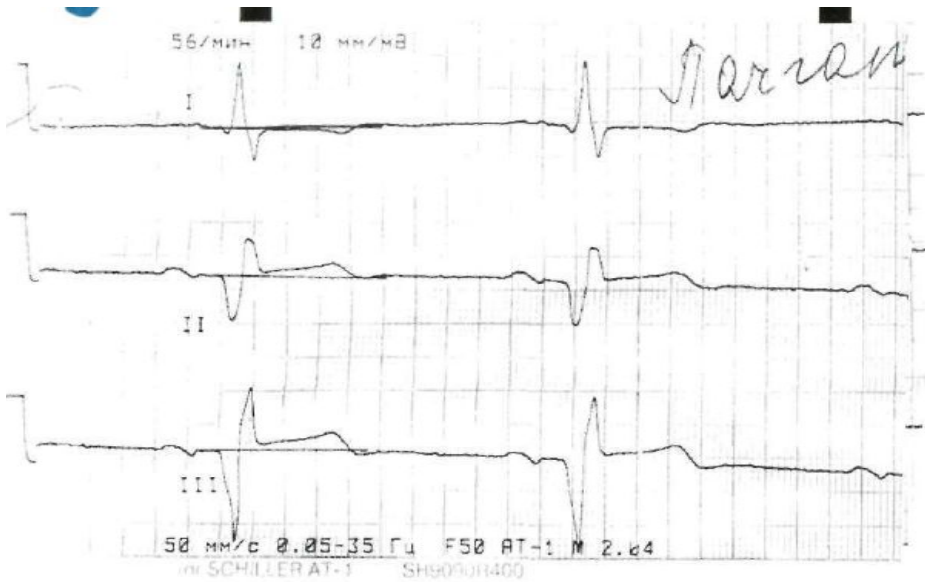
57



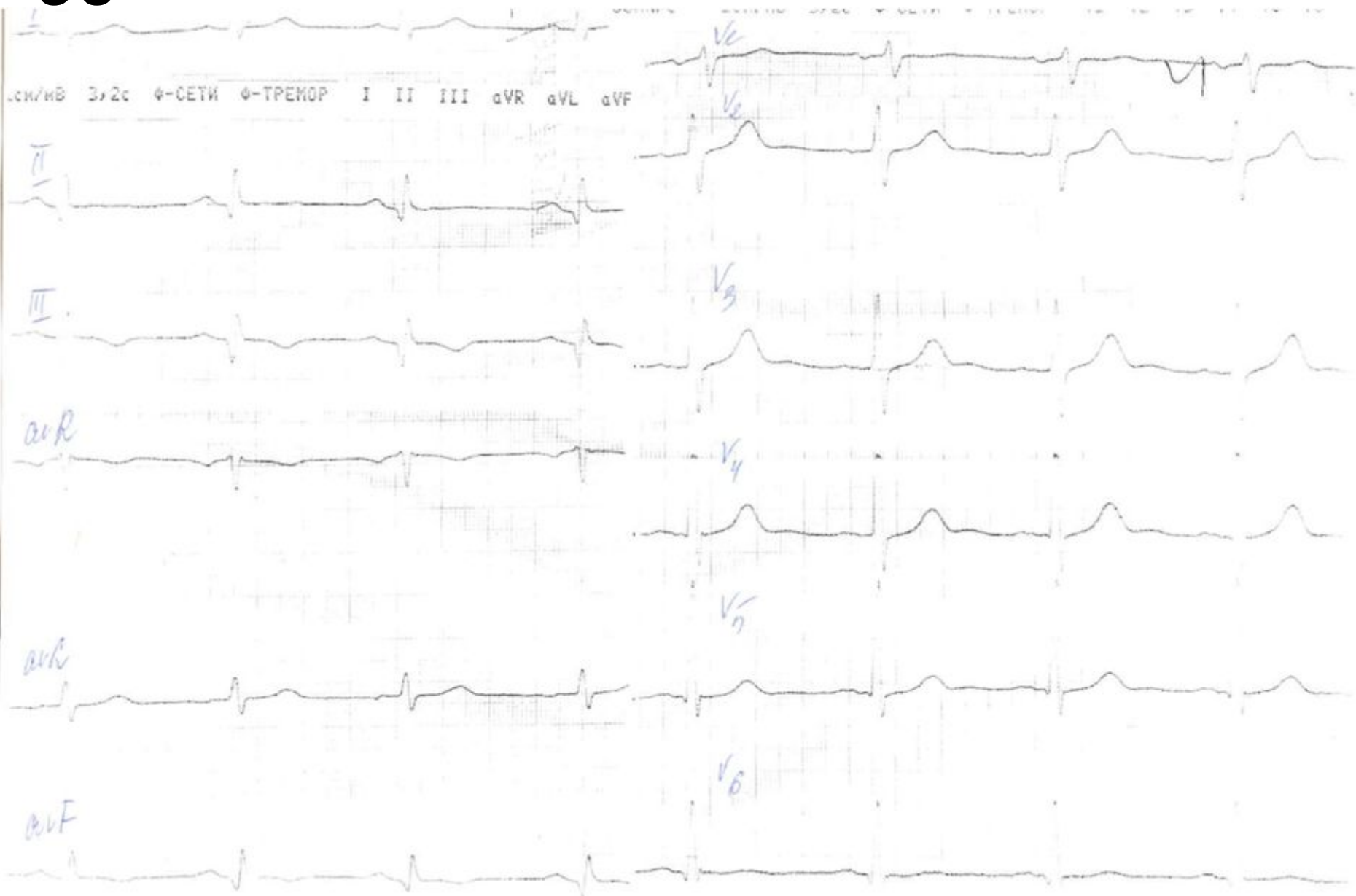
58



59




60



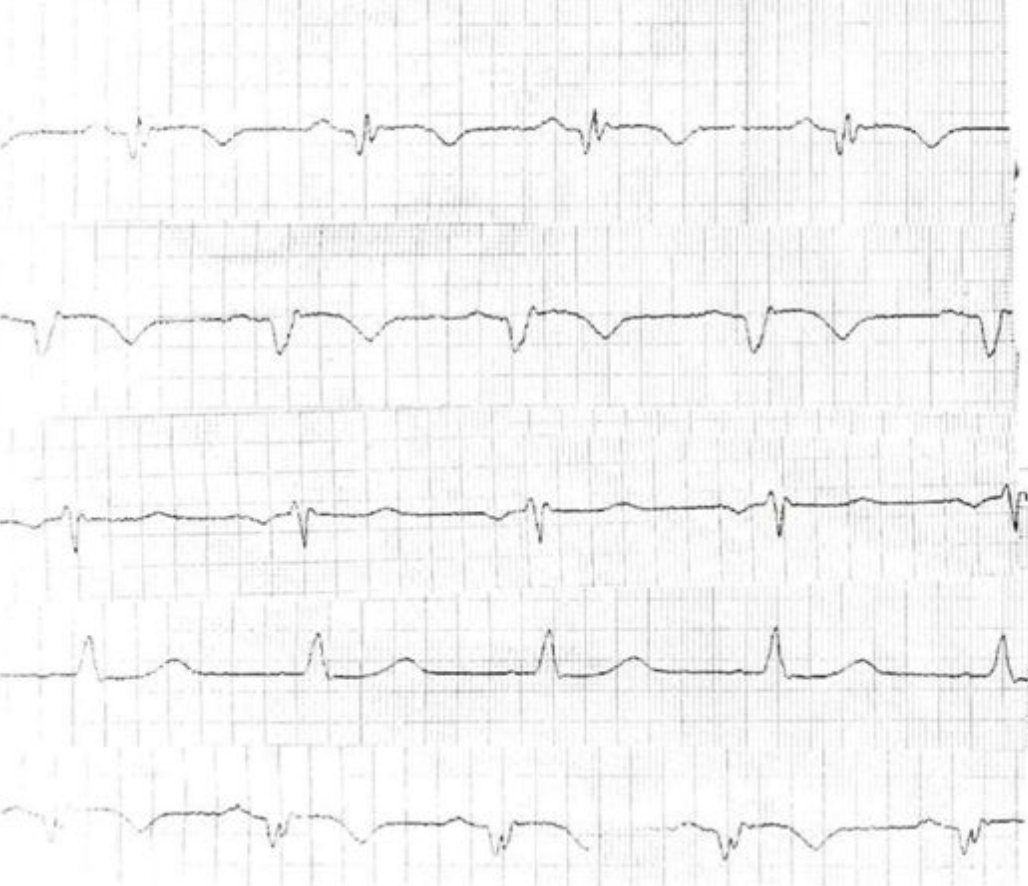
61

16/100

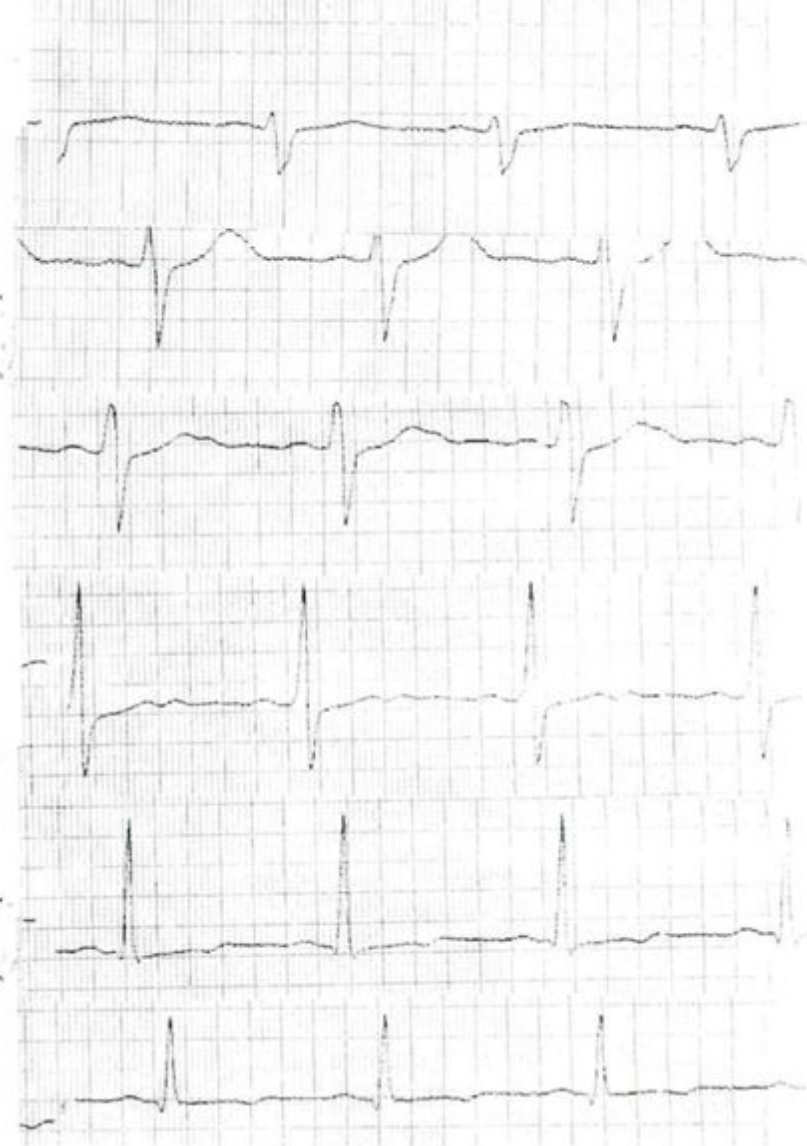
HR - 85 03.07.16 09:



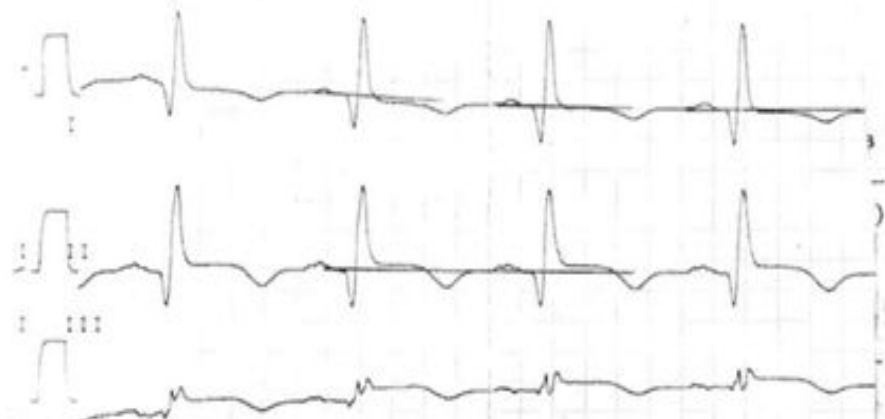II HR - 88 03.07.16 09:19 50m



V1 HR - 84 03.07.16 0



5 mm/mB

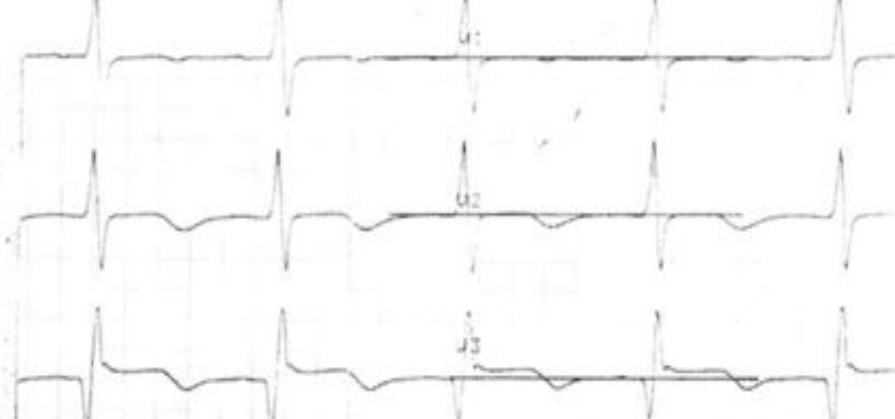


50 мм/с 0,85-35 Гц F50 AT-1 2,84  
 SCHILLER SWITZERLAND Art. No. 2.157.014 CE

Продолжительность систолы QR ST \_\_\_\_\_

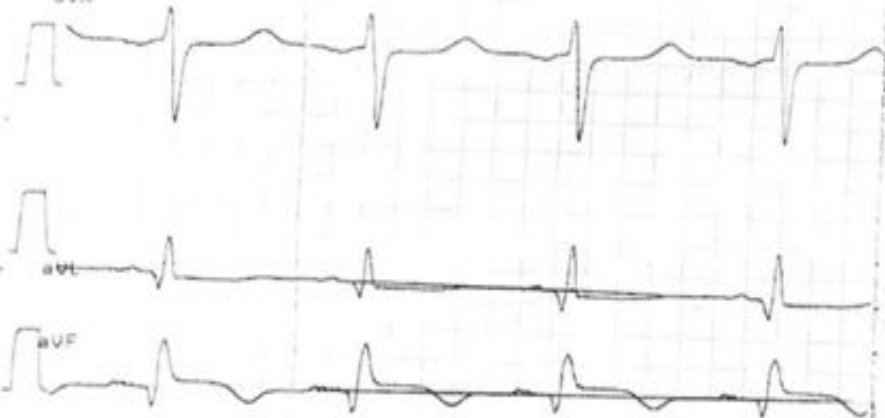
Экстрасистолы, исходящие \_\_\_\_\_

5 мм/мВ



0,85-35 Гц F50 AT-1 2,84 50 мм/с 0,85-35 Гц F50 AT-1 2,84  
 SCHILLER SWITZERLAND Art. No. 2.157.014 CE

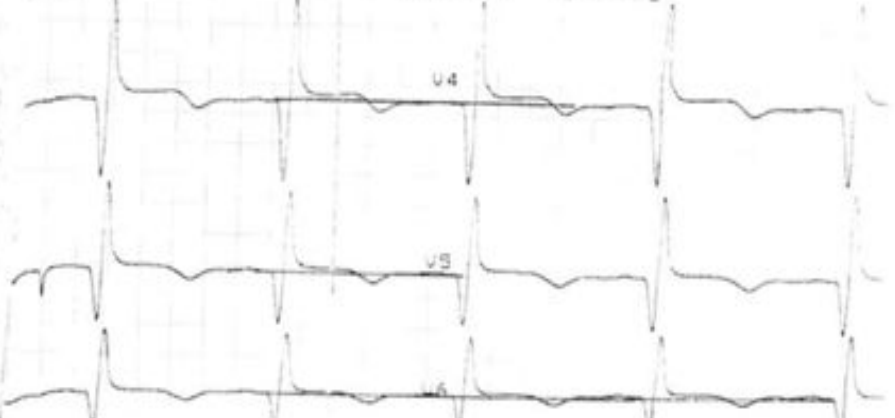
98/мин 12 мм/мВ



50 мм/с 0,85-35 Гц F50 AT-1 2,84  
 SCHILLER SWITZERLAND Art. No. 2.157.014 CE

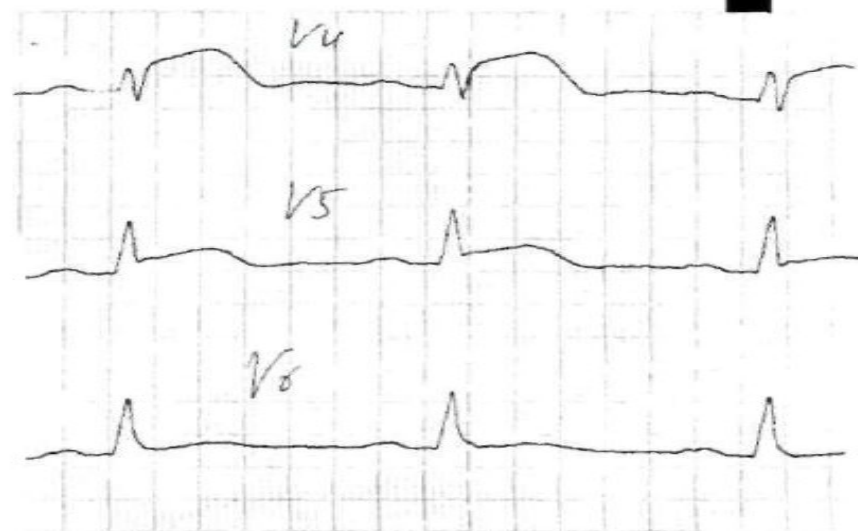
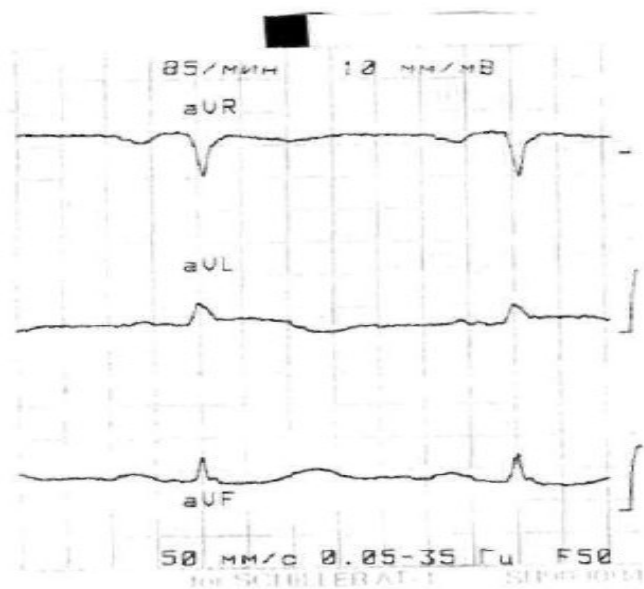
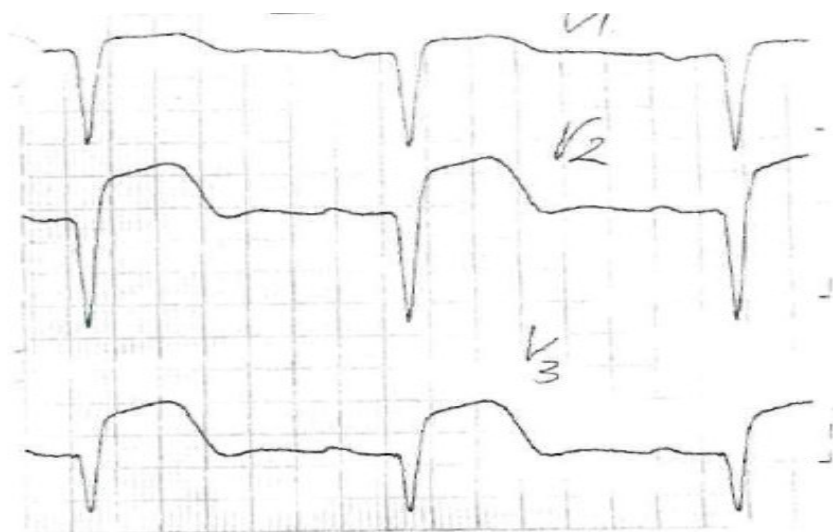
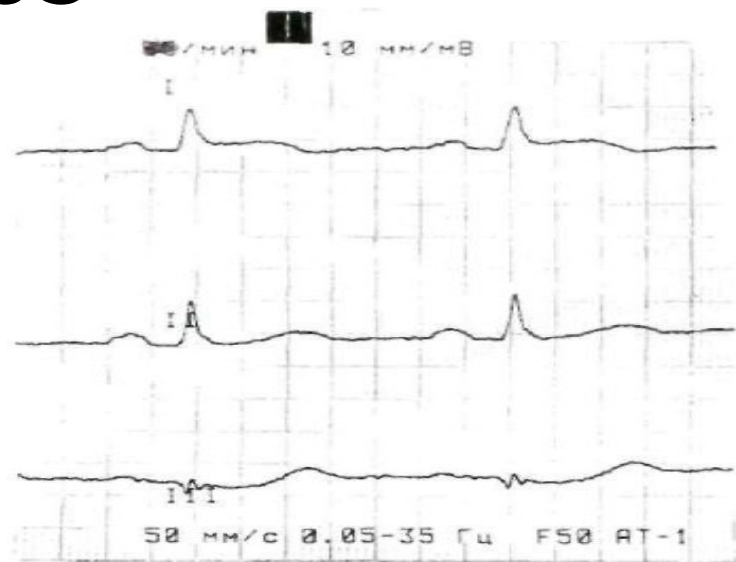
12 мм/мВ

100/мин 5 мм/мВ



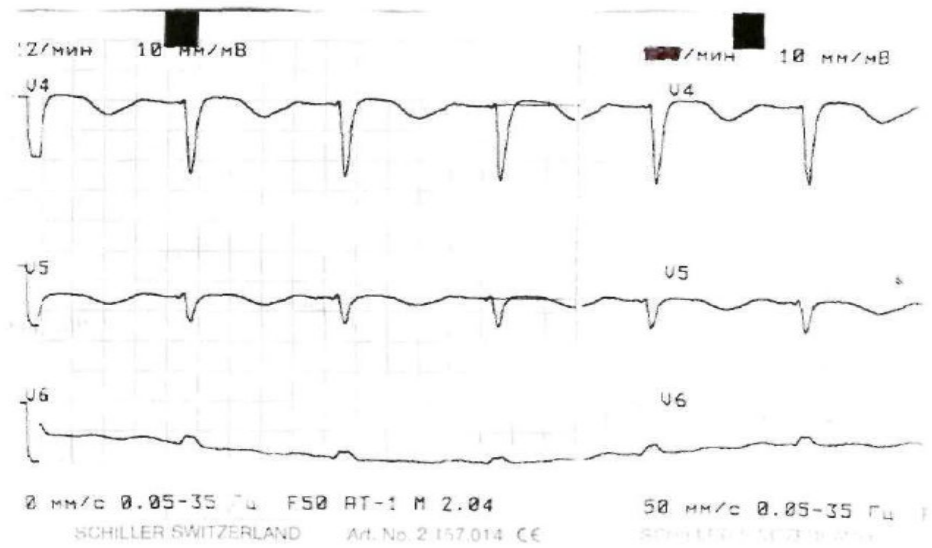
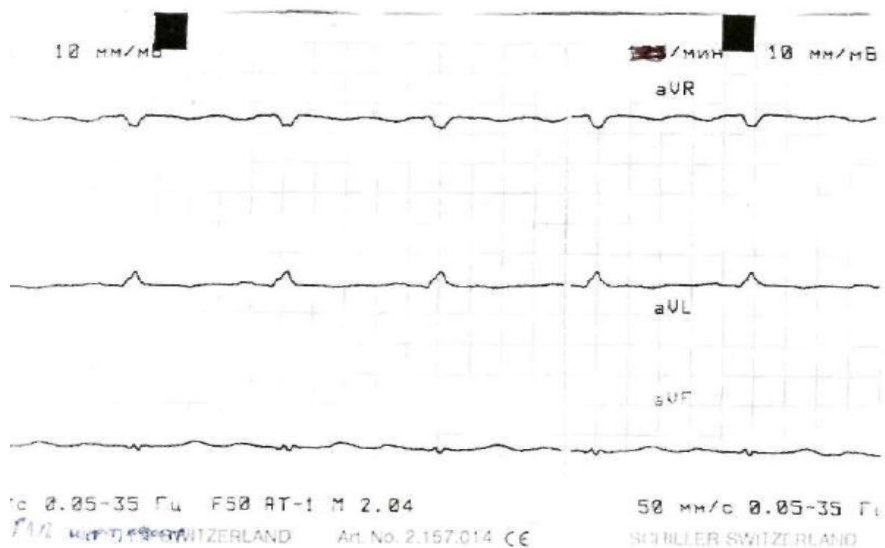
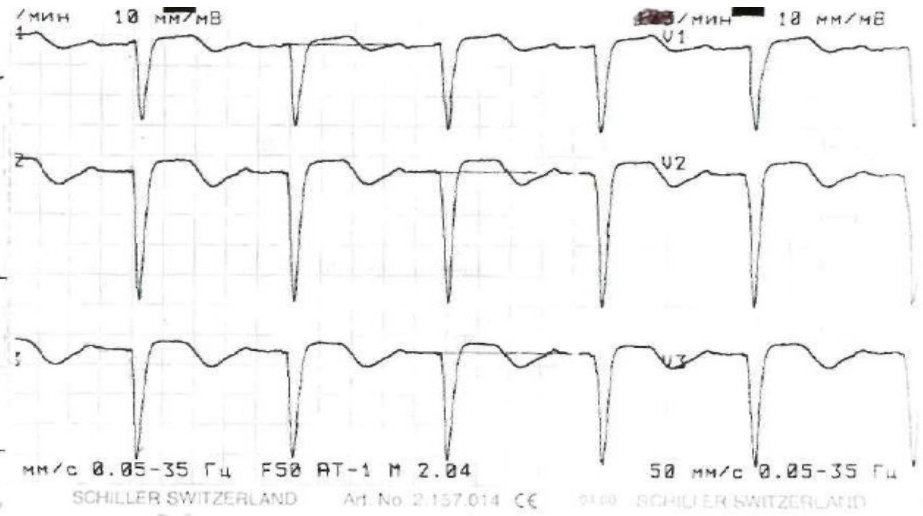
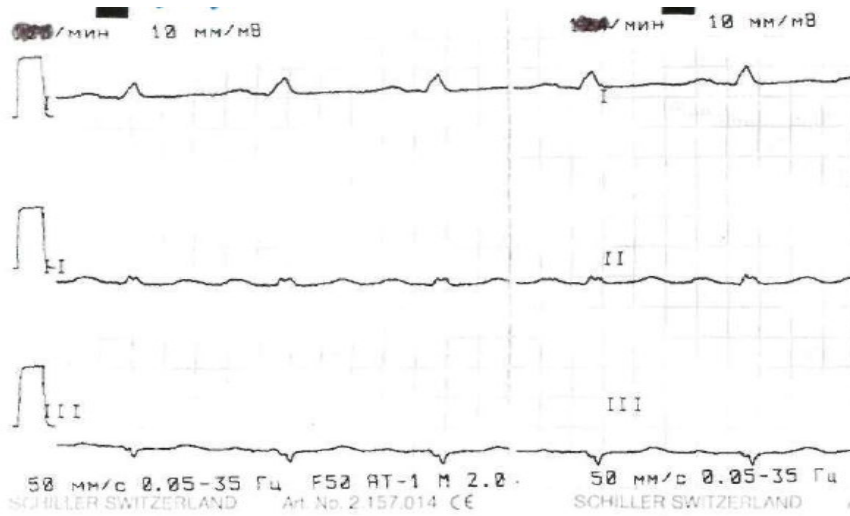
0,85-35 Гц F50 AT-1 2,84 50 мм/с 0,85-35 Гц F50 AT-1 2,84  
 SCHILLER SWITZERLAND Art. No. 2.157.014 CE

63

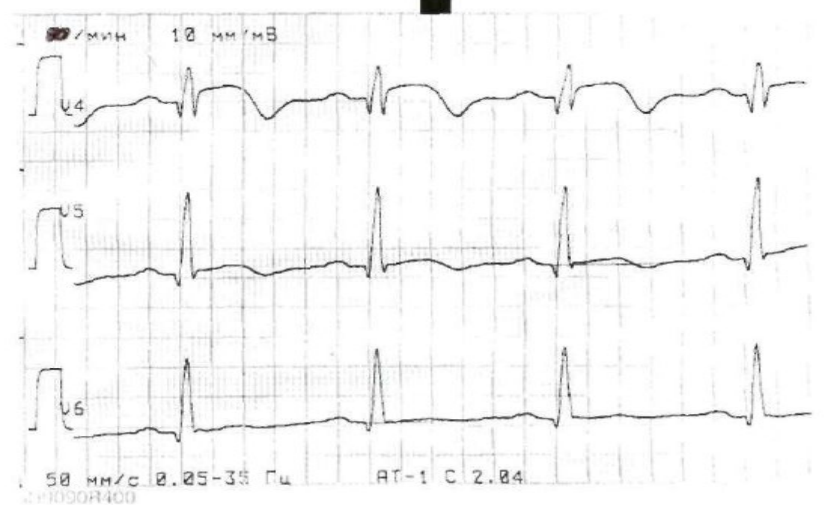
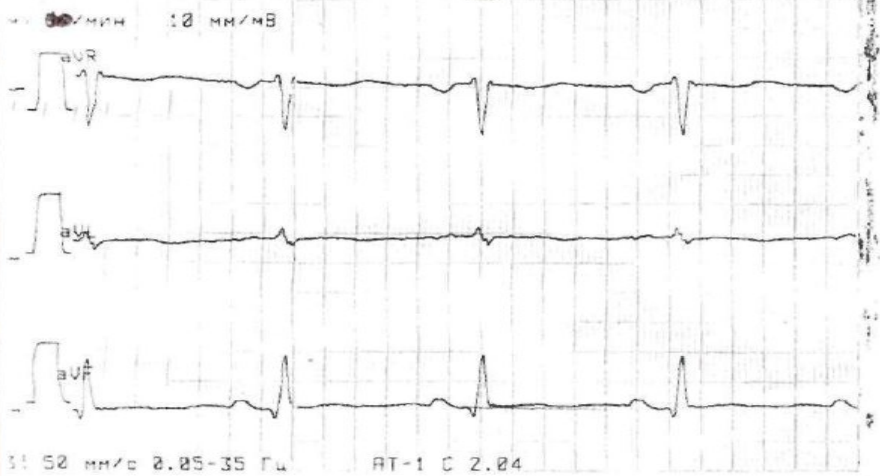
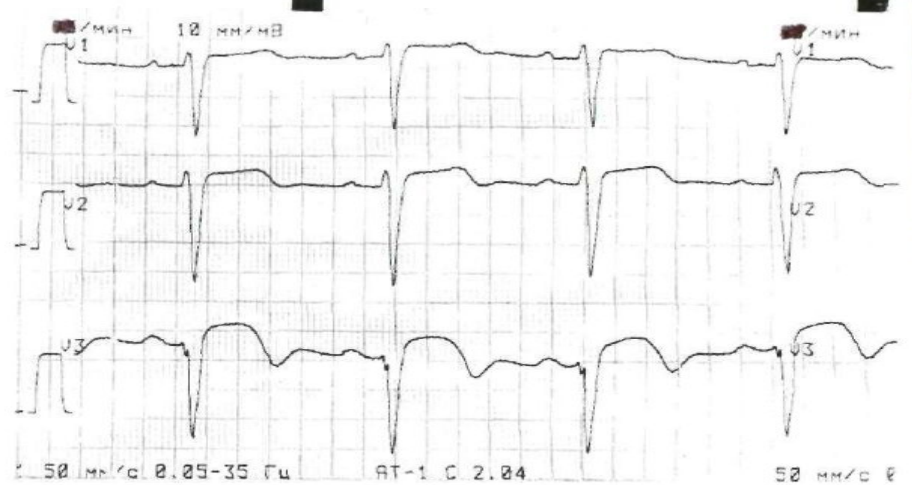
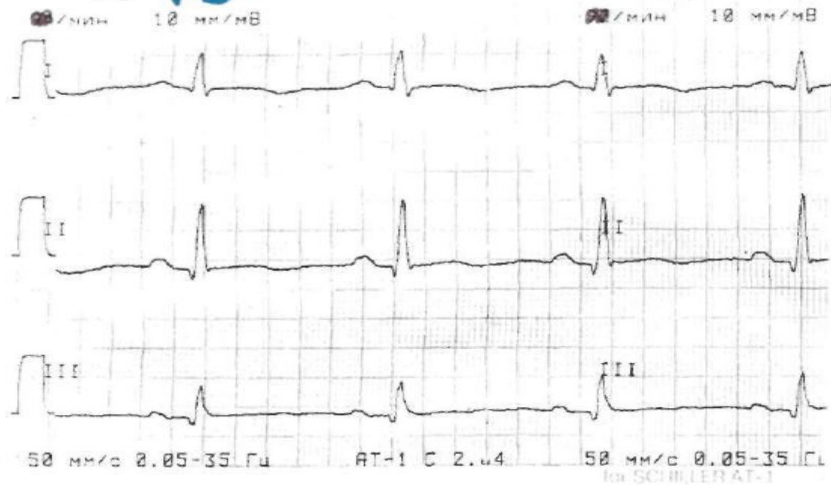




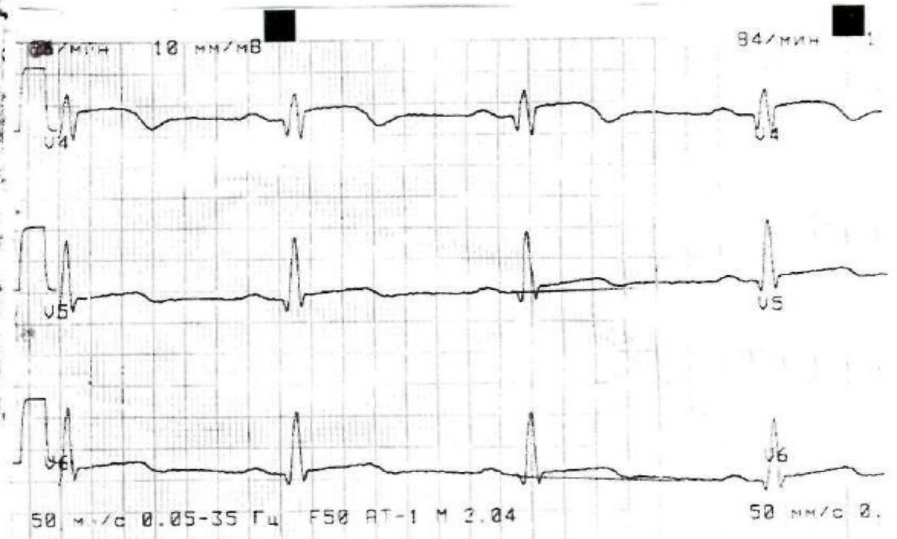
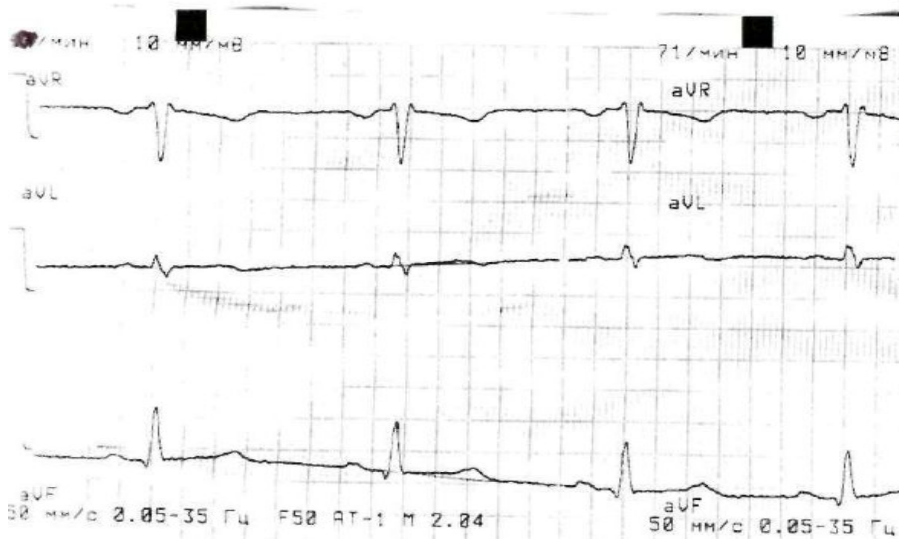
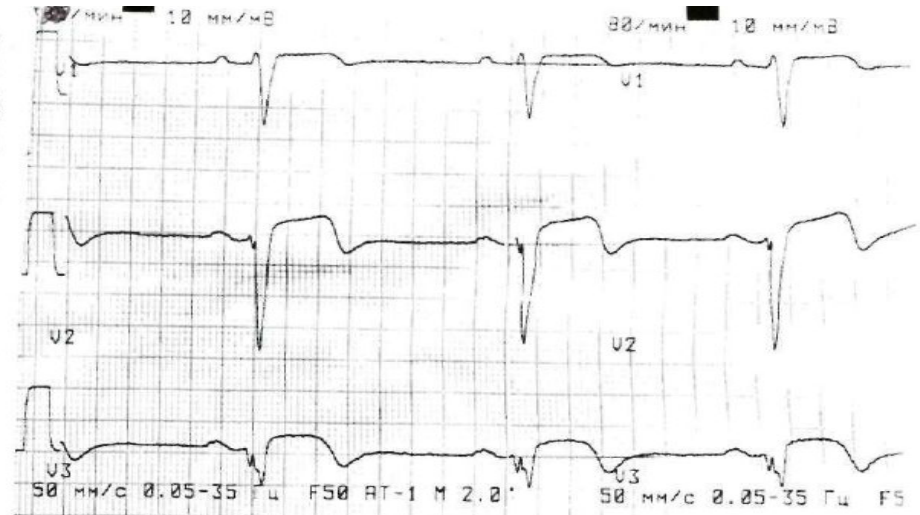
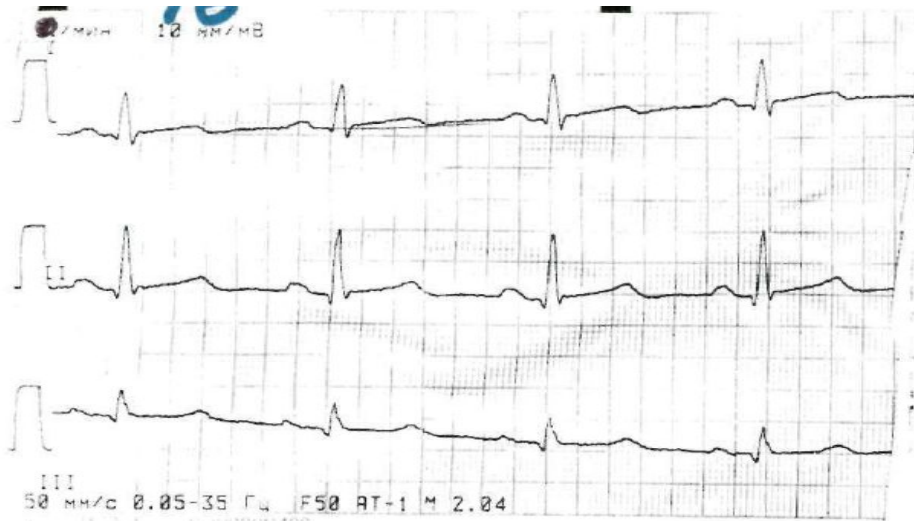# 64



65



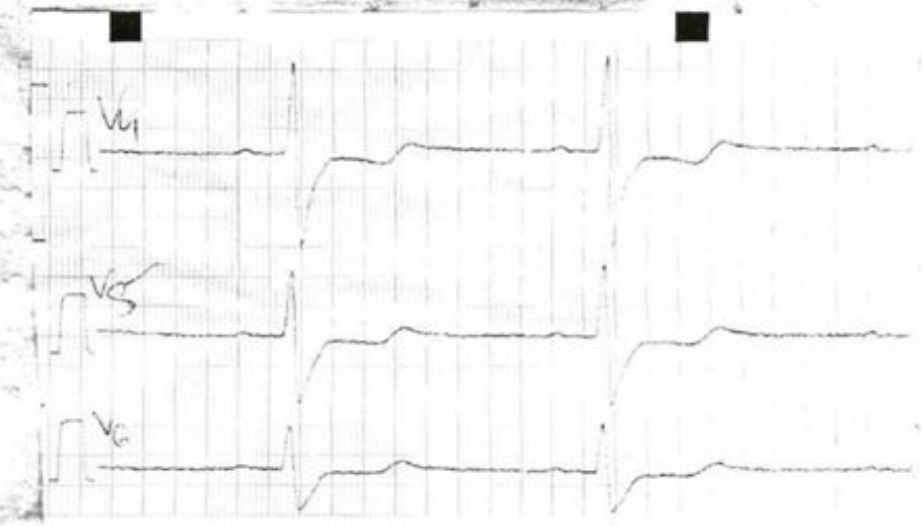
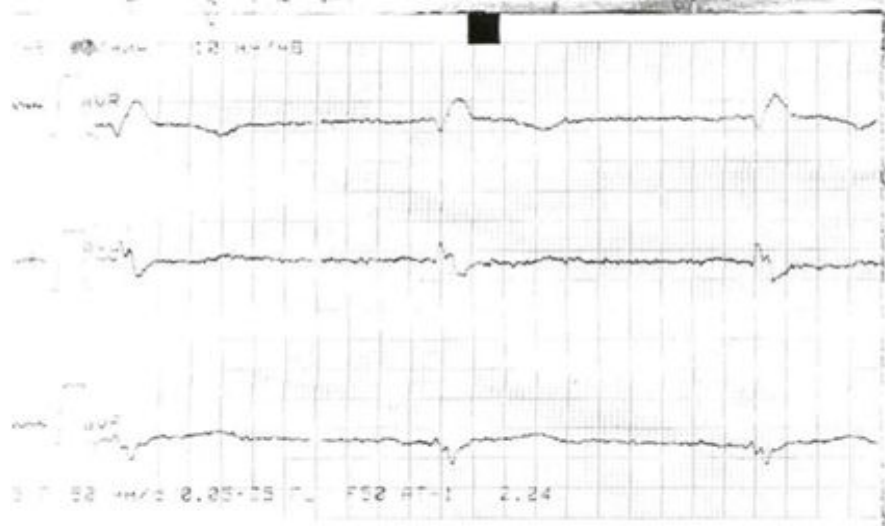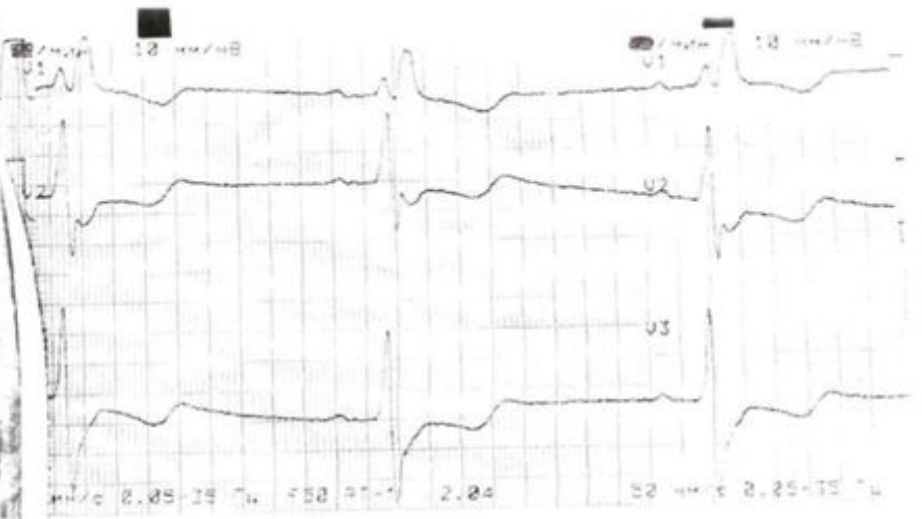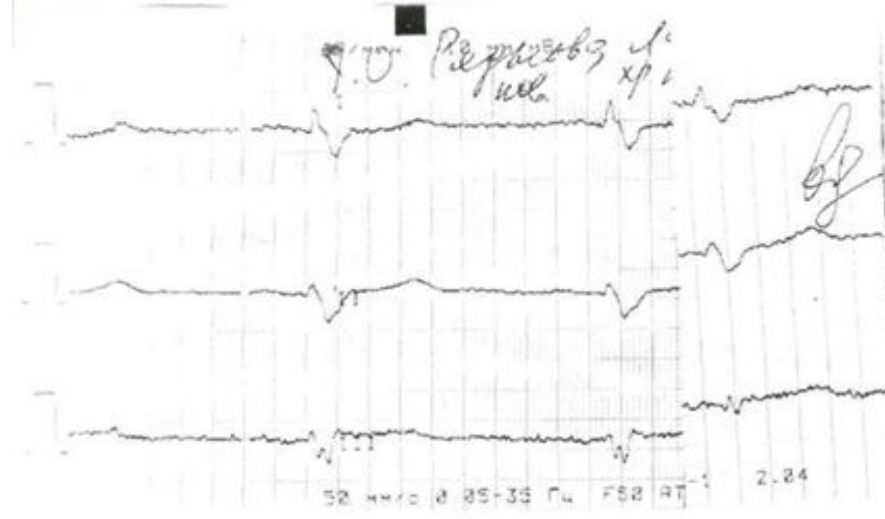# 66



67

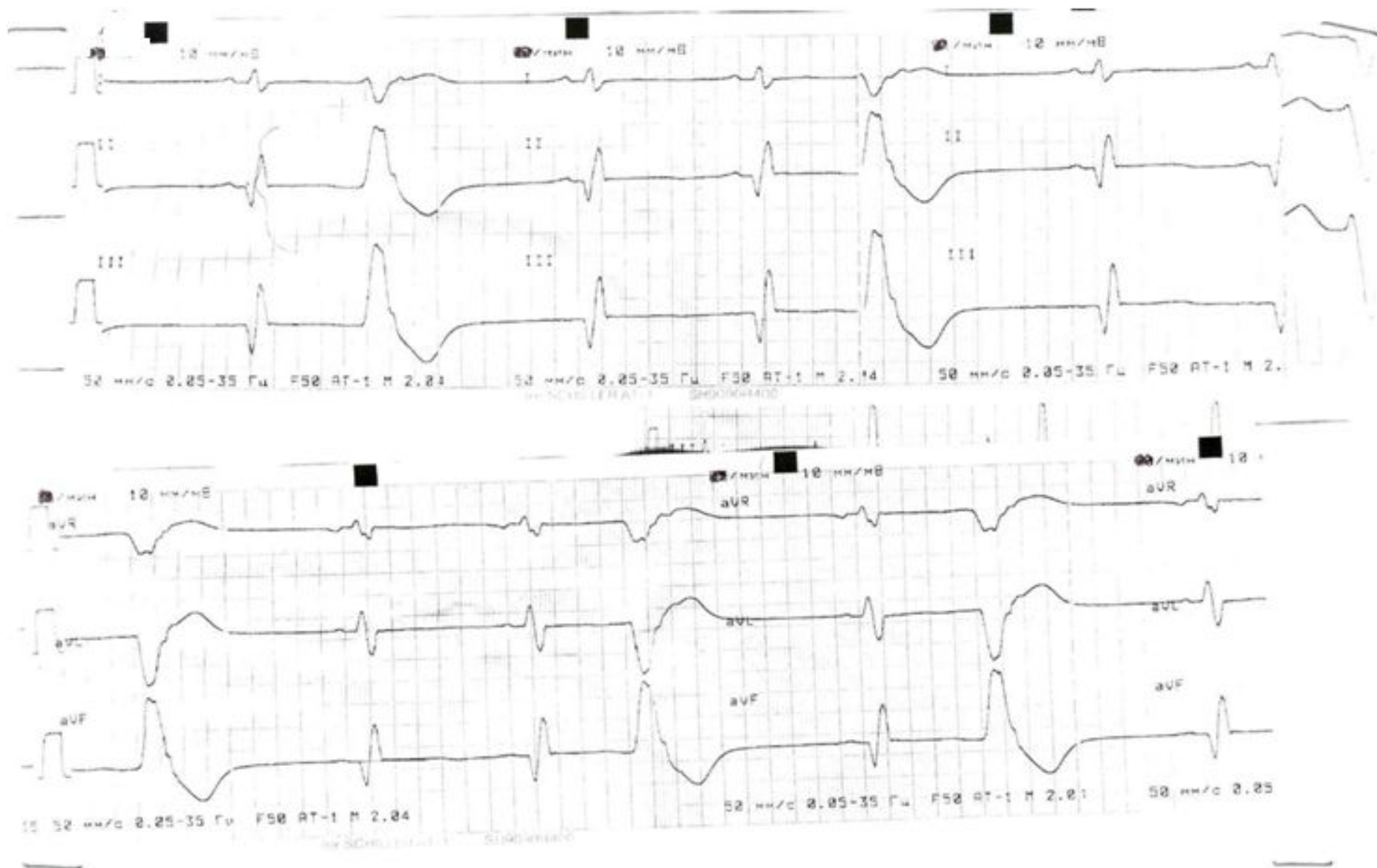
9.10. Резнищев С.  
Ива ХР 1

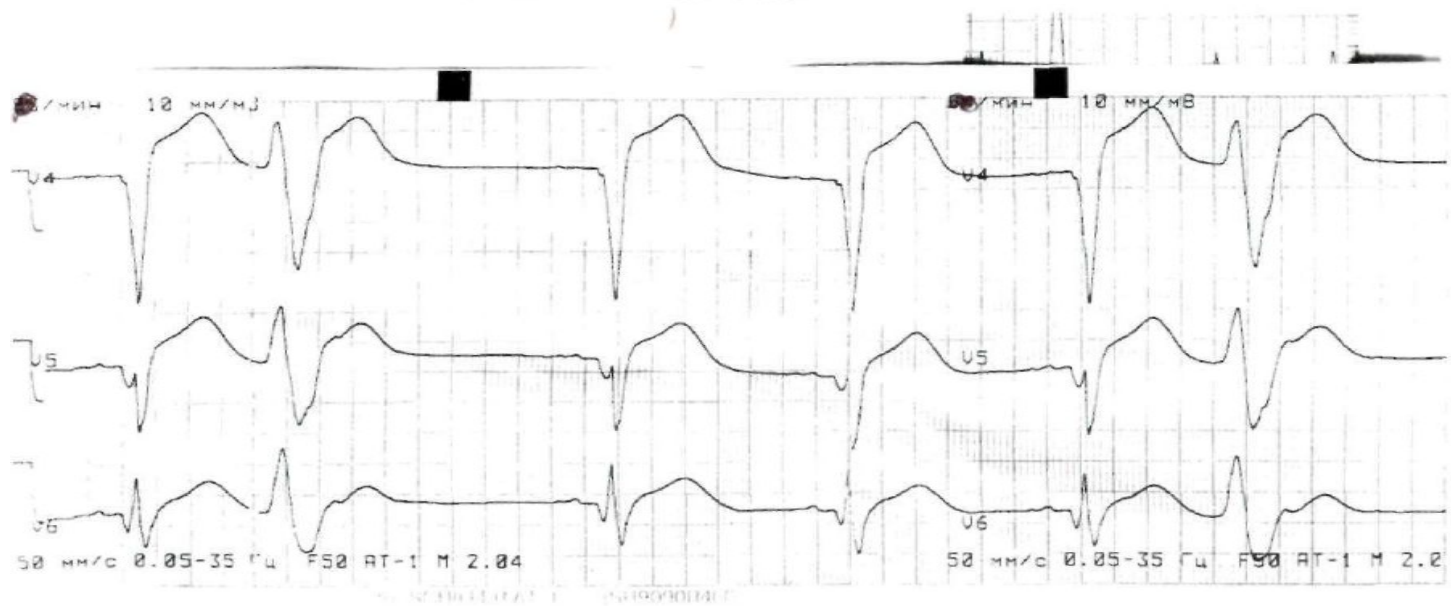
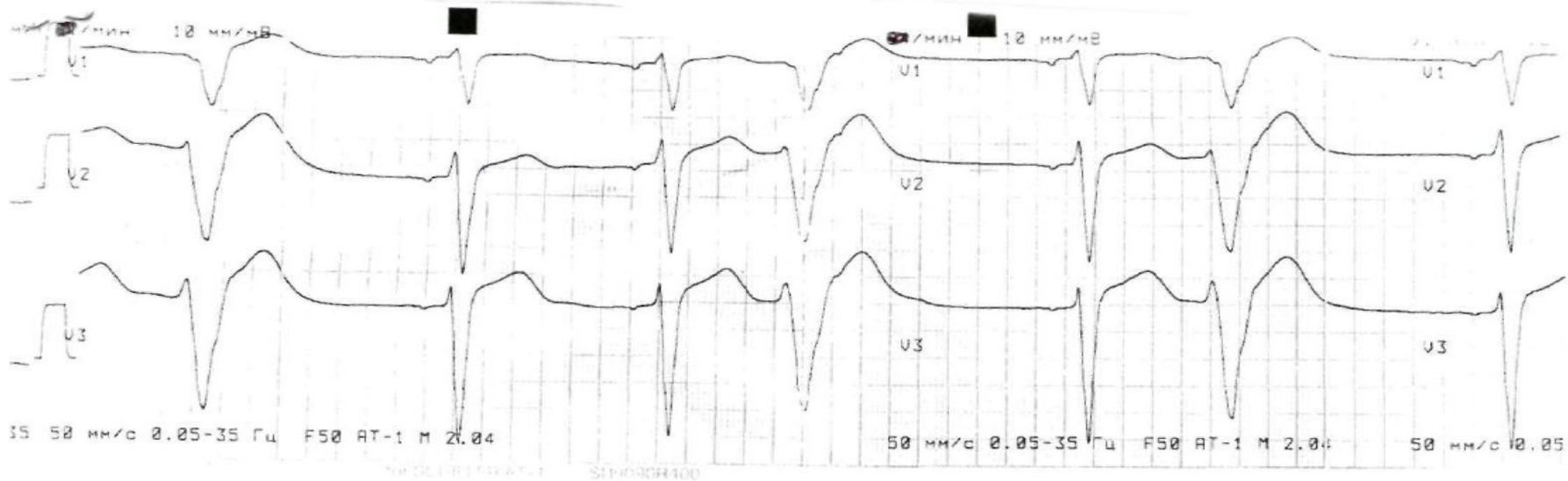67



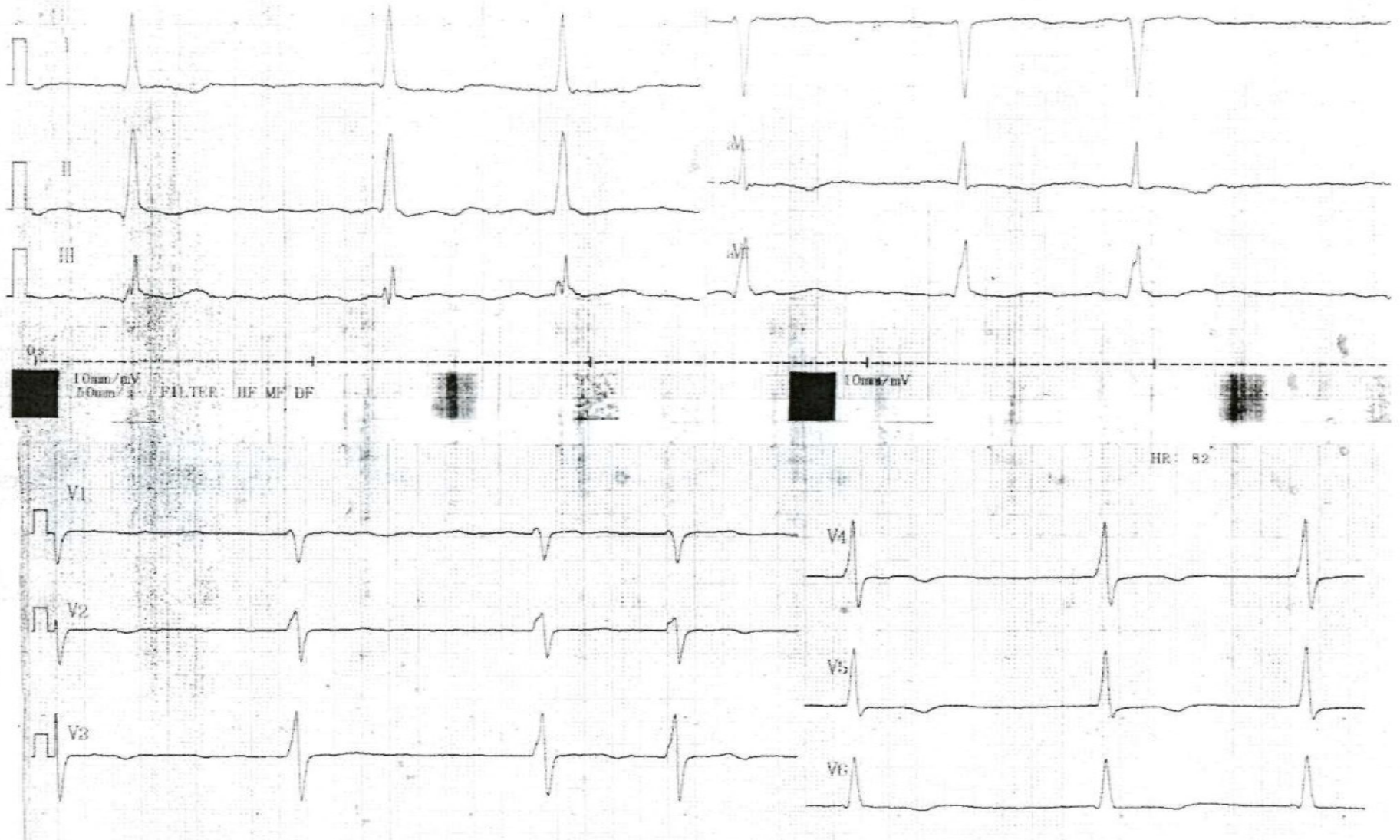
зав. электрокардиографическим кабинетом

68



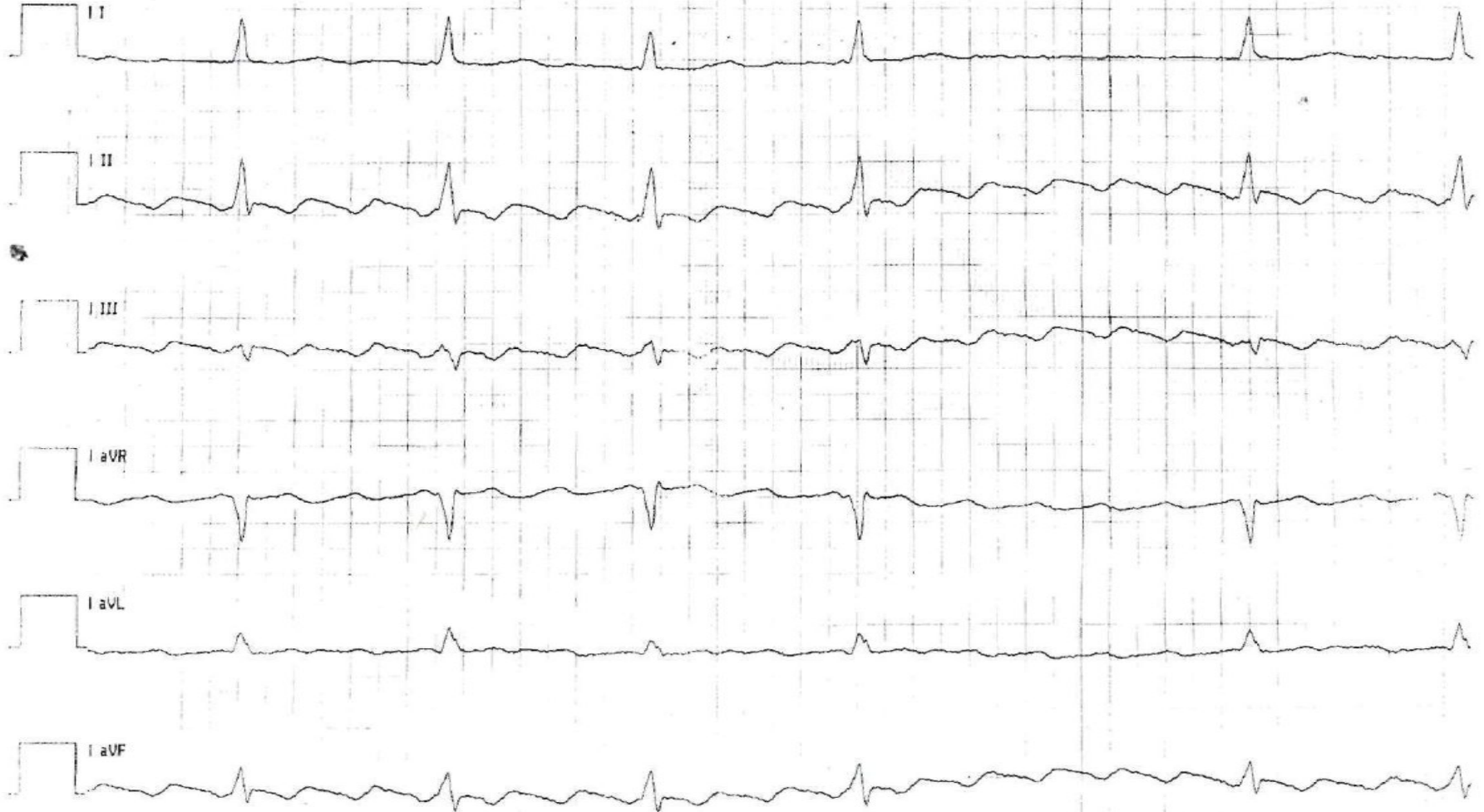

69



# 70

Reviewed by:





10

I V1

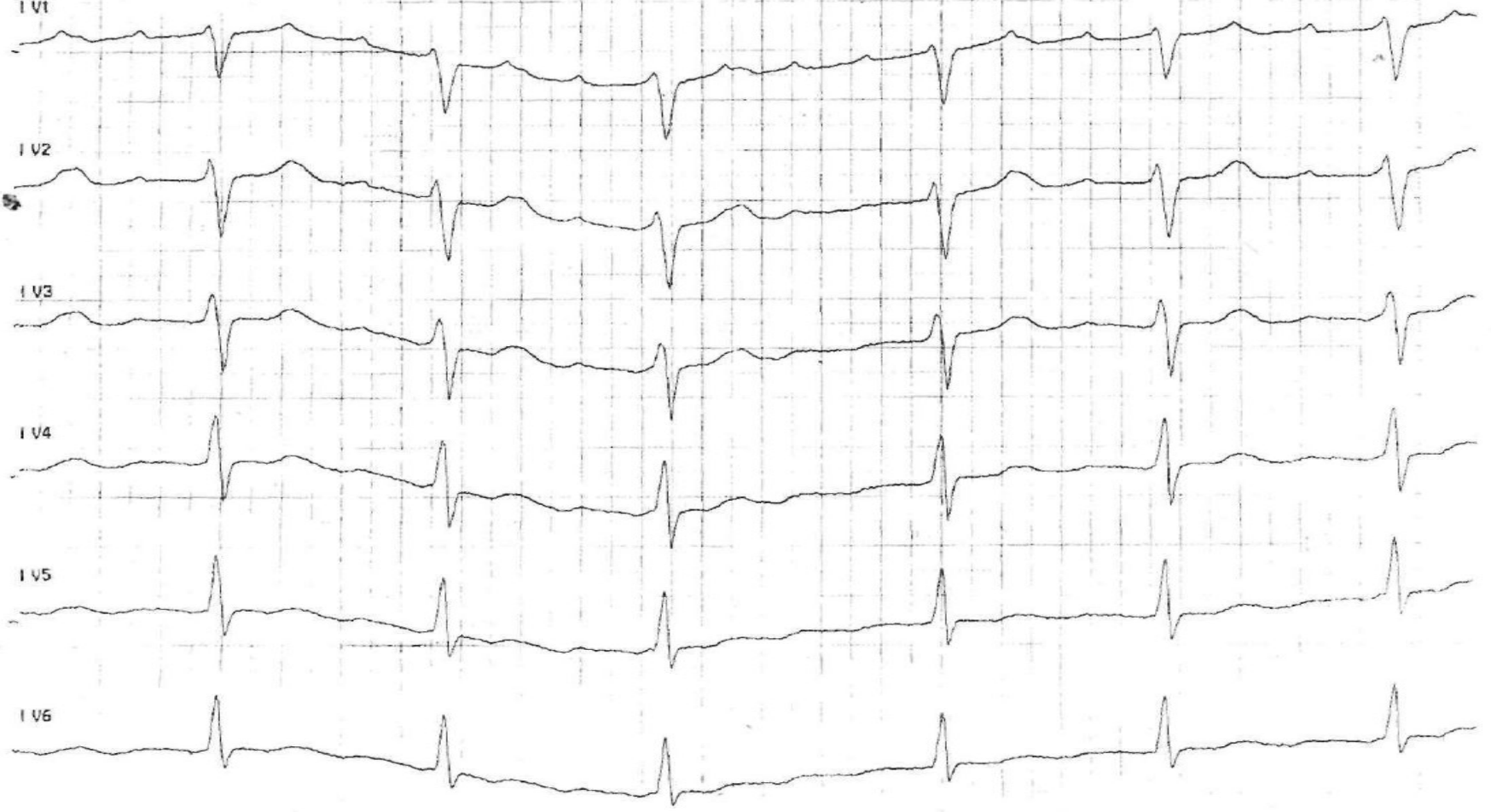
I V2

I V3

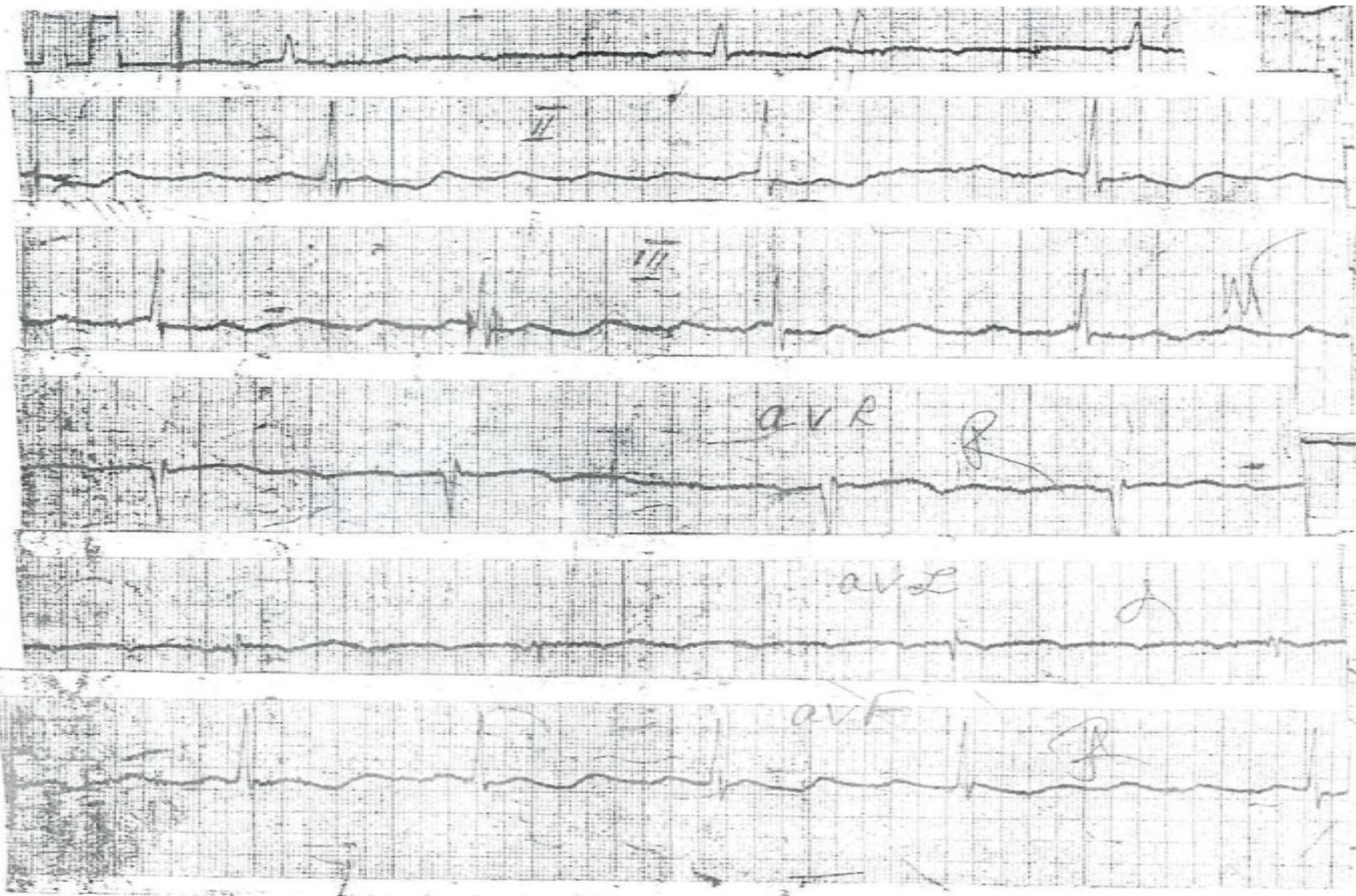
I V4

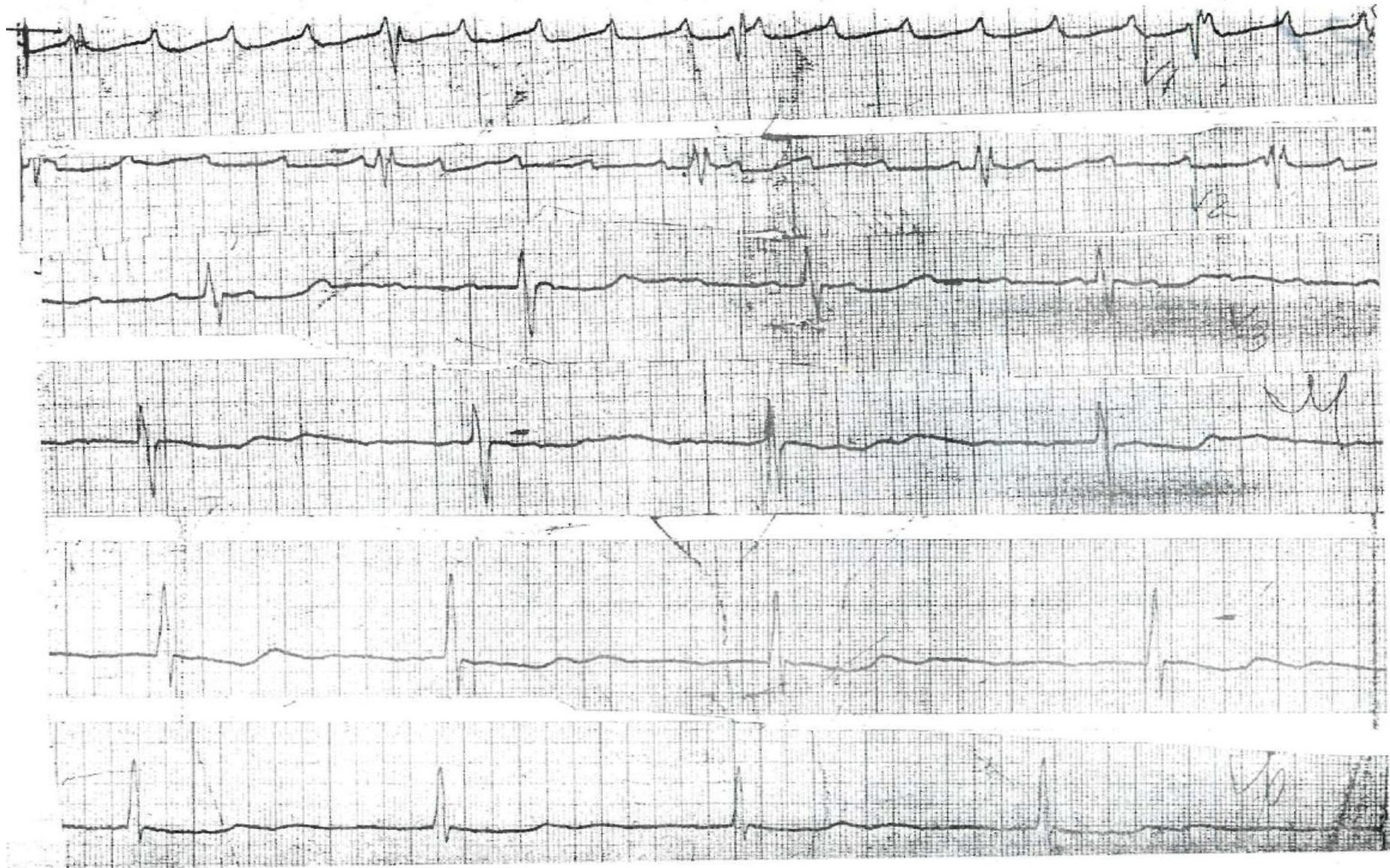
I V5

I V6

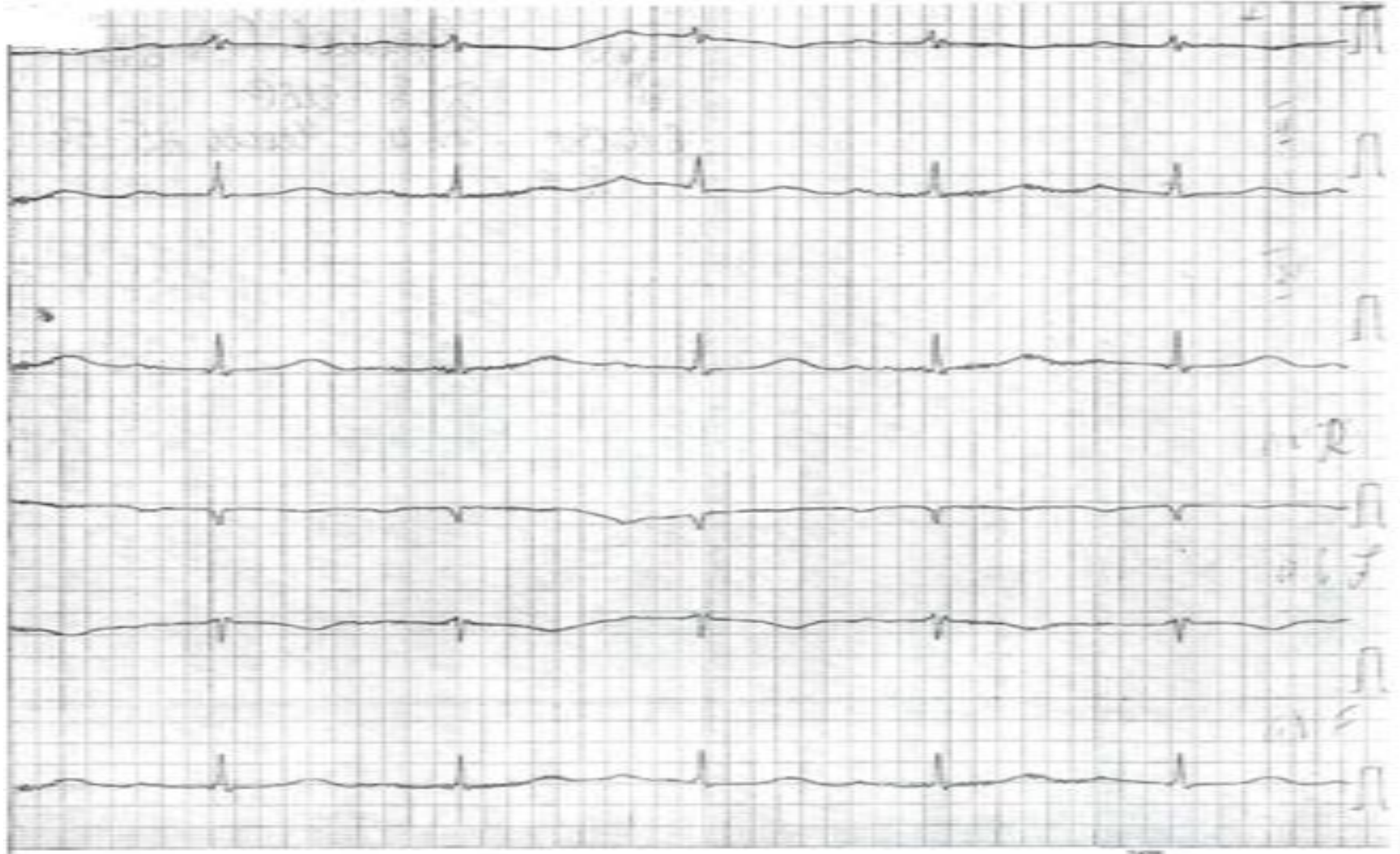


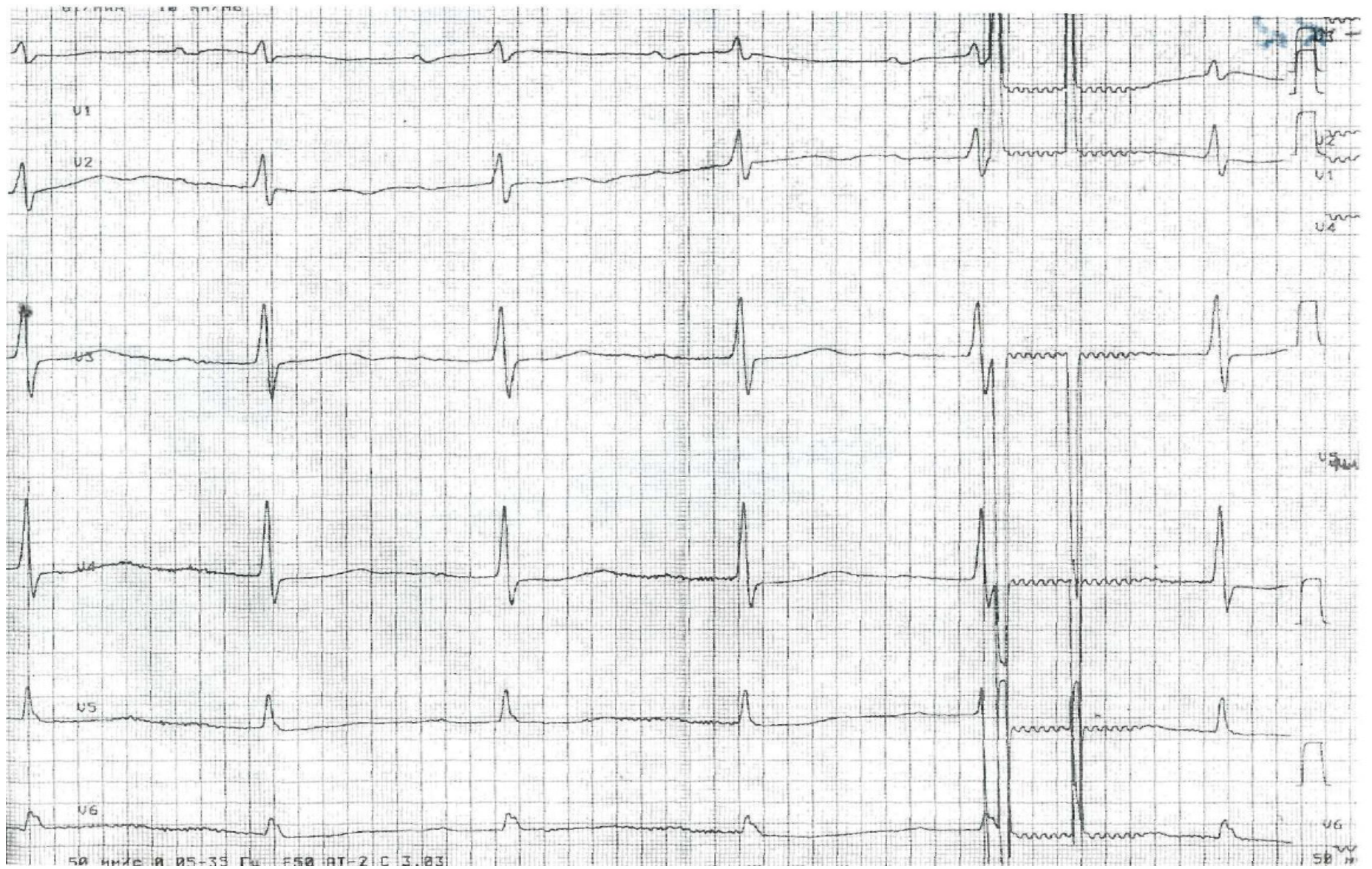
71



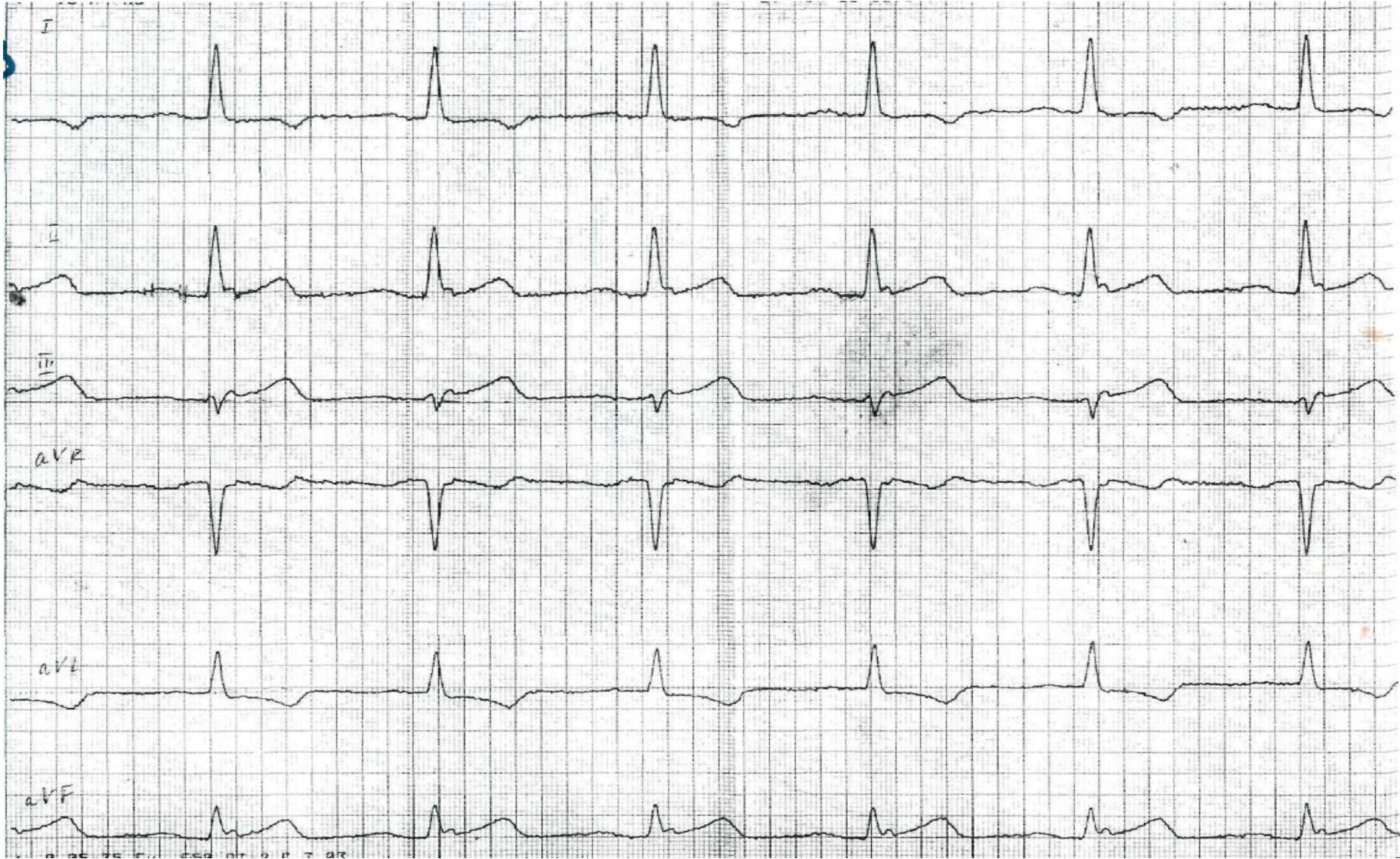

72





73



69710.0 10 мм/мВ

ПТ 21-НОЯ-08 12:04:34

V1

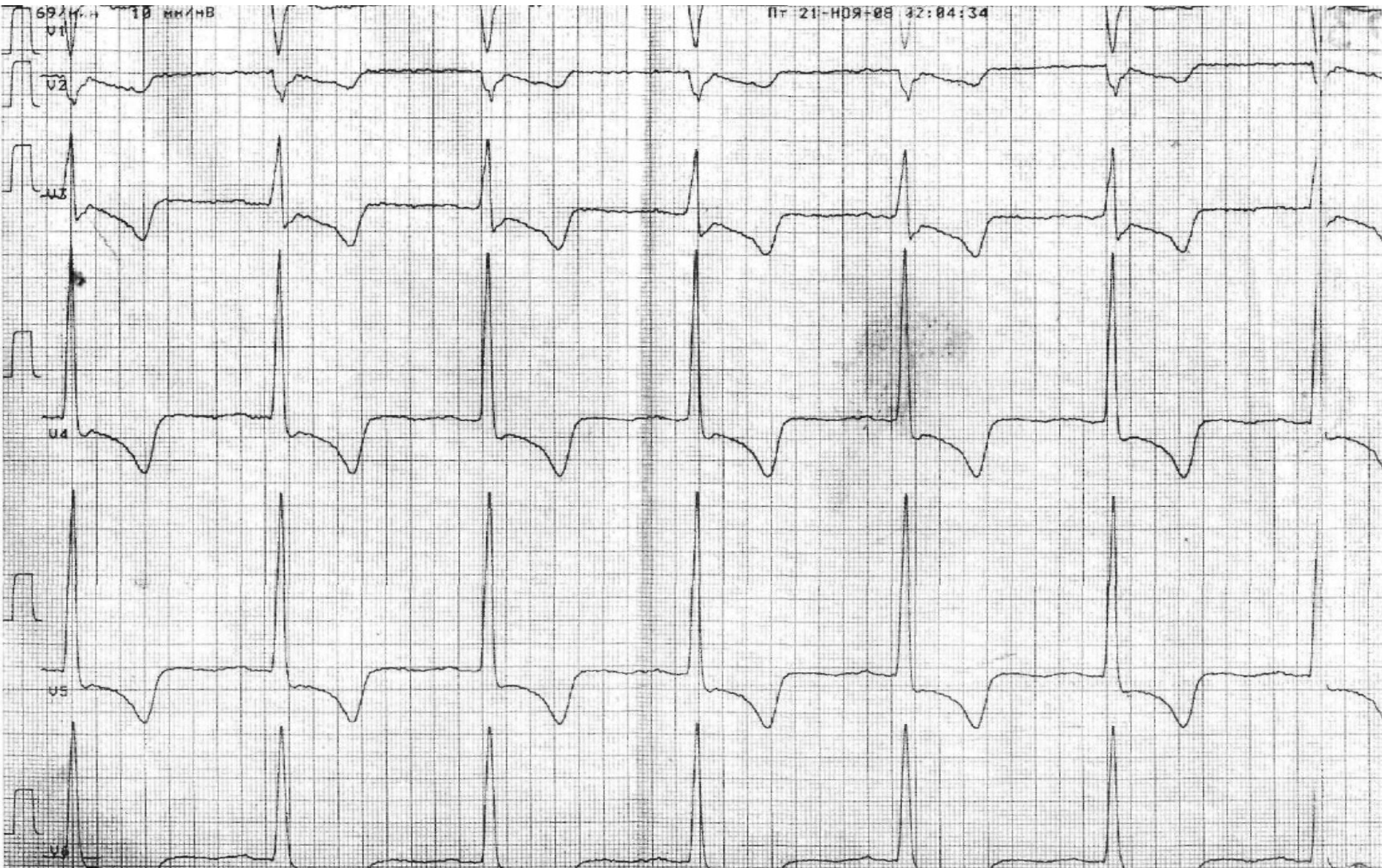
V2

V3

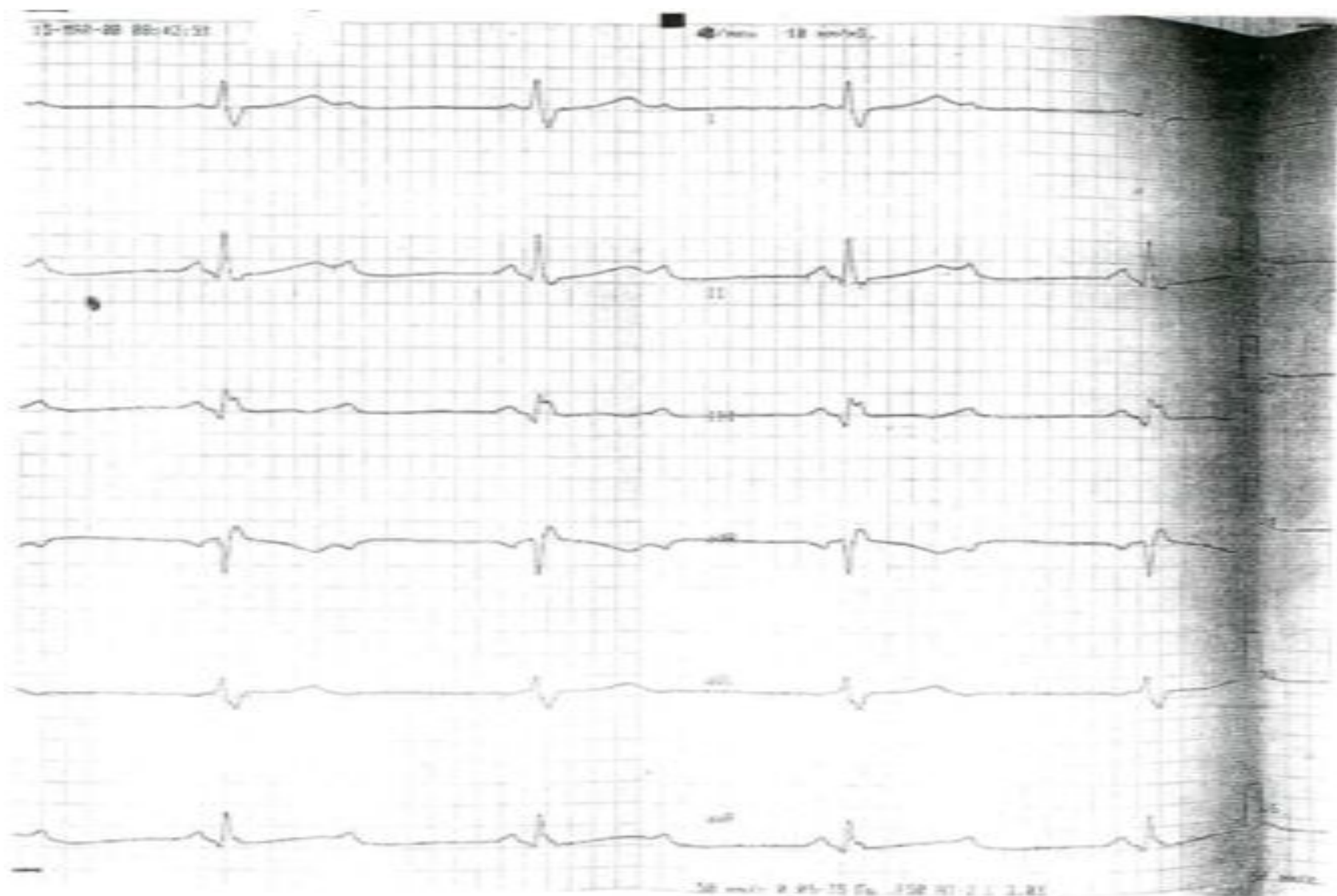V4

V5

V6



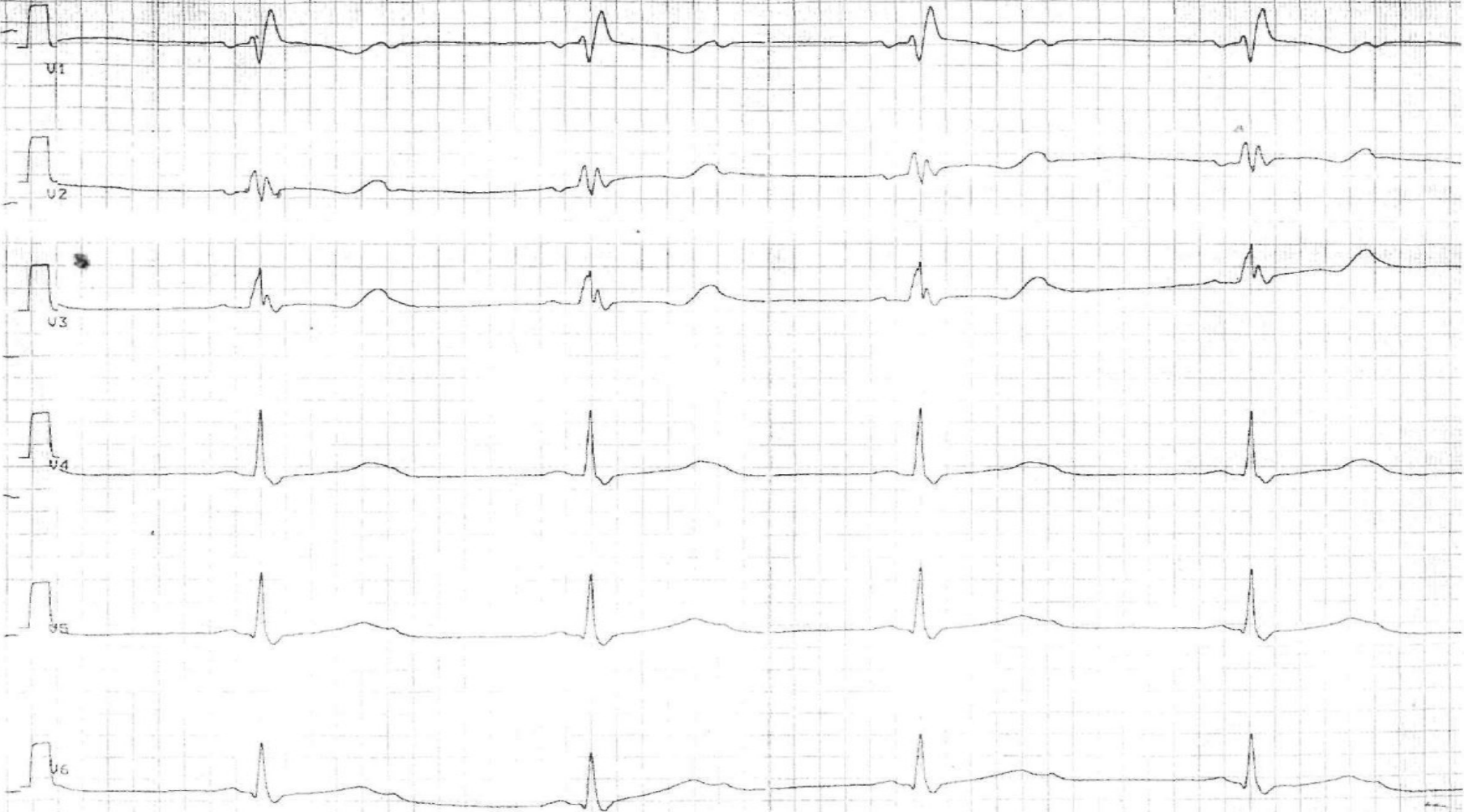74





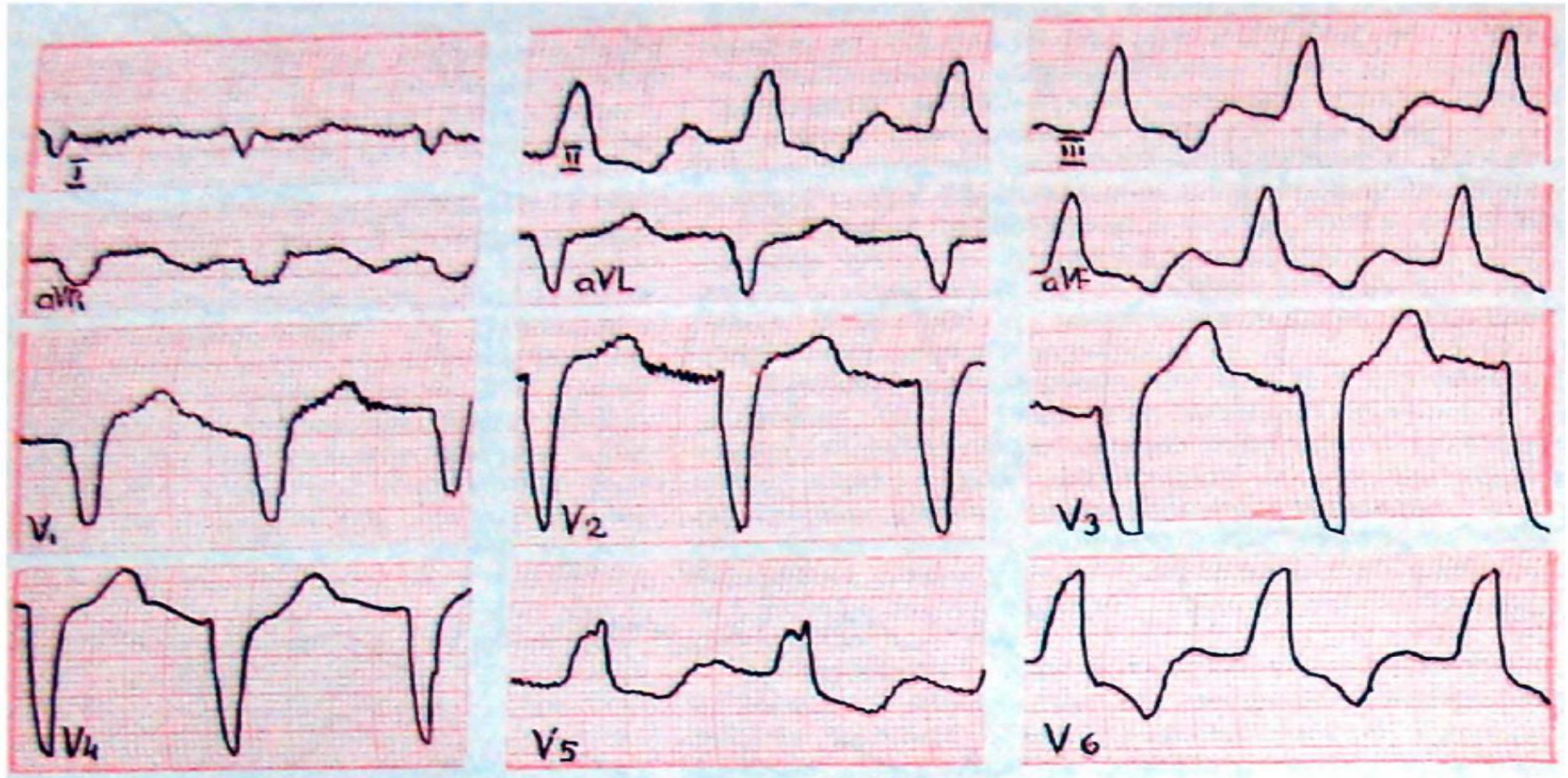
50/мин 10 мм/кВ

ЧТ 15-МАЯ-08 08:43:00

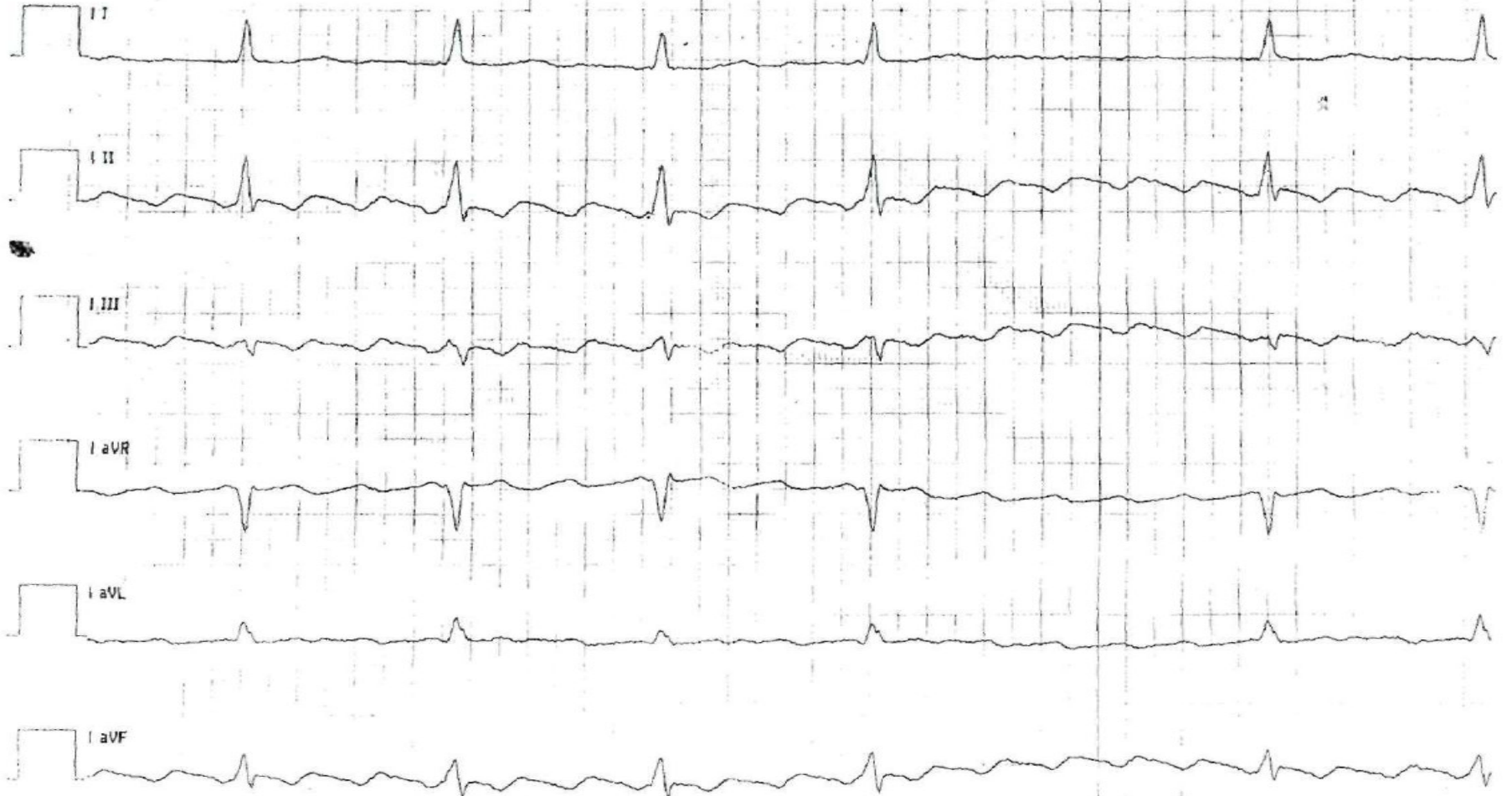


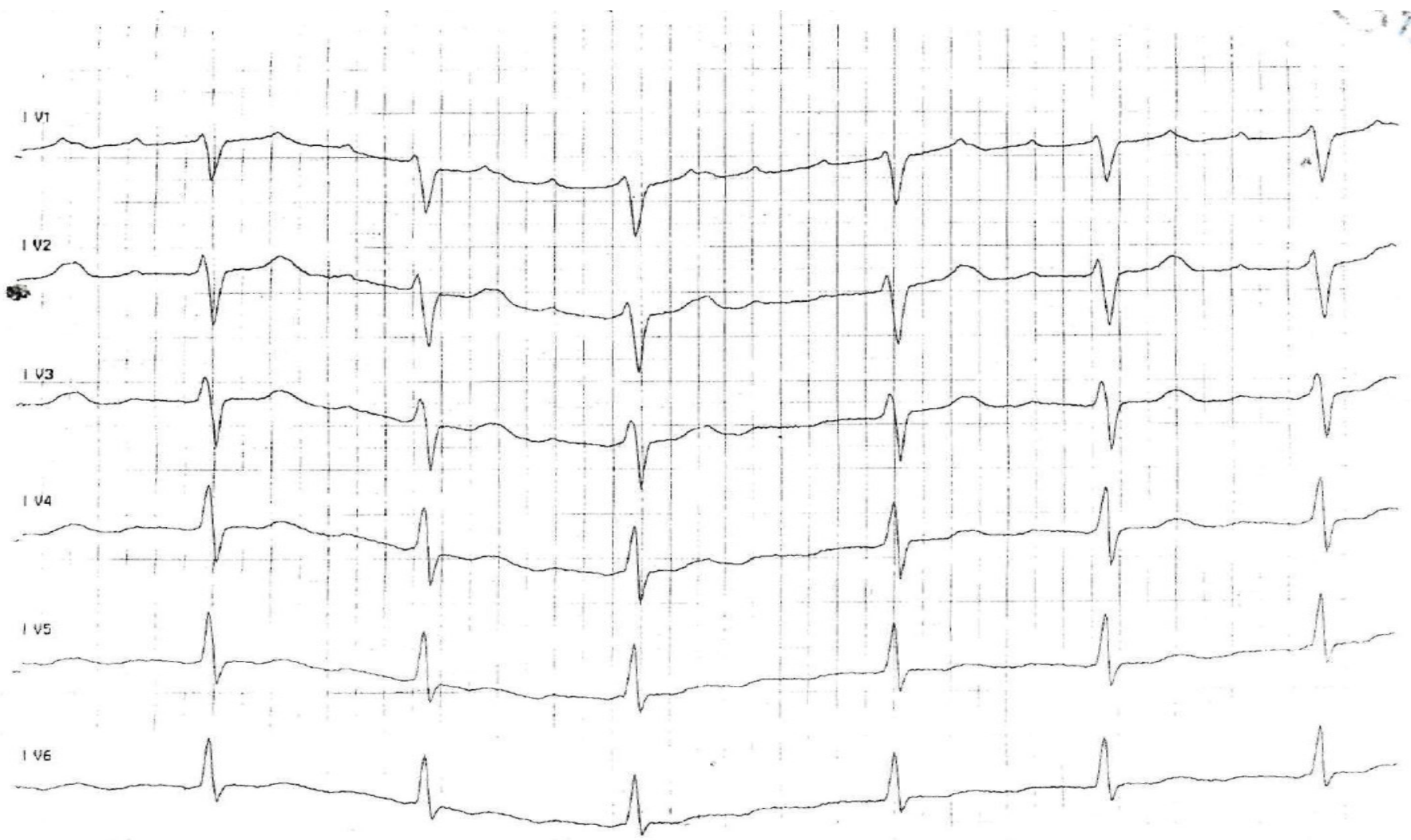
50 мм/с 0.05-35 Гц F50 AT-2 C 3.03

75

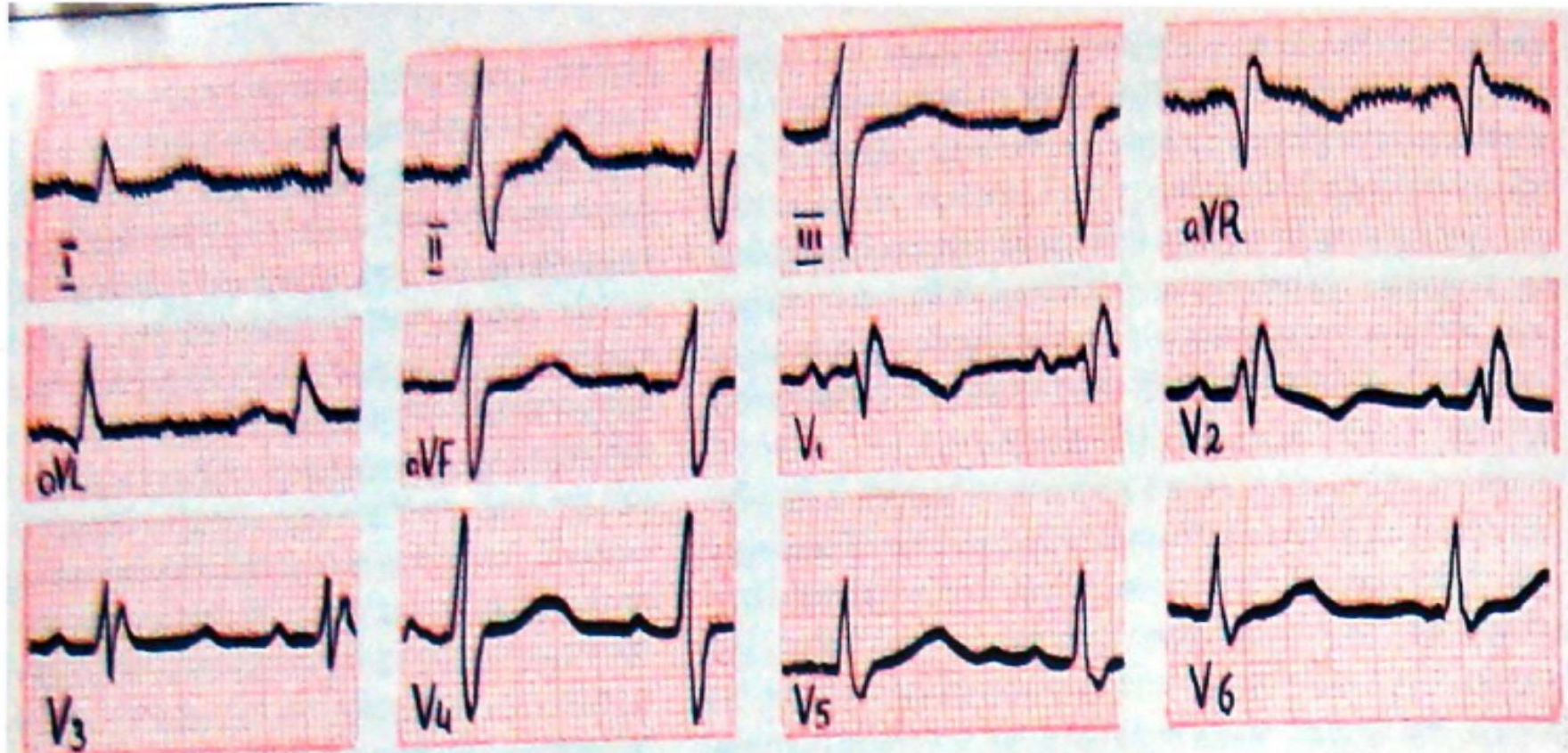


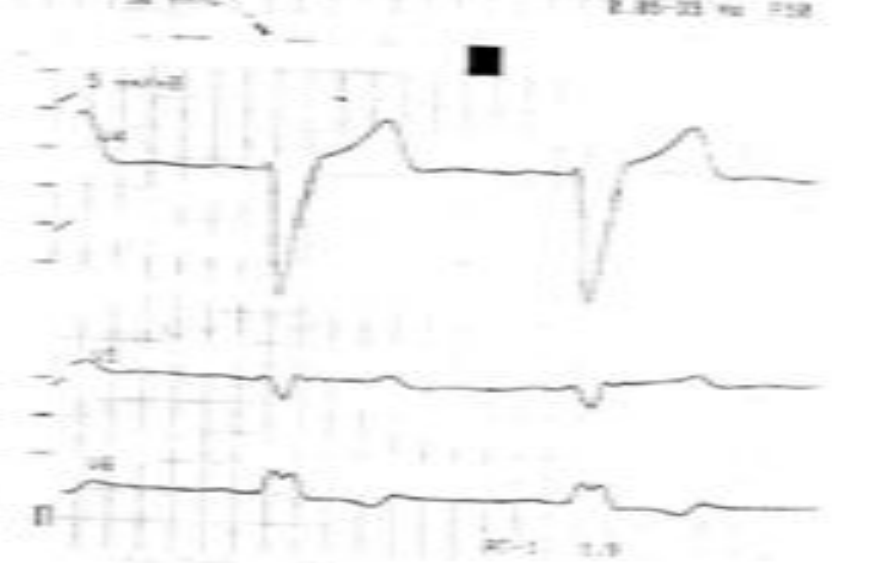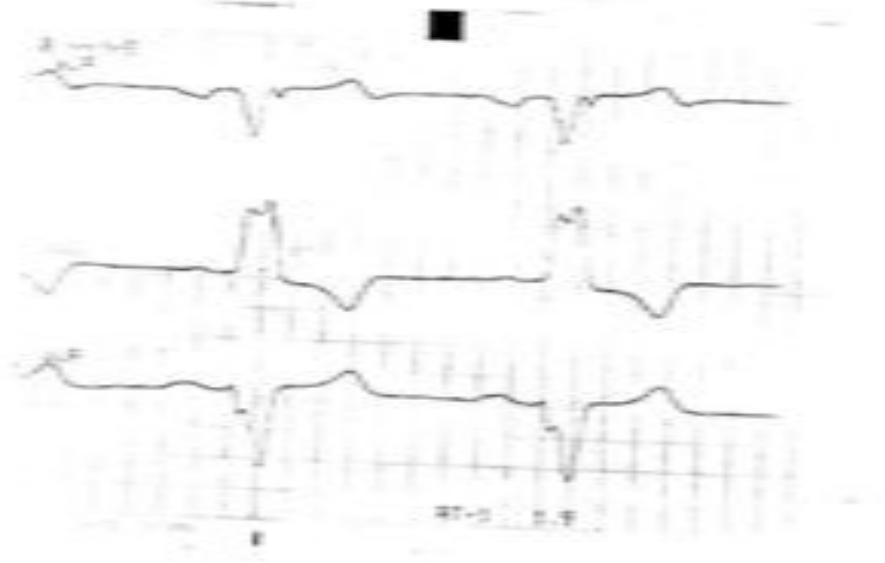
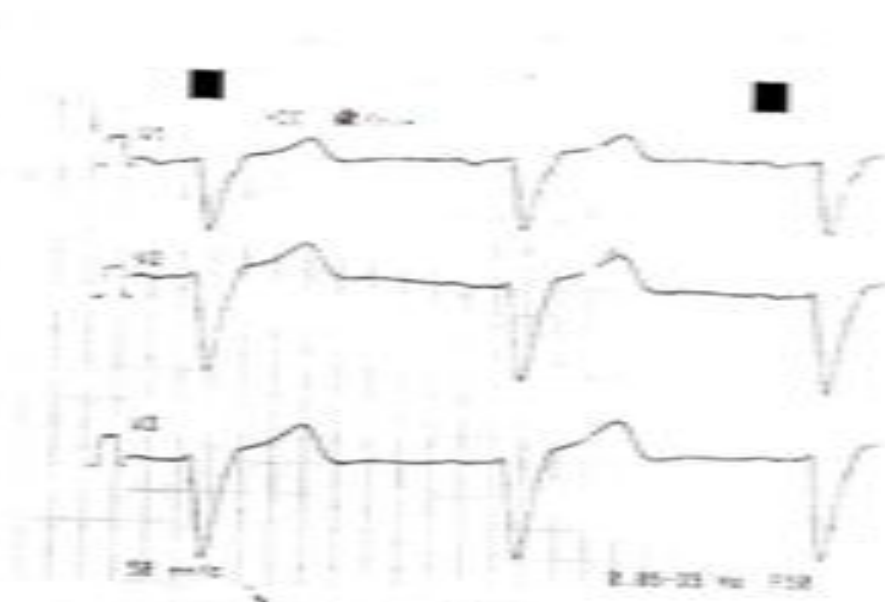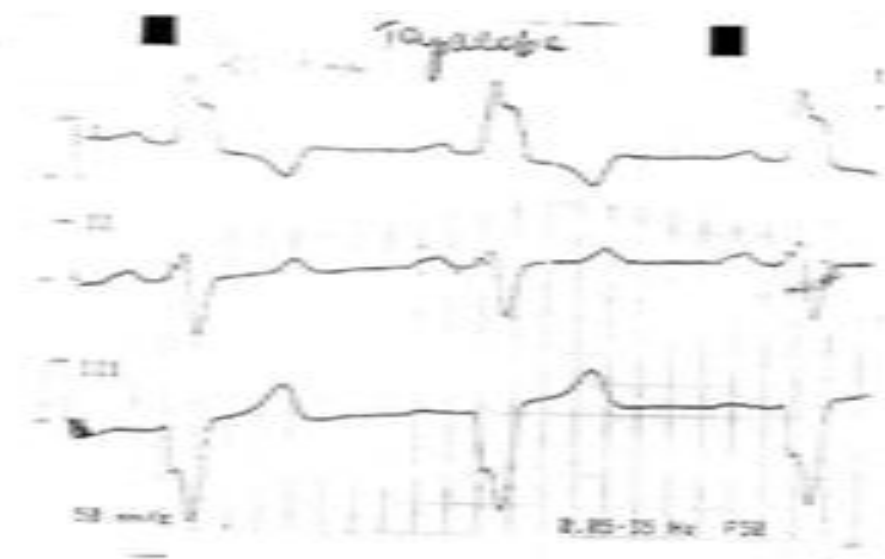Reviewed by:



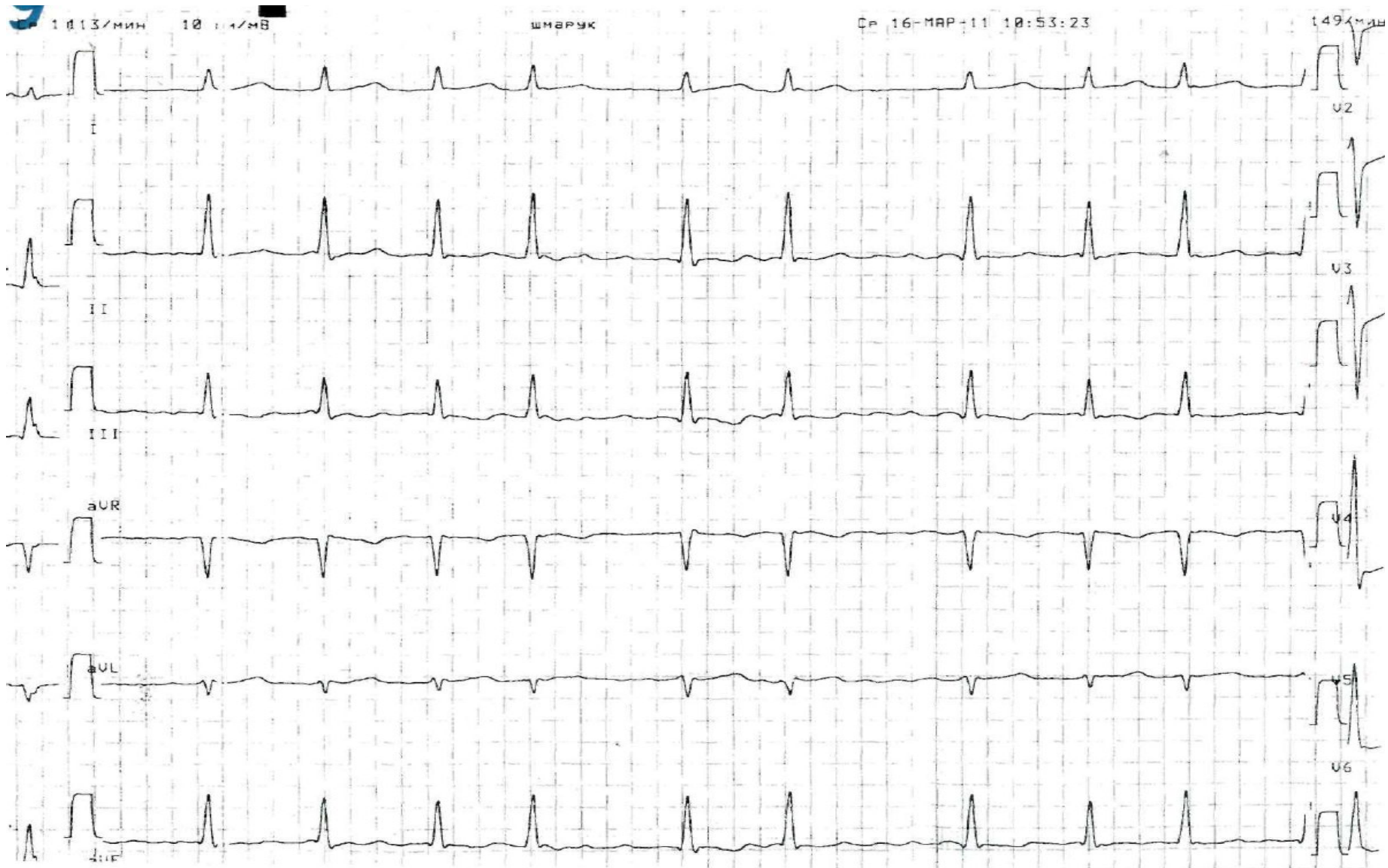


77





79

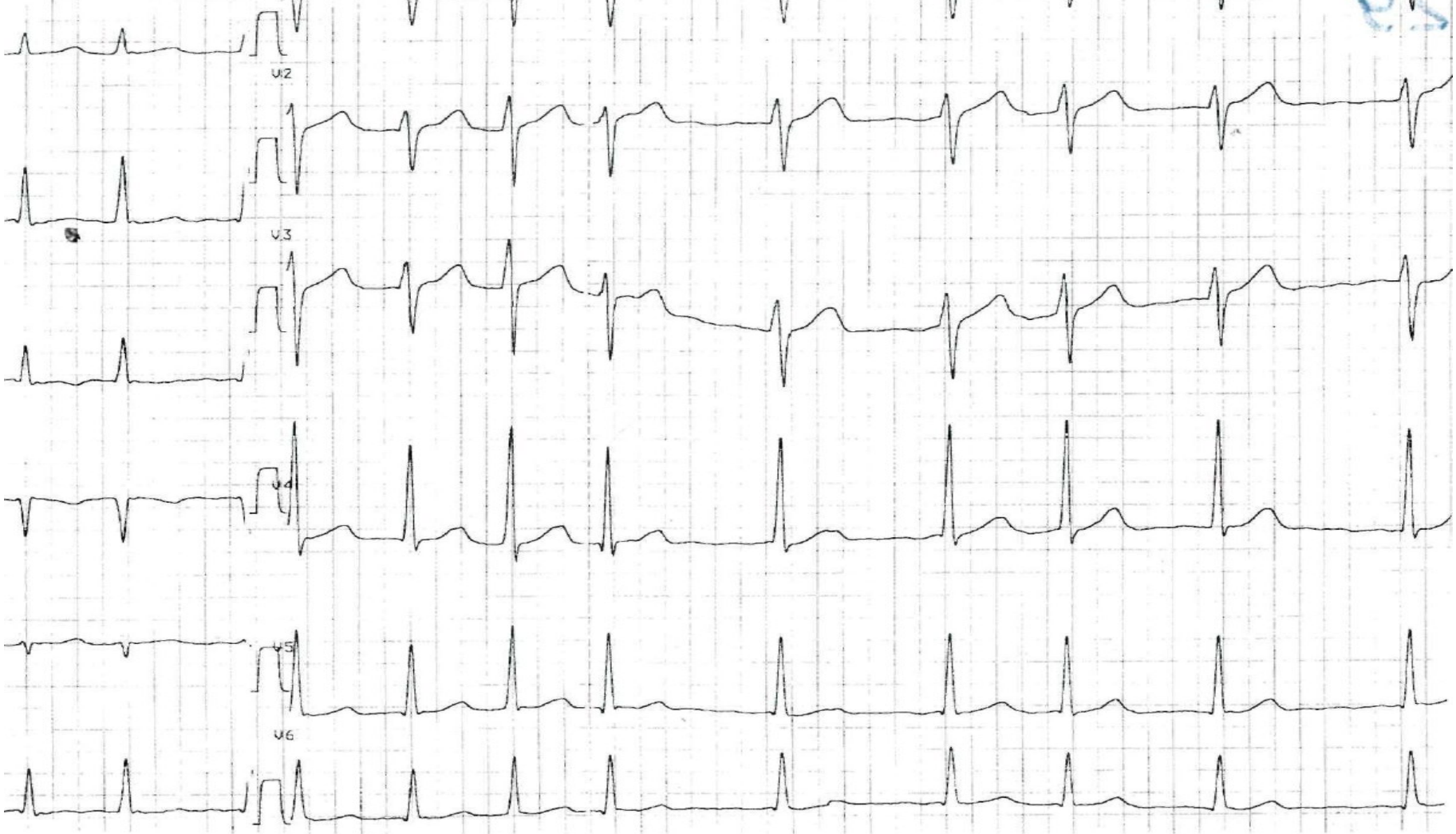

23

149 мин 10 мм/св

СР 16-МАР-11 18:53:31

23





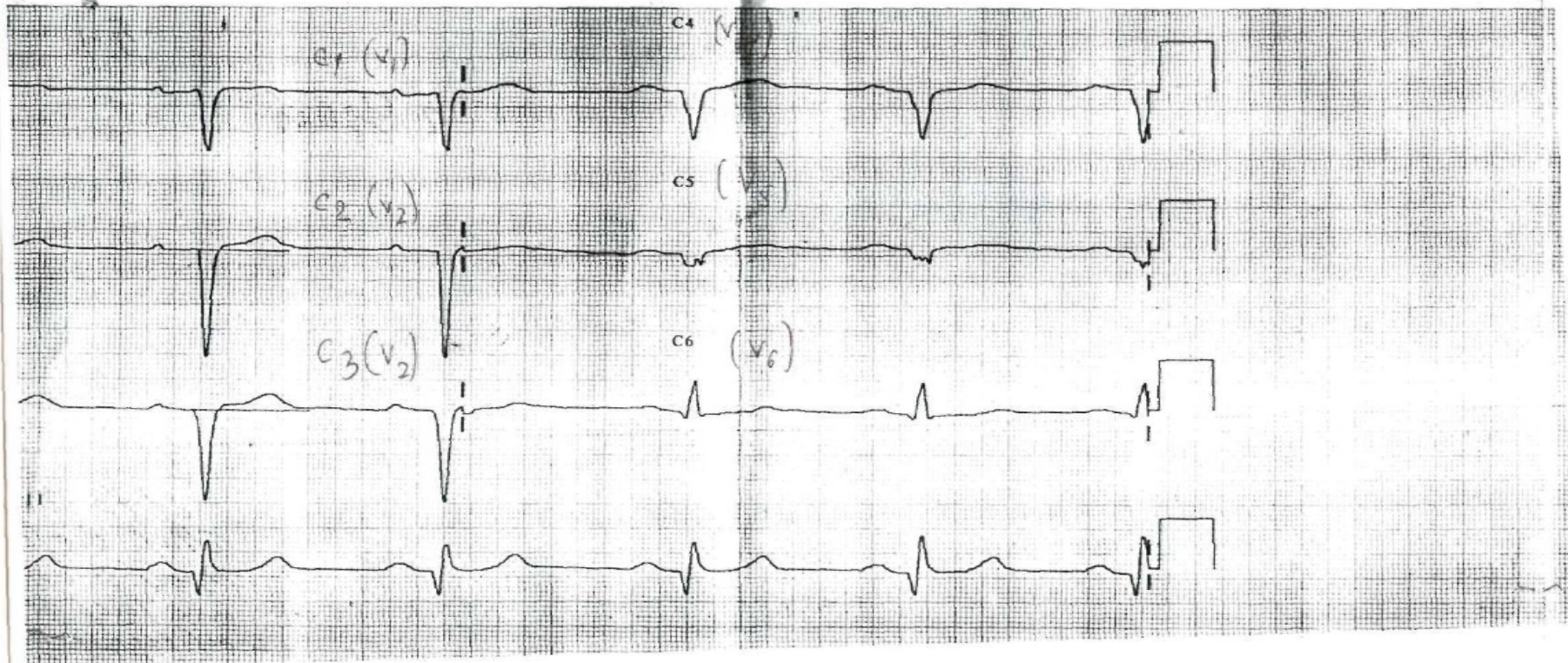
80

01-Мар-2007 14:02:18  
59 Годы

2 из 2

Мужской

Ханты Мансийская ОКБ ОФД



ЧСС 73 . NORMAL SINUS RHYTHM, RATE 73  
PR 176 . BORDERLINE LEFT ATRIAL ABNORMALITY  
ДЛQRS 88 . INFERIOR INFARCT, OLD  
QT 362 . EXTENSIVE ANTERIOR INFARCT, AGE INDETERMINATE  
QTc 399

--Ось--

P 55

QRS 7

T 80

Продолжение на следующей странице

- ABNORMAL ECG -

Неподтвержденный диагноз

