hookworm

Necator americanus

HAMED ALJAZAA

What is hookworm?

- Hookworm is an intestinal parasite of humans. The larvae and adult worms live in the small intestine can cause intestinal disease. The two main species of hookworm infecting humans are *Ancylostoma duodenale* and *Necator americanus*.

Causal Agent:

The human hookworms include the nematode species,

1. ***Ancylostoma duodenale* and**

2. ***Necator americanus*.**

THE INTESTINAL ROUNDWORMS OF MAN

HABITAT	IMPORTANT SPECIES	DISEASES CAUSED	GEOGRAPHICAL PREVALENCE
Intestinal worms without tissue stages	1. *Enterobius vermicularis*	Enterobiasis, oxyuriasis or pinworm infection	Worldwide with higher incidence in temperate and colder climates than in the tropics. More prevalent in children
	2. *Trichuris trichiuria*	Whipworm infection or trichuriasis	Worldwide with greater incidence in warm countries
Intestinal worms with tissue stages	1. *Ascaris lumbricoides*	Ascariasis or round-worm infection	Worldwide. Highest incidence in areas with poor sanitation, warm moist climate and poor economic and social development
	2. The hookworms: (a) *Ancylostoma duodenale* (b) *Necator americanus*	Hookworm disease, hookworm anaemia, ancylostomiasis, uncinariasis	*A. duodenale* (old world hook-worm): Europe, China, Japan, India, Africa *N. americanus* (new world hook-worm): southern Asia, South Africa, Central and South America, southern United States
	3. *Strongyloides stercoralis*	Strongyloidiasis	Worldwide but primarily in the tropics and subtropics

LIFE CYCLE HOOKWORM

1.Eggs are passed in the stool ,
and under favorable conditions (moisture, warmth, shade),
larvae hatch in 1 to 2 days.

2.The released rhabditiform larvae
grow in the feces and/or the soil and after 5 to 10 days (and two molts)

3.They become filariform (third-stage) .
These infective larvae can survive 3 to 4 weeks

The larvae penetrate the skin and are carried through
the blood vessels to the heart and then to the lungs.

They penetrate into the pulmonary alveoli,
ascend the bronchial tree to the pharynx, and are swallowed .

The larvae reach the small intestine,
where they reside and mature into adults.

4.Adult worms live in the lumen of the small intestine,
where they attach to the intestinal wall
with resultant blood loss by the host .

Most adult worms are eliminated in 1 to 2 years,
but the longevity may reach several years.

LIFE CYCLE HOOKWORM

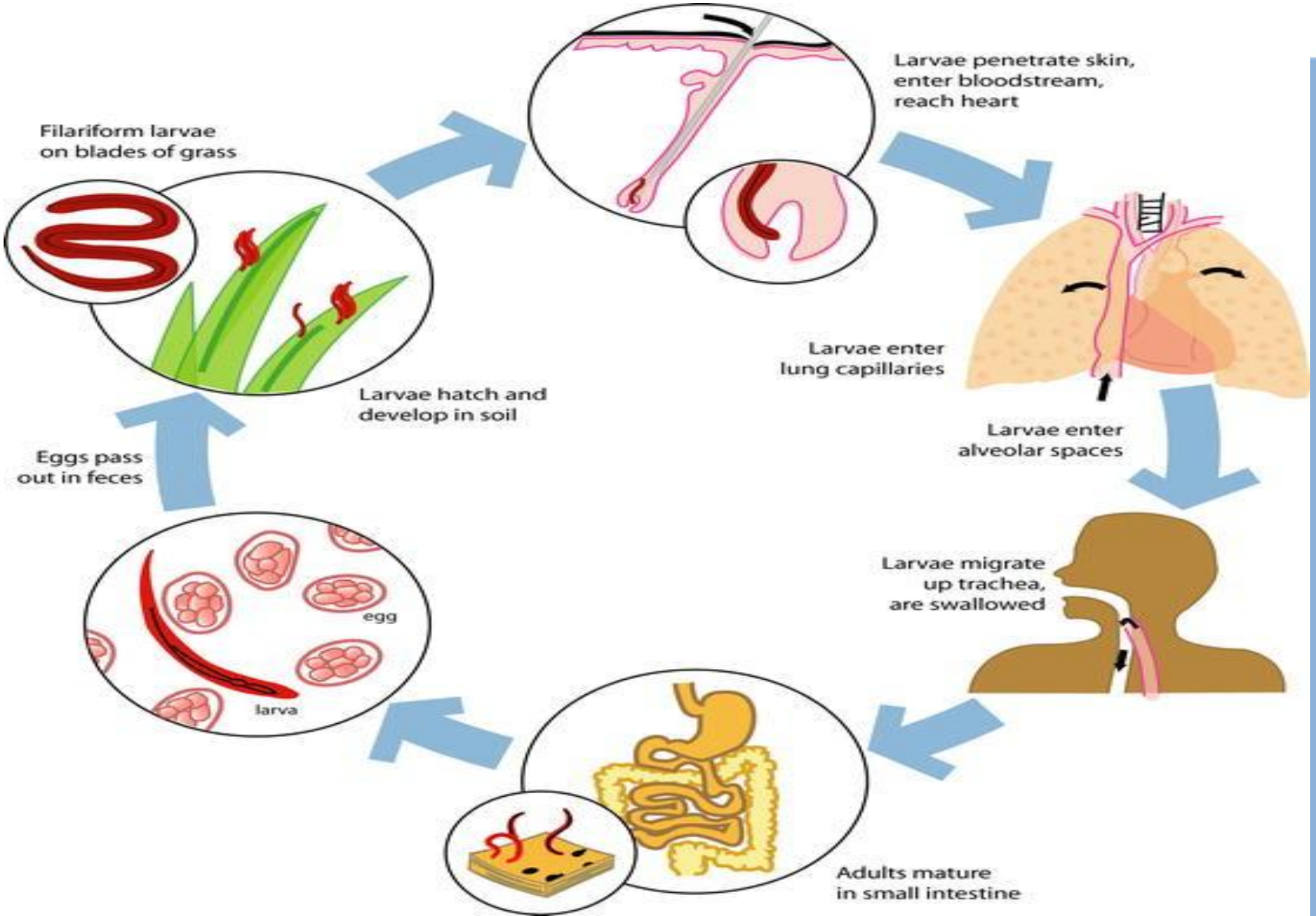

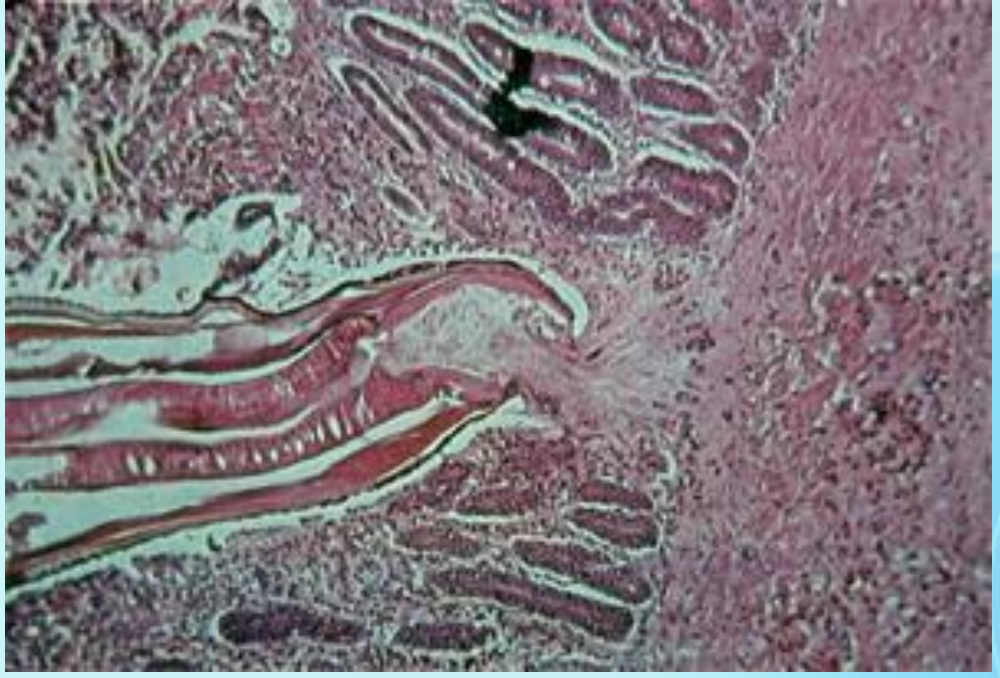

SYMPTOM & SIGN

High-intensity infections with these worms are less common among adults.

The most serious effects infection are the anemia and protein deficiency (blood loss) at the intestinal attachment of the adult worms.

When children are continuously infected by many worms, the loss of iron and protein can retard growth and mental development.

If you do experience symptoms, they generally start with itchiness and a small rash caused by an allergic reaction in the area that the larvae entered your skin. This is generally followed by diarrhea as the hookworms grow in your intestine. Other symptoms include:

- abdominal pain
- colic, or cramping and excessive crying in infants
- intestinal cramps
- nausea
- a fever
- blood in your stool
- a loss of appetite
- itchy rash

DIAGNOSE

Health care providers can diagnose hookworm by taking a stool sample and using a microscope to look for the presence of hookworm eggs.

Hookworm eggs in a stool .

Because eggs may be difficult
to find in light infections,
a concentration procedure is recommended.

Treatment

Hookworm infection is treated with albendazole, mebendazole, or pyrantel pamoate
Dosage is the same for children as for adults.
Albendazole should be taken with food.
Albendazole
is not FDA-approved for treating hookworm infection.

Drug	Dosage for adults and children
Albendazole	400 mg orally once
Mebendazole	100 mg orally twice a day for 3 days or 500 mg orally once
Pyrantel pamoate	11 mg/kg (up to a maximum of 1 g) orally daily for 3 days

PREVENTION & CONTROL

The best way to avoid hookworm infection is not to walk barefoot in areas

@ where hookworm is common and

@ where there may be human fecal contamination of the soil.

@ avoid other skin contact with such soil and avoid ingesting it.

Infection can also be prevented by not defecating outdoors and by effective sewage disposal systems.

Differential features of *Necator* and *Ancylostoma*

	Necator	*Ancylostoma*
ADULTS		
Size	♂ 5–9 × 0·3 mm ♀ 9–11 × 0·35 mm	♂ 8–11 × 0·45 mm ♀ 10–13 × 0·6 mm
Shape	Head small, bent acutely in opposite direction to general curve.	Bow shaped curve; head in same line as body.
Buccal capsule	Almost spherical.	Elongated, pear-shaped.
Mouth	Guarded by 2 semilunar cuticular cutting plates.	Guarded by 2 pairs of curved teeth.
FEMALE:		
Tail	No spine.	Sharp spine (often lost).
Vulva	Anterior to middle.	Posterior to middle.
MALE:		
Bursa	Narrow, longer than wide	Outspread, wider than long.
Dorsal ray	Deeply cleft. Tip of each cleft divided into two.	Shallow cleft. Tip of each cleft divided into three.
Spicules	Tips usually united and recurved.	Tips not united.
EGGS	Indistinguishable	
1ST & 2ND STAGE LARVAE	Indistinguishable	
3RD STAGE INFECTIVE LARVAE		
Size	Body length 590 μm Overall length 660 μm	Body length 660 μm Overall length 720 μm
Tail	Short and pointed (63 μm).	Long and blunt (85 μm)
Sheath	Marked striations especially at posterior end.	Faint cuticular striations.
Head	Pointed.	Blunt.
Intestine	Apparent gap between intestine and oesophagus.	No apparent gap between intestine and oesophagus.
Oesophageal spears	Prominent. Anterior end shaped like thistle funnel.	Not so prominent. Tips do not diverge.

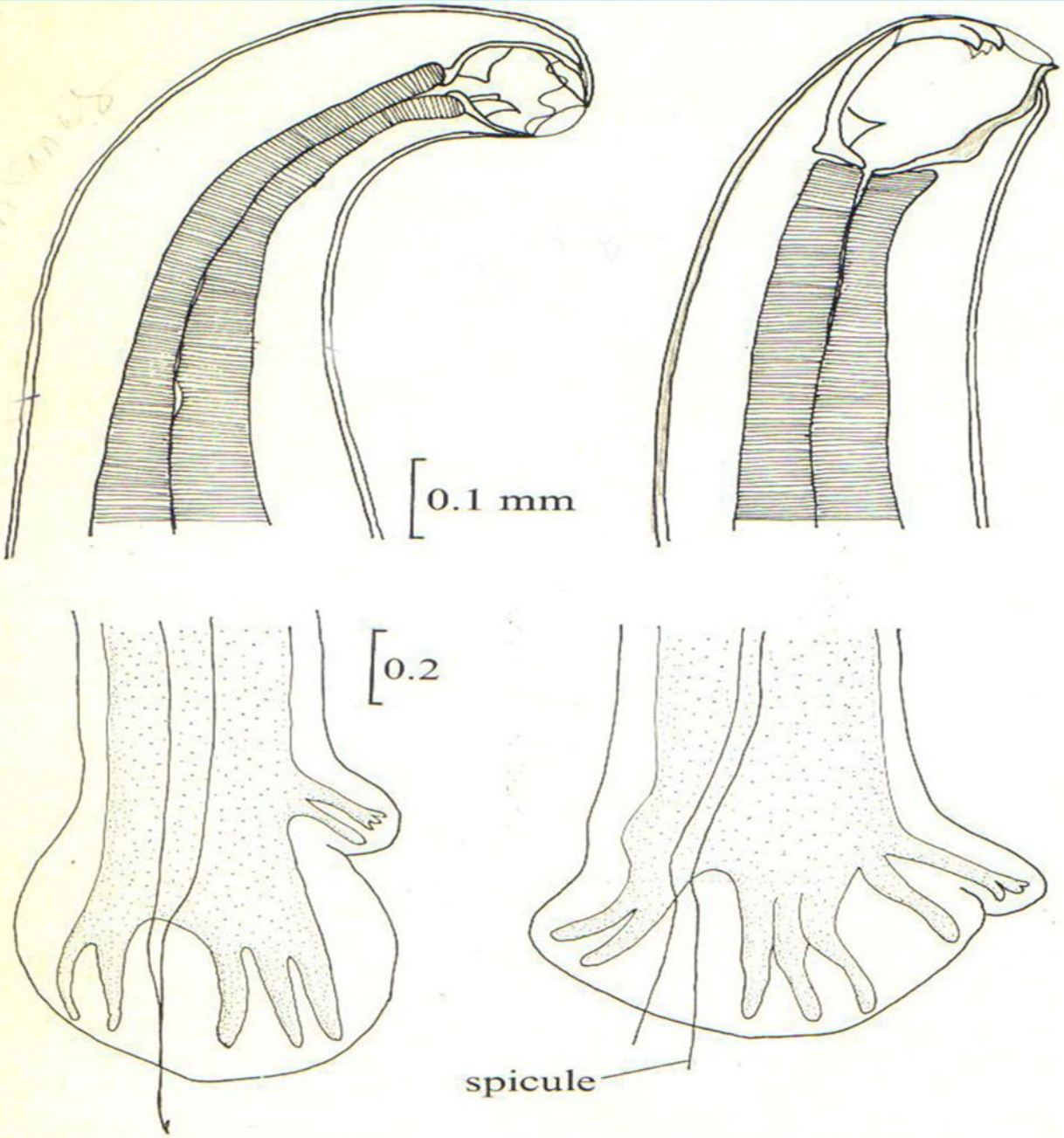

Fig 211 Anterior end and caudal bursa of male *N. americanus* (left) and *A. duodenale*

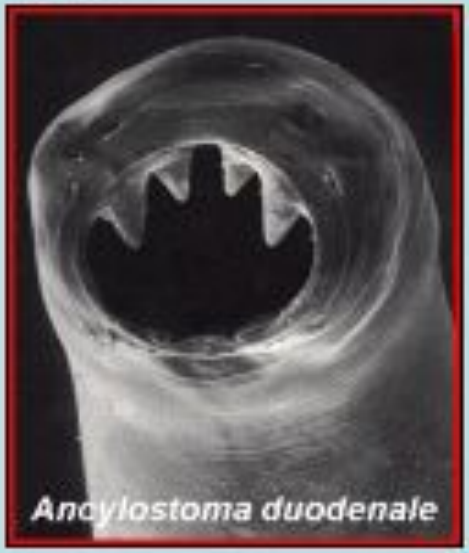

Fig 212 : Anterior end (Buccal capsule) of A. duodenale with teeth and N. americanus with plate

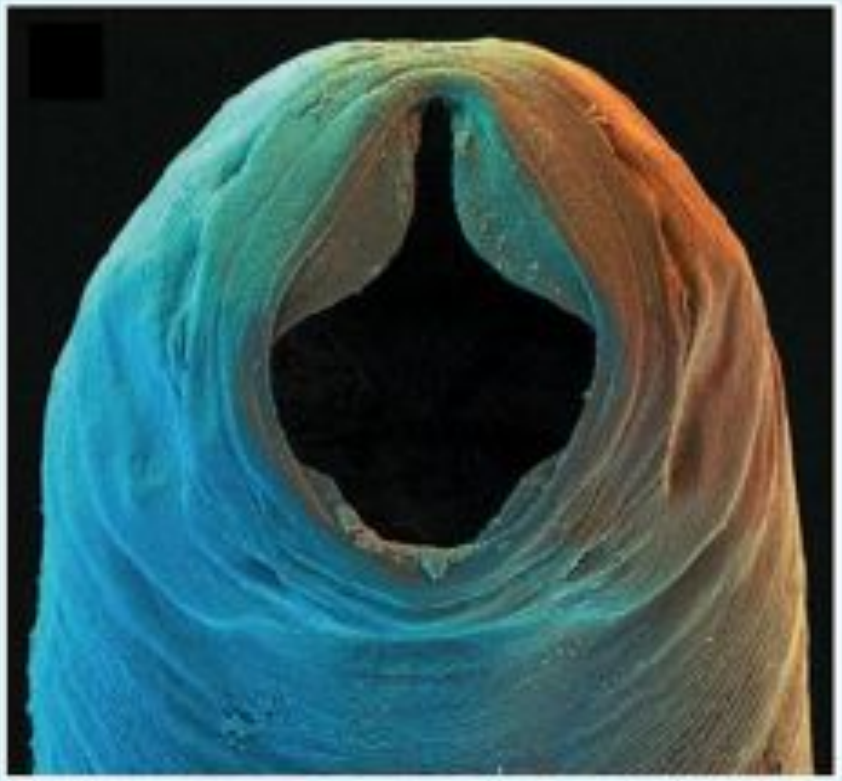

Fig 213 : Necator americanus anterior end

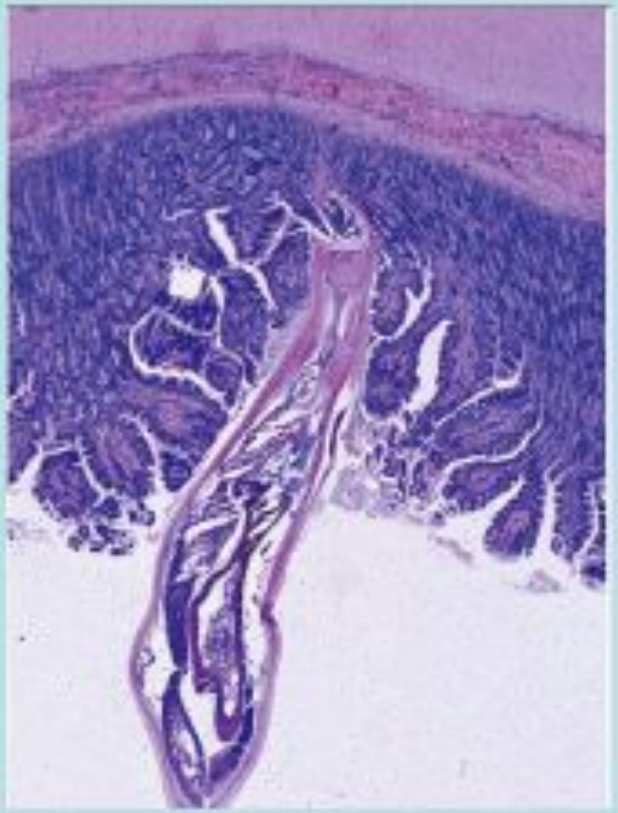

Fig 214 : HooKWorm
In Small Intestine Section

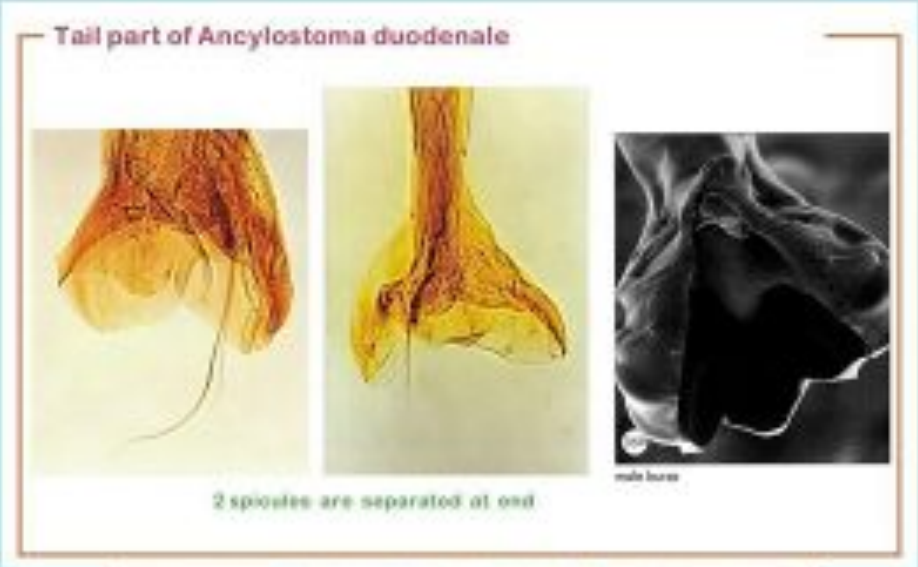

Fig 215 : posterior end in male (Bursa) of A. duodenale

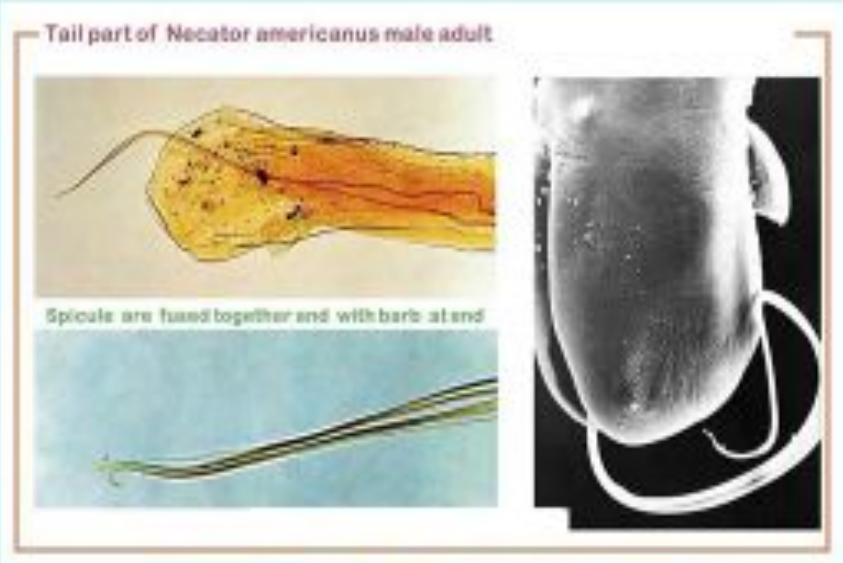

Fig 216 : posterior end in male (Bursa) of N. americanus

Tail part of Ancylostoma duodenale female adult

With a caudal spine at end

Fig 217 : posterior end in female of A. duodenale

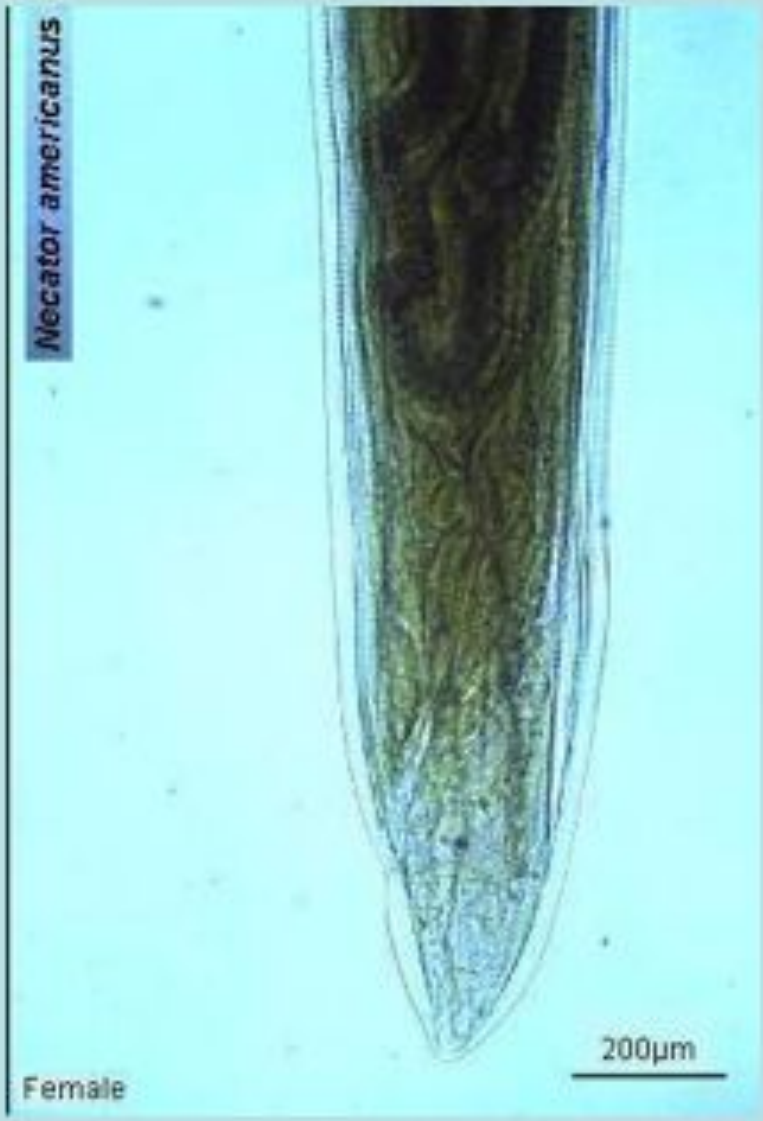

Fig 218 : posterior end in female of N. americanus

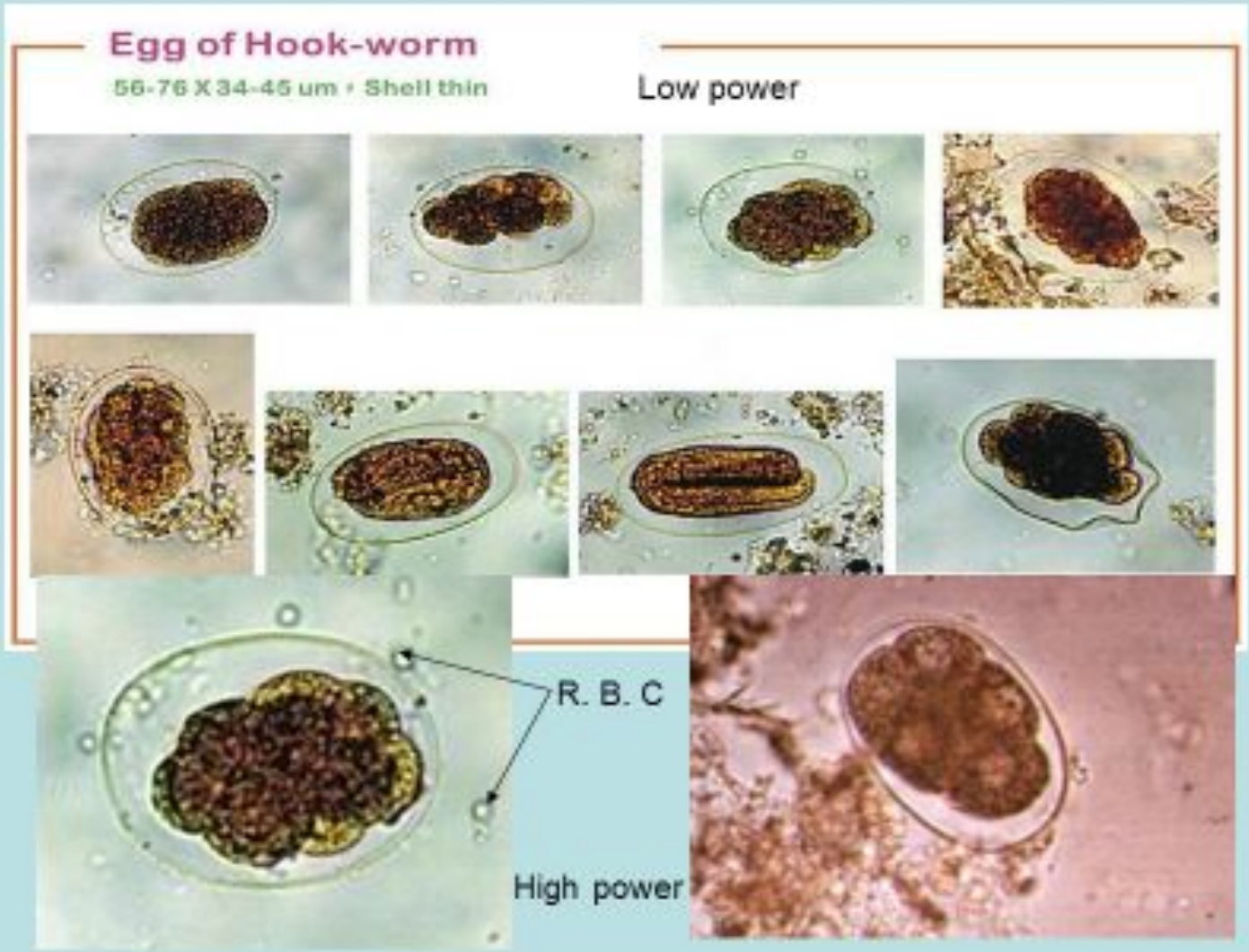

Fig 219 : hookworm eggs in stool smear (colour less, oval in shape, thin one walled shell segmented from 1 – 8 cell in fresh stool **Iodine stain**

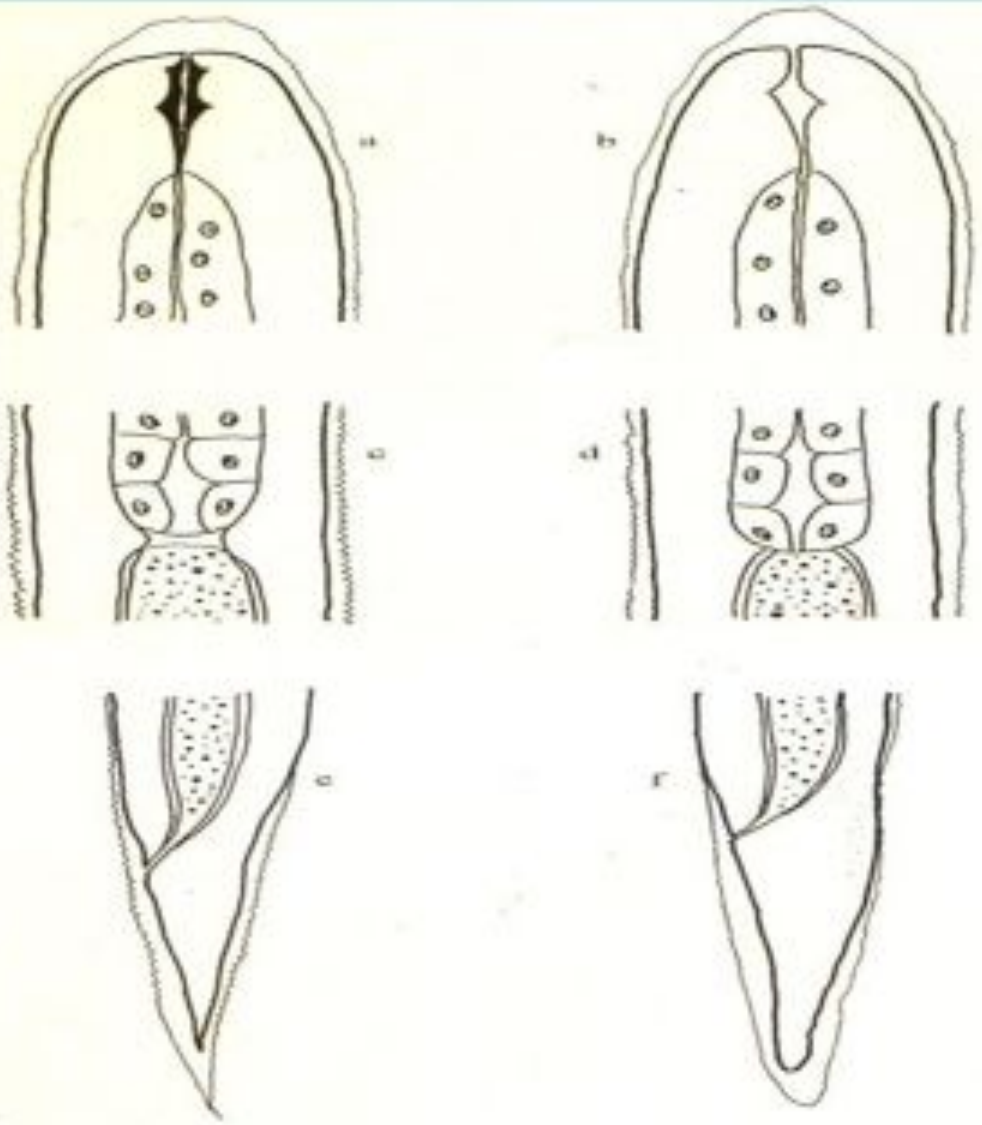

Differential features of
3rd stage larvae of hookworms

FIG. 220 3rd stage larvae of *Necator* (left) and *Ancylostoma*: a and b anterior ends; c and d junction of oesophagus and intestine, e and f tail ends.

Fig 221 : Ancylostoma duodenale Filariform Larva in sputum

CLM

Larva currens

Fig 222 : Ground itch, allergic skin reaction, at site of entry of larvae of hook worm


THANK YOU