

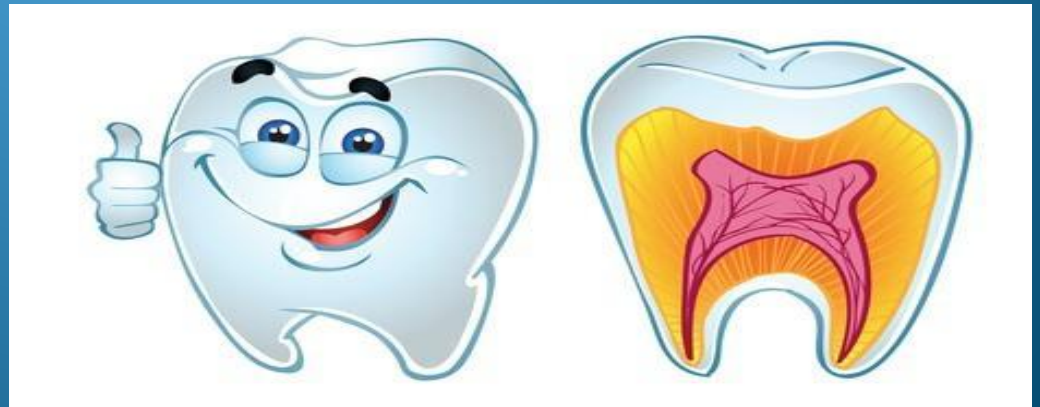
Karaganda State Medical University

The chair of foreign languages

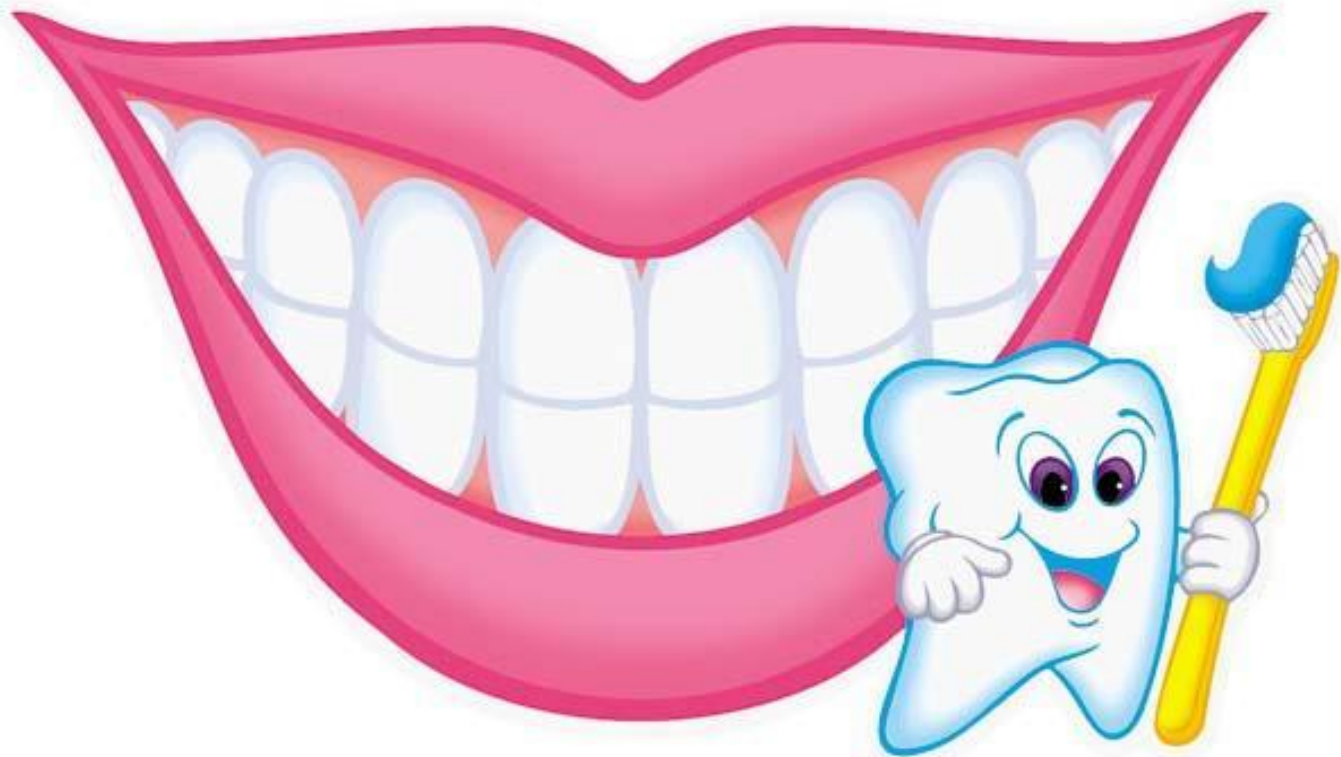

The classification of the tooth.

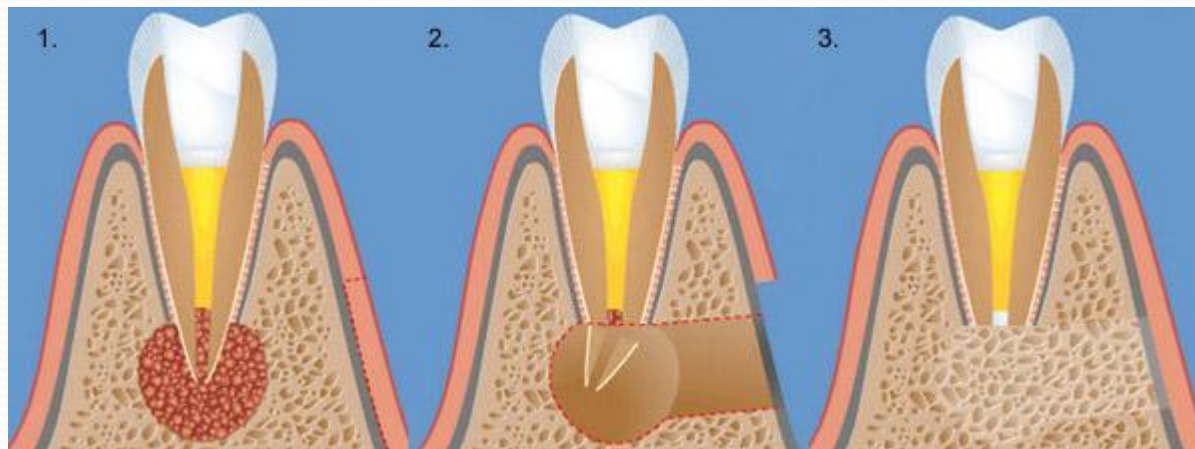
Made by: Koshakaeva Dinara 2-006 STOM
Checked by : Dashkina T.G.



- Teeth of humans are small, calcified, whitish structures found in the mouth that are used to break down food. The roots of teeth are embedded in the maxilla (upper jaw) or the mandible (lower jaw) and are covered by gums. Teeth are made of multiple tissues of varying density and hardness. Teeth are among the most distinctive (and long-lasting) features of mammal species. Humans, like other mammals, are diphyodont, meaning that they develop two sets of teeth. The first set (also called the "baby", "milk", "primary", and "deciduous" set) normally starts to appear at about six months of age, although some babies are born with one or more visible teeth, known as neonatal teeth. Normal tooth eruption at about six months is known as teething and can be painful.



- The anatomic crown of a tooth is the area covered in enamel above the cementoenamel junction (CEJ) or "neck" of the tooth. Most of the crown is composed of dentin (dentine in British English) with the pulp chamber inside. The crown is within bone before eruption. After eruption, it is almost always visible. The anatomic root is found below the CEJ and is covered with cementum. As with the crown, dentin composes most of the root, which normally have pulp canals. A tooth may have multiple roots or just one root (single-rooted teeth).



- Canines and most premolars, except for maxillary first premolars, usually have one root. Maxillary first premolars and mandibular molars usually have two roots. Maxillary molars usually have three roots. Additional roots are referred to as supernumerary roots. Humans usually have 20 primary (deciduous or "baby") teeth and 32 permanent (adult) teeth. Teeth are classified as incisors, canines, premolars, and molars. Incisors are primarily used for biting pieces from foods such as raw carrots or apples and peeled but uncut bananas, while molars are used primarily for grinding foods after they are already in bite size pieces inside the mouth. Most teeth have identifiable features that distinguish them from others.

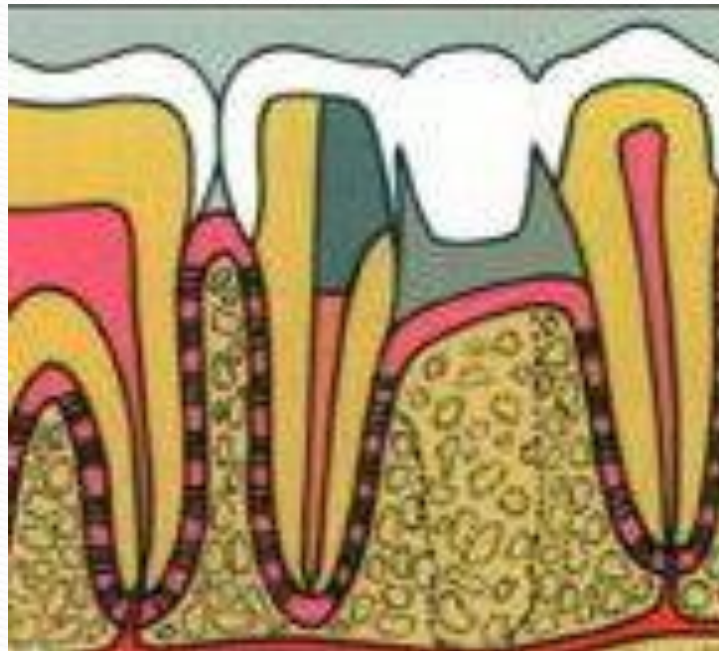

incisor


canine


molar

- There are several different notation systems to refer to a specific tooth. The three most common systems are the FDI World Dental Federation notation, the universal numbering system, and Palmer notation method. The FDI system is used worldwide, and the universal is used widely in the United States.



- **Sequence of tenses** - this time dependence of the verb of the subordinate clause from the time of the verb of the main clause.
- If the verb-predicate of the main clause is in a form of the past tense - the predicate verb of the subordinate clause (mainly *izjasnitelnyh*) also stands in one of the forms of the past tense.
- ❖ She asked what he was doing in her room. — Она спросила, что он делает в ее комнате.
- ❖ He said that he knew my friend. — Он сказал, что он знает моего друга.

- 
- ❖ If the action of the subordinate clause occurs simultaneously with the main action, the verb of the subordinate clause is used in the Past Simple or Past Progressive.
 - ❖ He said that they played football on Sundays. — Он сказал, что они играют в футбол по воскресеньям.
 - ❖ She said that he was reading a newspaper. — Она сказала, что он читает газету.

- 
- If the action of the subordinate clause is the future in relation to the action of the main clause, the verb of the subordinate clause is used in the form of Future-in-the Past (см. Grammar Notes).
 - He said that he would help him. — Он сказал, что поможет ему.