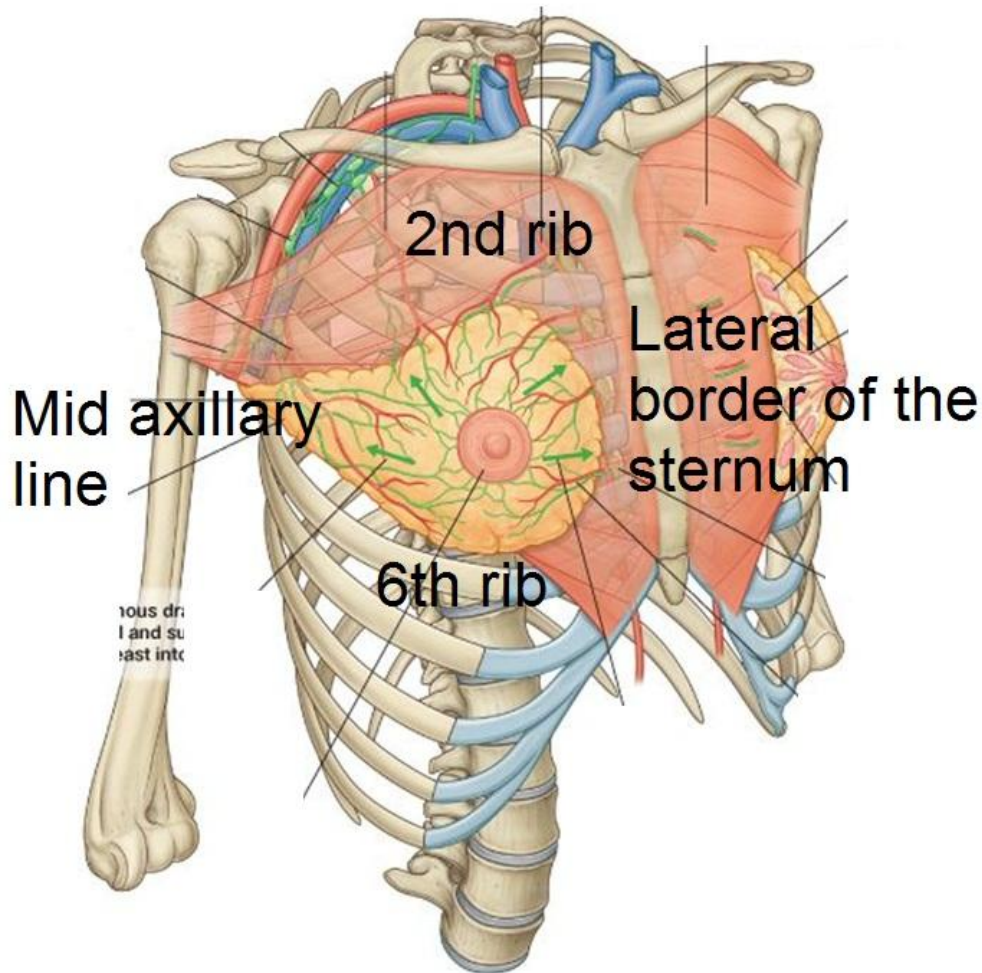


Breast Lump And Nipple Discharge

Anatomy of the Breast

Position & extent

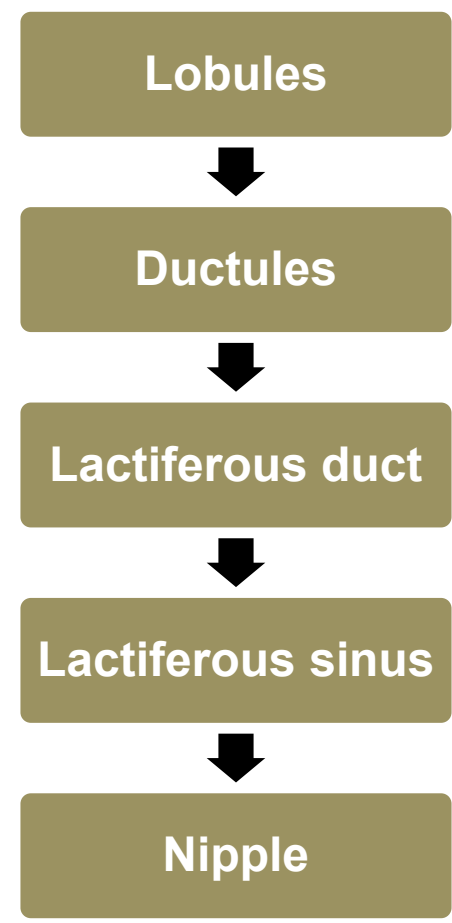
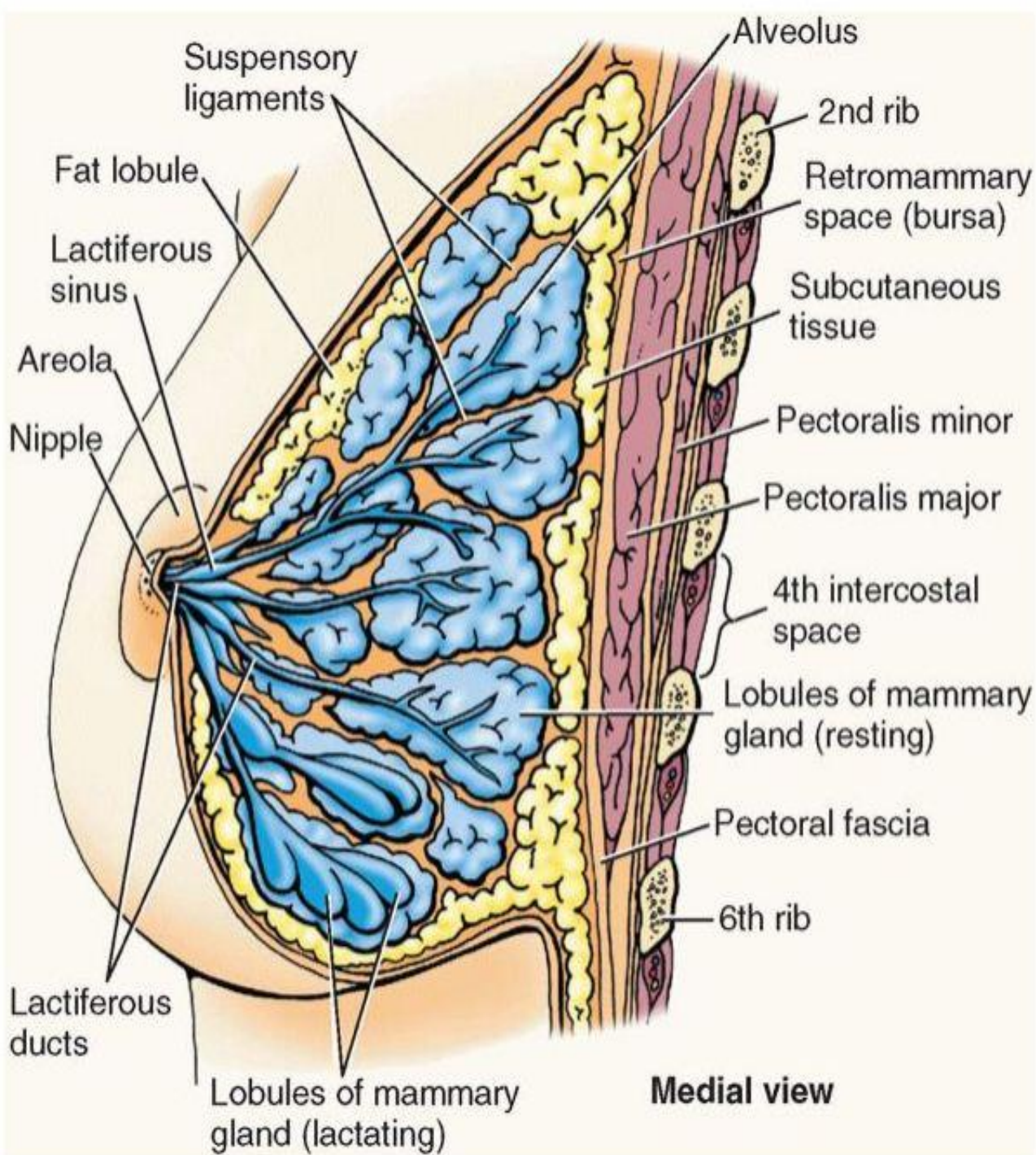


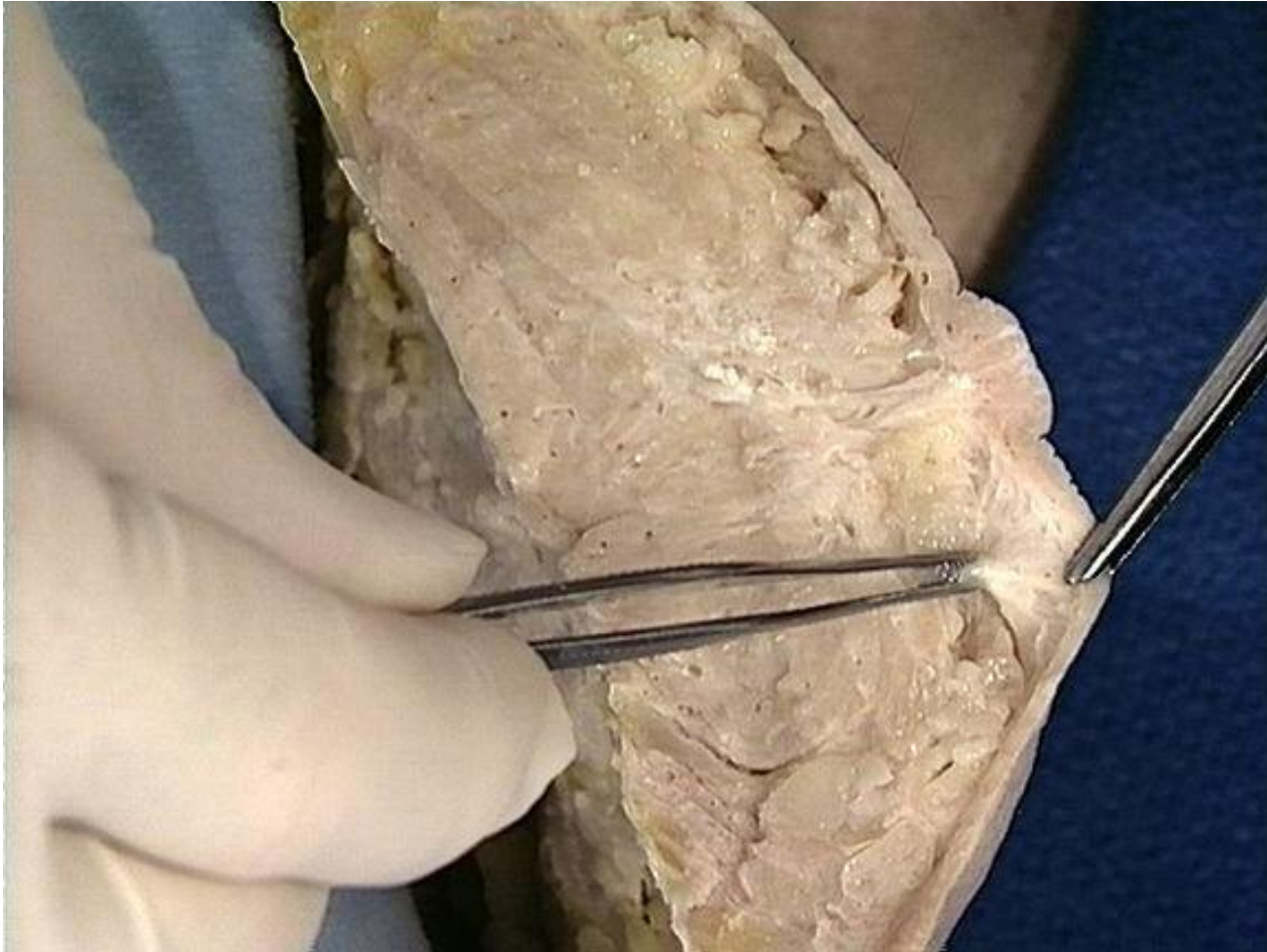- Extends from the **2nd to the 6th rib** & from the lateral margin of the sternum to the mid/anterior axillary line.
- 2/3 rests on **pectoralis major**, 1/3 on **serratus anterior**,
- while its lower medial edge just overlaps the upper part of the **rectus sheath**.

Structure of the Breast

- **The lobule is the basic structural unit** of the mammary gland. The number and size of the lobules vary enormously: they are most numerous in young women. From 10 to over 100 lobules empty via ductules into a lactiferous duct, of which there are 15-20. Each lactiferous duct is lined with a spiral arrangement of contractile myoepithelial cells and is provided with a terminal ampulla, a reservoir for milk or abnormal discharges.
- **The nipple is covered by thick skin with corrugations.** Near its apex lie the orifices of the lactiferous ducts. The nipple contains smooth muscle fibres arranged concentrically and longitudinally; thus, it is an erectile structure, which points outwards.

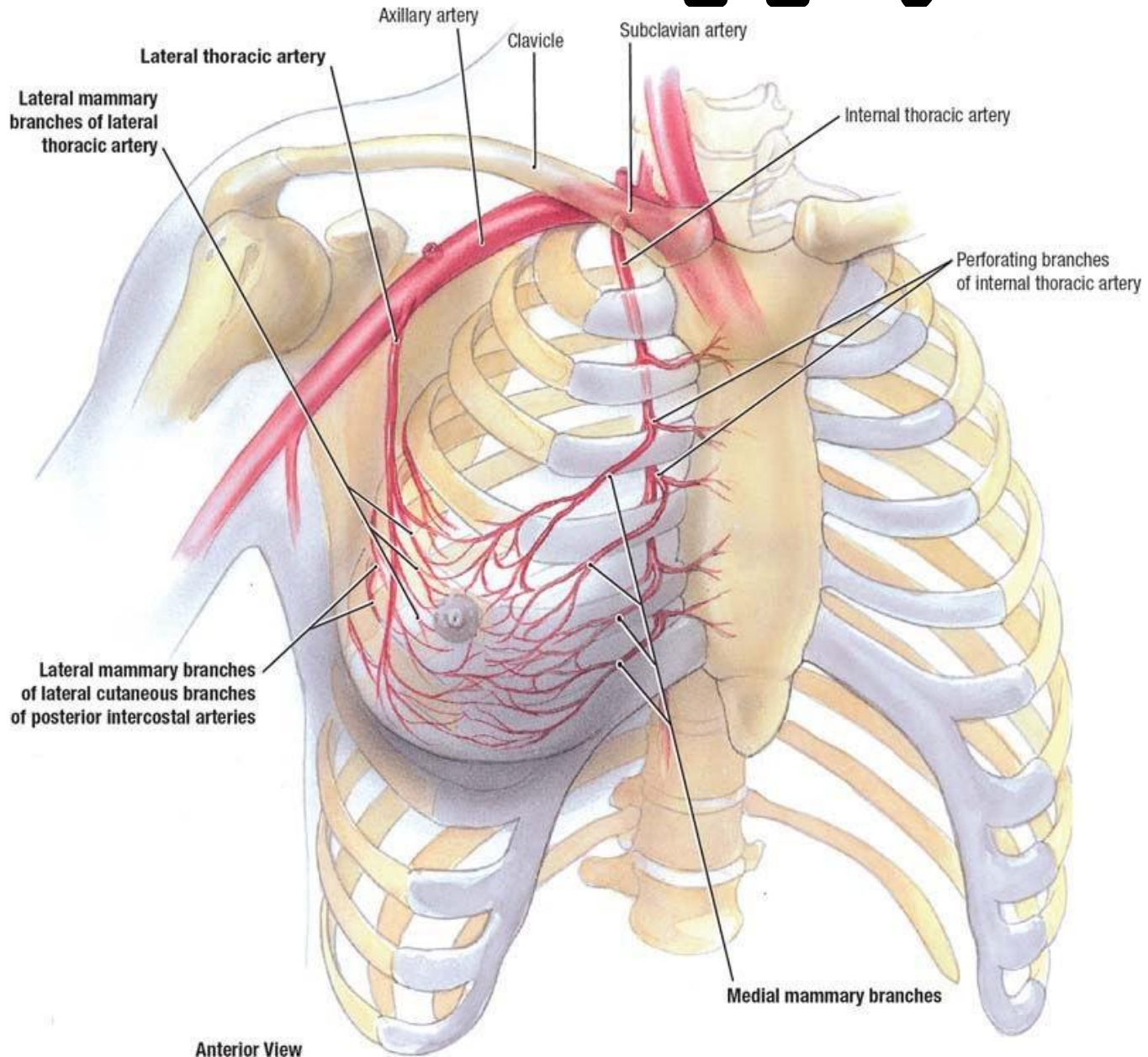
- **The ligaments of Cooper** are hollow conical projections of fibrous tissue filled with breast tissue; the apices of the cones are attached firmly to the superficial fascia and thereby to the skin overlying the breast. The shape of the breasts is naturally determined by the support of the suspensory Cooper's ligaments





The ligaments of Cooper

Blood supply



Blood supply

1. **Internal thoracic "mammary" artery** - perforating branches
2. **Axillary artery** -
 1. Lateral thoracic artery "mainly"
 2. Superior thoracic artery
 3. Acromiothoracic artery
3. **Posterior intercostal arteries** - lateral branches
- relatively unimportant source

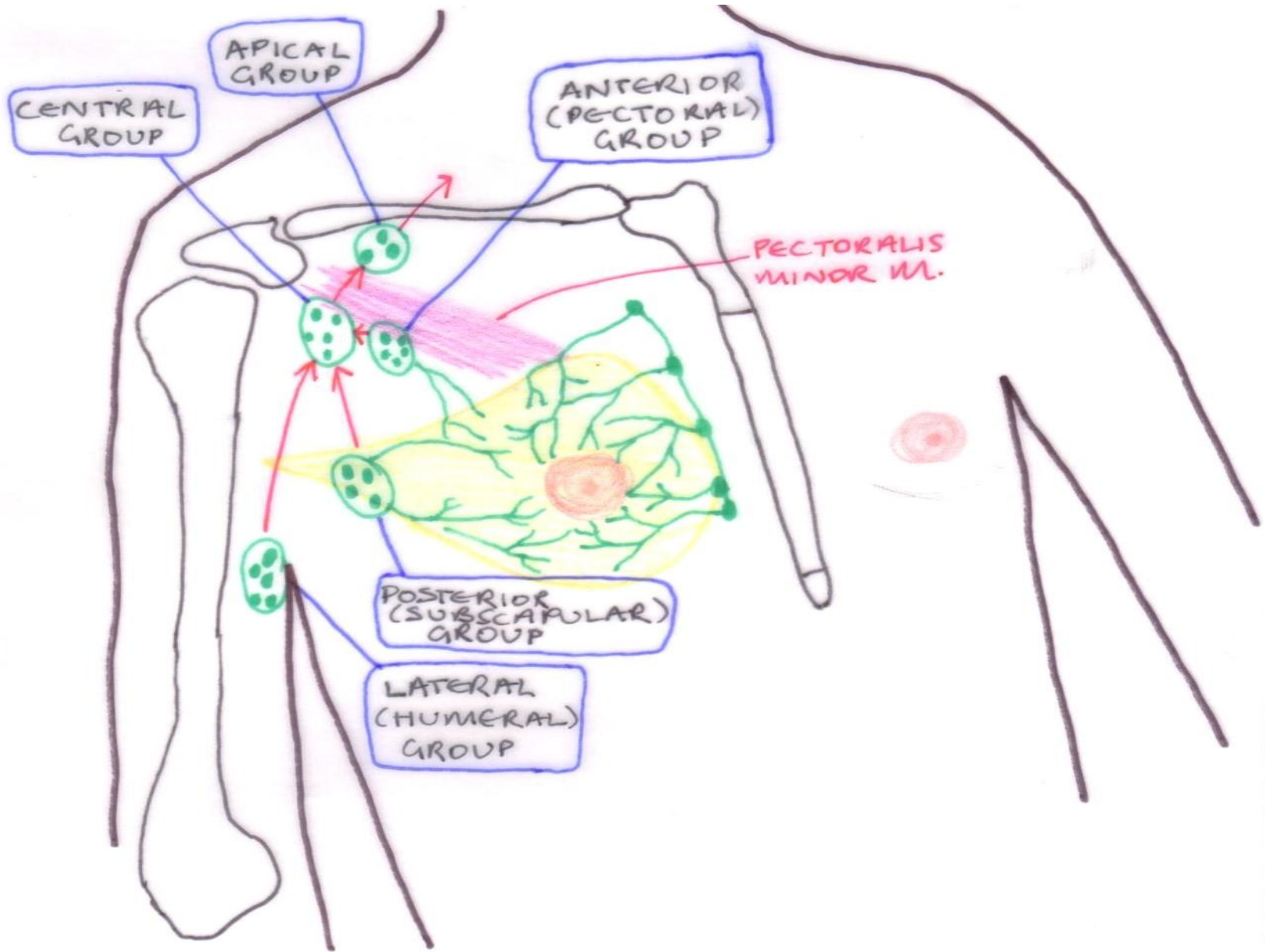
Venous drainage

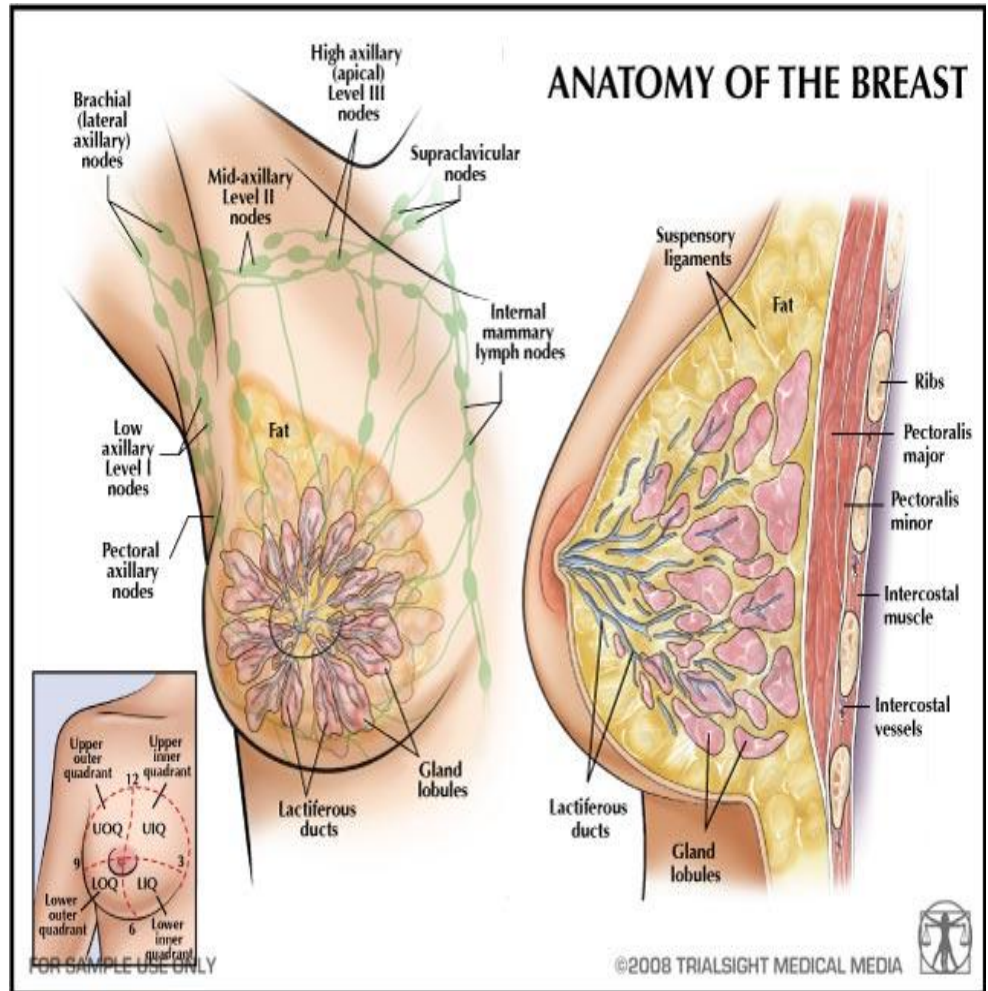
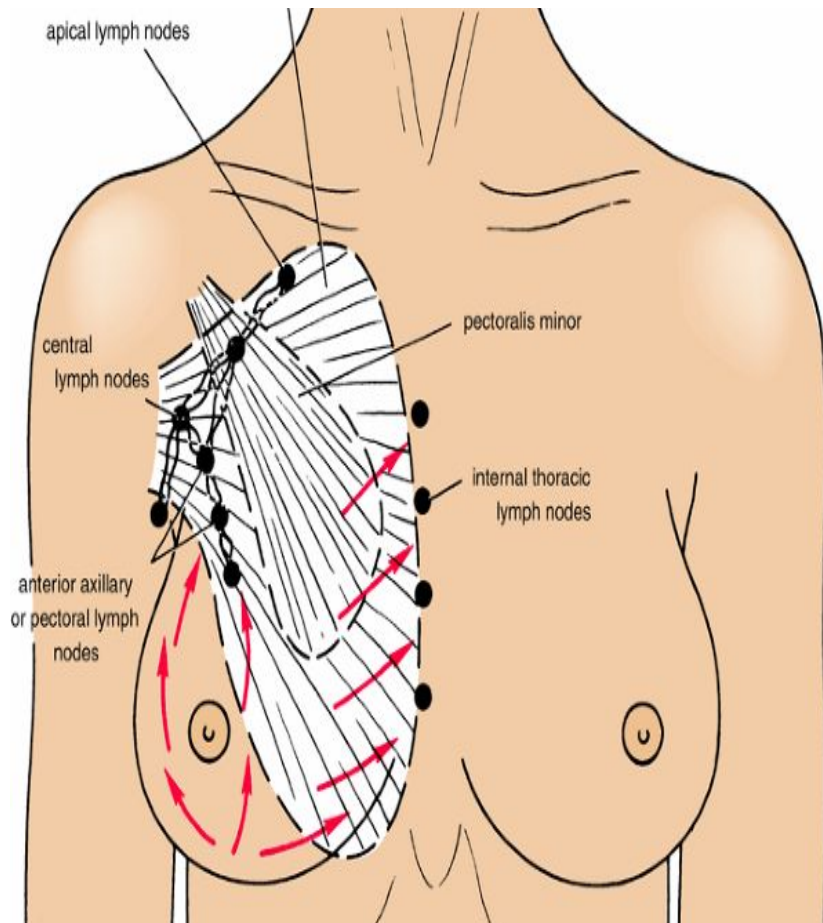
- Sub areolar venous plexus
- Posterior intercostal veins communicate with internal vertebral venous plexus veins - therefore cancers can spread to vertebra- may cause back pain

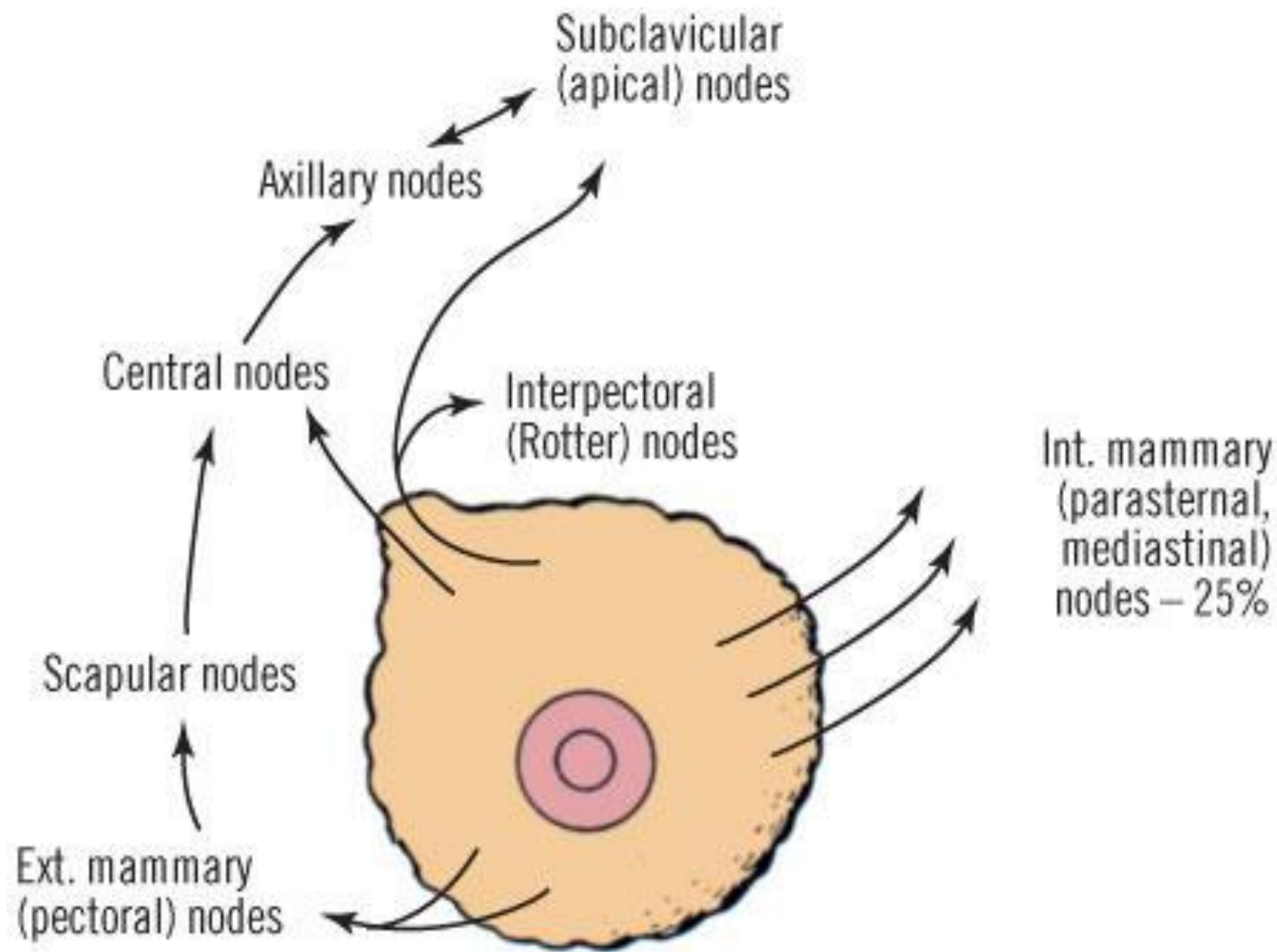
Nerves of the Breast

- Cutaneous innervation
- Medial pectoral nerve
- Lateral pectoral nerve
- Long thoracic nerve

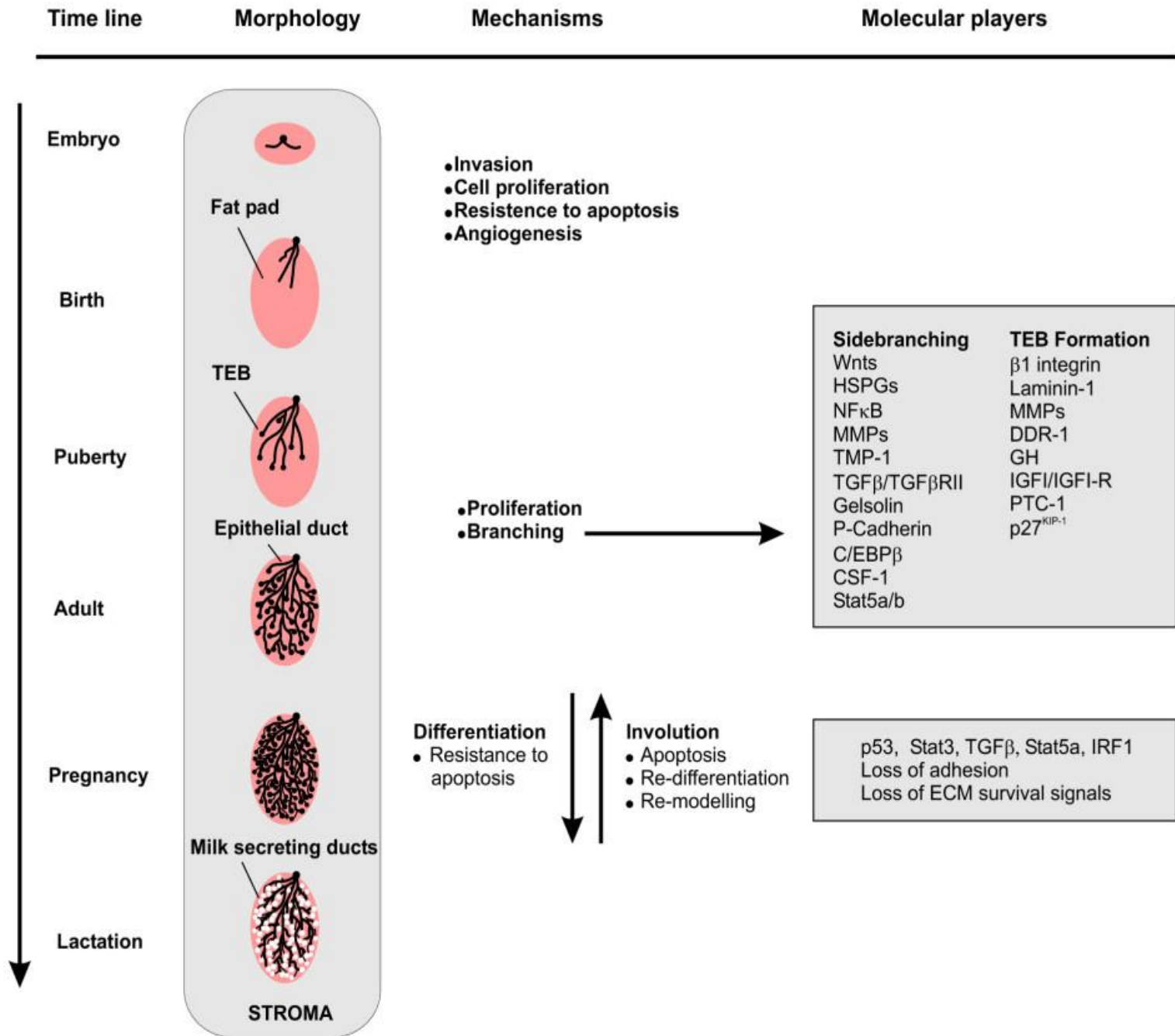
- **The lymphatics** of the breast drain predominantly into the axillary and internal mammary lymph nodes. The axillary nodes receive approximately 85% of the drainage and are arranged in the following groups:
 - lateral, along the axillary vein;
 - anterior, along the lateral thoracic vessels;
 - posterior, along the subscapular vessels;
 - central, embedded in fat in the centre of the axilla;
 - interpectoral, a few nodes lying between the pectoralis major and minor muscles;
 - apical, which lie above the level of the pectoralis minor tendon.





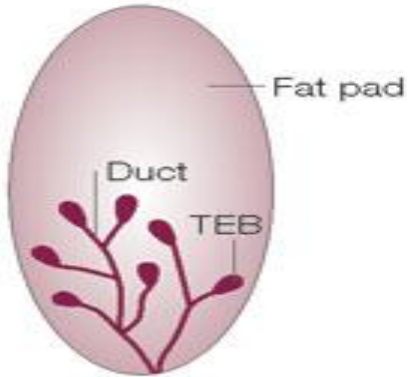


Copyright ©2006 by The McGraw-Hill Companies, Inc.
All rights reserved.

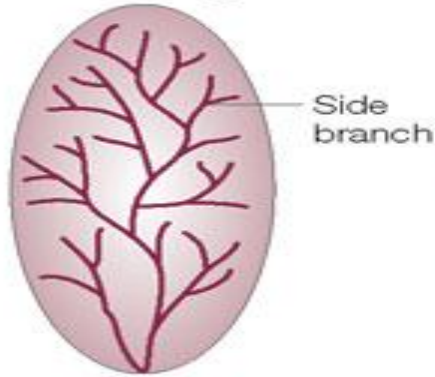


Physiology of the Breast

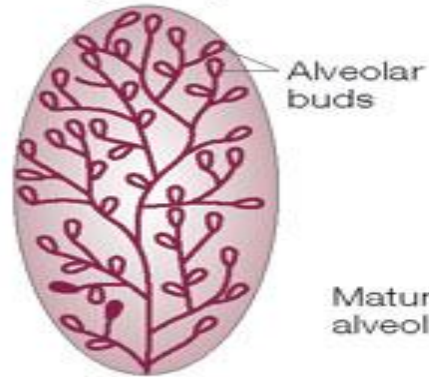
Aa Puberty



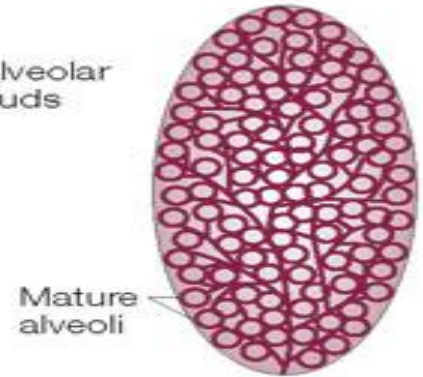
b Mature virgin



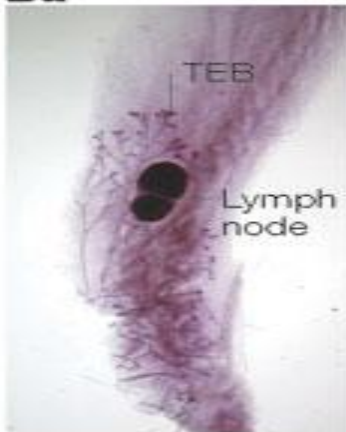
c Pregnancy



d Lactation

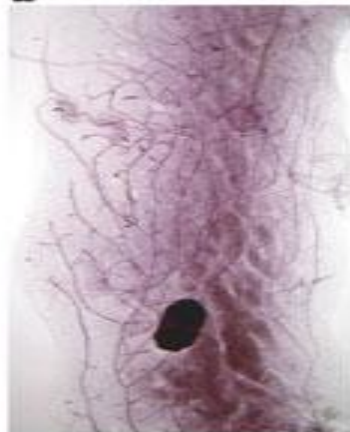

Ba



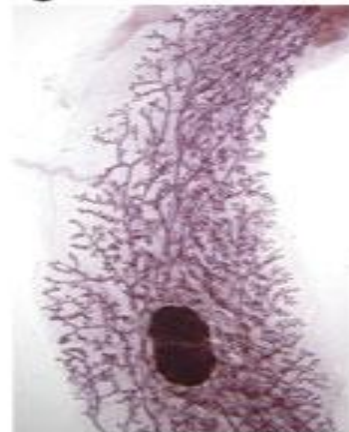
Oestrogen,
progesterone

b



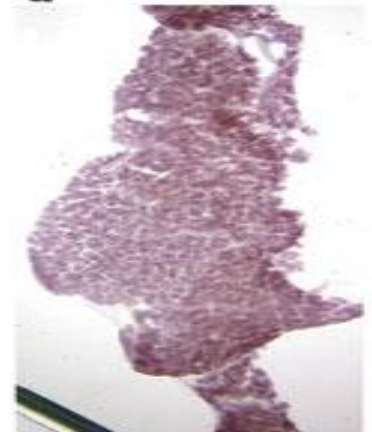
Progesterone,
prolactin

c



Prolactin, progesterone,
placental lactogens,
ERBB4 ligands, RANK-L

d

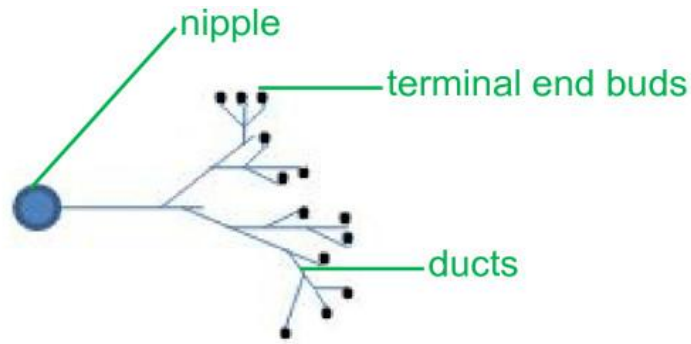


Prolactin, ERBB4
ligands

Copyright © 2005 Nature Publishing Group
Nature Reviews | **Molecular Cell Biology**

**GROWTH HORMONE, PROLACTIN, ADRENAL
GLUCOCORTICOIDS, INSULIN**

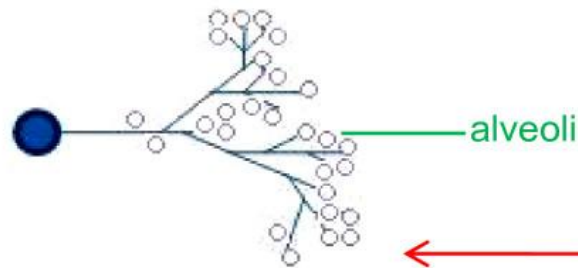
Puberty



ductal
development

estrogen
progesterone

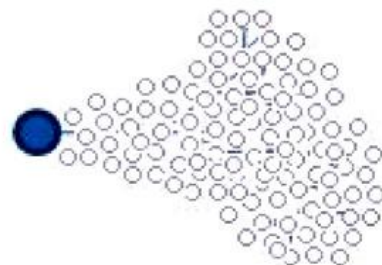Pregnancy



lobuloalveolar
development and
differentiation

estrogen
progesterone

Lactation



milk protein
secretion

prolactin

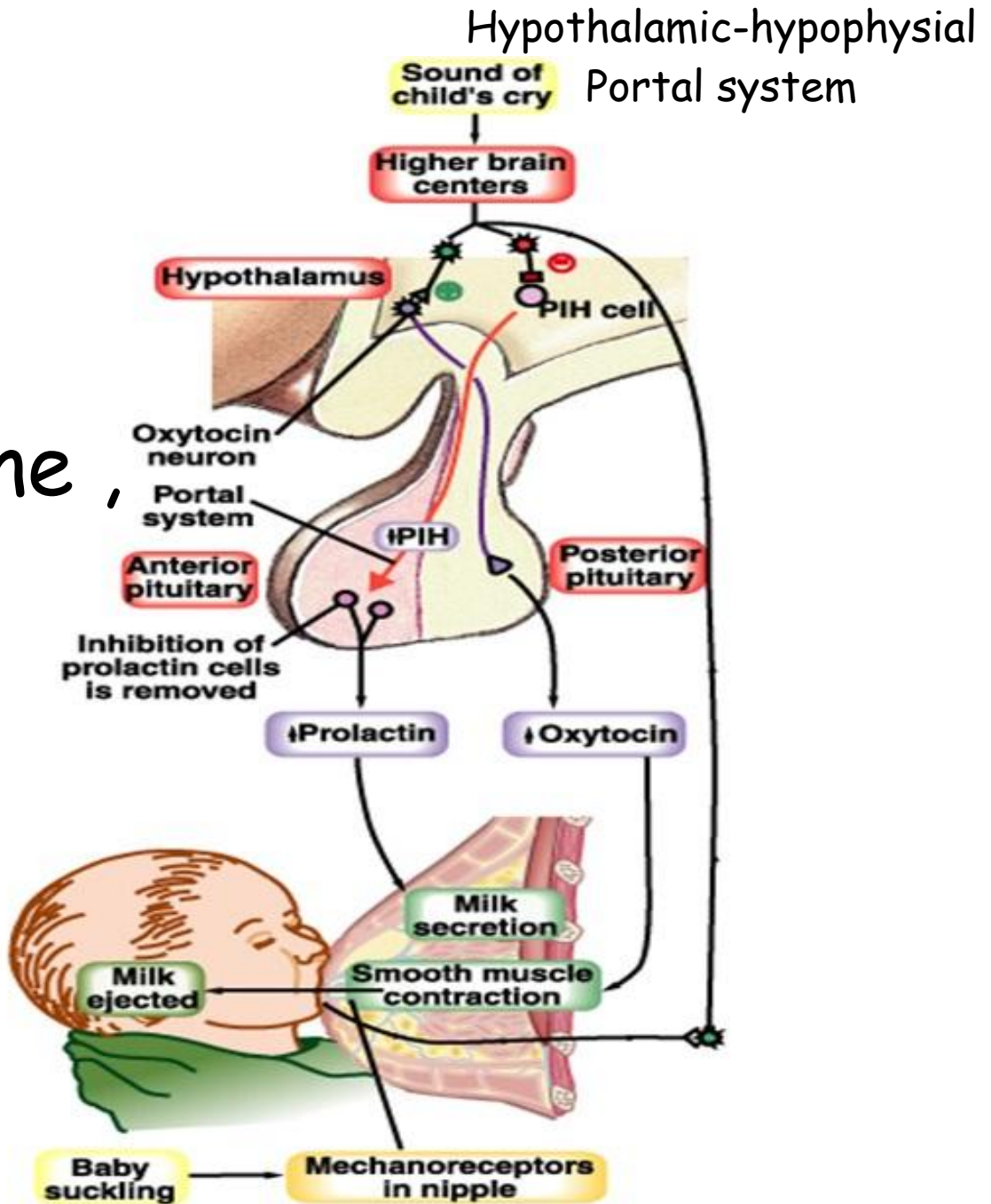
*proliferation of
epithelial cells*

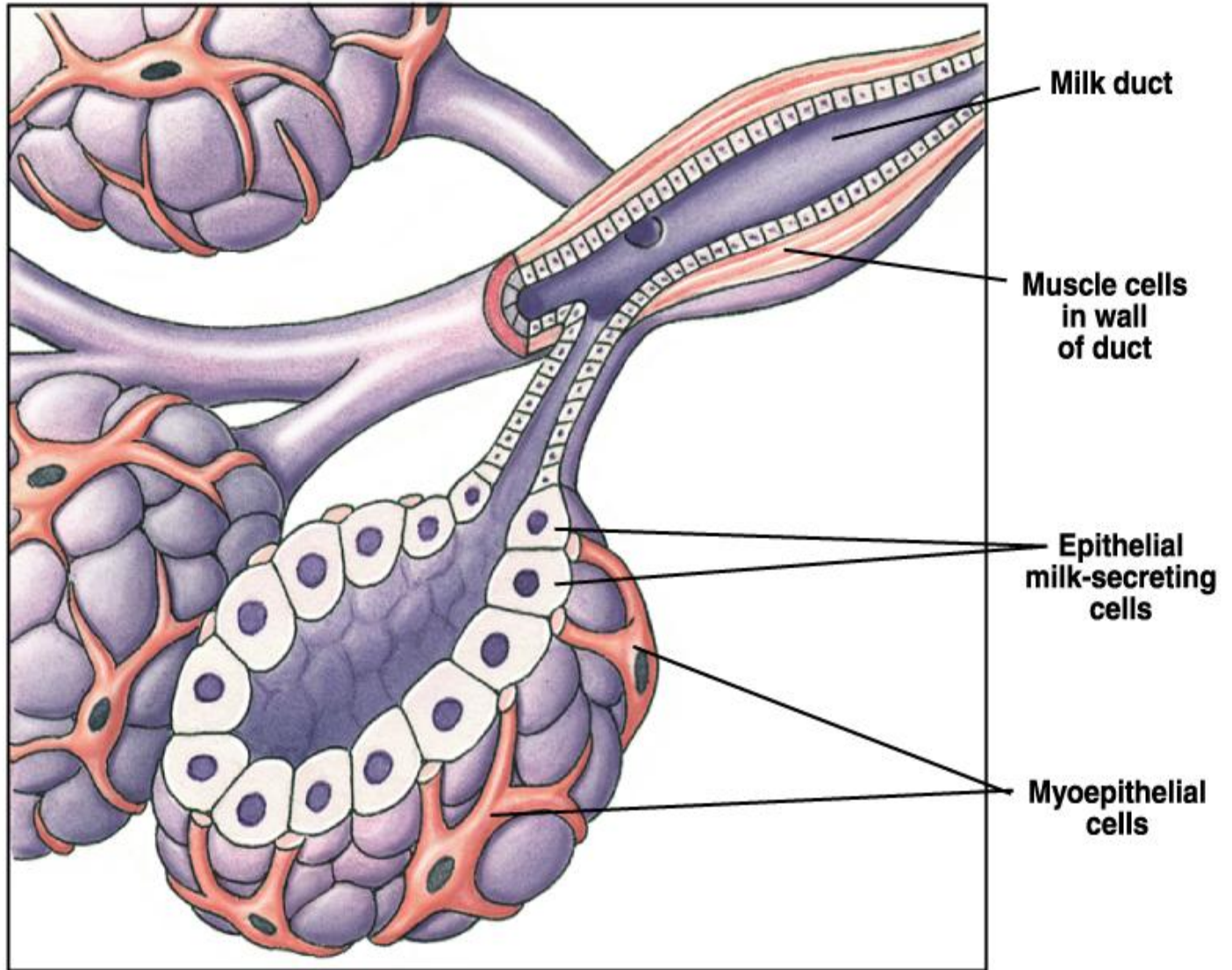
*cell proliferation,
ER formation*

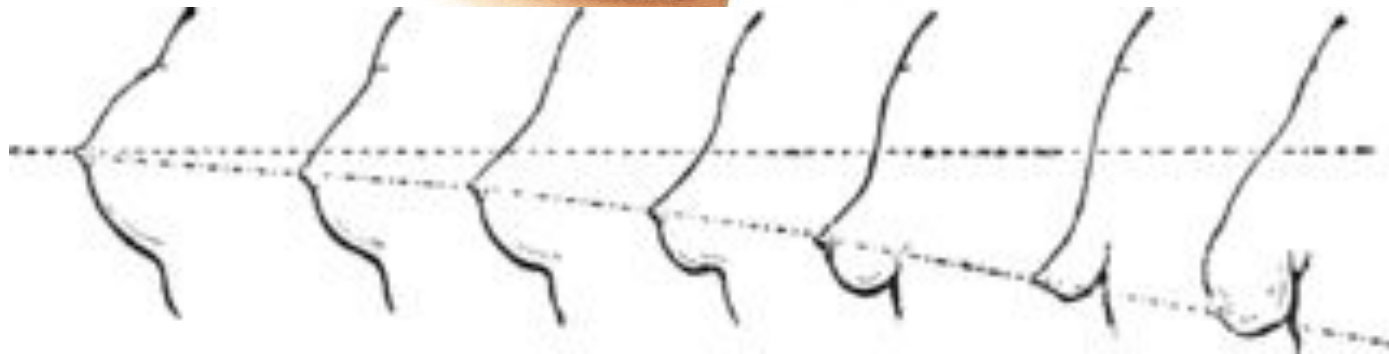
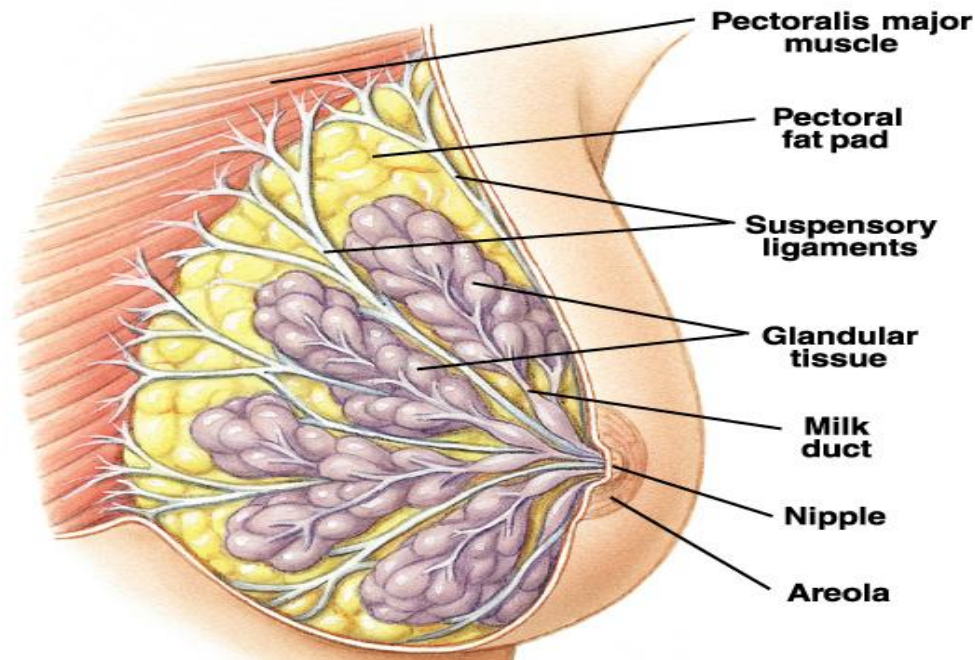
cortisol

*upregulation of early and
late milk protein genes;
suppression of involution*

Growth hormone,
Parathyroid hormone,
cortisol
insulin







The breast glands and ducts begin to shrink and disappear. Connective tissue supporting the glands becomes dehydrated and less elastic. These changes mean that breasts become smaller and less firm. Women may notice that their breasts flatten or droop.

Benign Breast Disease

Benign Breast Disease

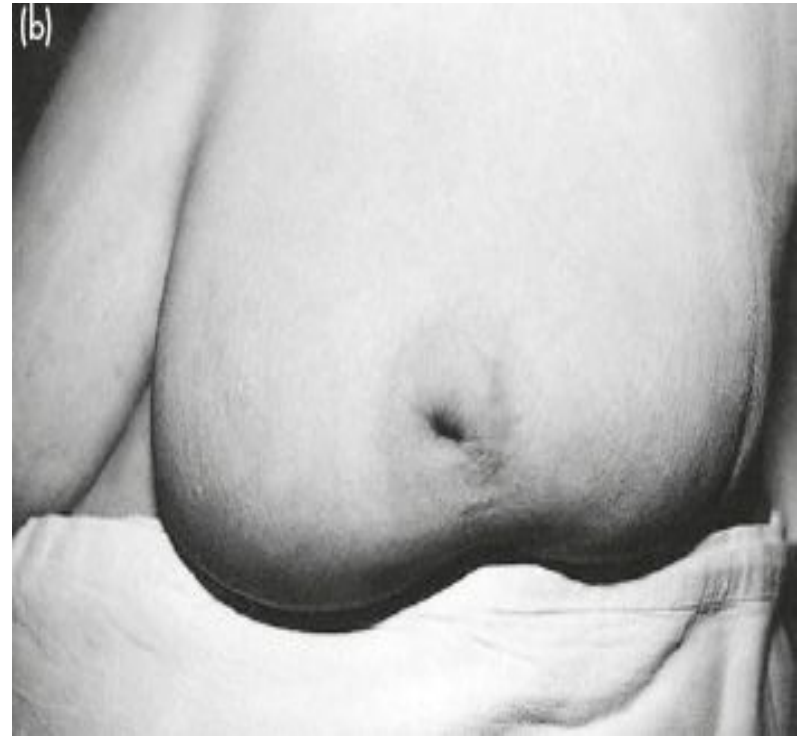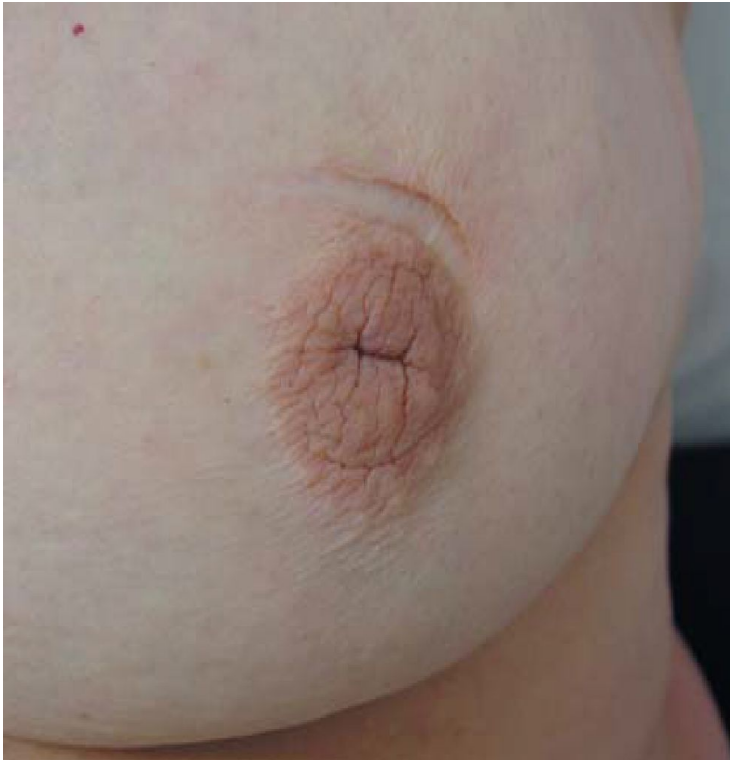- The most common cause of breast problems.
- 30% of women will suffer from a benign disorder requiring treatment some time in their lives.
- Most common symptoms are Pain, Lumpiness or a Lump.

Benign breast disease

- 1.** Benign conditions of the nipple.
- 2.** Aberrations of normal development & involution.
- 3.** Fibroadenomas & Phyllodes Tumor
- 4.** Acute & subacute inflammations.
- 5.** Injuries to the breast.
- 6.** Congenital abnormalities.

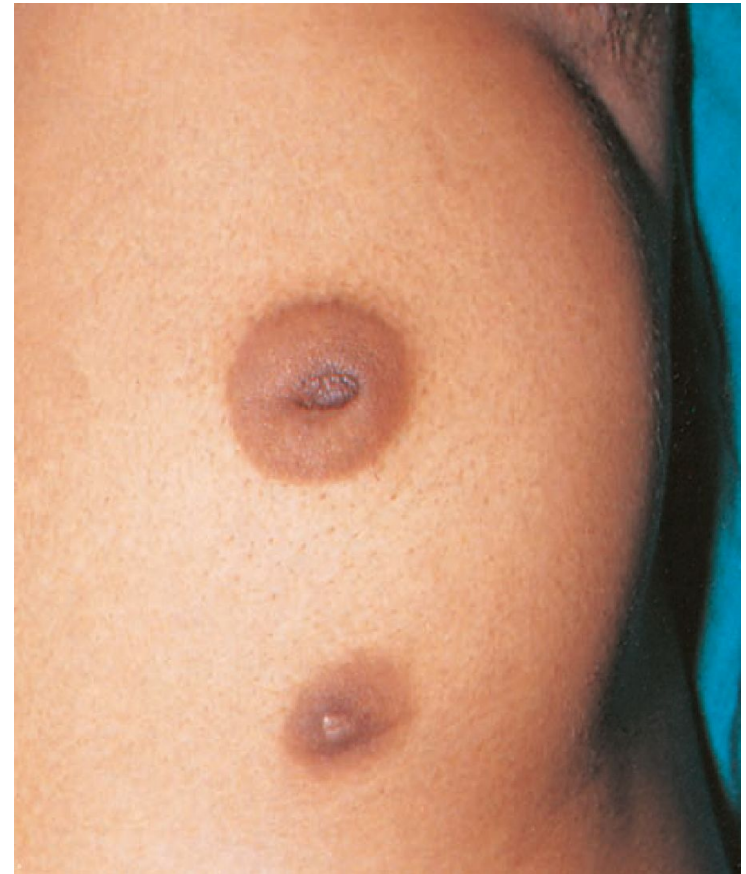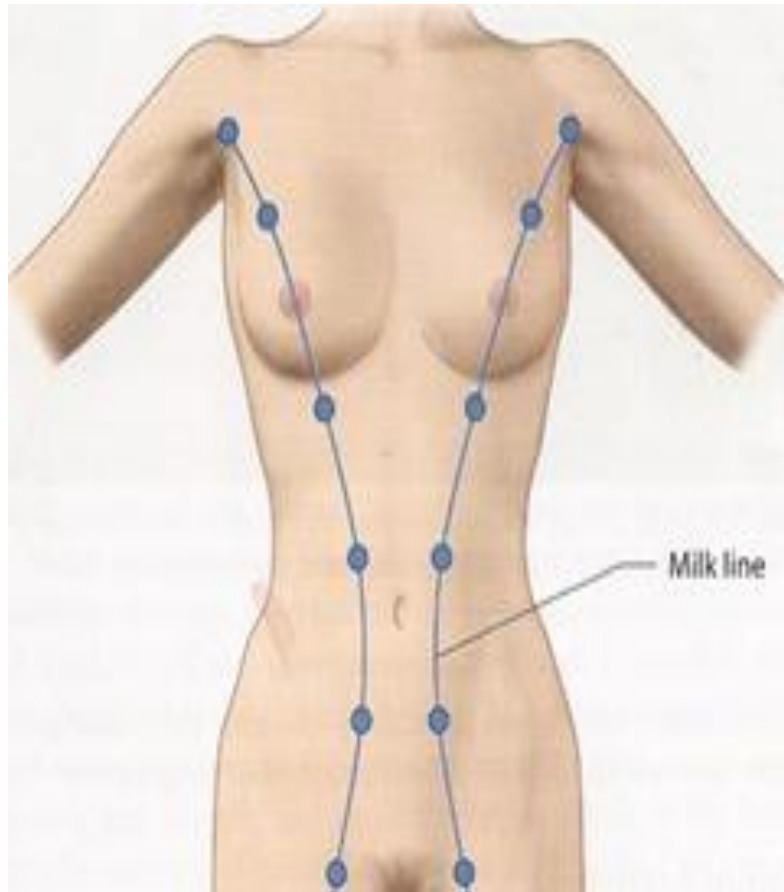
Conditions of the nipple

- 1-Nipple retraction



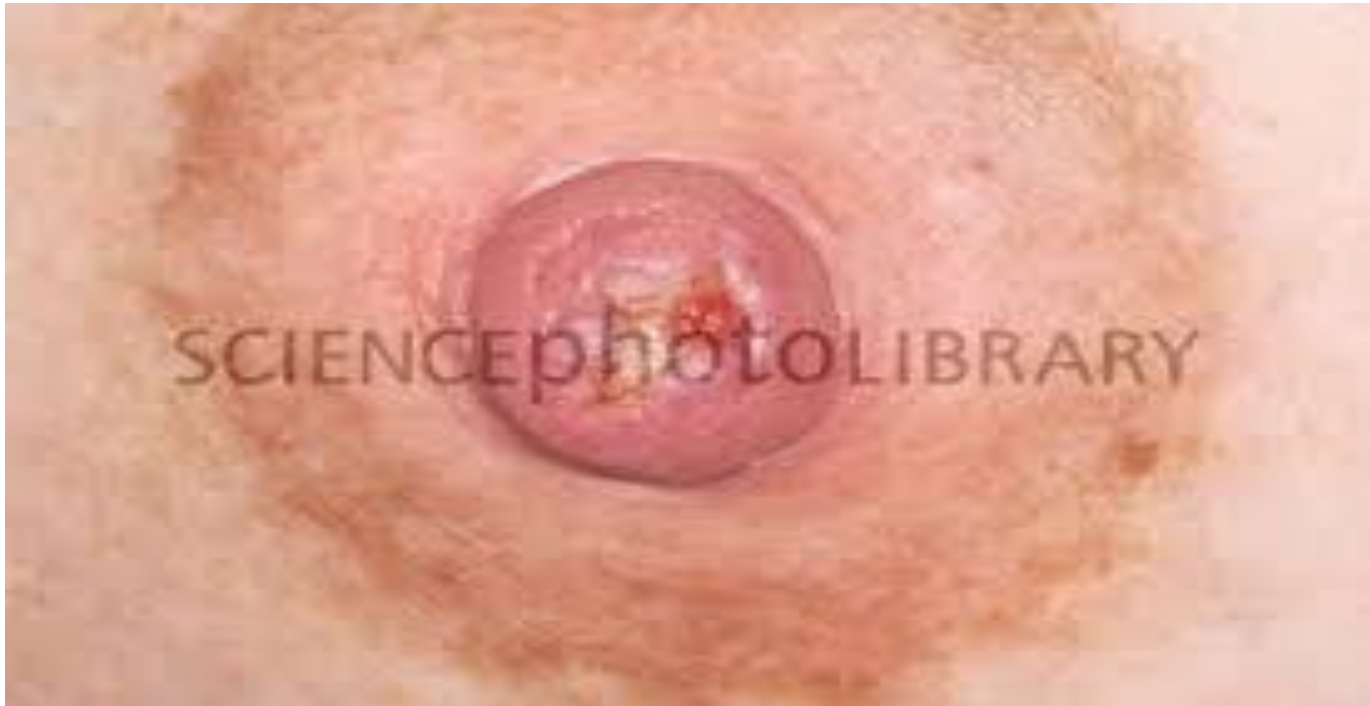Conditions of the nipple

2- supernumerary nipples



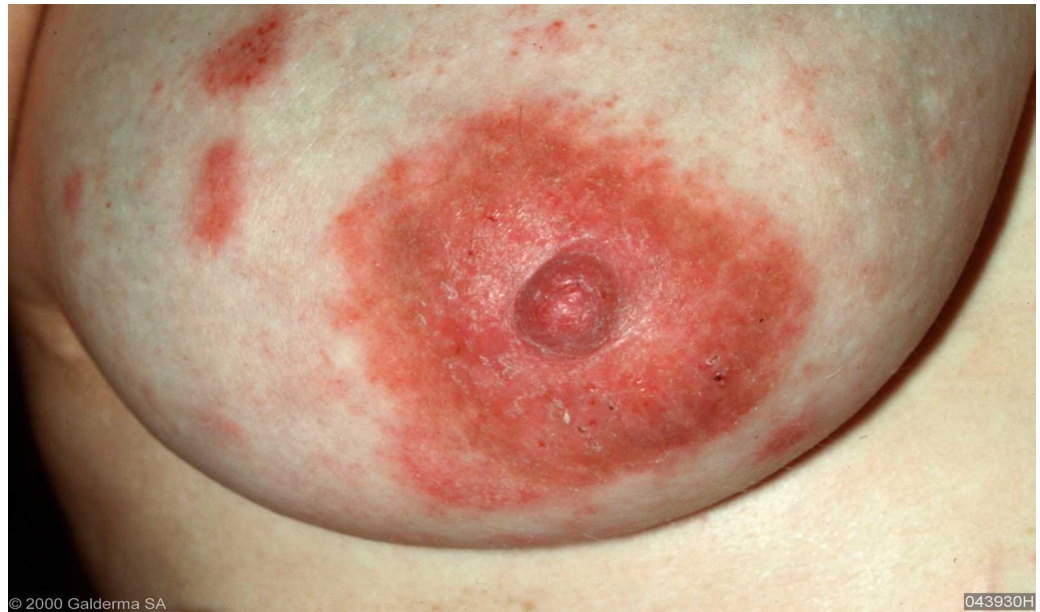Conditions of the nipple

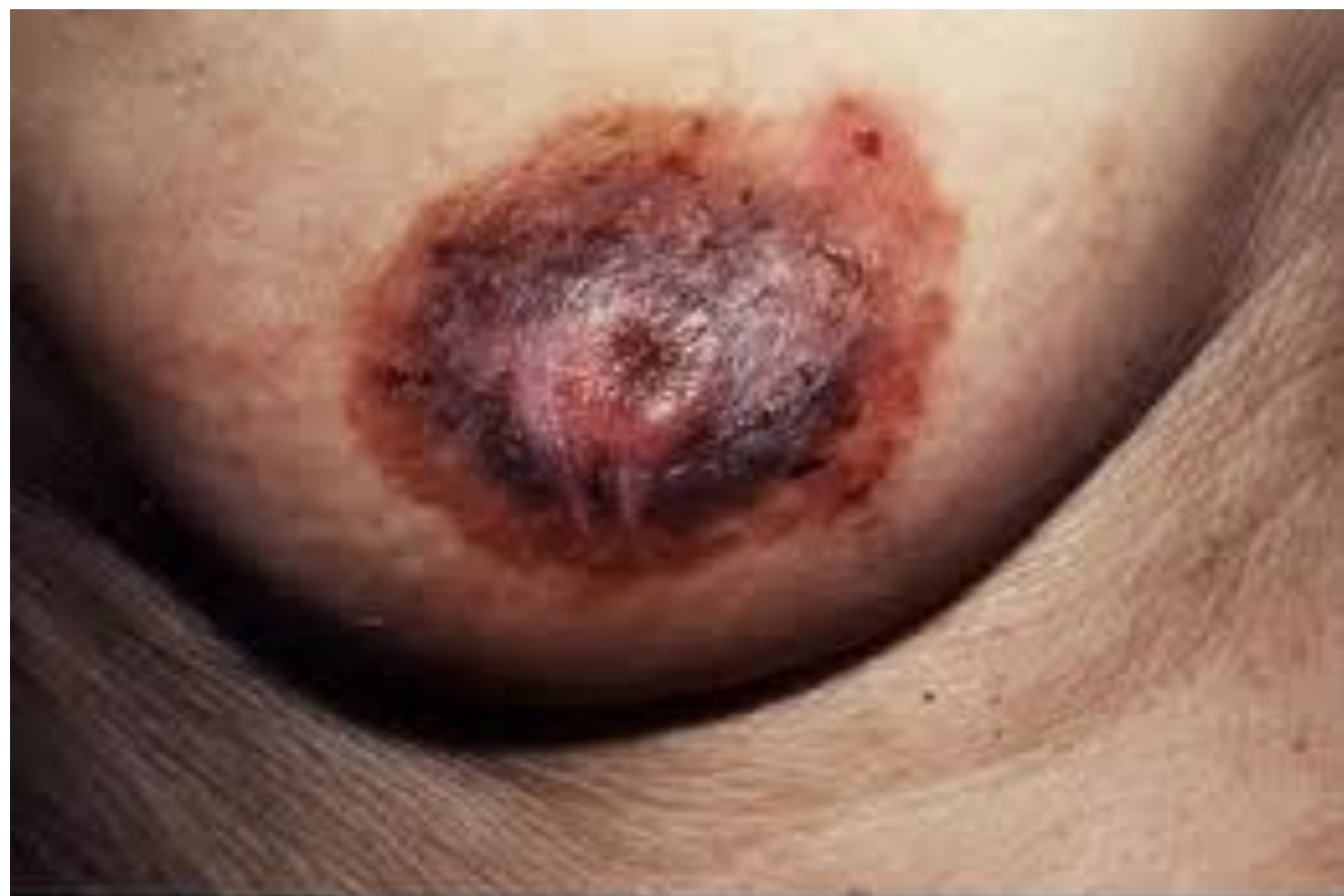3- cracked nipple : forerunner of infective mastitis



Conditions of the nipple

- 4-papilloma of the nipple
- 5-retention cyst
- 6-eczema (should be distinguished from paget's disease)





- 7- Nipple discharge

Discharge from the surface

- Paget's disease
- Skin diseases (eczema, psoriasis)
- Rare causes (e.g. chancre)

Discharge from a single duct

- Blood-stained
 - Intraduct papilloma**
 - Intraduct carcinoma**
 - Duct ectasia
- Serous (any colour)
 - Fibrocystic disease**
 - Duct ectasia**
 - Carcinoma

Discharge from more than one duct

- Blood-stained

Carcinoma

Ectasia

Fibrocystic disease

- Black or green

Duct ectasia

- Purulent

Infection

- Serous

Fibrocystic disease

Duct ectasia

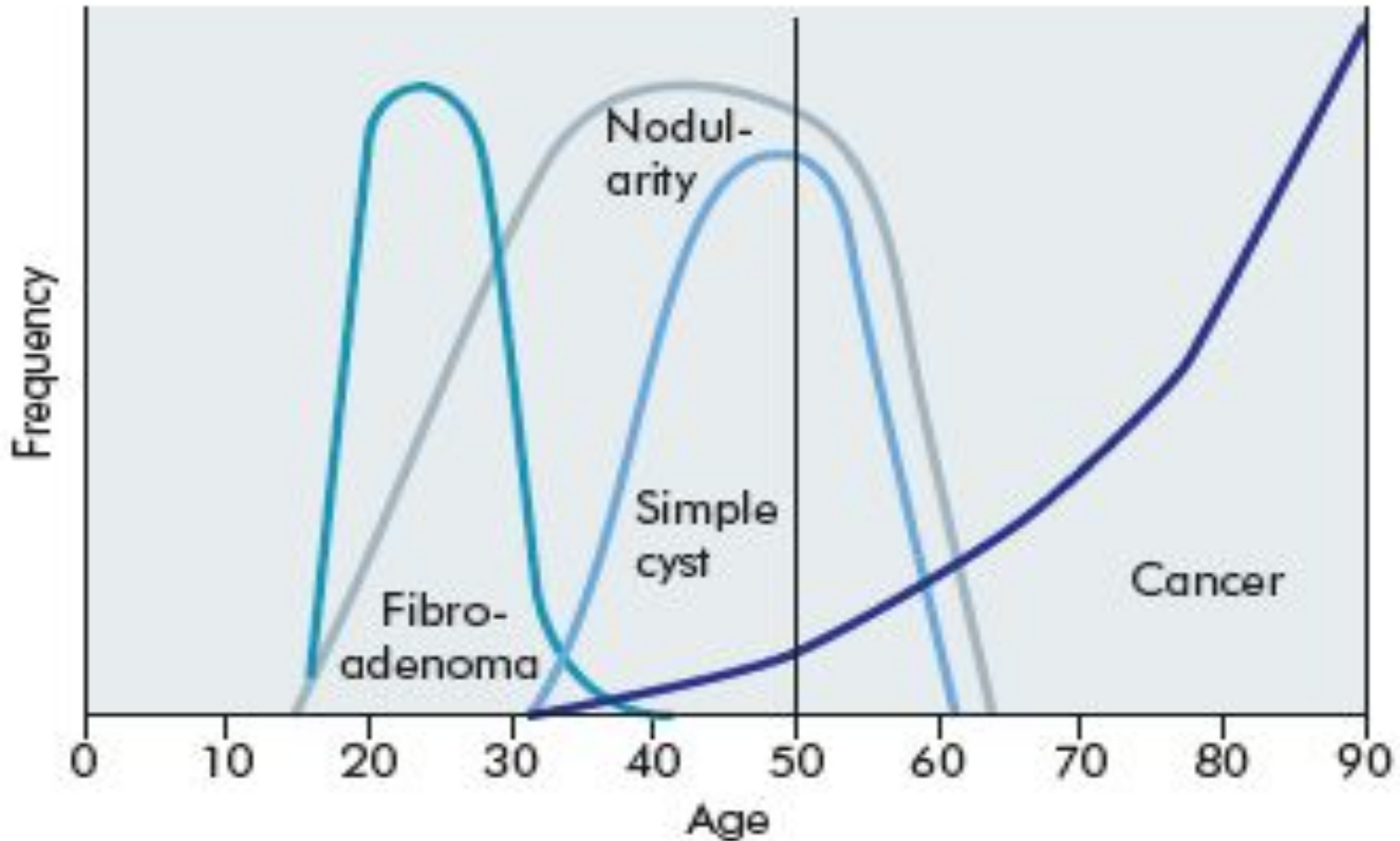
Carcinoma

- Milk:

Lactation

Rare causes (hypothyroidism, pituitary tumour)

Aberrations of normal development & involution



Aberrations of normal development & involution

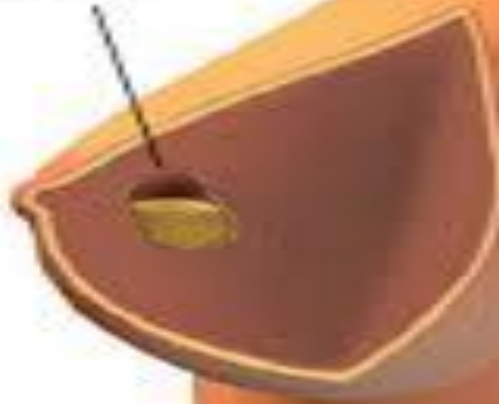
- 1.** Cyst formation
- 2.** Fibrosis
- 3.** Hyperplasia
- 4.** Papillomatosis

ANDI

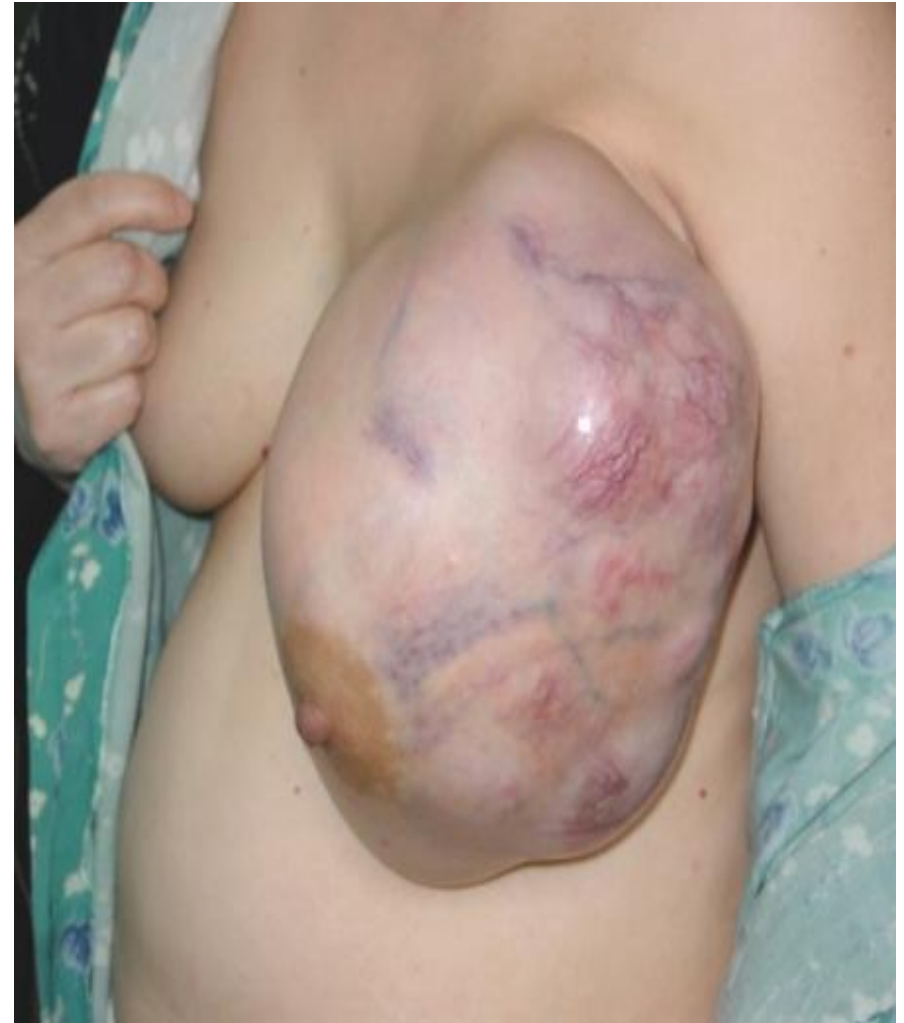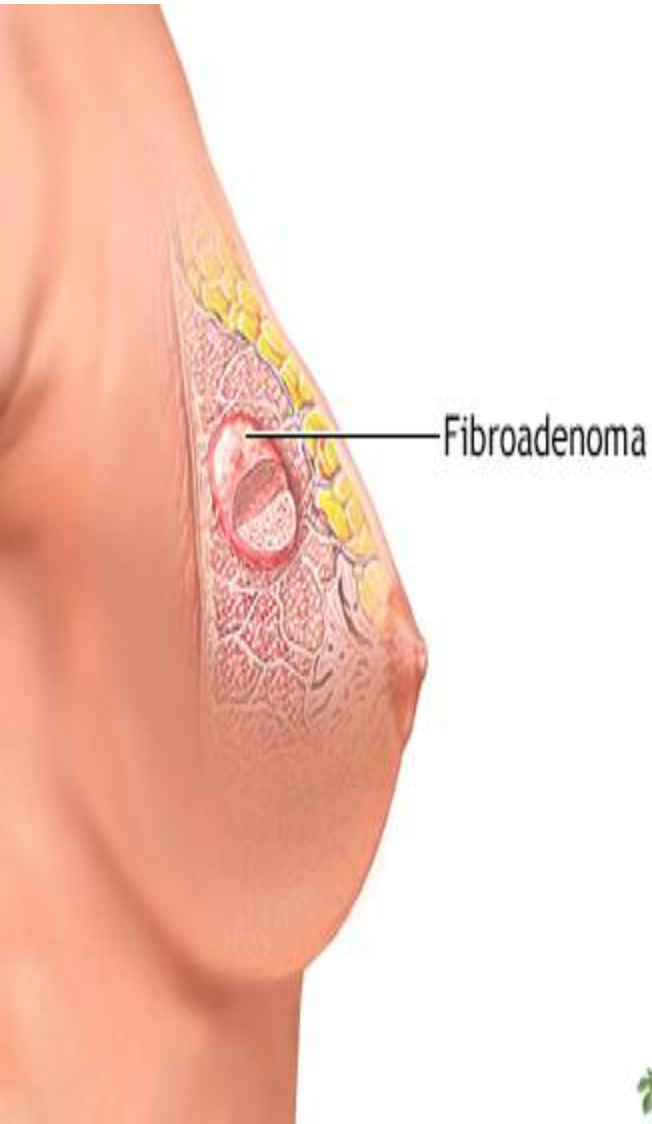- Breast cysts

Breast with single fluid-filled sac

Fluid-filled
sac

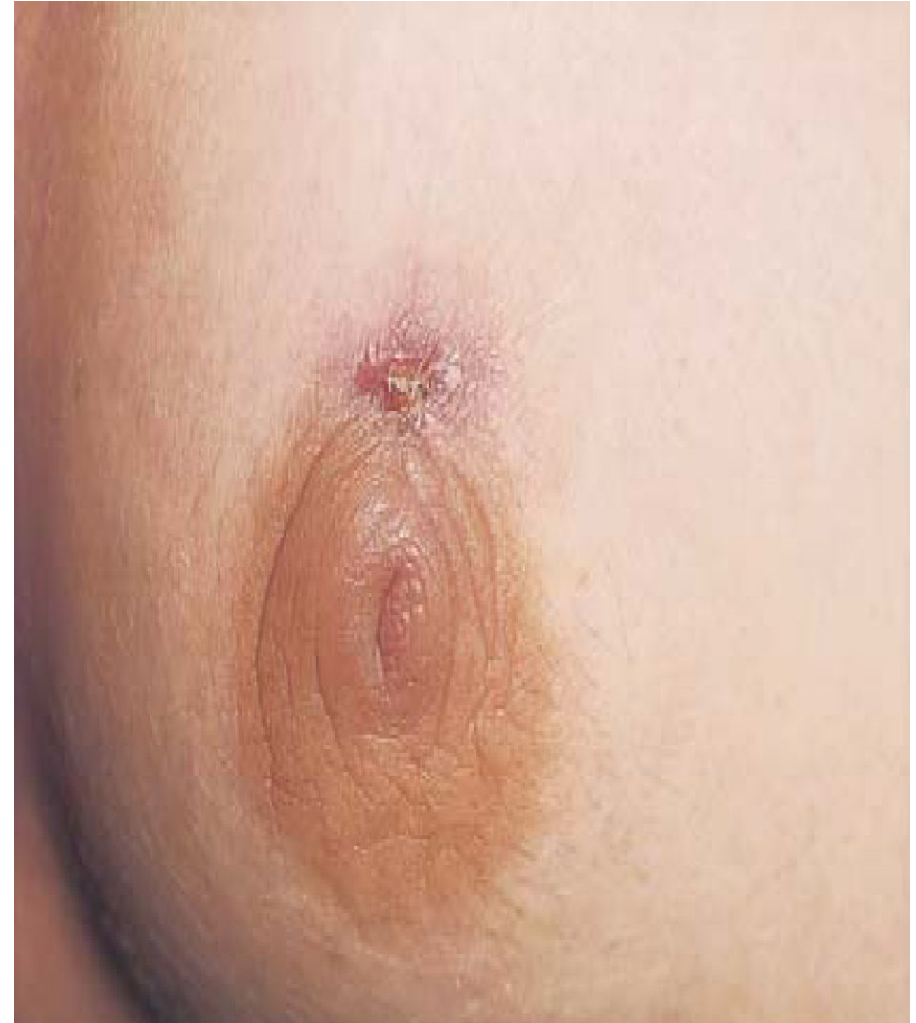
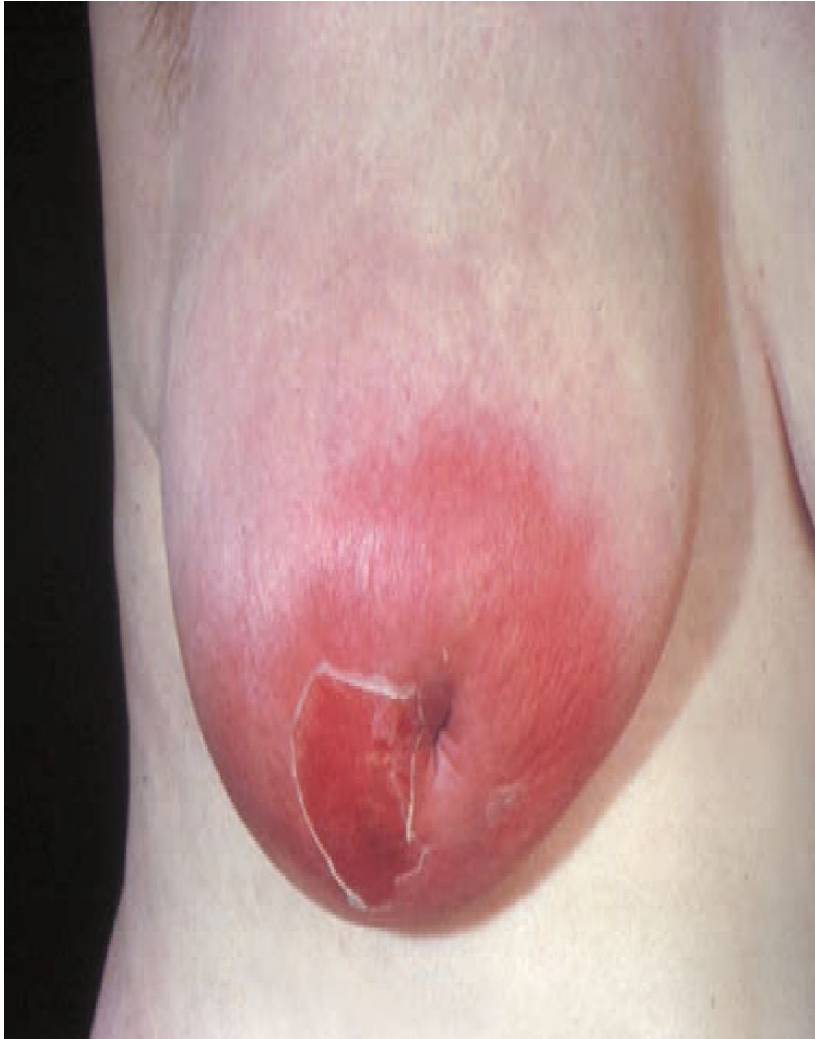
Fibroadenomas & Phyllodes Tumor:



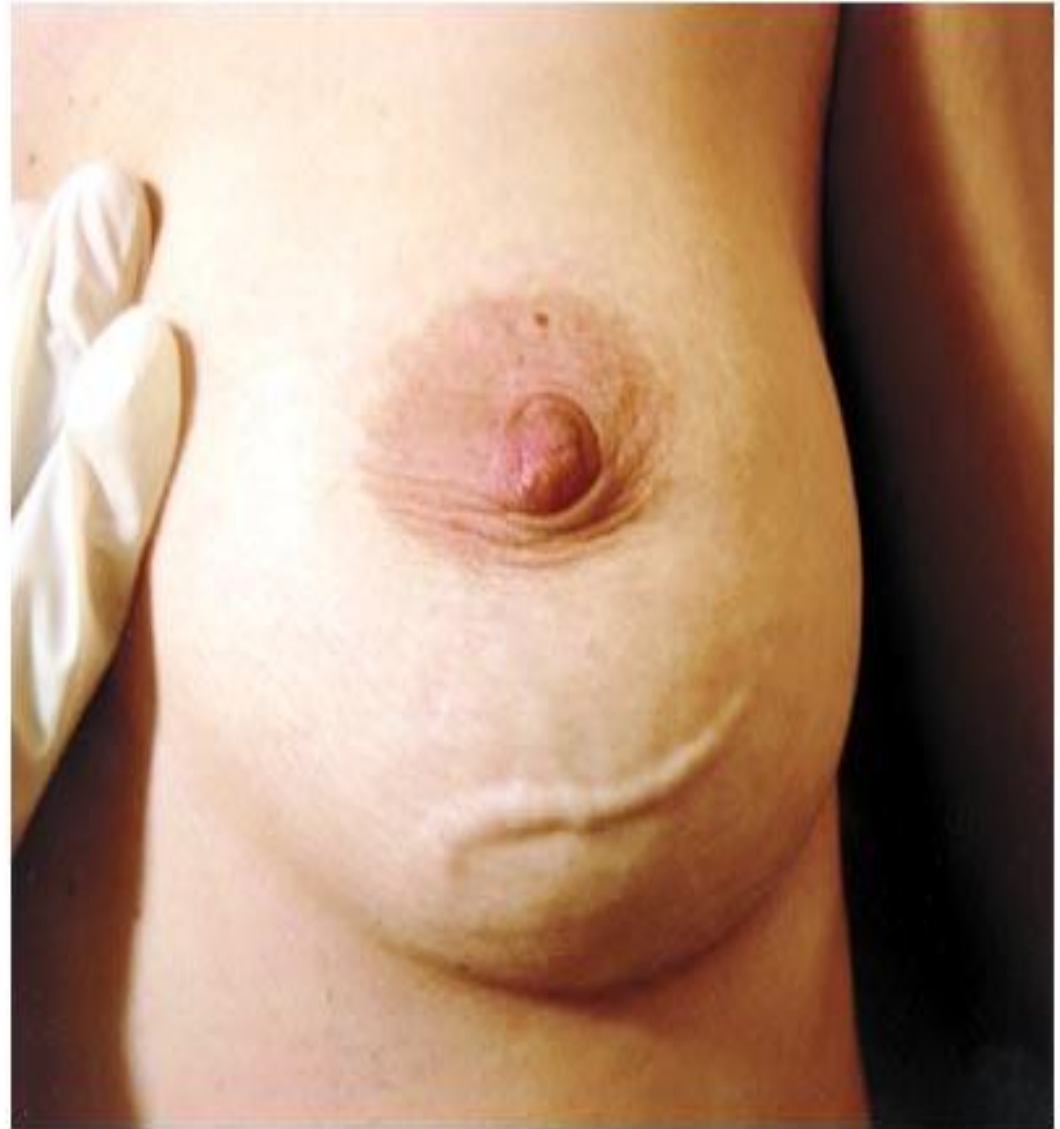- **Acute and Subacute Inflammations of the Breast:**

- 1- Bacterial mastitis & breast abscess:



- 2- Mondor's disease:

□ Should be distinguished from **Lymphangitis** caused by cancer.



• 3- Duct ectasia/periductal mastitis:

- Nipple Discharge.
- Periductal Mastitis.
- Abscess.
- Fistula.
- Nipple retraction.
- mass.

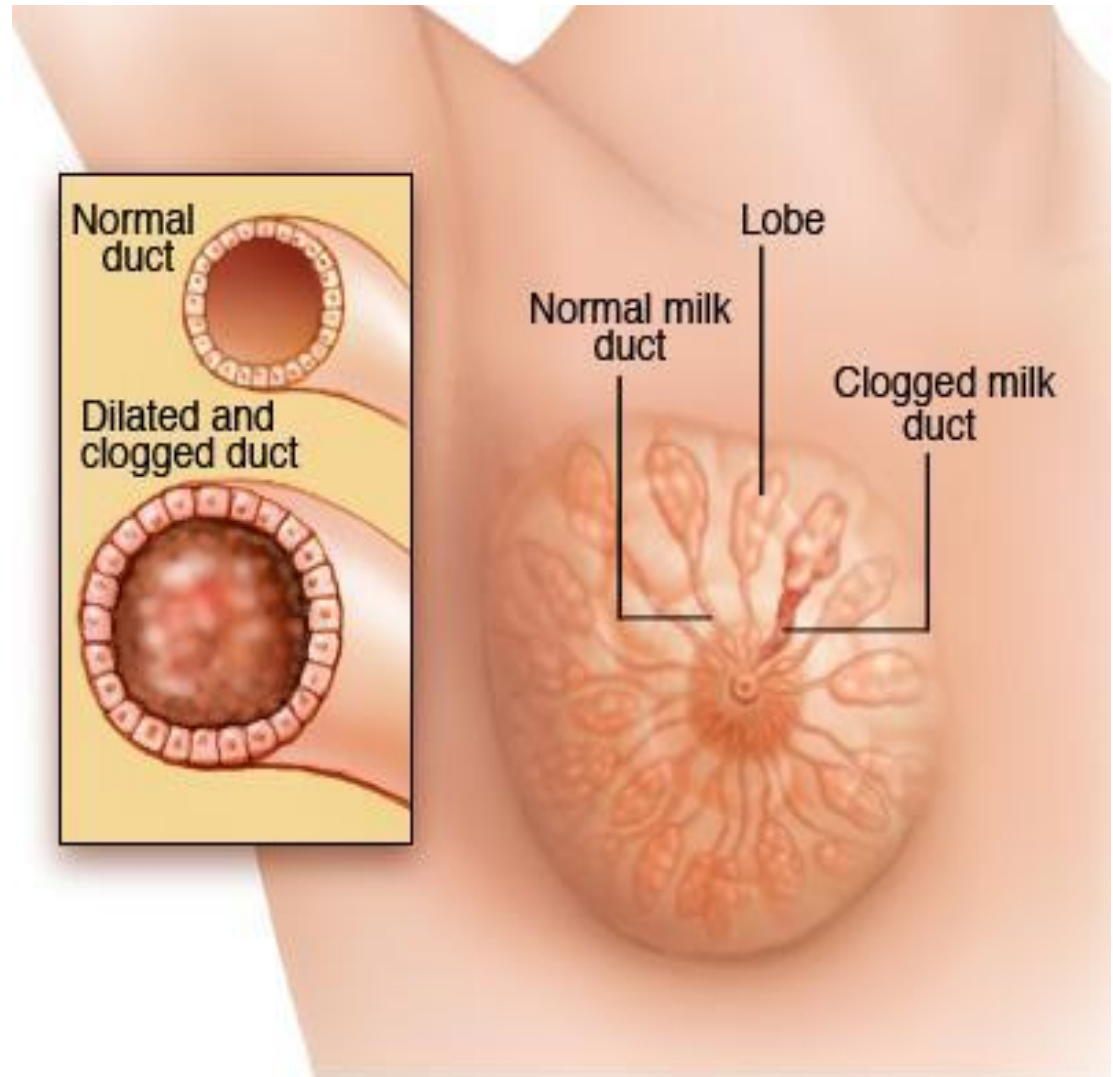

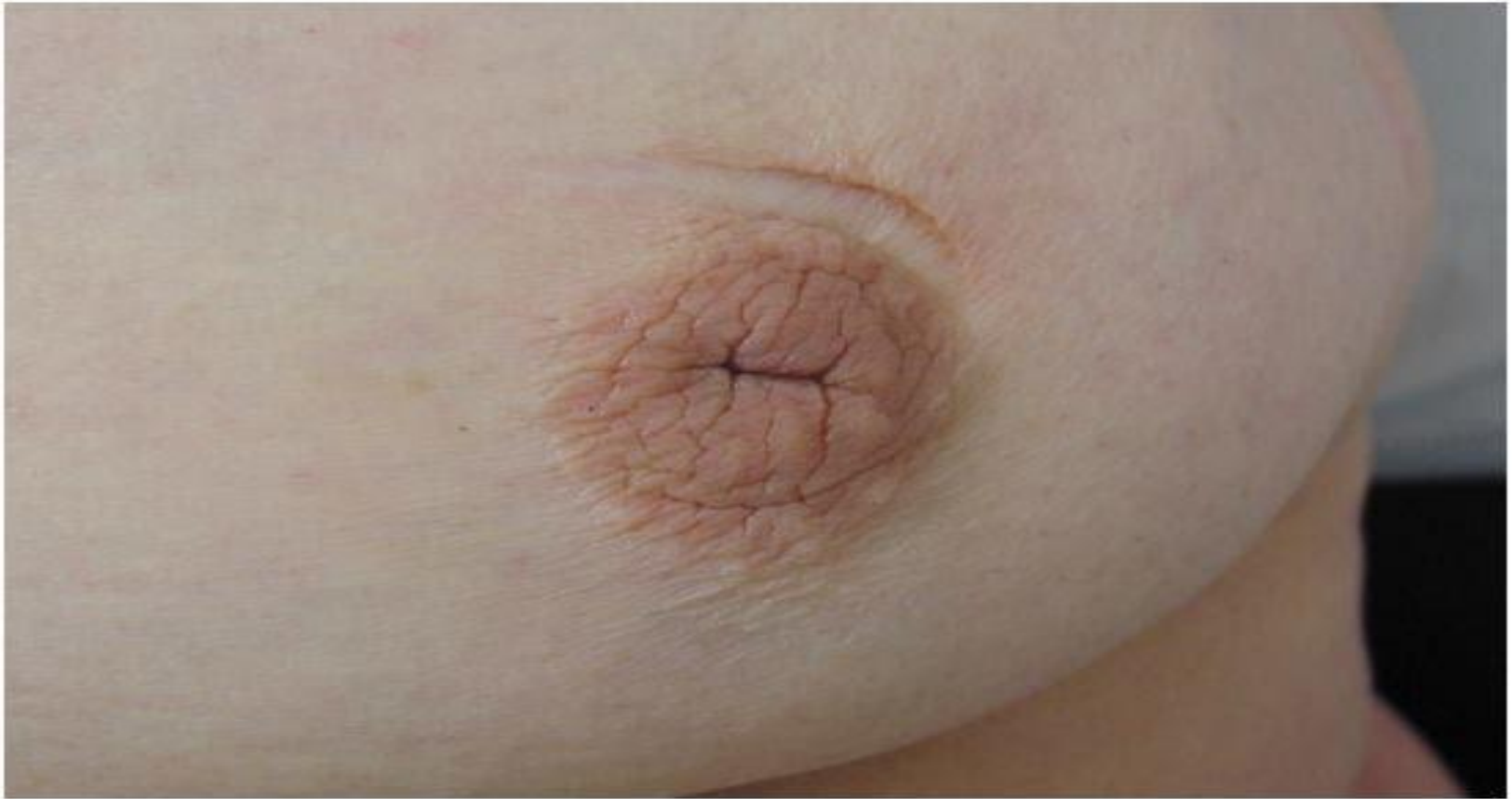


Fig. 13.11 The typical appearance of the nipple in duct ectasia. Note the transverse slit. The scar above the areola is the aftermath of an incision made to drain an abscess caused by periductal mastitis.

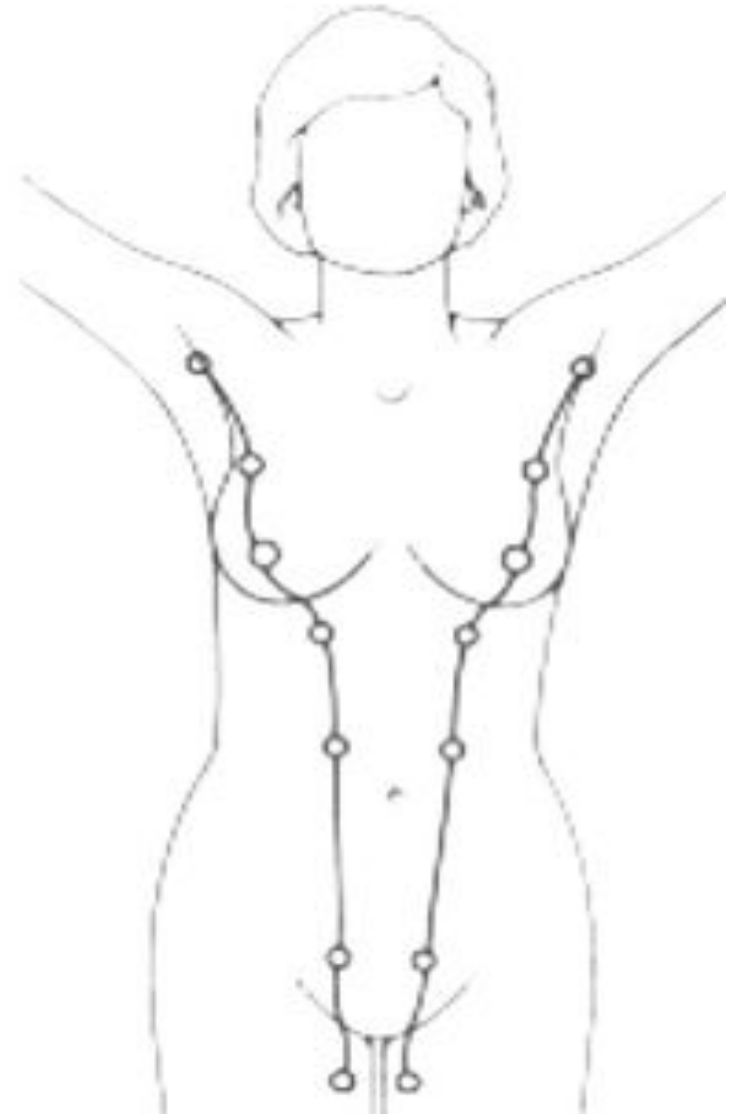
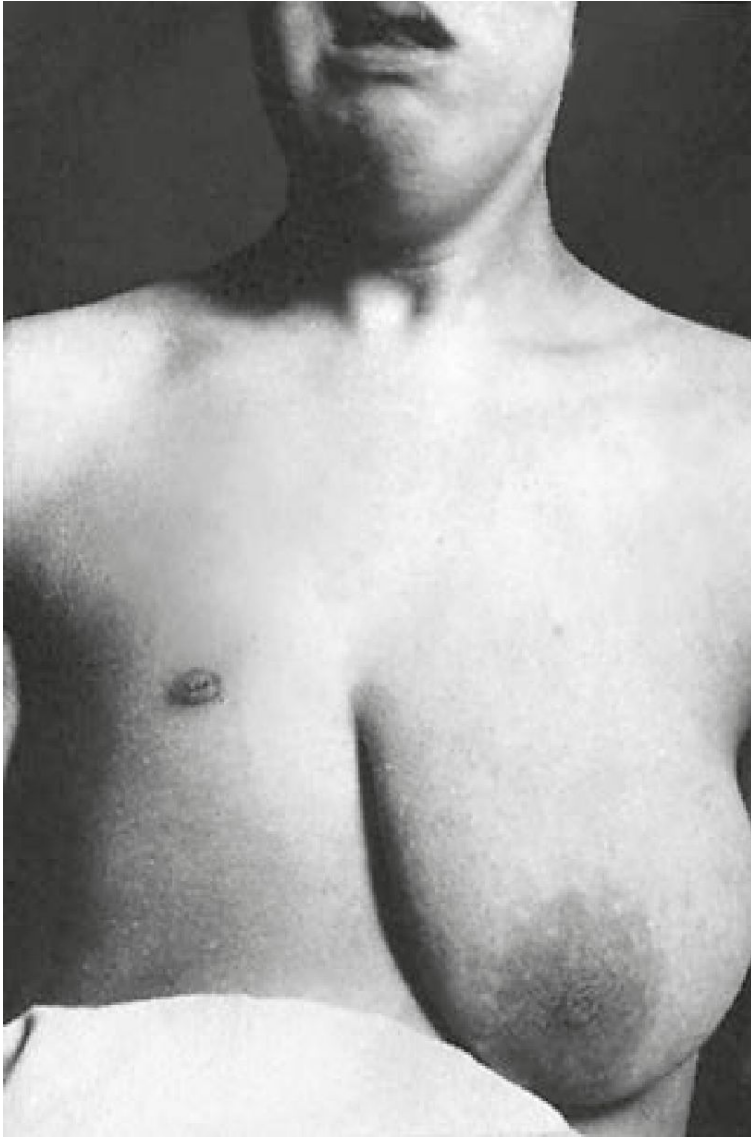• Injuries to the Breast:

1- Haematoma.

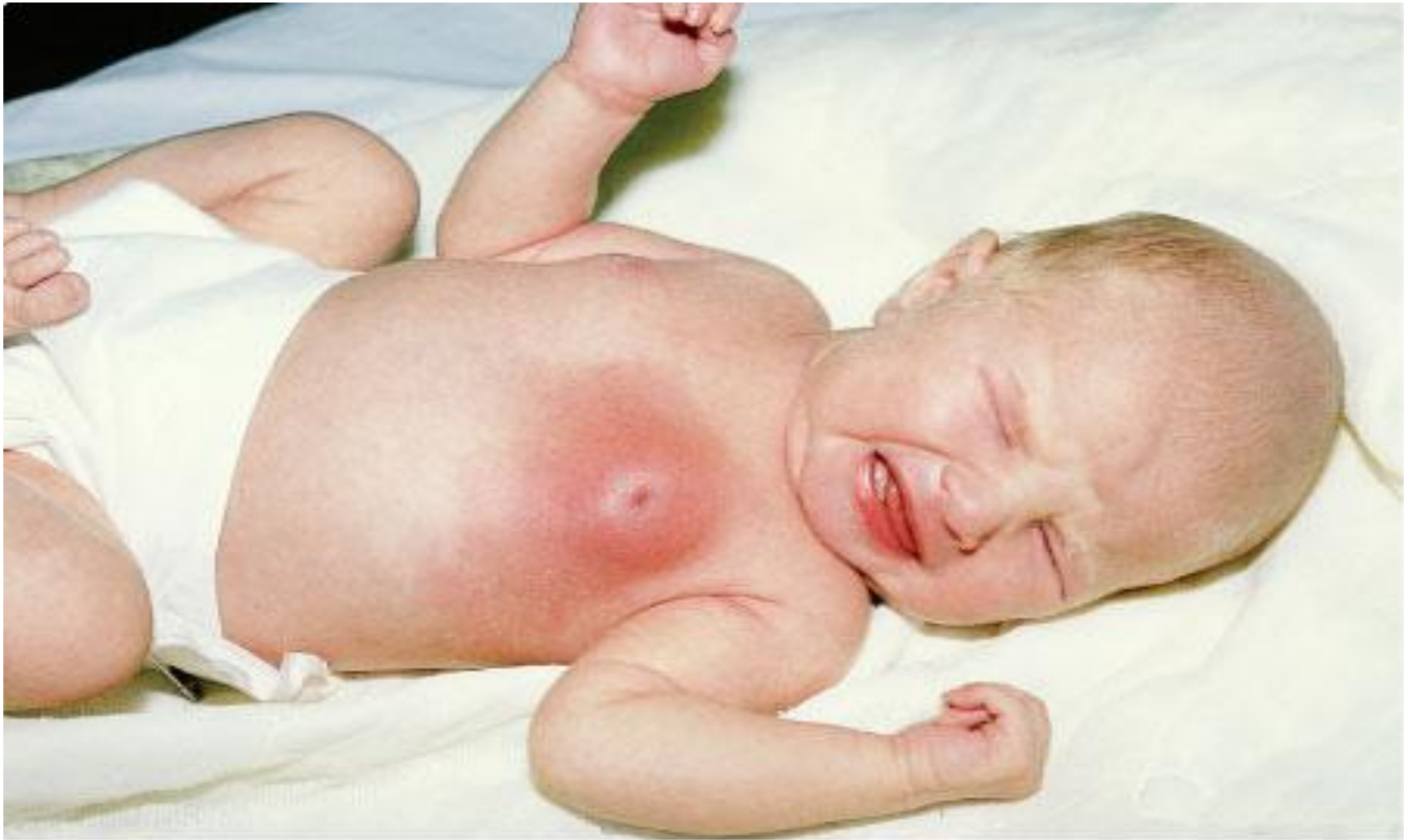2- Traumatic fat necrosis.

• **Congenital Abnormalities:**

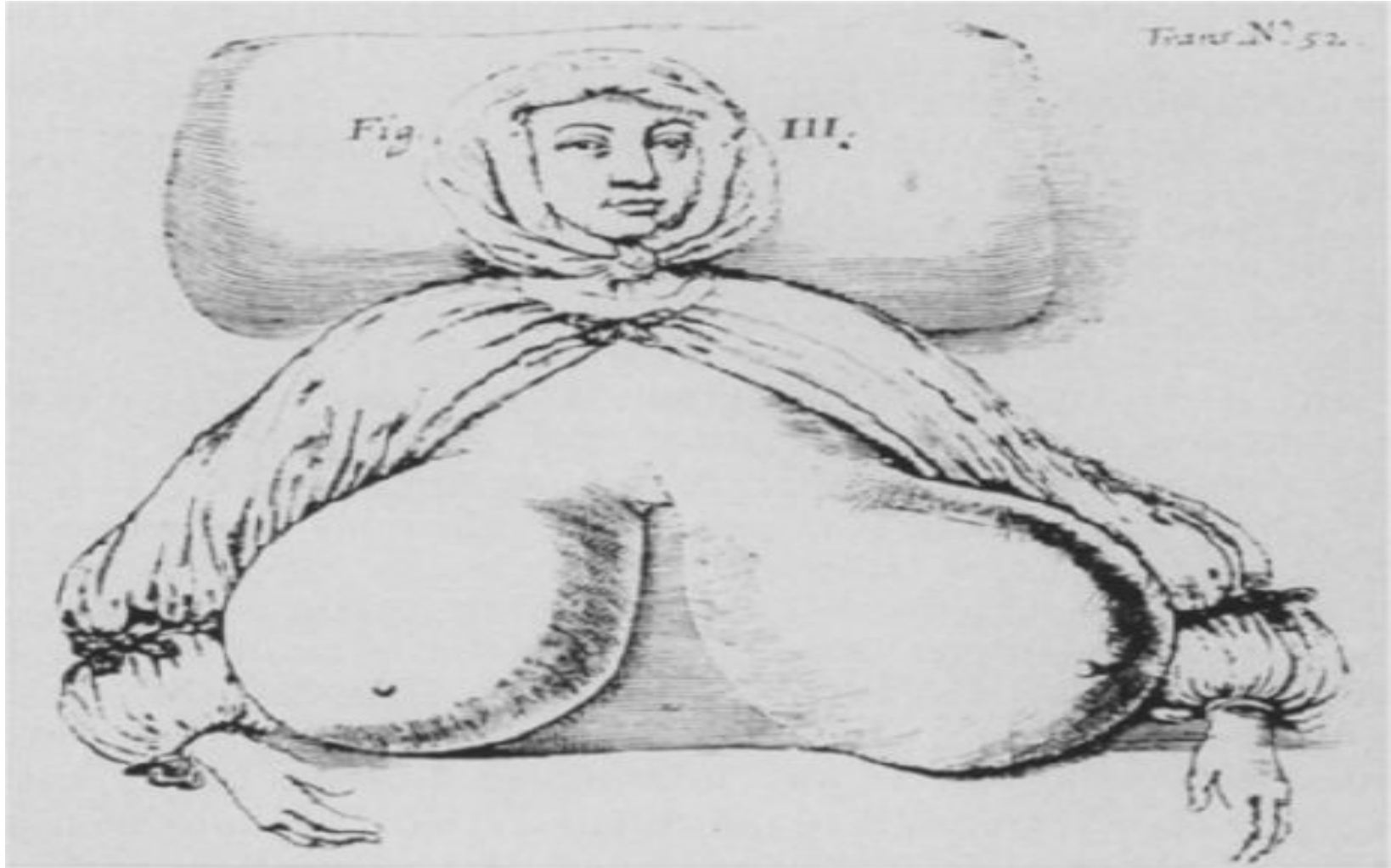
- 1- Amazia & polymazia:



- 2- Mastitis of infants:



- 3- Diffuse hypertrophy:



Malignant diseases

CARCINOMA OF THE BREAST

- **Breast cancer** is the second most common cancer with nearly 1.7 million new cases in 2012.
- Most common cancer in women.
- Most common cause of death in middle-aged women.

Aetiological factors

- *Geographical...*
- *Age...*
- *Gender...*
- *Genetic...*
- *Diet...*
- *Endocrine...*
- *Previous radiation...*

Pathogenesis

- Genetic factor...
- Hormonal factor...
- Enviromental factor...

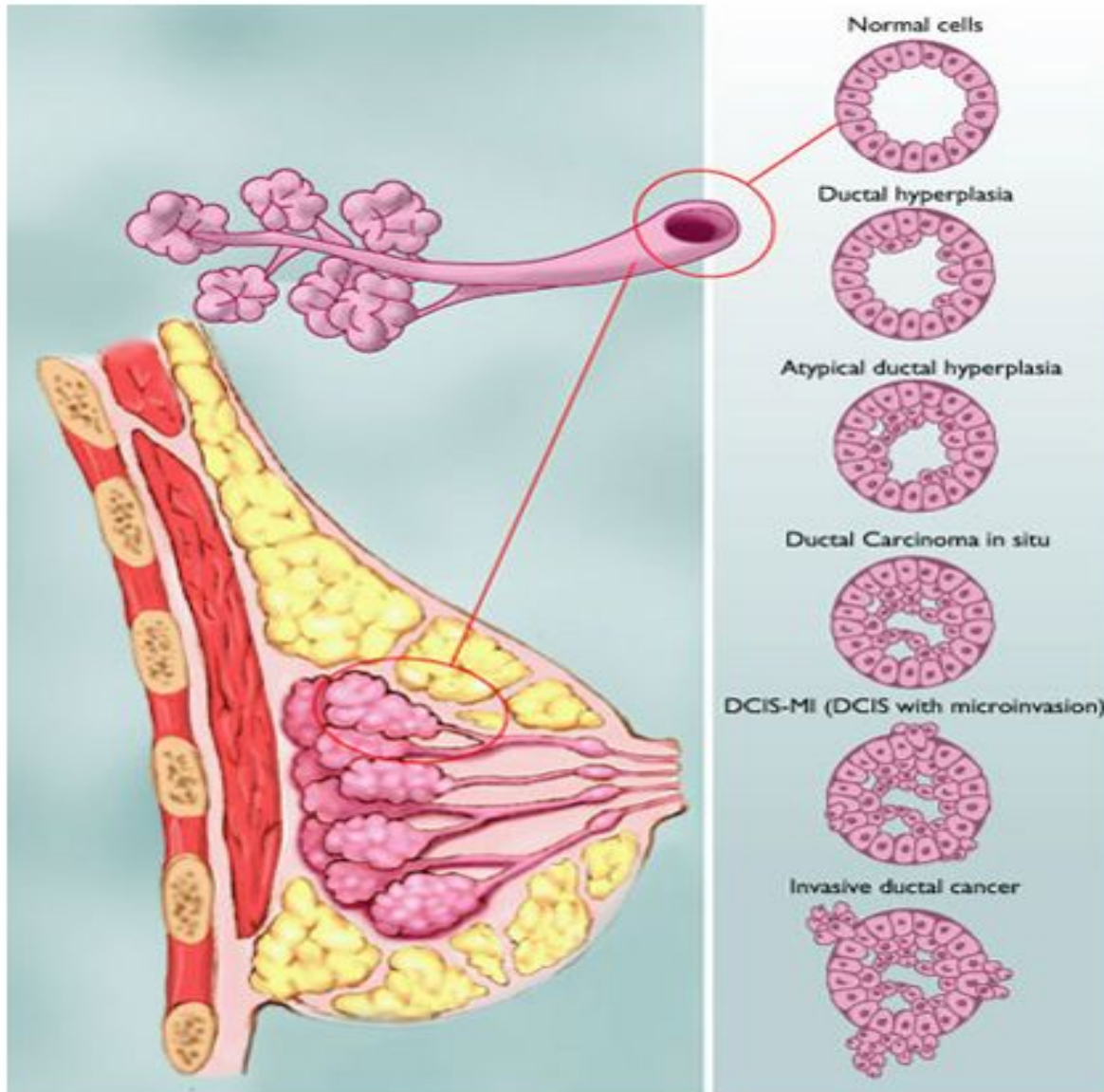
Histopathologic classification

Ductal ----- Lobular

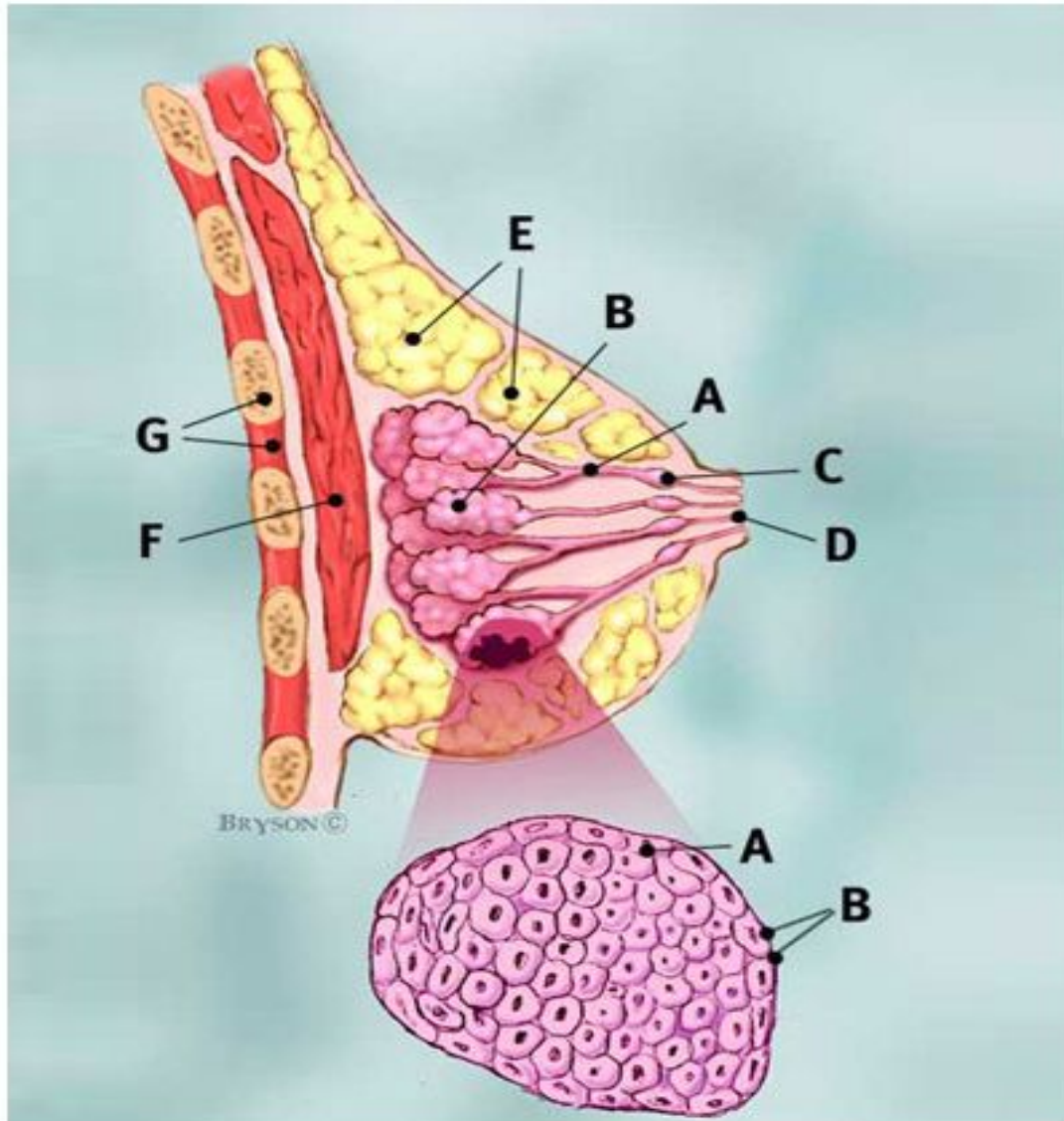
Invasive ----- In situ

Breast carcinoma in situ

Ductal carcinoma in situ (DCIS)



Lobular carcinoma in situ (LCIS)



Normal breast with lobular carcinoma in situ (LCIS) in an enlarged cross-section of the lobule

- *In situ* carcinoma is pre-invasive cancer.
- Becoming increasingly common.
- At least 20% of patients will develop invasive cancer.

Treatment

- **Surgical excision**

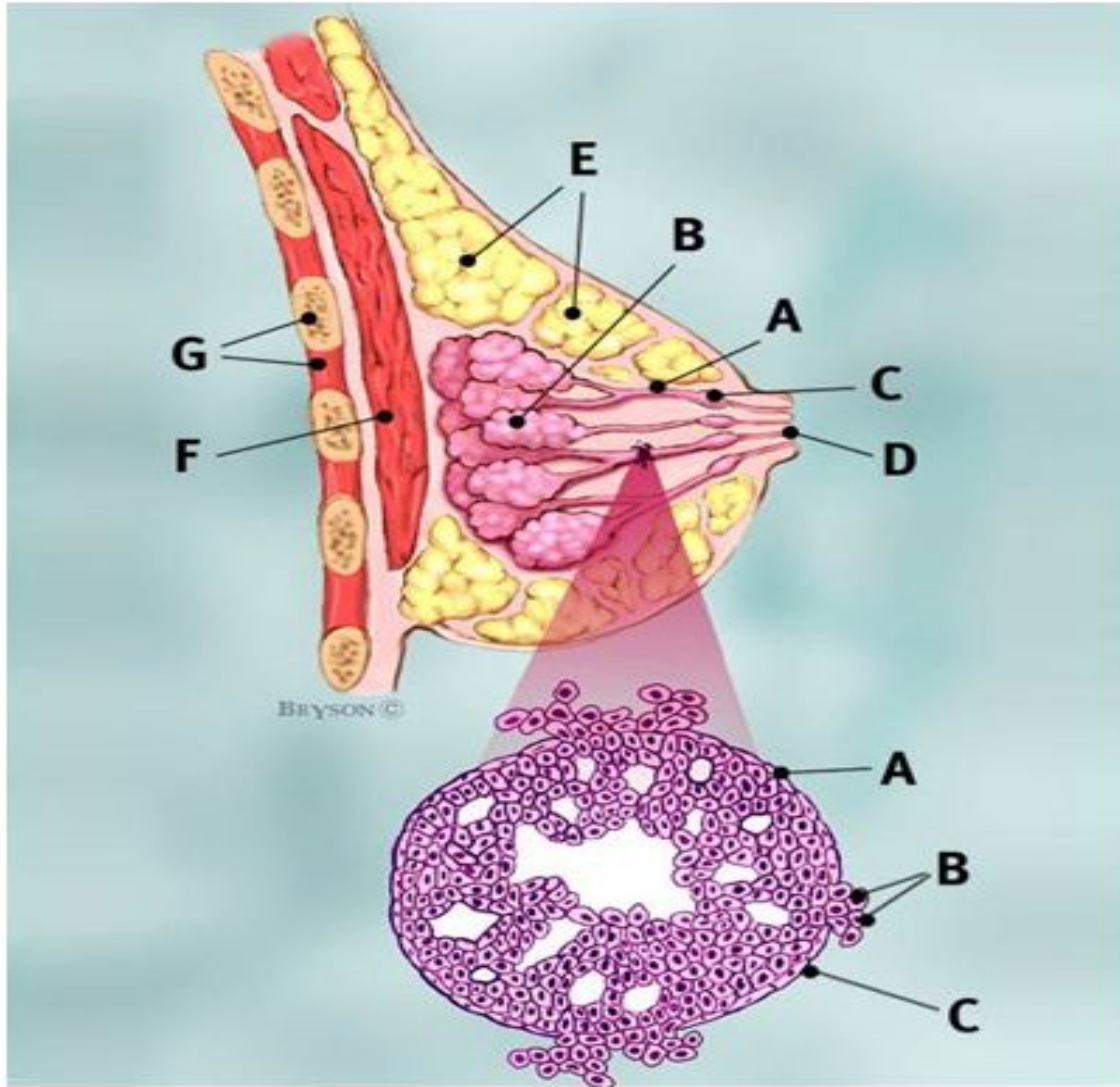
Mastectomy?

Partial mastectomy with safety margins $> 1\text{cm}$

- **Radiotherapy?**

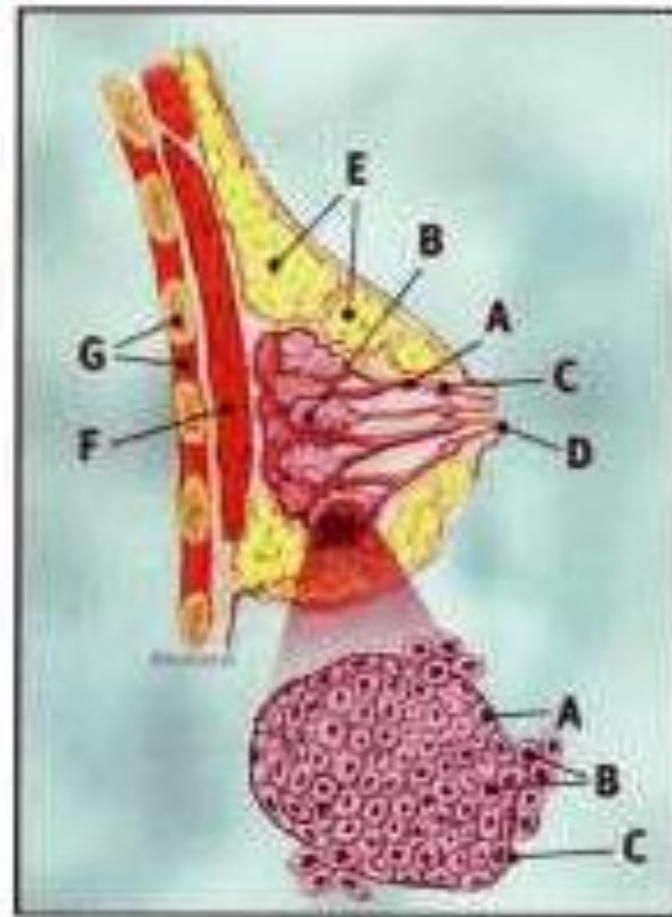
Invasive breast carcinoma

Invasive Ductal carcinoma (IDC)



Normal breast with invasive ductal carcinoma (IDC) in an enlarged cross-section of the duct

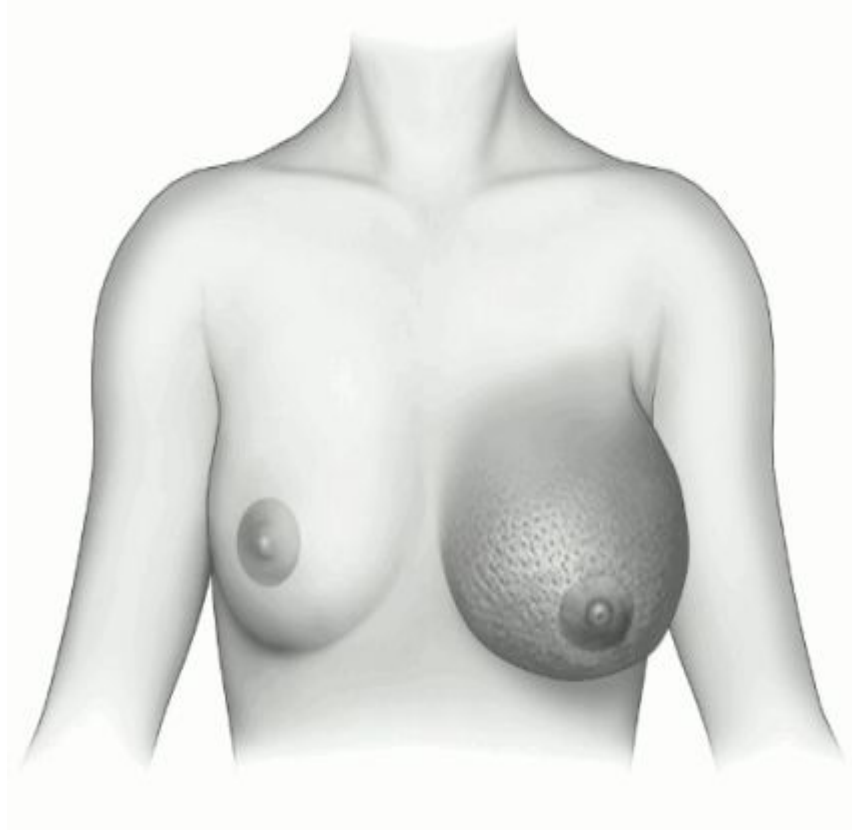
Invasive Lobular carcinoma (ILC)



Other rarer variants

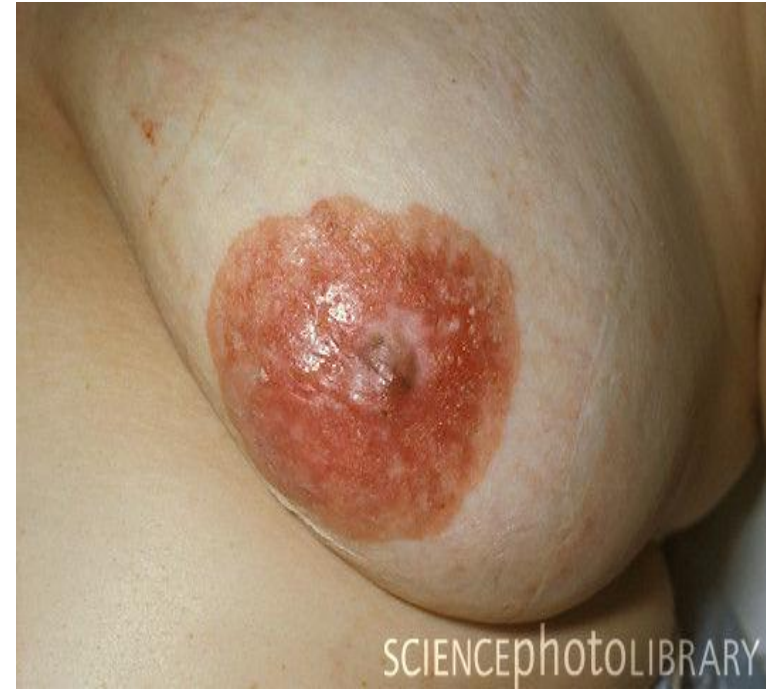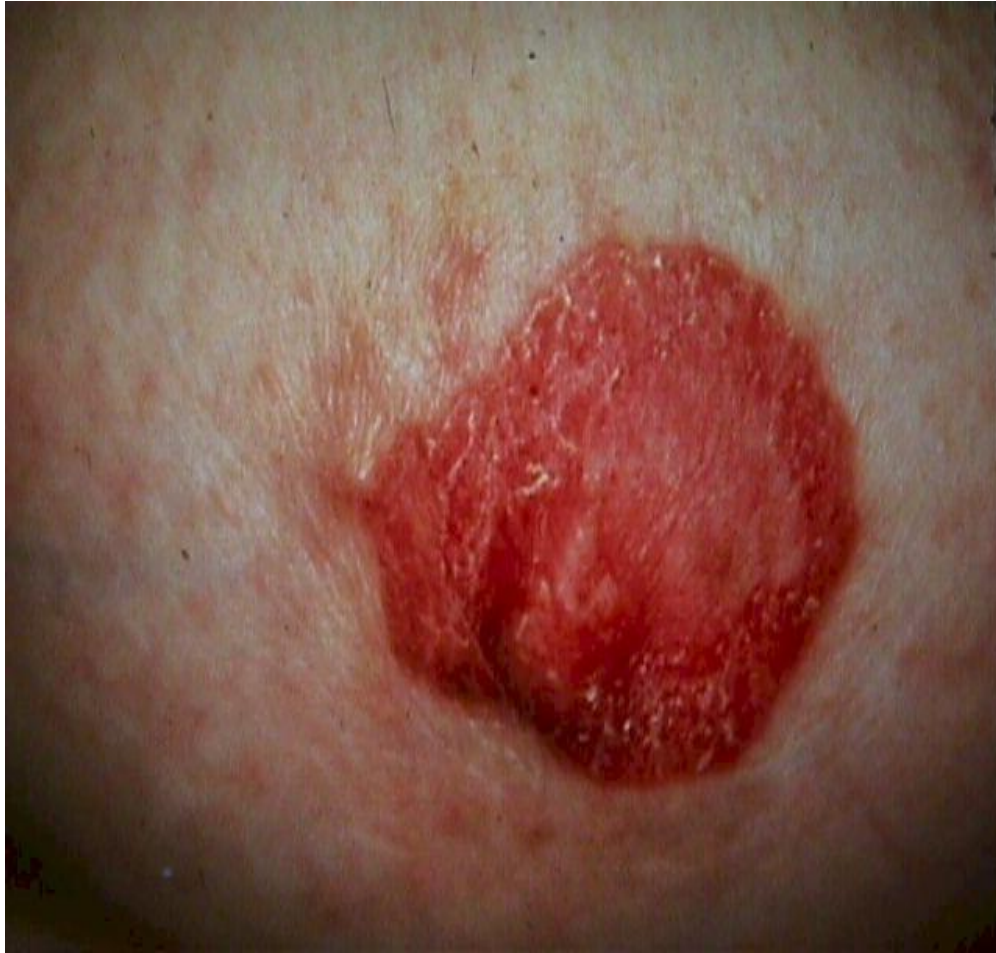- Colloid (mucinous) carcinoma: produce abundant mucin.
- Medullary carcinoma: solid sheets of large cells often associated with a marked lymphocytic reaction.
- Tubular carcinoma.
- Papillary carcinoma.

Inflammatory breast cancer



- Rare, highly aggressive cancer that presents as a painful, swollen breast, which is warm with cutaneous oedema.
- Biopsy...
- Aggressive chemotherapy, radiotherapy and salvage surgery.

Paget Disease of the Nipple



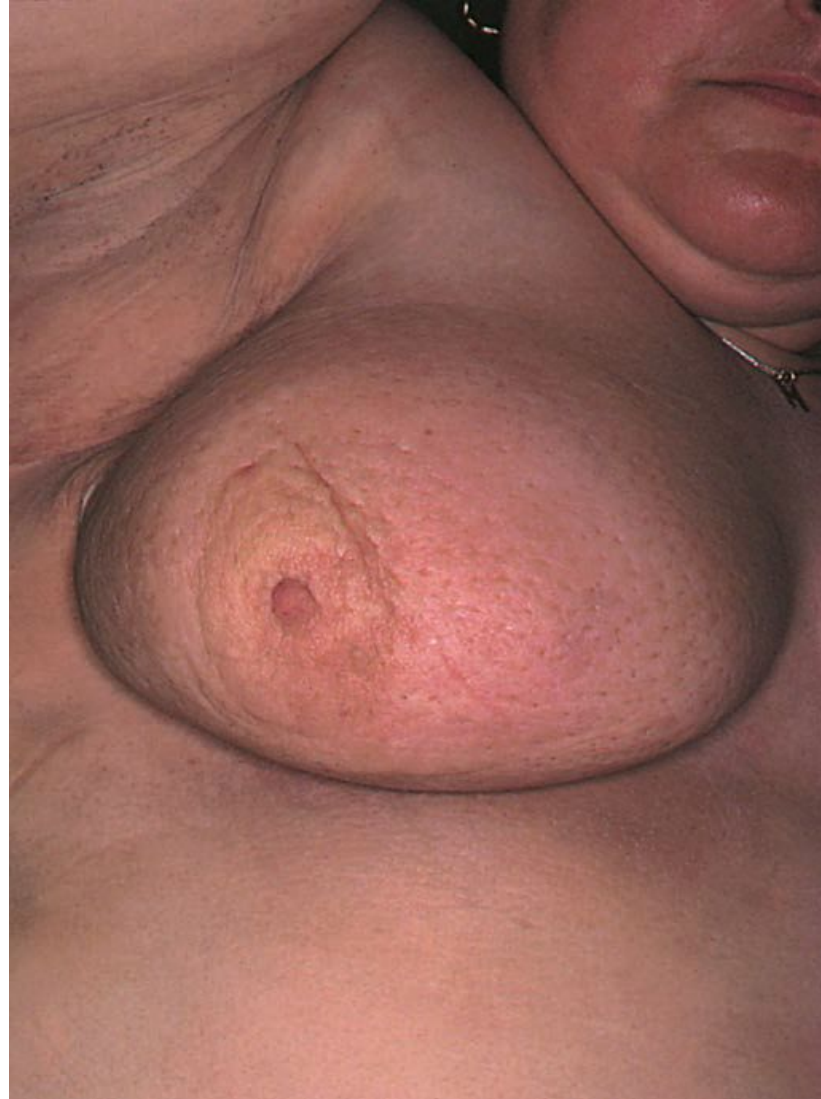- It is a superficial manifestation of an underlying breast carcinoma (IDC or DCIS).
- Presents as an eczema-like condition of the nipple and areola, which persists despite local treatment.

The spread of breast cancer

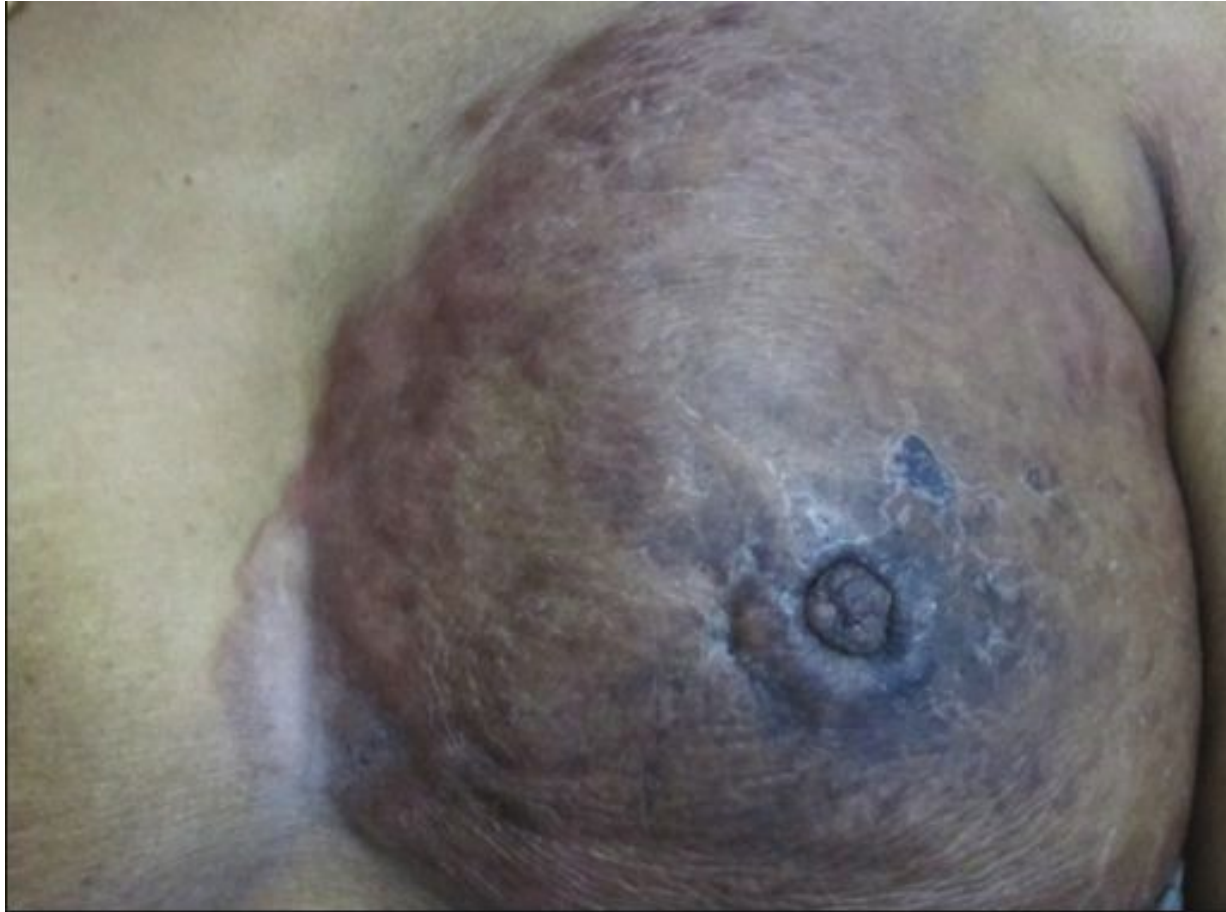- Local spread...
- Lymphatic metastasis...
- Hematogenous spread...

**Phenomena resulting from
lymphatic obstruction in
advanced breast cancer:**

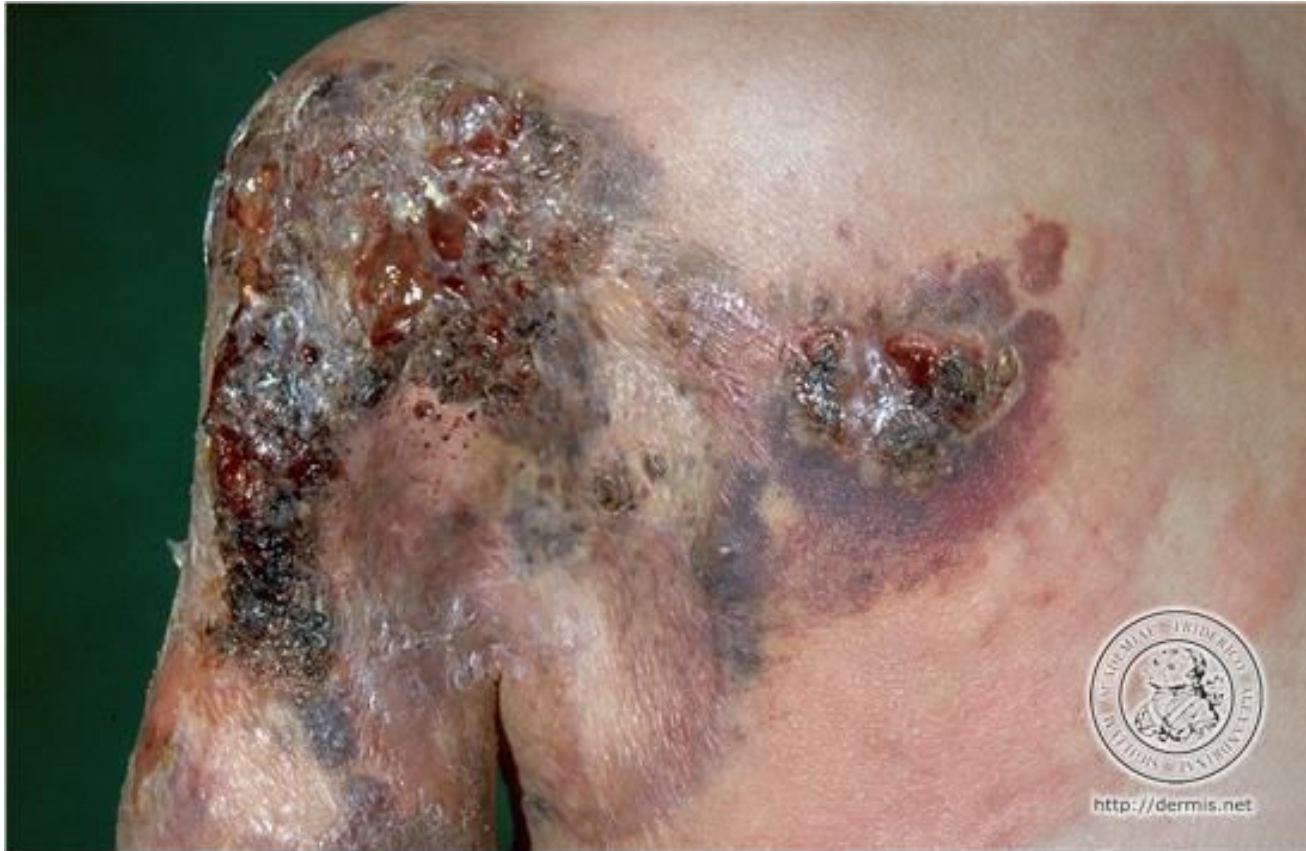Peau d'orange

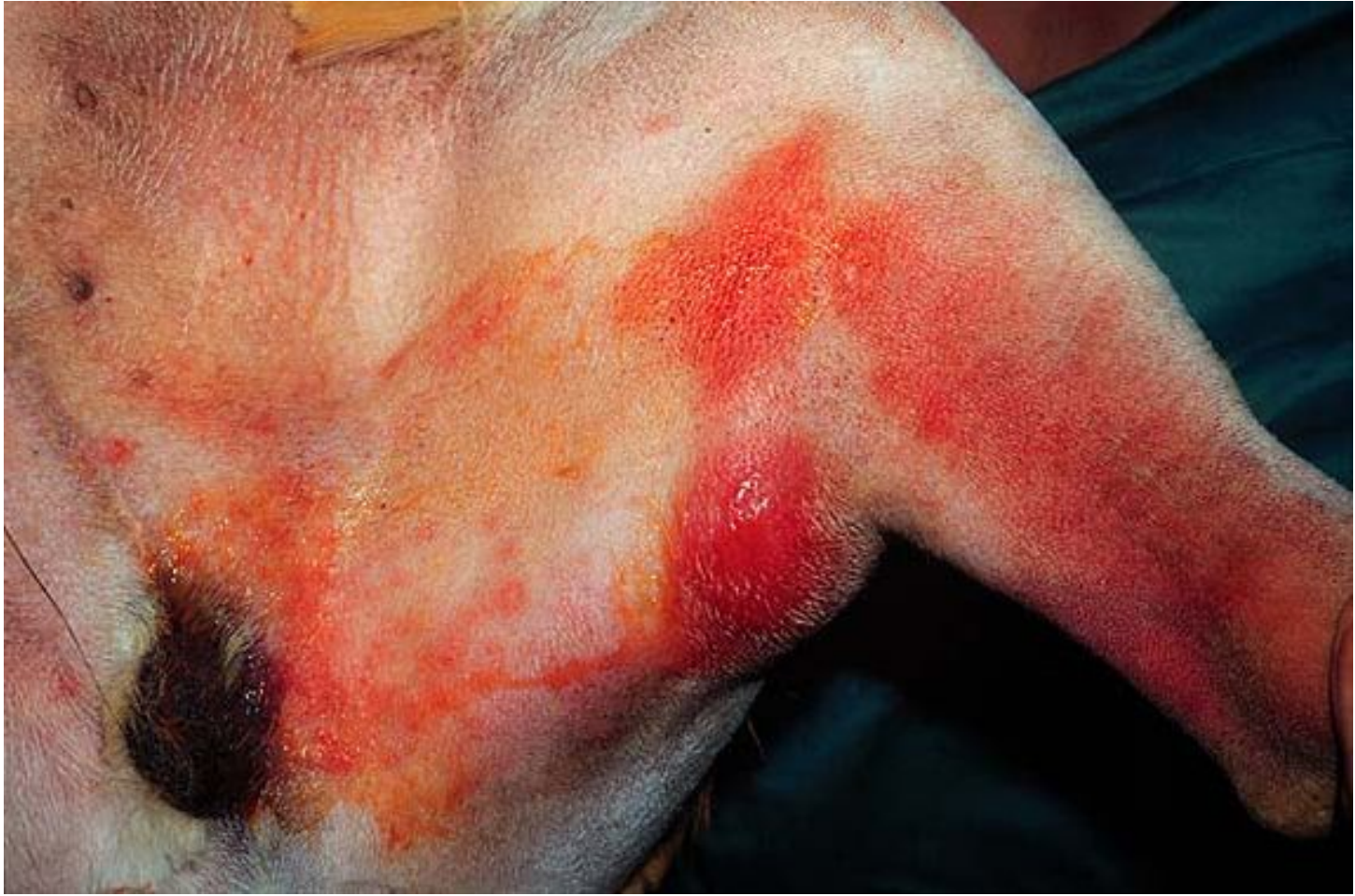

Cancer-en-cuirasse



Lymphangiosarcoma





Breast Carcinoma Grading





The degree of differentiation:

- Well differentiated.
- Moderately differentiated.
- Poorly differentiated.

Breast cancer staging

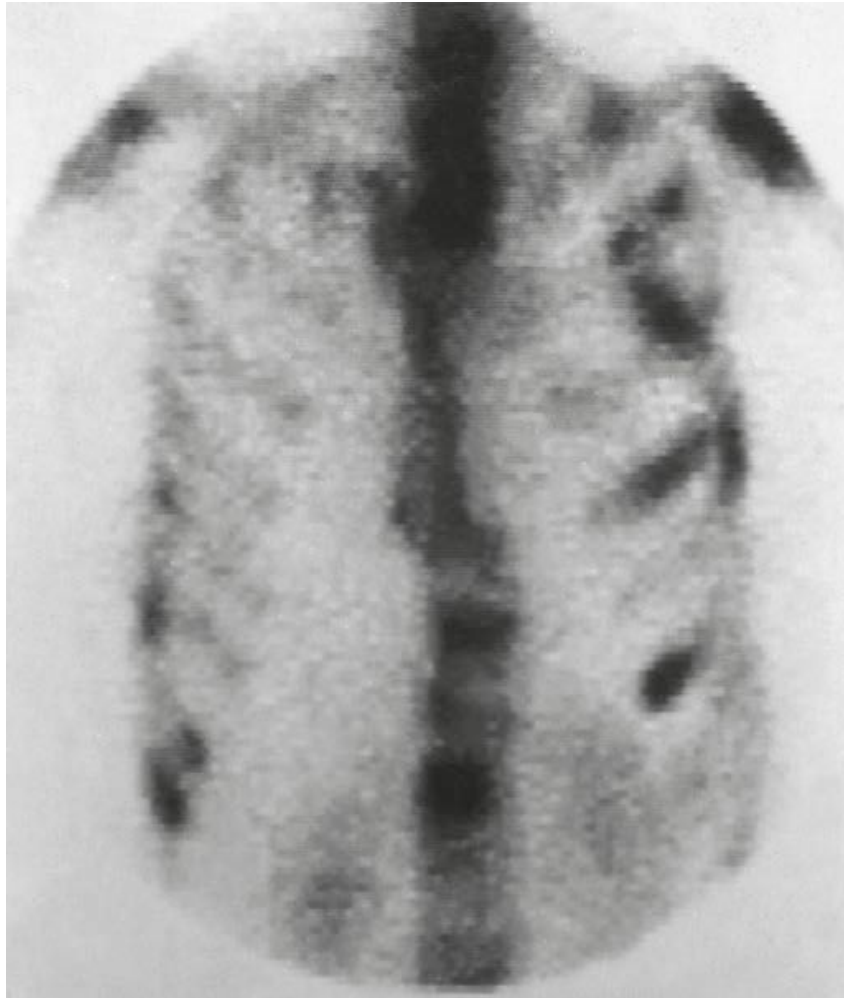TNM staging takes into account:

- 1.** The size of the tumour (T).
- 2.** Whether the cancer has spread to the lymph glands (lymph nodes) (N).
- 3.** Whether the tumour has spread anywhere else in the body (M - for metastases).

<p>Tumor size</p> <p>T</p>	<p>Tumor size < 2 cm</p>  <p>T1</p>	<p>Tumor size 2-5 cm</p>  <p>T2</p>	<p>Tumor size > 5 cm</p>  <p>T3</p>	<p>Tumor extends to skin or chest wall</p>  <p>T4</p>
<p>Lymph Nodes</p> <p>N</p>	<p>N0</p> <p>No lymph node metastasis</p>	<p>N1</p> <p>Metastasis to ipsilateral, movable, axillary LNs</p>	<p>N2</p> <p>Metastasis to ipsilateral fixed axillary, or IM LNs</p>	<p>N3</p> <p>Metastasis to infraclavicular/supraclavicular LN, or to axillary and IM LNs</p>
<p>Metastasis</p> <p>M</p>	<p>M0</p> <p>No distant metastasis</p>	<p>M1</p> <p>Distant metastasis</p>		

TNM stage groupings

STAGE 0	TIS	N0	M0
Stage IA	T1 ^a	N0	M0
Stage IB	T0	N1mi	M0
	T1 ^a	N1mi	M0
Stage IIA	T0	N1 ^b	M0
	T1 ^a	N1 ^b	M0
	T2	N0	M0
Stage IIB	T2	N1	M0
	T3	N0	M0
Stage IIIA	T0	N2	M0
	T1 ^a	N2	M0
	T2	N2	M0
	T3	N1	M0
	T3	N2	M0
Stage IIIB	T4	N0	M0
	T4	N1	M0
	T4	N2	M0
Stage IIIC	Any T	N3	M0
Stage IV	Any T	Any N	M1



Skeletal isotope bone scan showing multiple 'hot-spots' due to metastases.

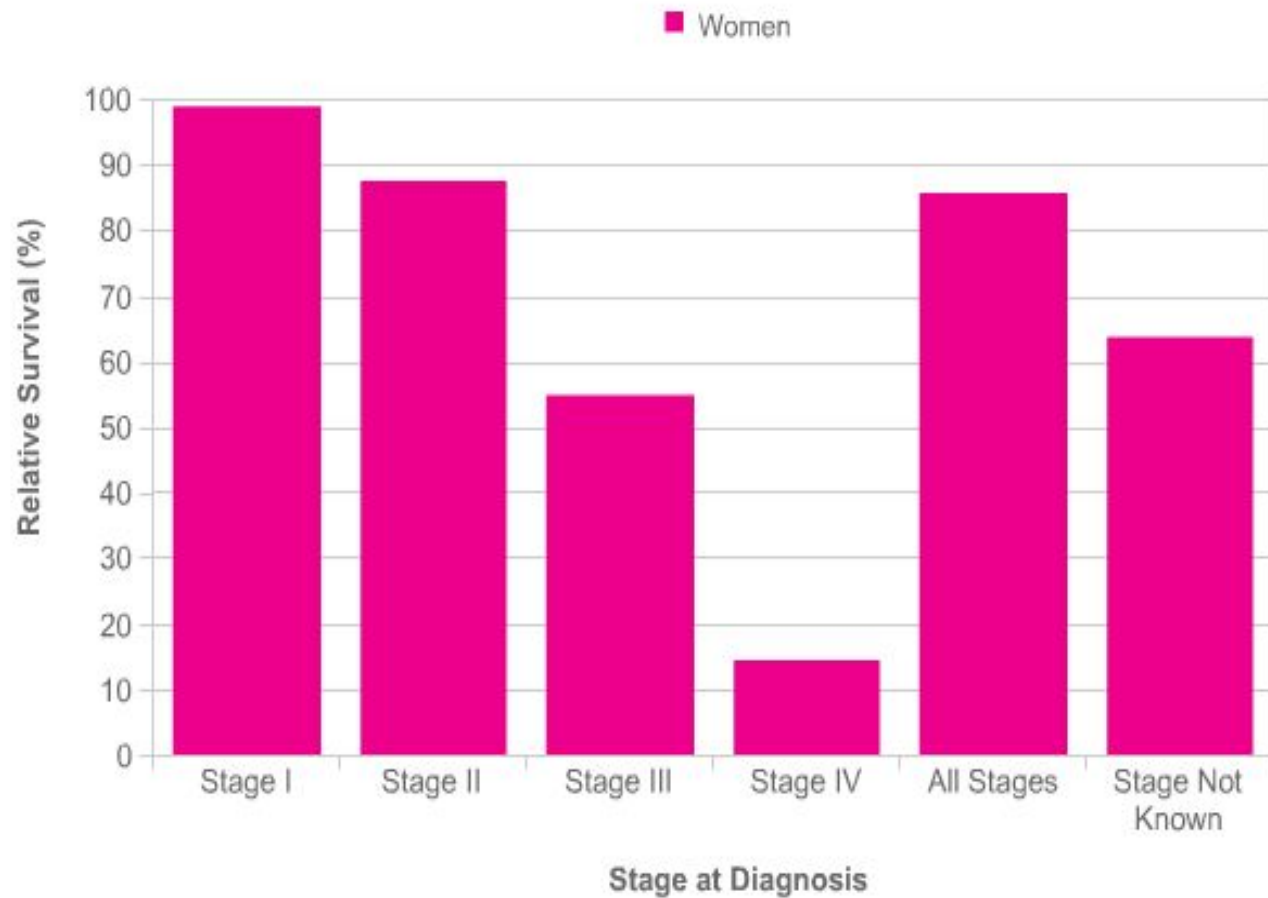
Prognosis of breast cancer

- The best indicators of likely prognosis in breast cancer remain tumour **size**, **grade** and **lymph node involvement**...
- Nottingham prognostic index (NPI)

$$NPI = [0.2 \times S] + N + G$$

Score	5-year survival
≥ 2.0 to ≤ 2.4	93%
> 2.4 to ≤ 3.4	85%
> 3.4 to ≤ 5.4	70%
> 5.4	50%

Figure 3.7 Breast Cancer (C50), Five-Year Relative Survival by Stage, Women (Aged 15-99 Years), Former Anglia Cancer Network, 2002-2006



Breast Cancer in Men

Breast Cancer in Men accounts for less than 1% of male cancers and less than 1% of all breast cancers. BRCA2 mutations are associated with approximately 5% of these cancers.

Patients generally present with a nontender hard mass. Mammography distinguishes gynecomastia from malignancy. Malignant lesions are more likely to be eccentric, with irregular margins, and are often associated with nipple retraction and microcalcifications. Biopsy of suspicious lesions is essential.

85% of malignancies are infiltrating ductal carcinoma and are +ve for ER.

Adjuvant hormonal, chemotherapy, and radiation treatment criteria are the same as in women.

Screening & Imaging

- Breast screening aims to find breast cancers early. It uses an X-ray test called a mammogram that can spot cancers when they are too small to see or feel.
- Most common screening tests are:
 - 1.** Mammogram.
 - 2.** Clinical Breast Exam.
 - 3.** Self Breast Exam.

Advantages

Reduced mortality

Reduced incidence of invasive cancers

Improved prognosis for individual patients

Reduced morbidity for cases treated at earlier stages

Identification of high-risk groups and opportunities for intervention

Reassurance for those screened negative

Cost savings

Disadvantages

Detection of cases already incurable may increase morbidity for some patients

Unnecessary treatment of those potentially malignant lesions, which may not have progressed

Psychological trauma for those with a false-positive screen

False reassurance for those negative screen

Reinforcement of bad habits among individuals screened negative

Costs

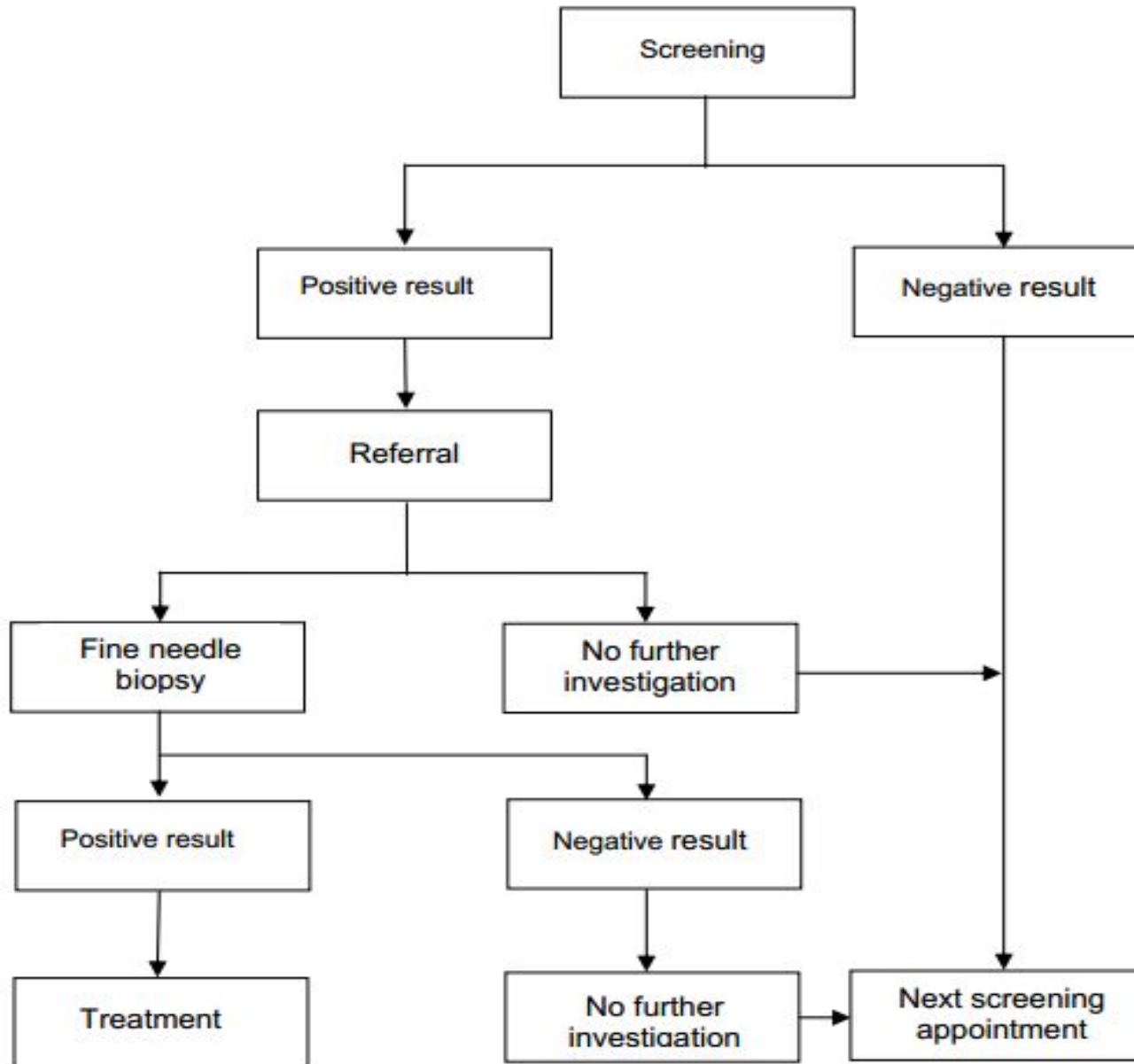
Early Detection Plan

Early Detection Plan

Women at normal risk can follow the Early Detection Plan below, which summarizes the national recommendations in Jordan:

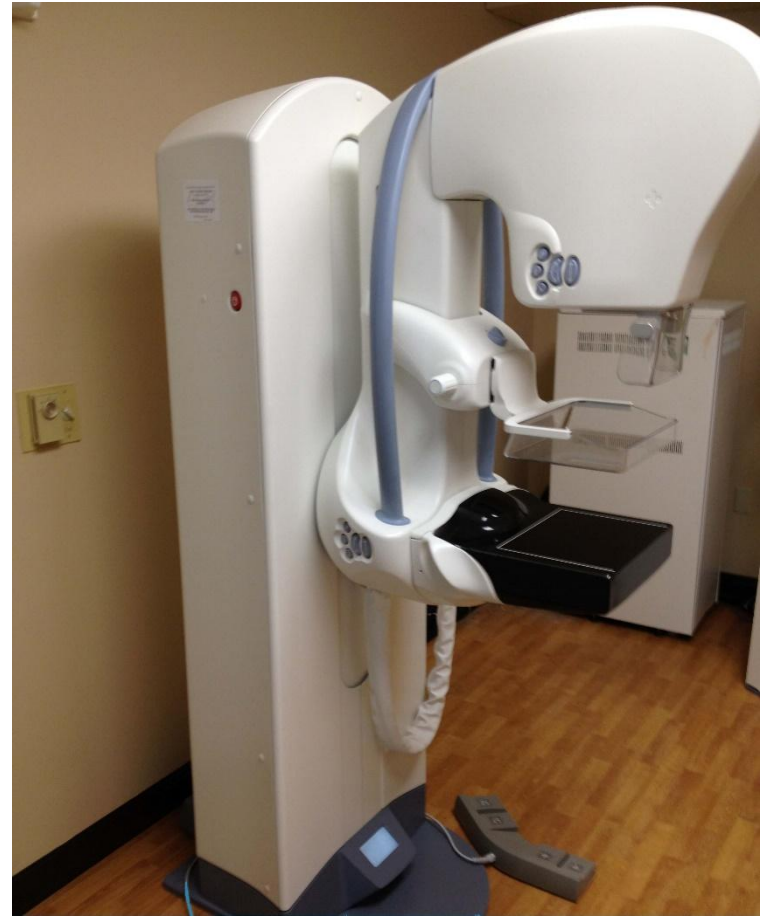Screening/ Age	20-29	30-39	40-52	52+
Self Breast Exam	Monthly	Monthly	Monthly	Monthly
Clinical Breast Exam	Once every 1-3 years	Once every 1-3 years	Annually	Annually
Mammogram	-----	-----	Once Every 1-2 years	Once Every 2 years

Screening Protocol

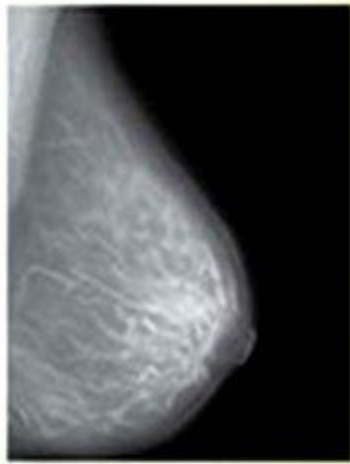

Mammography

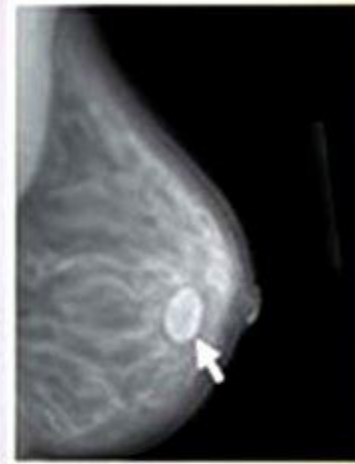- Soft tissue radiographs are taken by placing the breast in direct contact with ultrasensitive film and exposing it to x-rays. The dose of radiation is **very low** and, therefore, mammography is a **very safe** investigation.
- The **sensitivity** of this investigation **increases with age** as the breast becomes **less dense**.
- In total, only **5 per cent** of breast cancers are **missed** by population-based mammographic screening programs.



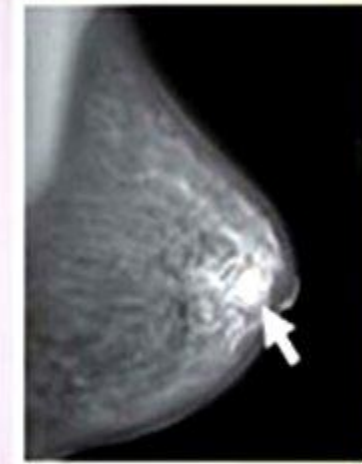Mammography (Cont'd)



Normal
mammogram



Benign cyst
(not cancer)



Cancer

Ultrasonography

- Ultrasound is particularly useful in **young women with dense breasts** in whom mammograms are difficult to interpret, and in distinguishing cysts from solid lesions.
- It can also be used to localize impalpable areas of breast pathology.
- It is not useful as a screening tool and remains **operator dependent**.

Ultrasonography (Cont'd)

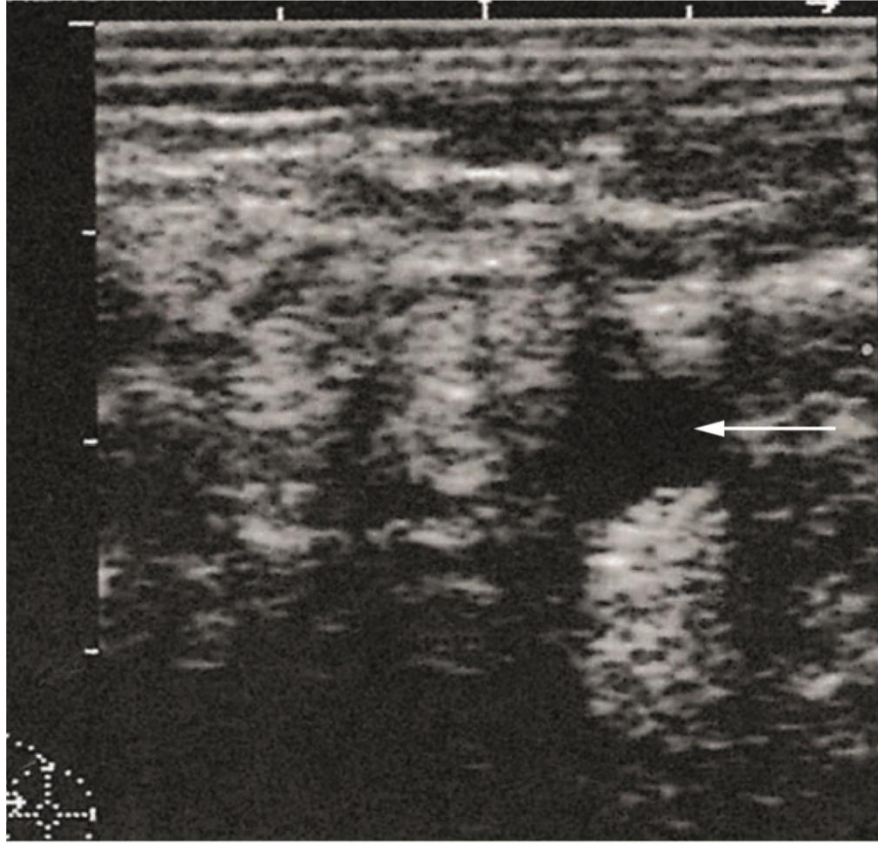


Figure 53.3 Ultrasound of the breast showing a cyst (arrow).

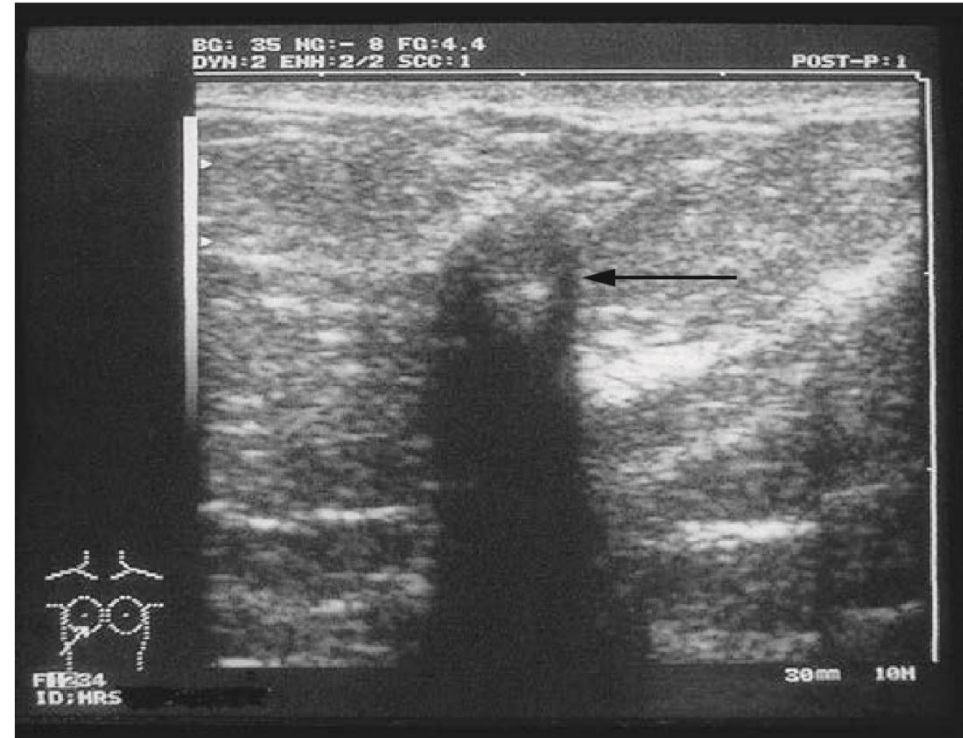
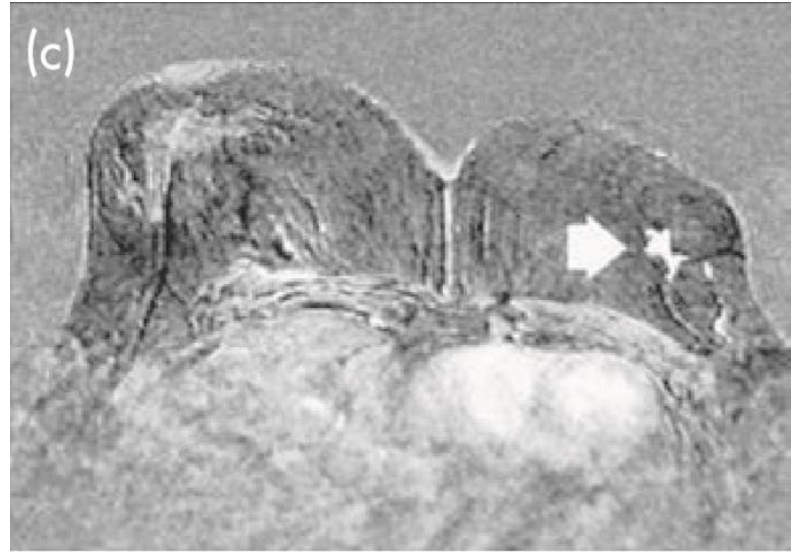
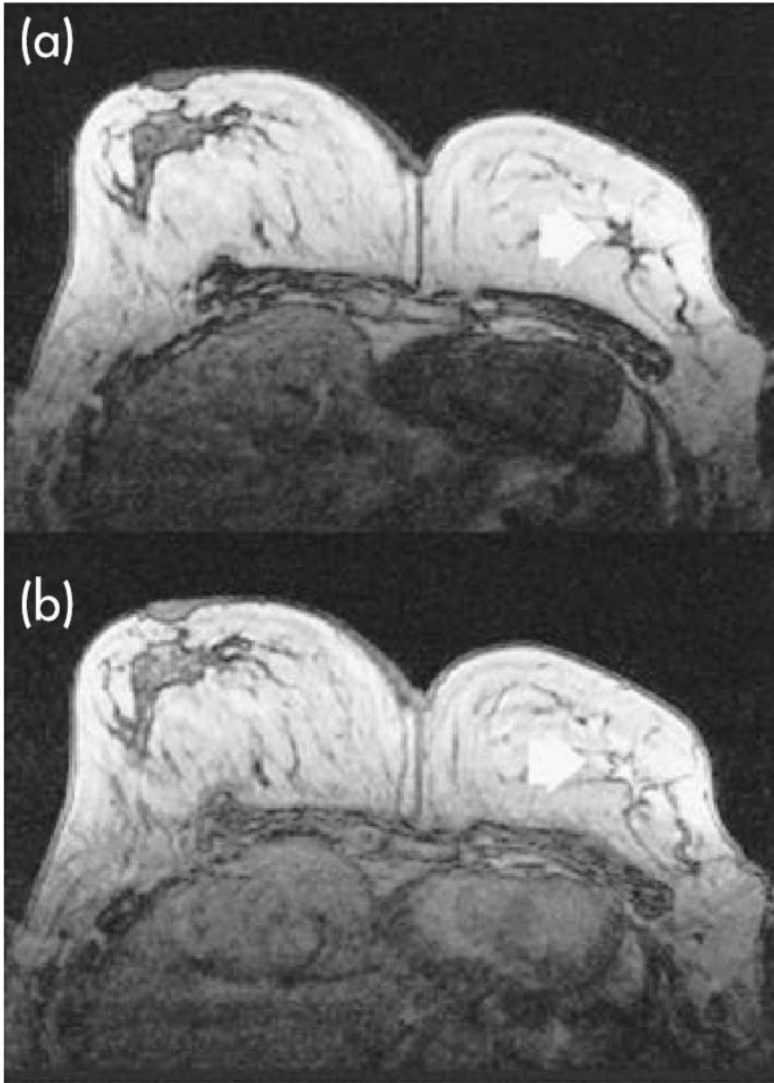


Figure 53.4 Ultrasound of the breast showing a carcinoma (arrow).

Magnetic Resonance Imaging

- Magnetic resonance imaging (MRI) is of increasing interest to breast surgeons in a number of settings:
 - 1.** It can be useful to distinguish **scar** from **recurrence** in women who have had previous breast conservation therapy for cancer.
 - 2.** It is becoming the standard of care when a **lobular cancer** is diagnosed to assess for **multifocality** and **multicentricity**.
 - 3.** It has proven to be useful as a screening tool in **high-risk women** (because of family history).

Magnetic Resonance Imaging (Cont'd)



Magnetic resonance imaging scan of the breasts showing carcinoma of the left breast (arrows). (a) Pre-contrast; (b) post-gadolinium contrast; (c) subtraction image.

History:

PRESENTATION OF BREAST DISEASE

- Breast disease presents in three main ways:
 - **lump**, which may or may not be painful,
 - **pain**, which may or may not be cyclical,
 - **nipple discharge** or change in appearance.

Focused history has to be taken according to these presentations

Breast lump (Mass)

- When did the patient first notice it & how?
- Site
- Painful or not
- Hard or soft
- Single or multiple
- Changes in the size & shape of the mass
- Skin changes overlying the mass
- Relation to the menstrual cycle
- Other local symptoms :
 - Nipple discharge and inversion
 - Retroareolar pain or hotness & discoloration of skin

Breast pain

- Duration
- SOCRATES
- Relation with periods
- Nipple discharge
- Discoloration and hotness of skin
- Fever, fatigue, anorexia and weight loss
- History of trauma
- Pregnancy or lactation
- Last menstrual cycle

Nipple Discharge

- Site (nipple itself or adjacent area)
- Episodic or continuous
- Color
- Viscosity
- Passive or induced
- Uni/bilateral

Skin changes

- Skin dimple
- Eczema
- Indrawing of the skin
- Ulceration
- Discoloration
- Redness and hotness
- Overall swelling of the breast

Nipple changes

- Is it retracted or destroyed
- Uni/bilateral
- Can it be everted easily

• Gynecological symptoms :

- ✓ Last menstrual cycle
- ✓ duration
- ✓ menarche
- ✓ menopause
- ✓ Any changes: Increased blood, clots or irregularity
- ✓ previous pregnancies and lactation:
 - How many children has the patient had?
 - Age of the pt when she had her 1st child
 - Were the children breast-fed, and if so, for how long?

- **Past History** (e.g breast cyst)
- **Drug History** (e.g oral contraceptives, hormone replacement therapy)
- **Family History** (breast or ovarian Ca)
- **Previous Irradiation** (Hodgkins lymphoma)

Physical Examination:

Position

Inspection

Palpation

position

- The patient must be fully undressed to the waist.
- sitting 45 degrees
- Patients sometimes say that their lump can only be felt when they adopt a certain posture and they should therefore be examined in this position as well.

Inspection

- Stand or sit directly in front of the patient, inspect both breasts and look for the following features

A) With the patient's hands resting on thighs
:

1. Size

2. Symmetry

3. Skin :

-ulceration -puckering

-nodules -peau d'orange -discoloration

4. Nipples & Areolae:

- Depression
- Destruction
- Discoloration
- Displacement
- Deviation
- Discharge

- To check for accessory nipple: check the nipple line (axilla-->groin), if the nipple is inverted ask the patient to evert it.
- Normal direction **downward** and **outward** (if not deviated).
- To check if there is discharge or not:
 - ❖ ask her if there was discharge on her underwear.
 - ❖ ask her to squeeze the nipple.

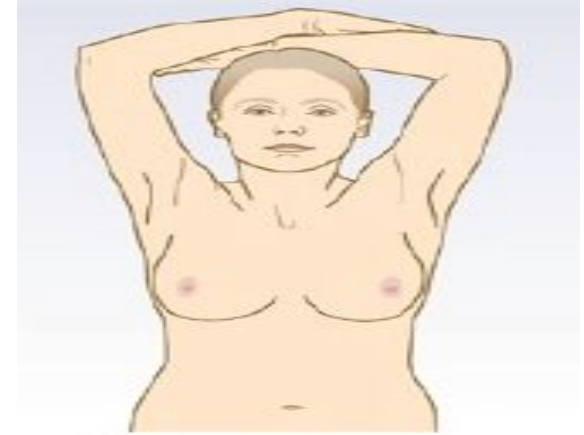5. Arm, axilla and neck

(Supraclavicular fossa)

- Ectopic breast tissue in the anterior axillary fold
- Visible LN in arm, axilla and supraclavicular fossa
- Distended vein
- Arm lymphedema

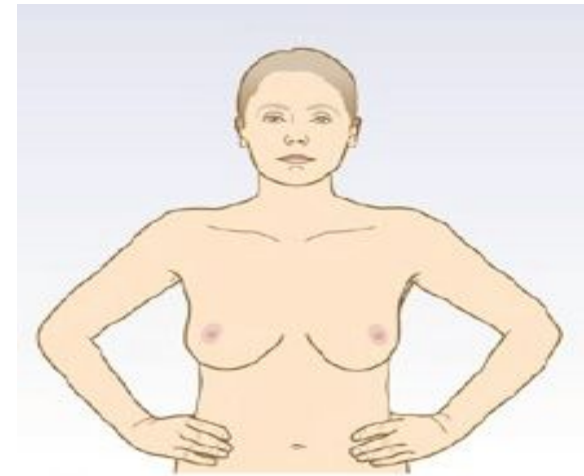
B) Arms Over Head :

Skin changes (esp. tethering) are more prominent, and to expose the underside in obese pt. .

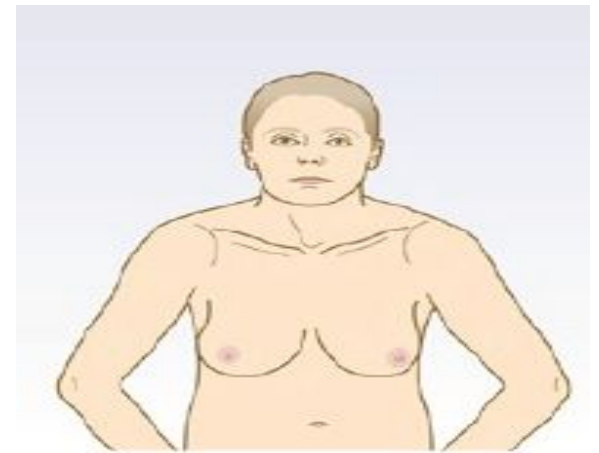


C) Hands Pressed Against Hips:

Tensing pectoralis muscle, may reveal previously invisible swellings.

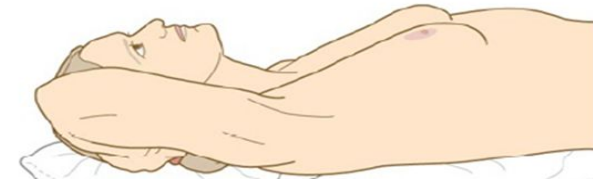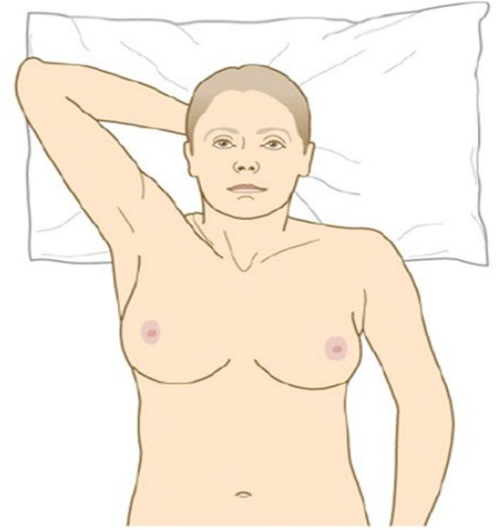


D) Leaning Forward:

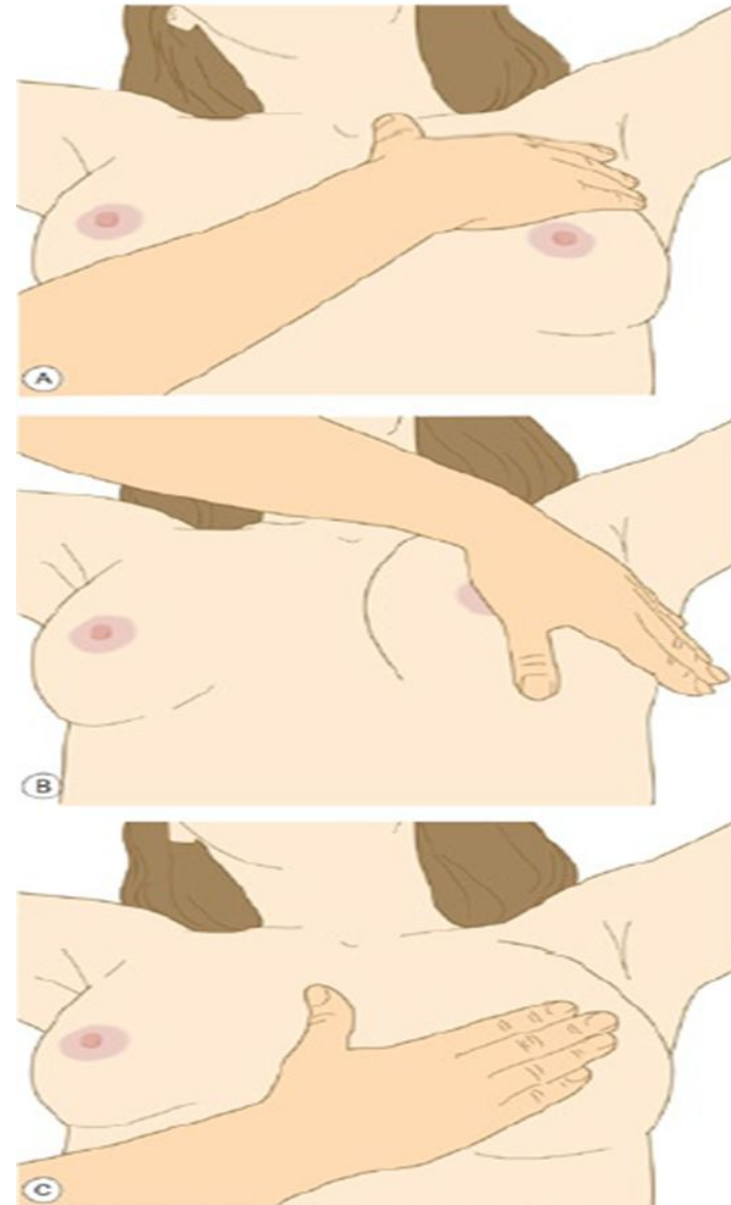


PALPATION

- Ask the patient to lay down with her hand ipsilateral to the breast.
- Ask where is the abnormality?
- Start with the normal breast, then abnormal, away from the tender area (for comparison and looking for separate pathology).



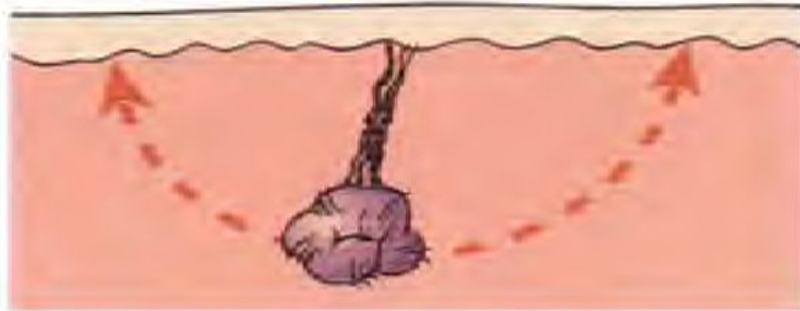- The breast should be palpated with the flat of the fingers and not with the palm of the hand.
- Palpate the axillary tail between your thumb and index finger
- Examine under the nipple using two fingers .
- In palpation we are looking for:
 - ❖ Tenderness
 - ❖ Temperature
 - ❖ Mass



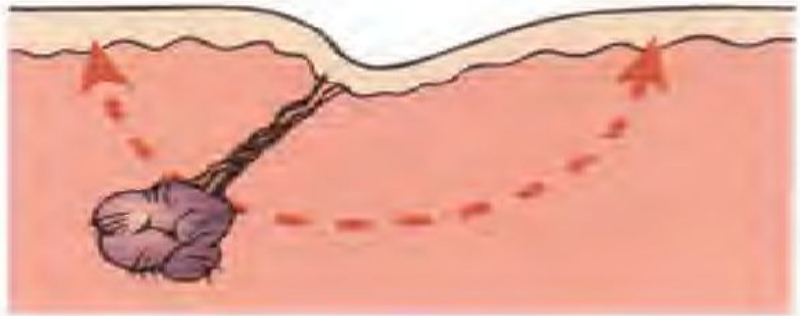
* If there is a lump we should analyze it :

L
S
S
S
E
S
C
F

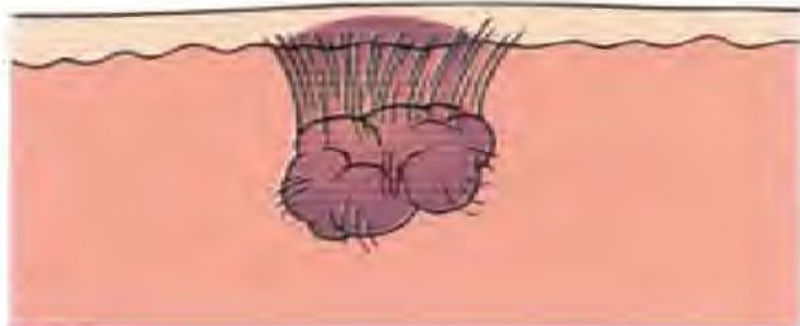
Relations of the lump to skin



Most lumps can be moved anywhere within the arc depicted, without moving the skin.



If when a lump is pulled outside the arc the skin indents, it is **tethered**.



If a lump cannot be moved without moving the skin, it is **fixed**.

Thank You 🥰