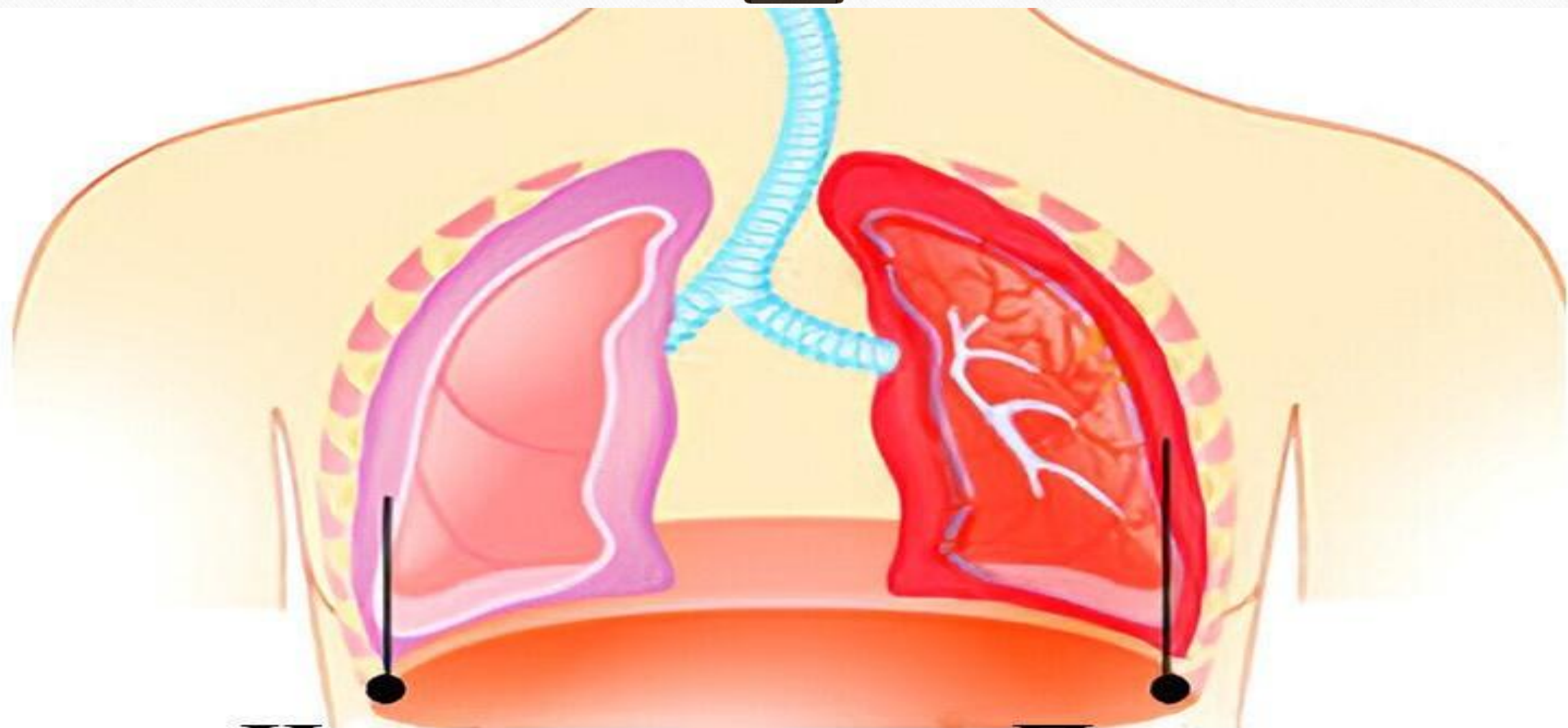


Toshkent Davlat Stomatologiya
Instituti Stomatologiya fakulteti
205-“A” guruh talabasi Dilruxsor
Hamidovaning Terapiya fanidan
tayyorlagan taqdimoti

Plevritlar etiologiya, patogenez,

patomorfologiya, xarakterli
simptomlari. Unda og'iz bo'shligida o' ziga xos
o'zgarishlar parhez va
medikamentoz davolash.



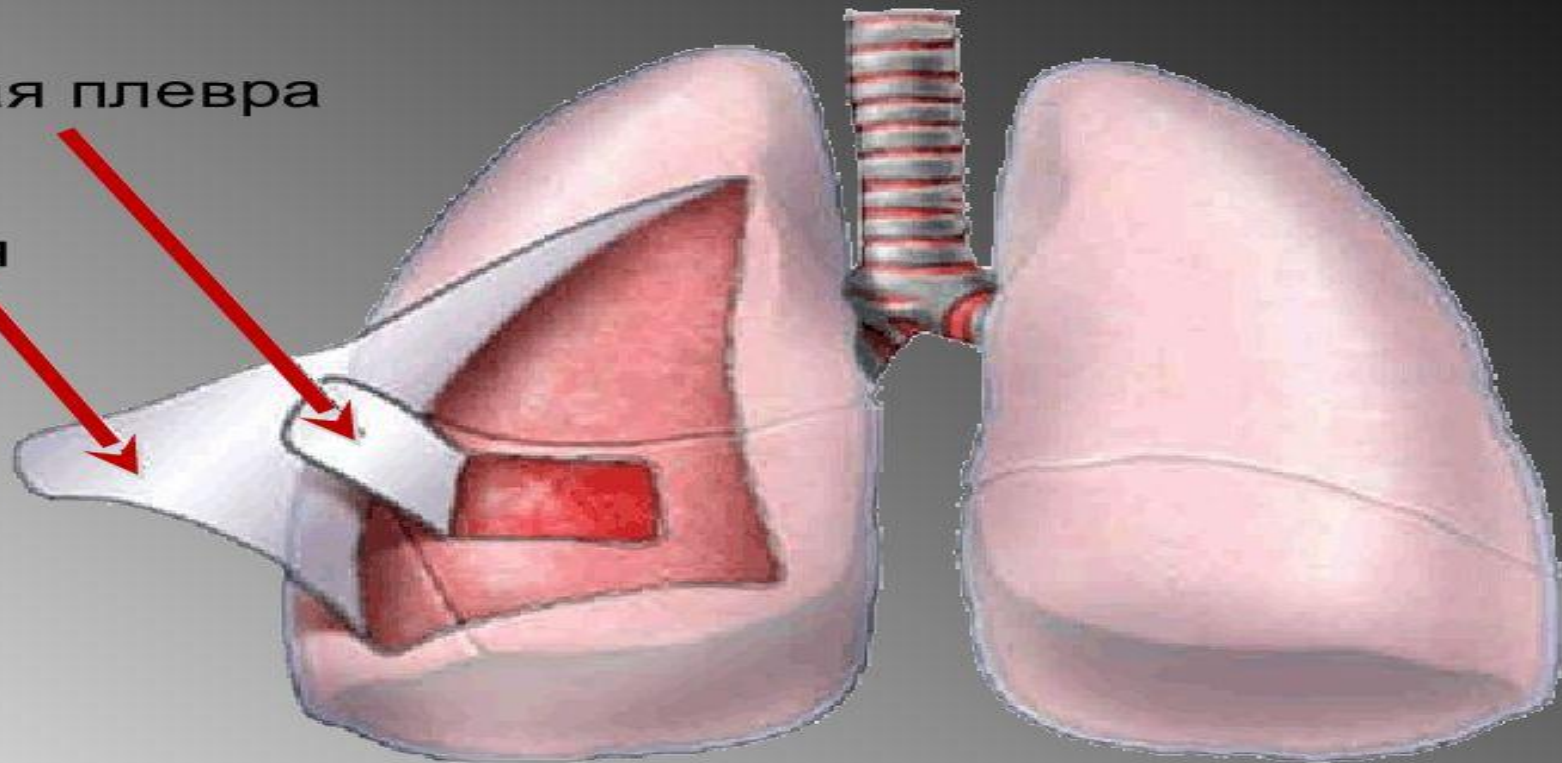
Норма

Плеврит

Плевра

Висцеральная плевра

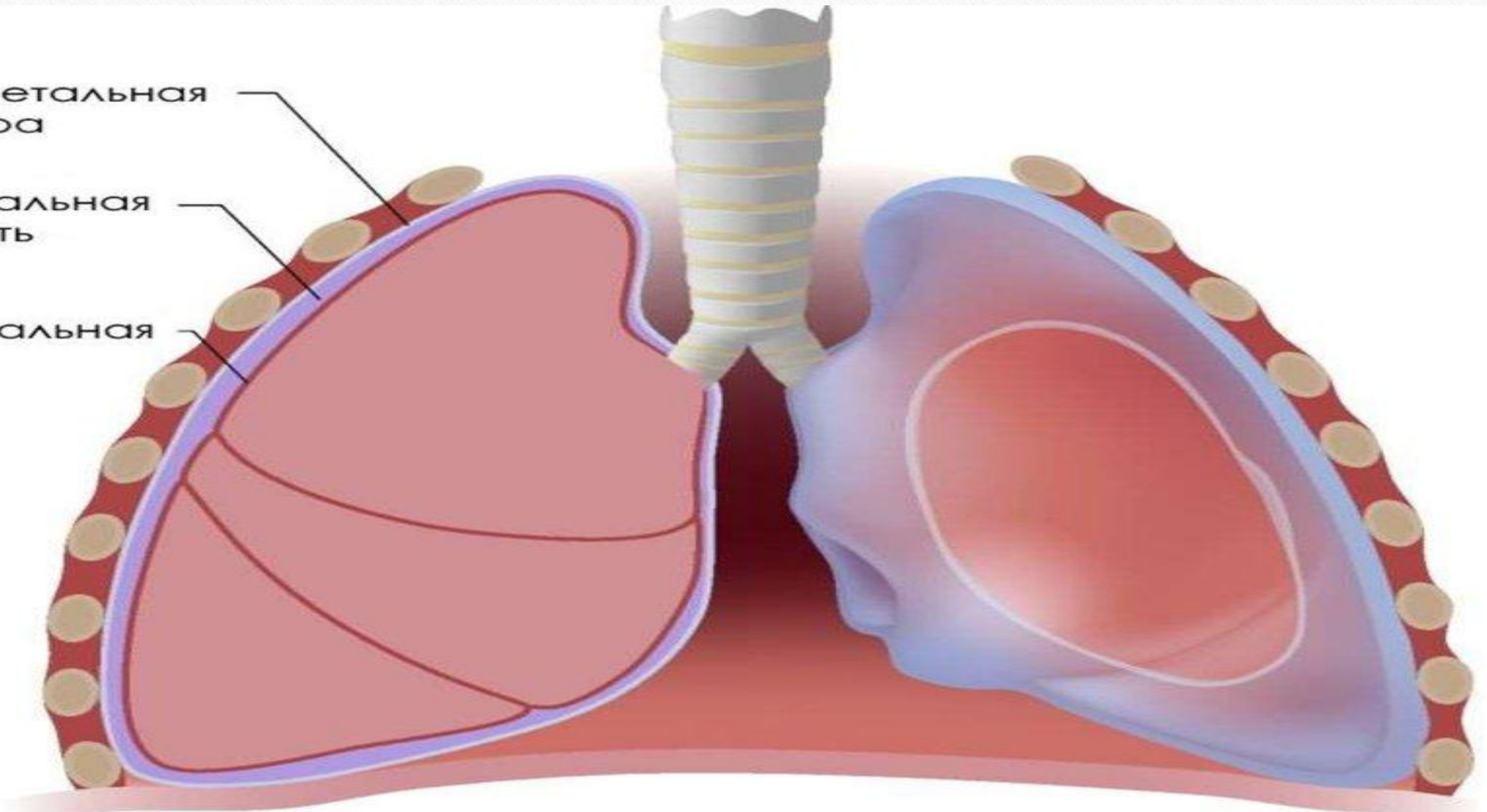
Париетальная плевра



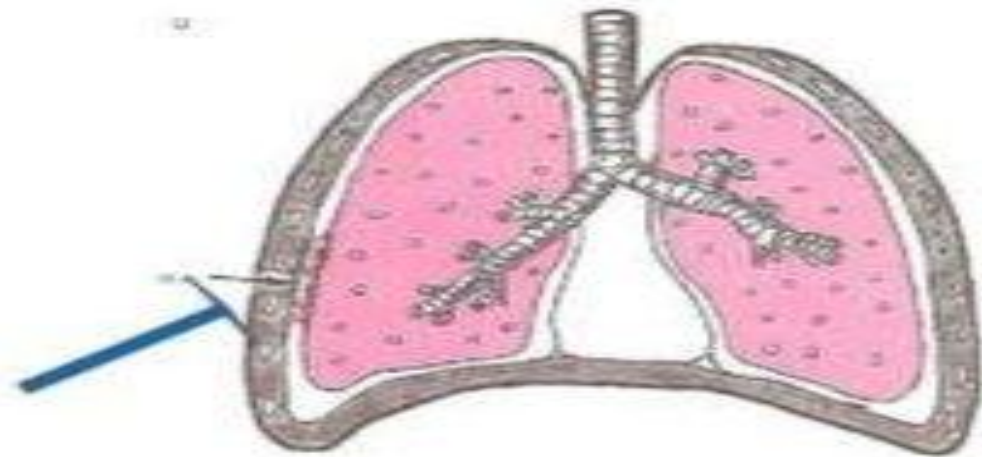
Париетальная
плевра

Плевральная
полость

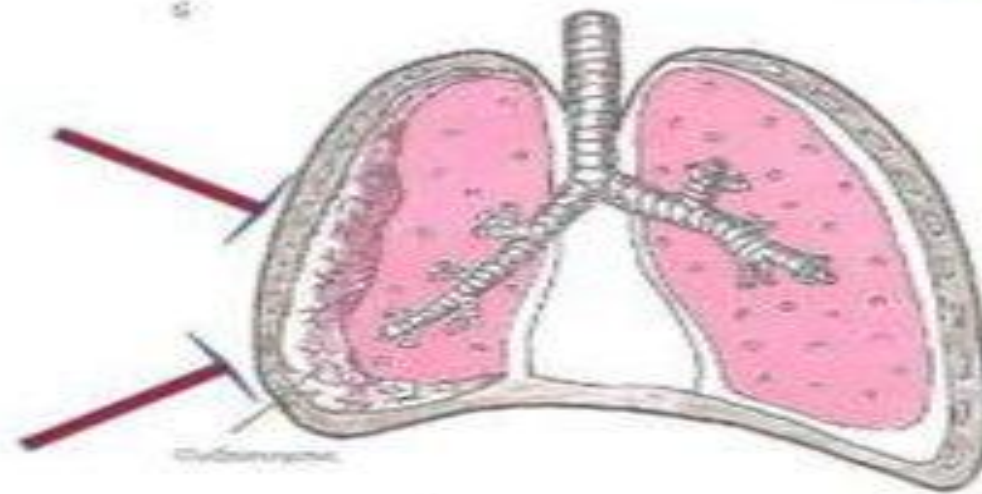
Висцеральная
плевра



• Плеврит сухой



• Плеврит
экссудативный



1. Ekssudat xarakteri bo'yicha

serozli;

fibrinozli;

seroz-fibrinozli;

yiringli;

chirigan;

gemorragik;

xilez,

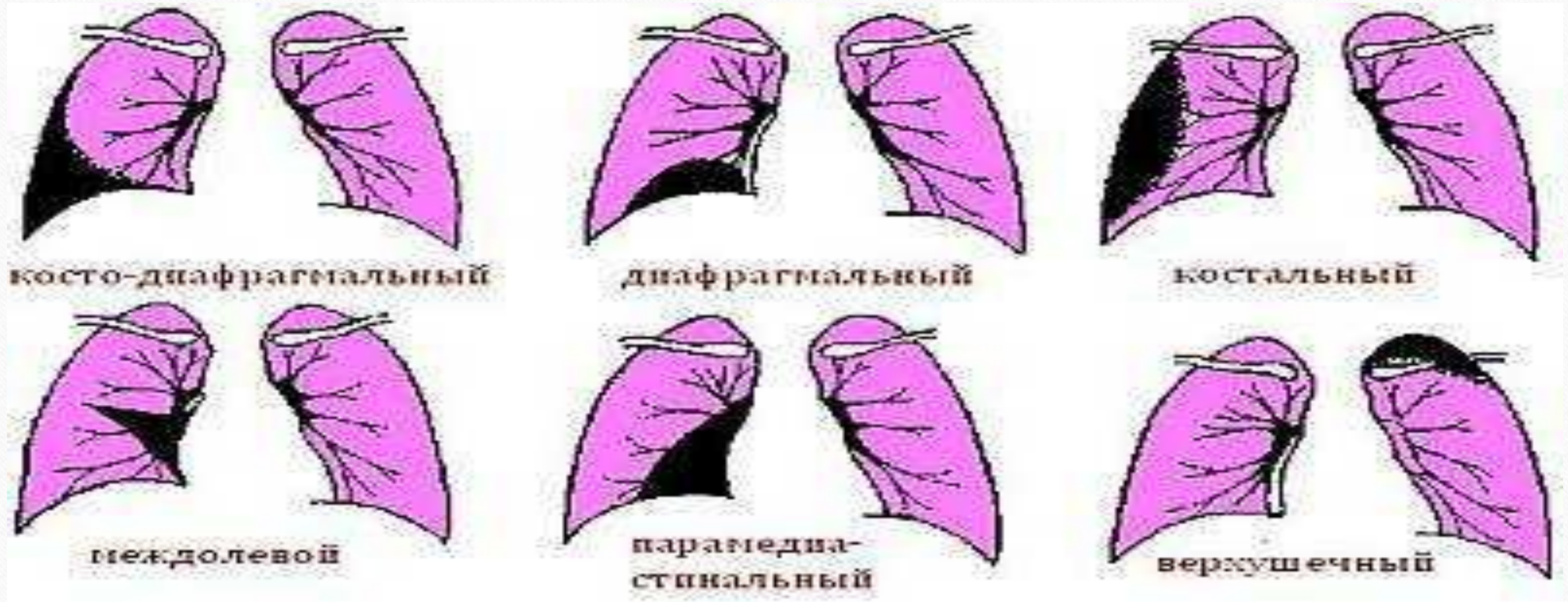
soxta xilez;

eozinofilli;

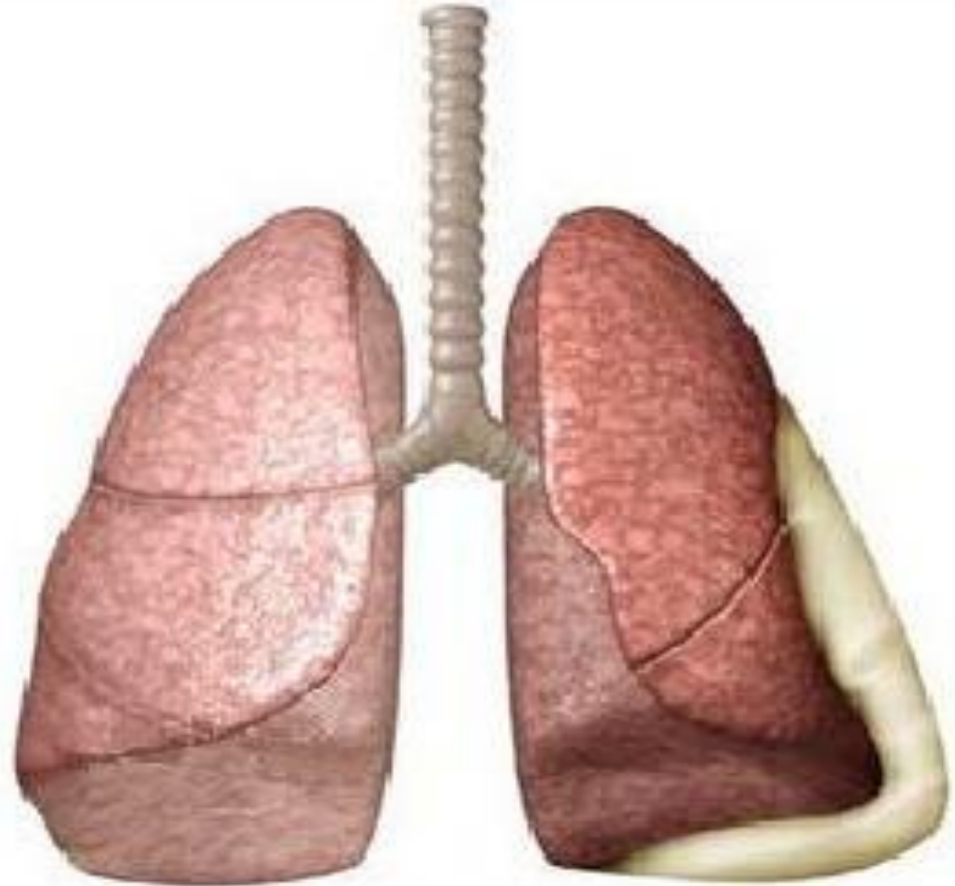
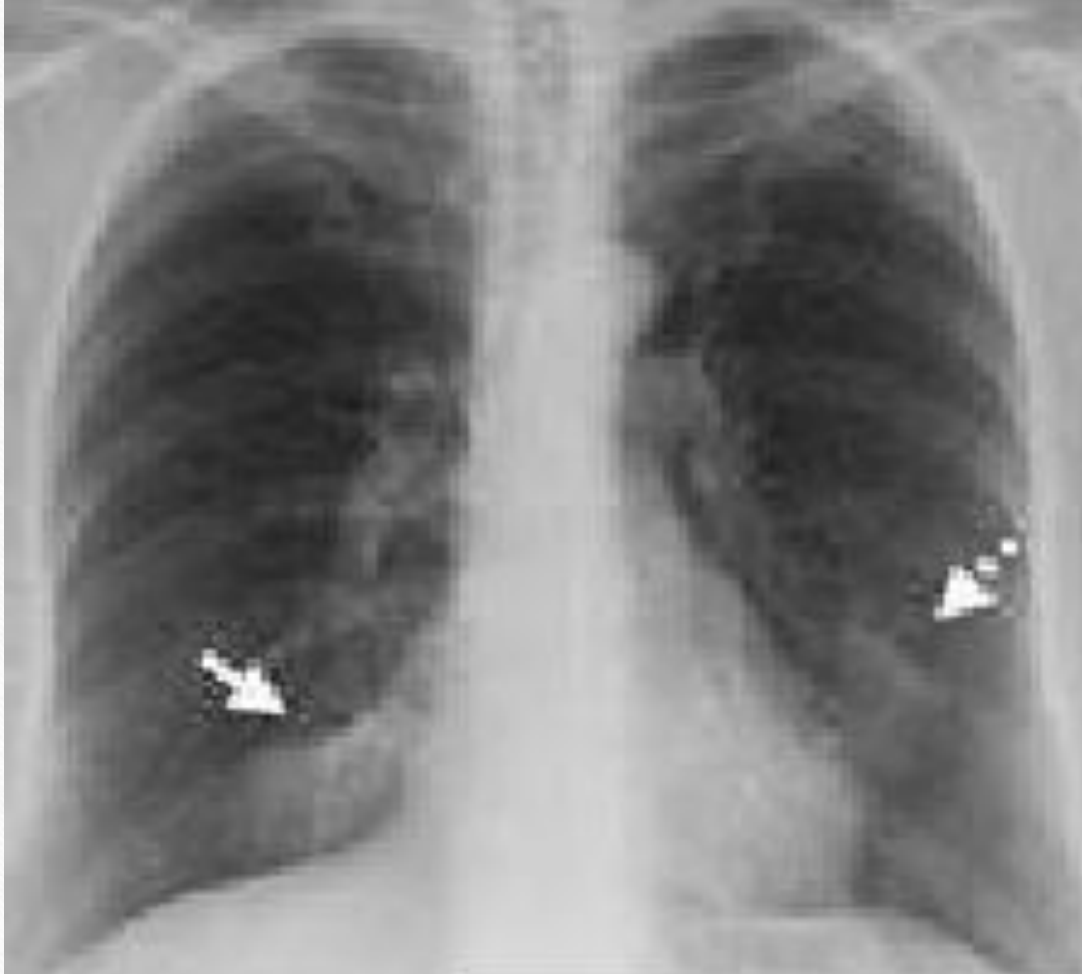xolesterinli;

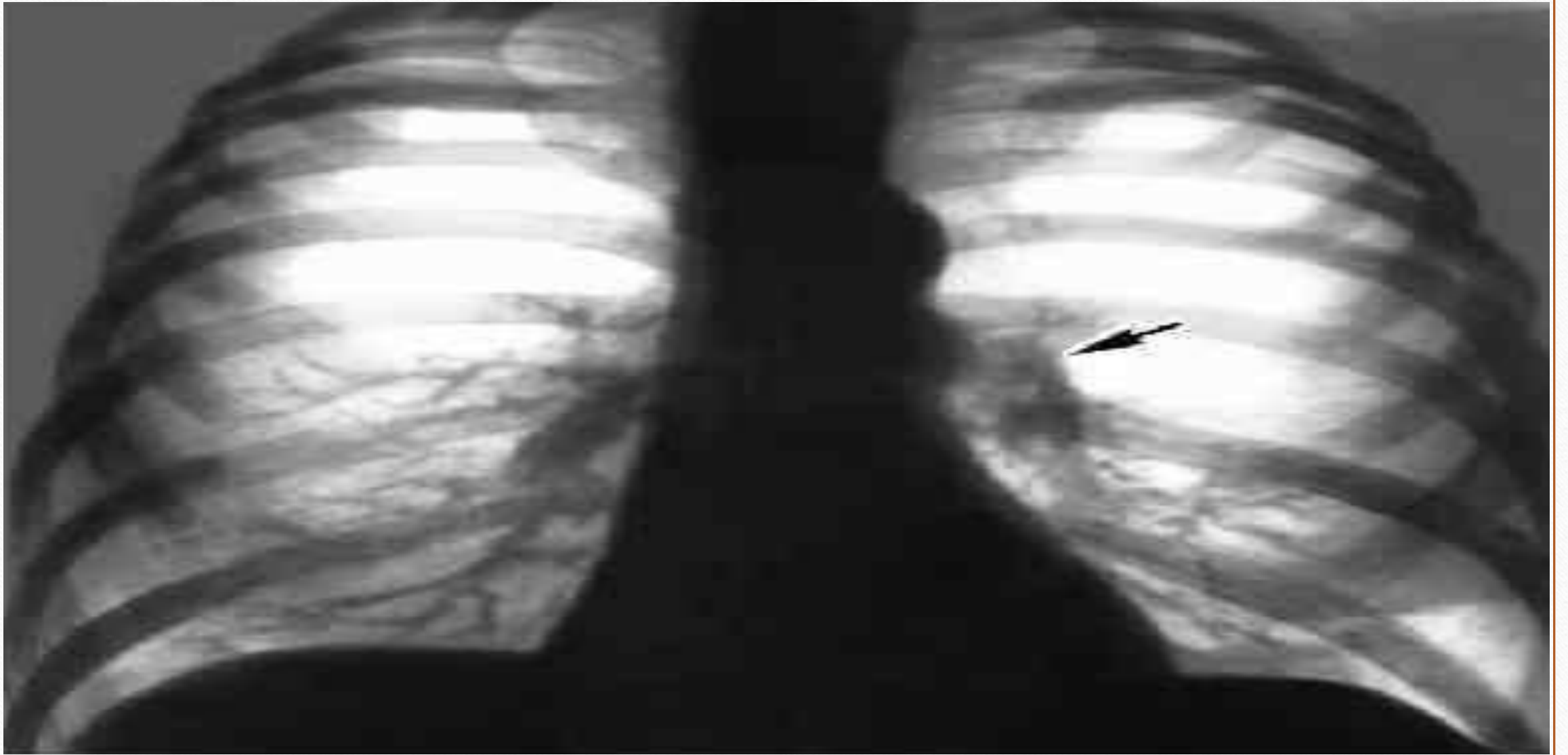
aralash.

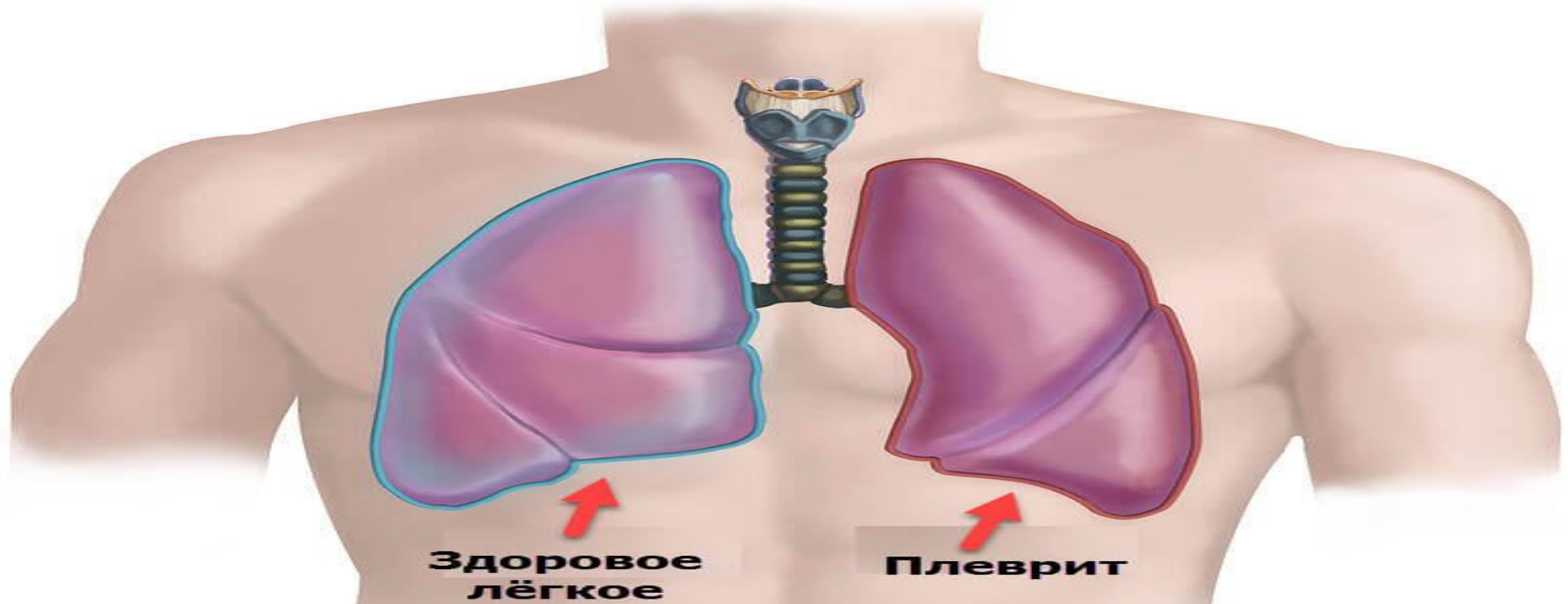
1. Joylashishi bo'yicha diffuz va chegaralangan (xaltachasimon)



Quruq (fibrinoz) plevrit



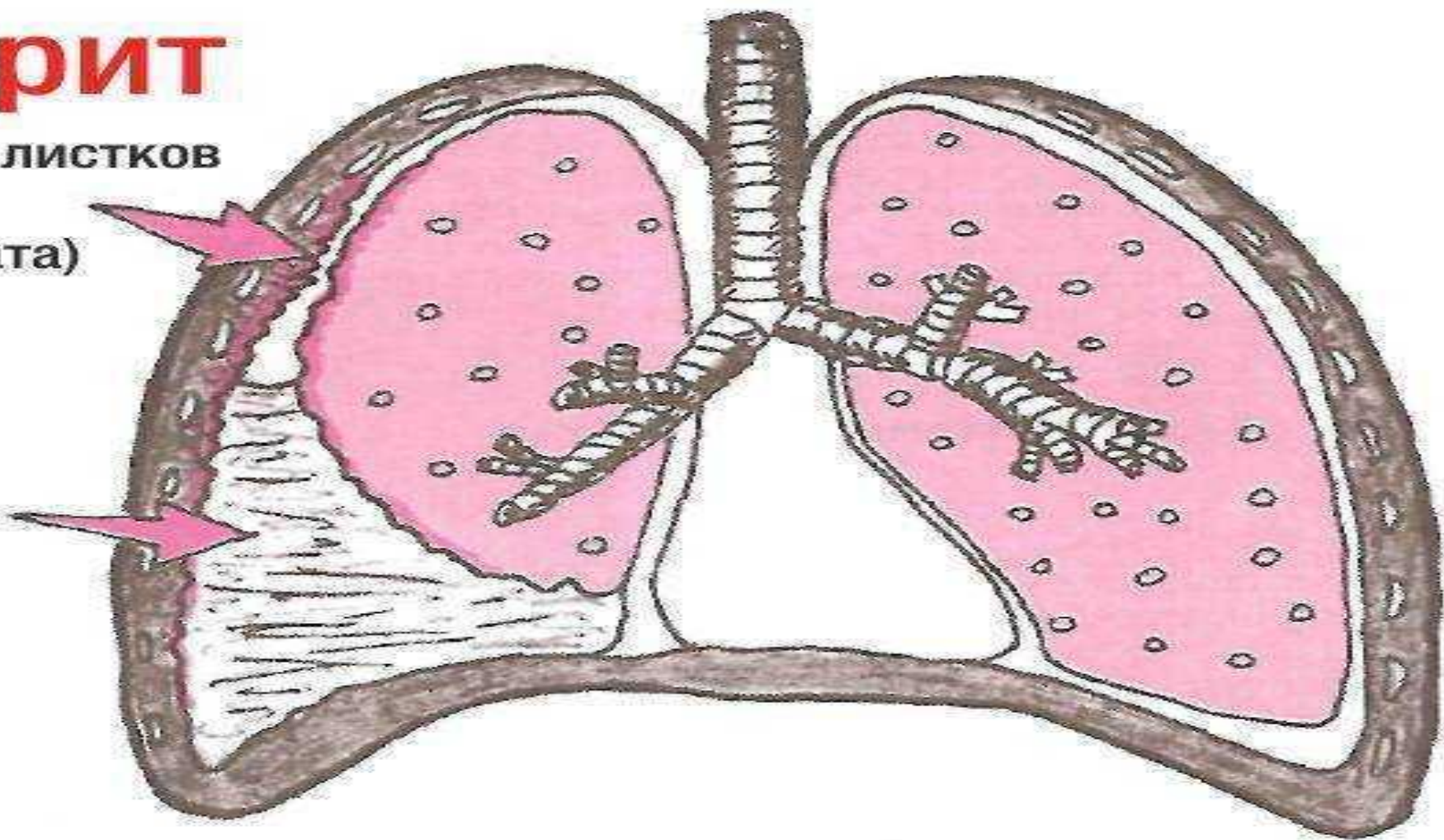


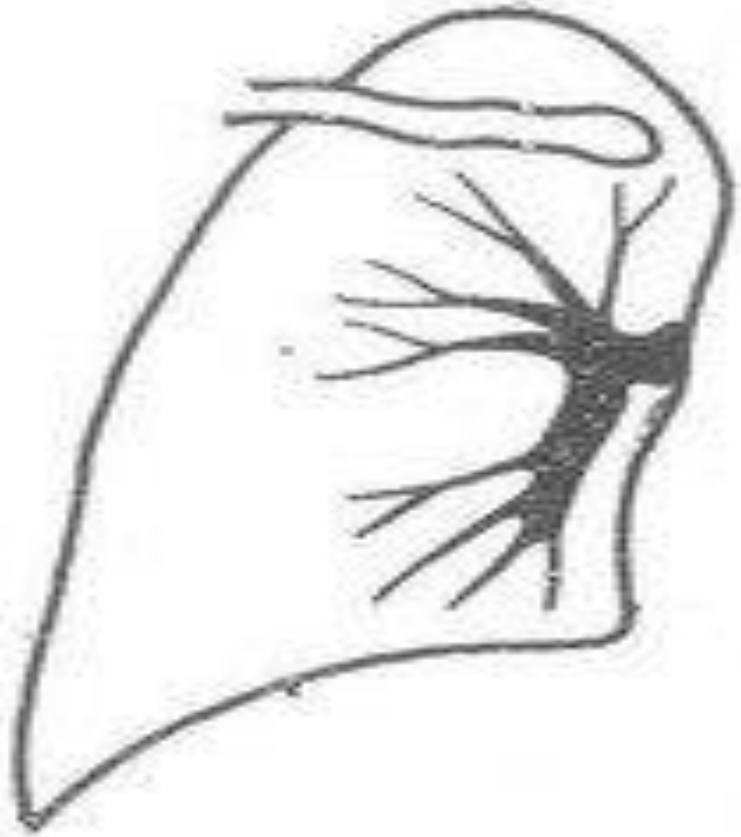


Плеврит

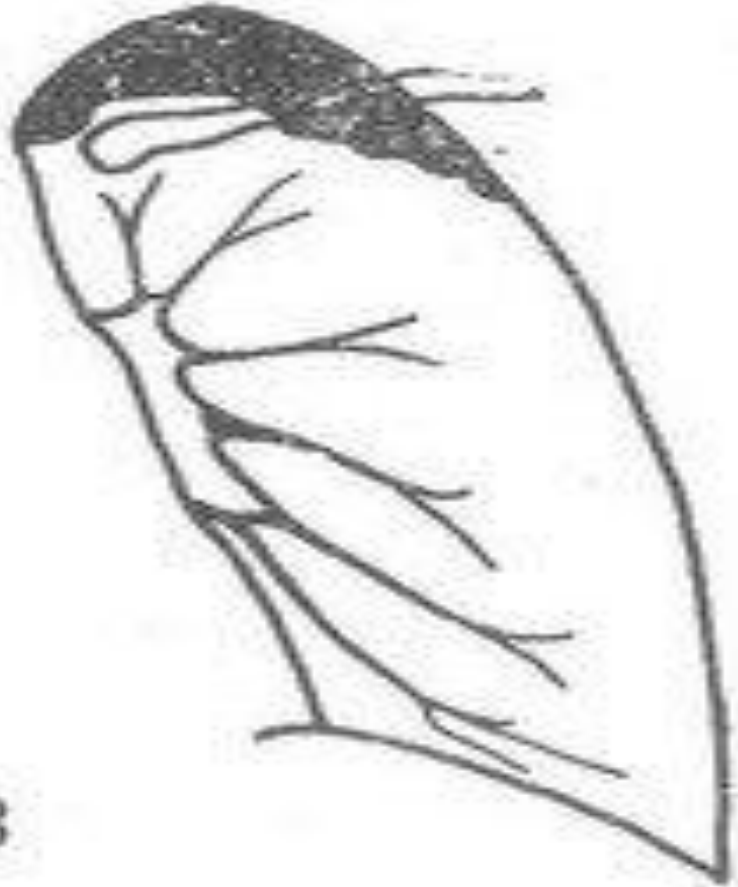Воспаление листков
плевры
(без экссудата)

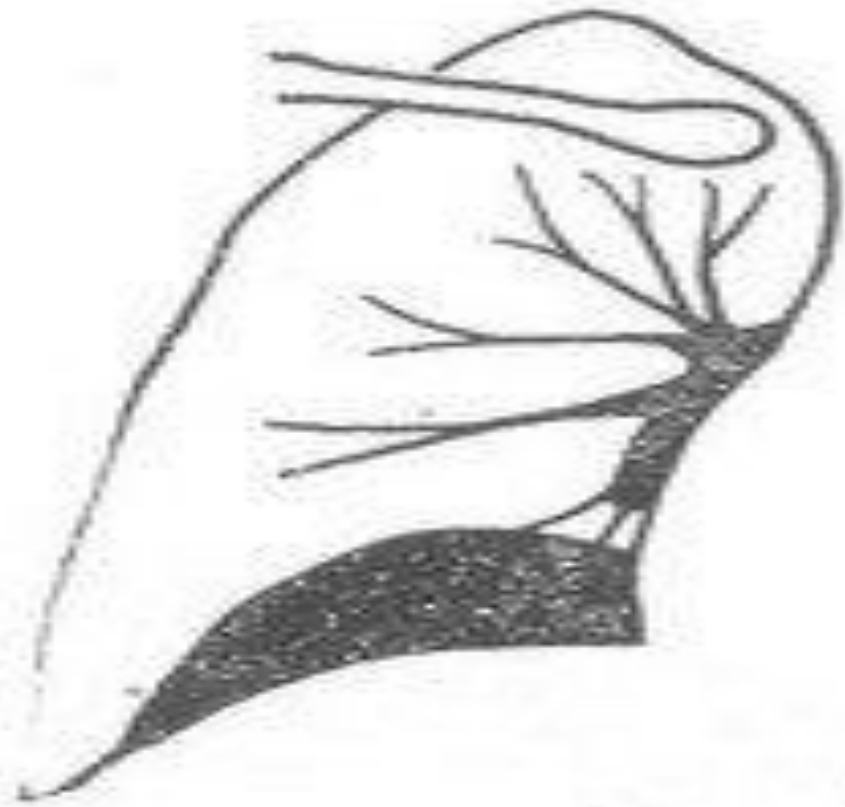Экссудат



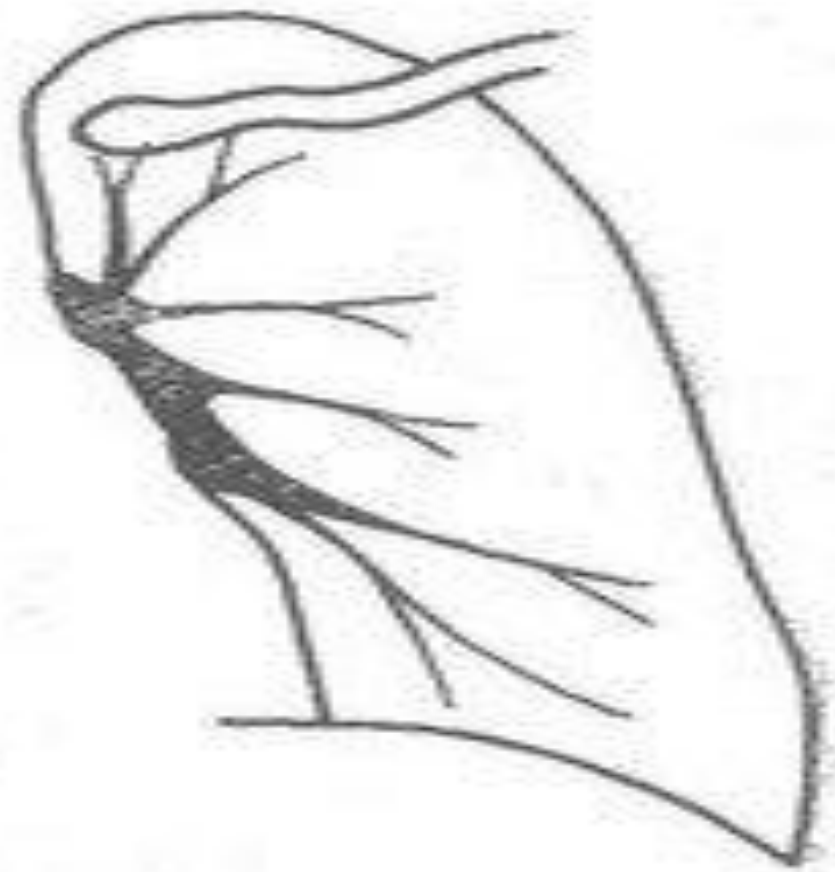


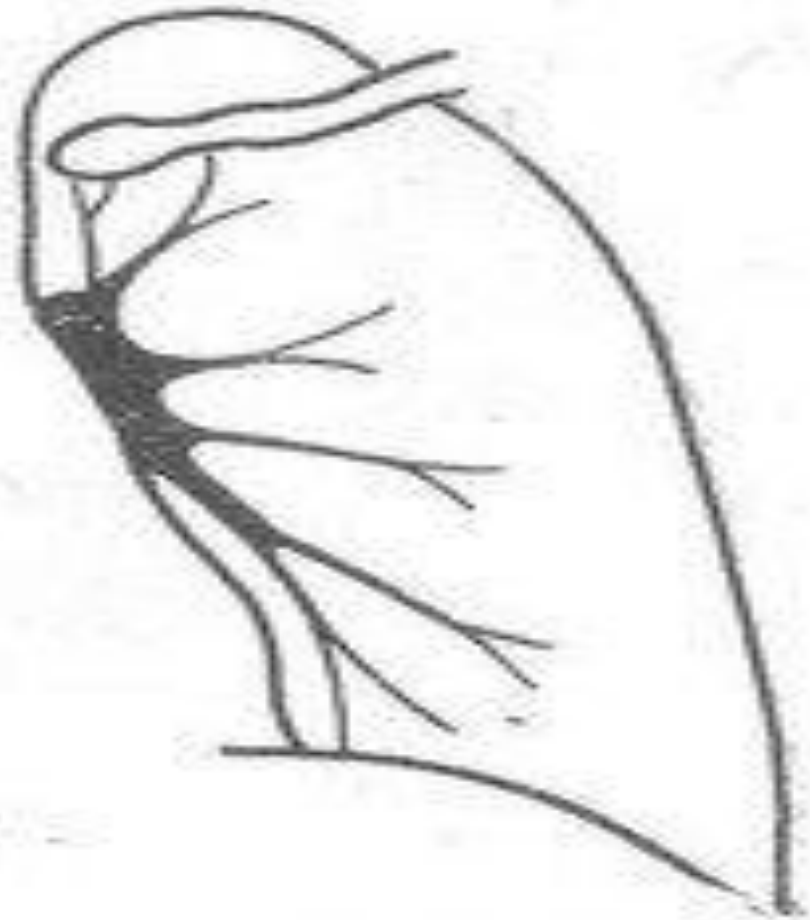
3





4



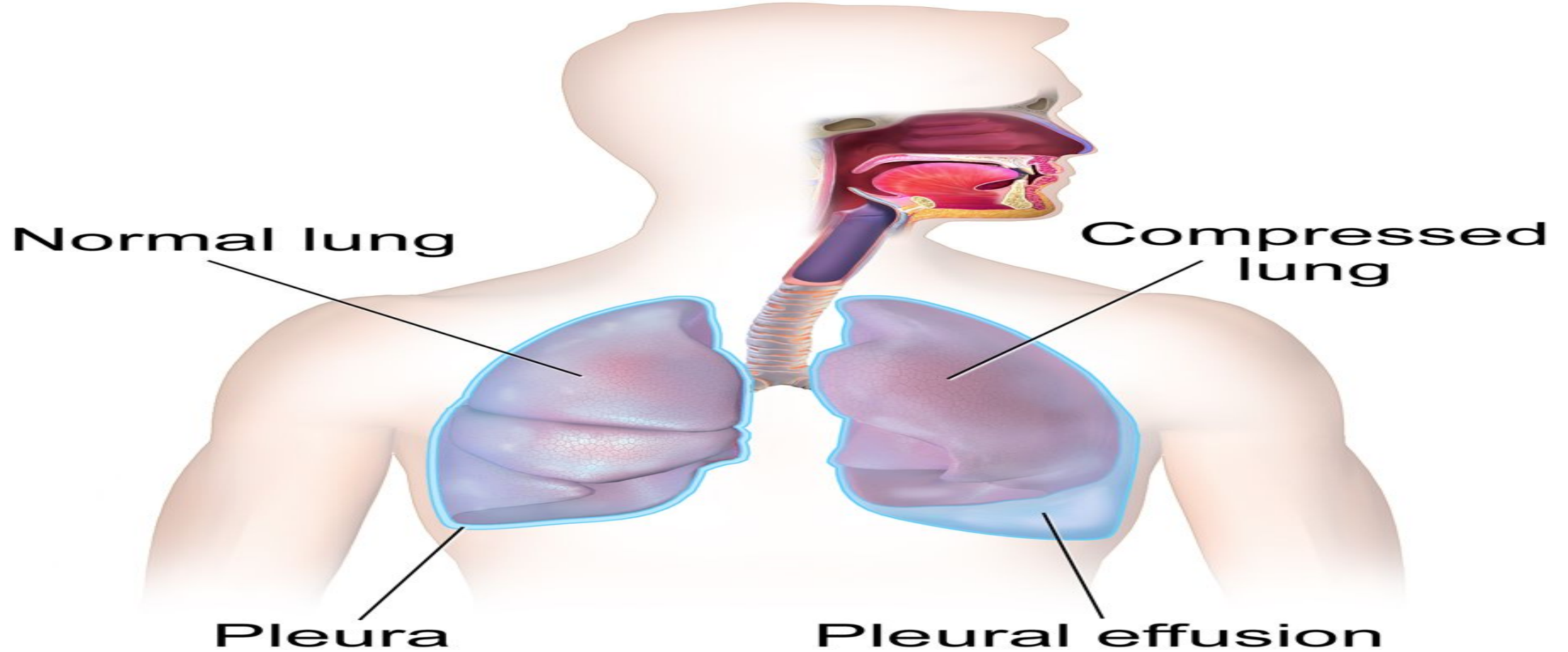


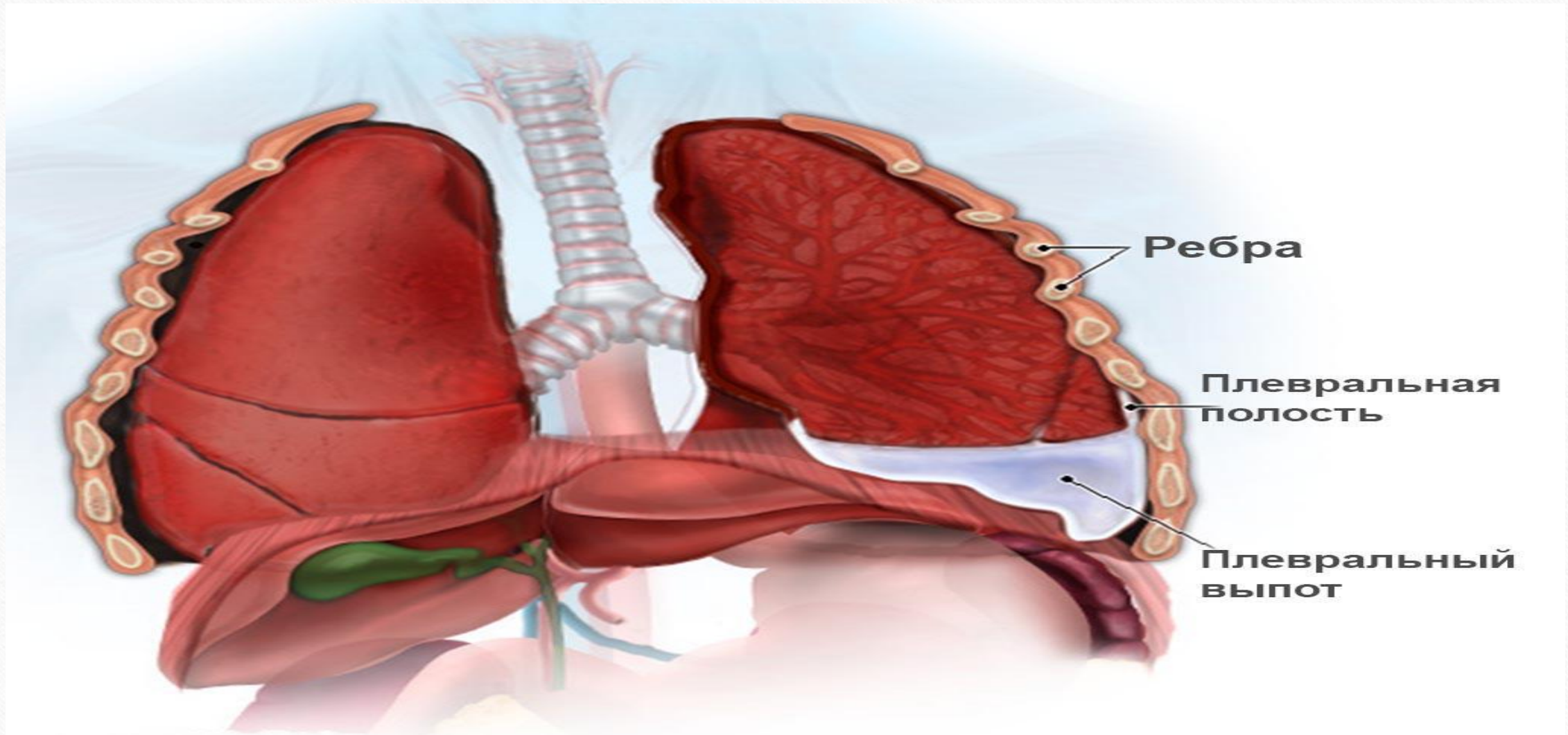
5

Obyektiv ko'rik:

- Perkussiya
- Auskultatsiya

Pleural Effusion

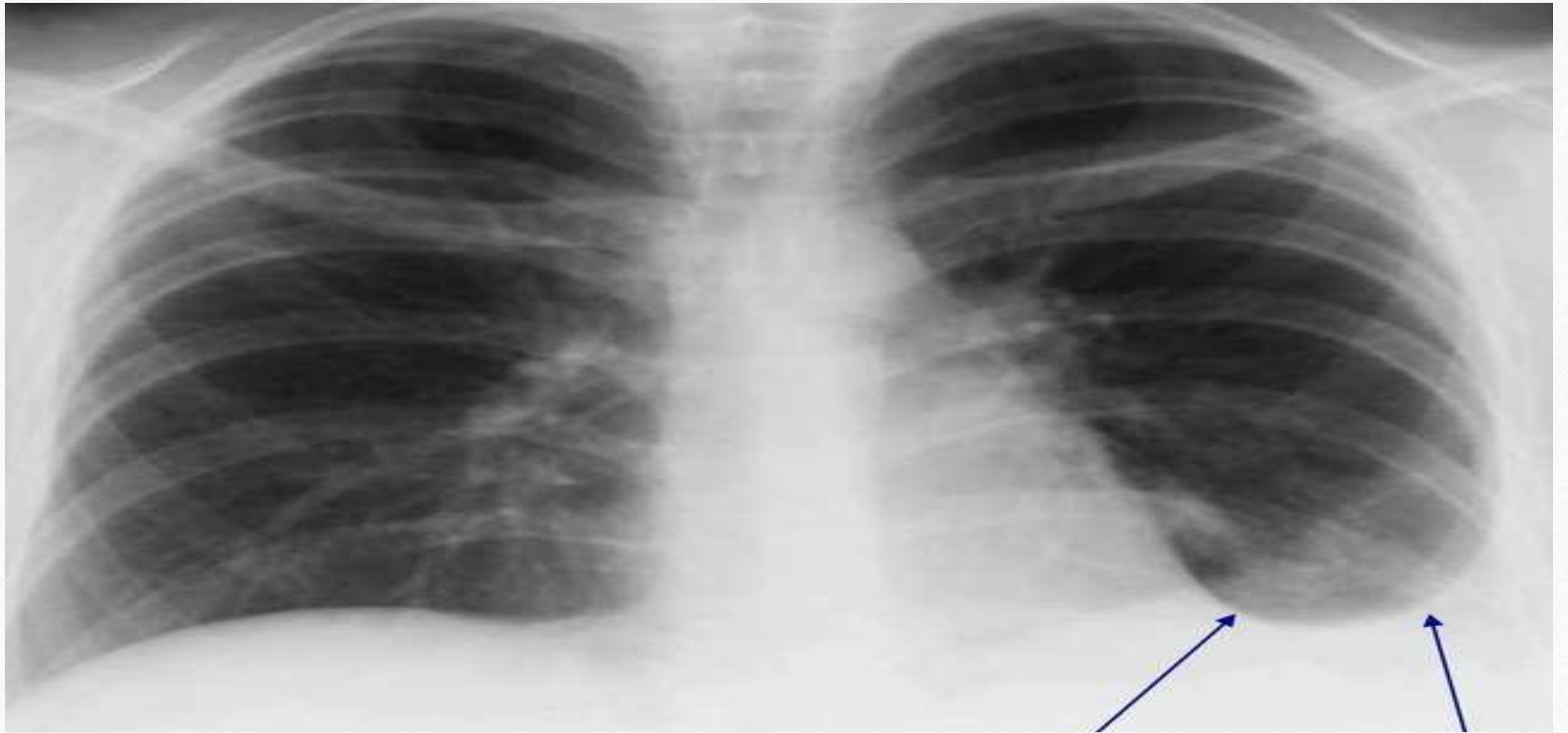

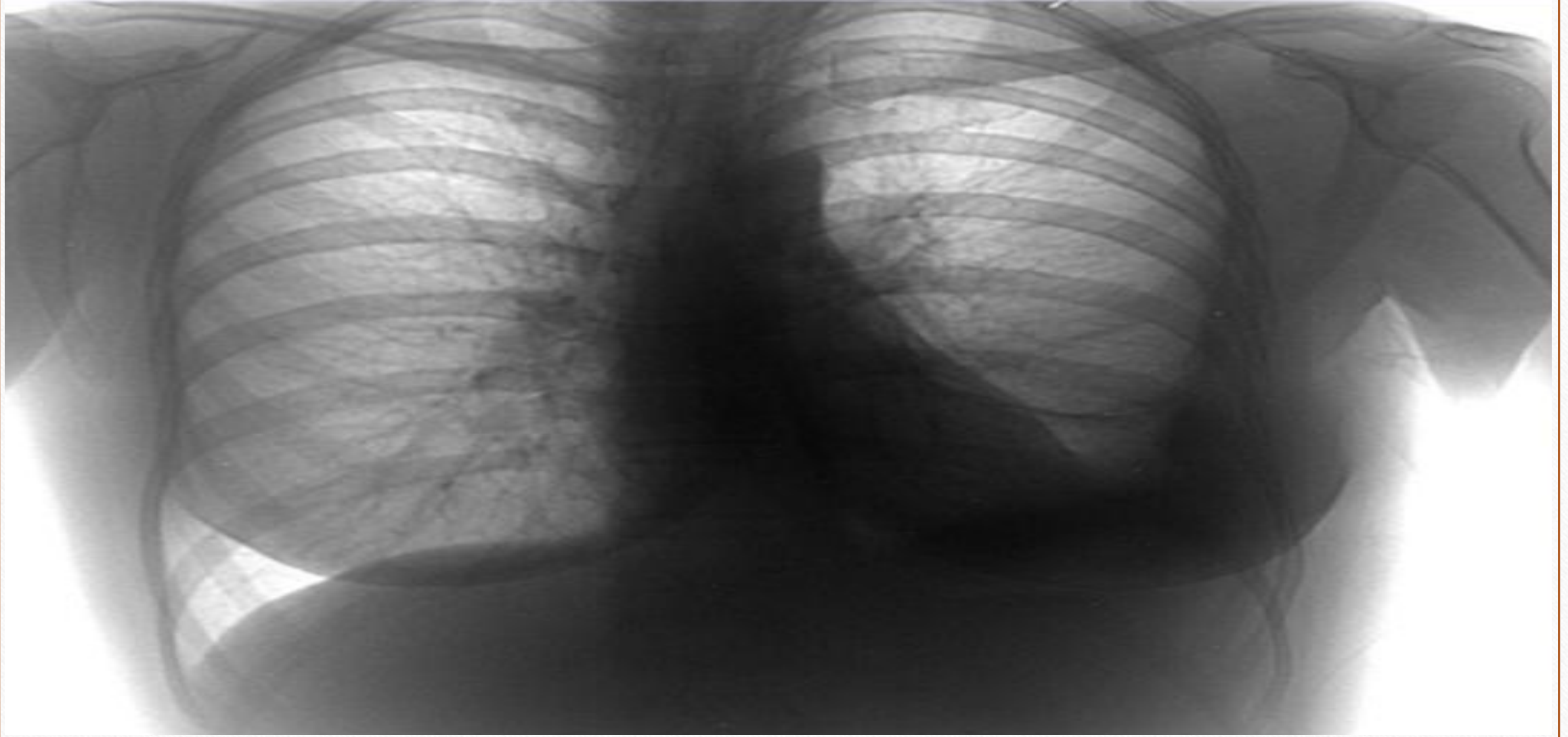


Ребра

Плевральная
полость

Плевральный
выпот





Chap tomonlama ekssudatli plevritda perkussiya va auskultatsiya ma'lumotlari va ekssudat joylashishi. 1) ekssudat; 2) Ellis-Damuazo-Sokolov chizig'i; 3) Garlend uchburchagi; 4) Grokko-Rauxfus uchburchagi.

