

# Туберкулез верхних дыхательных путей

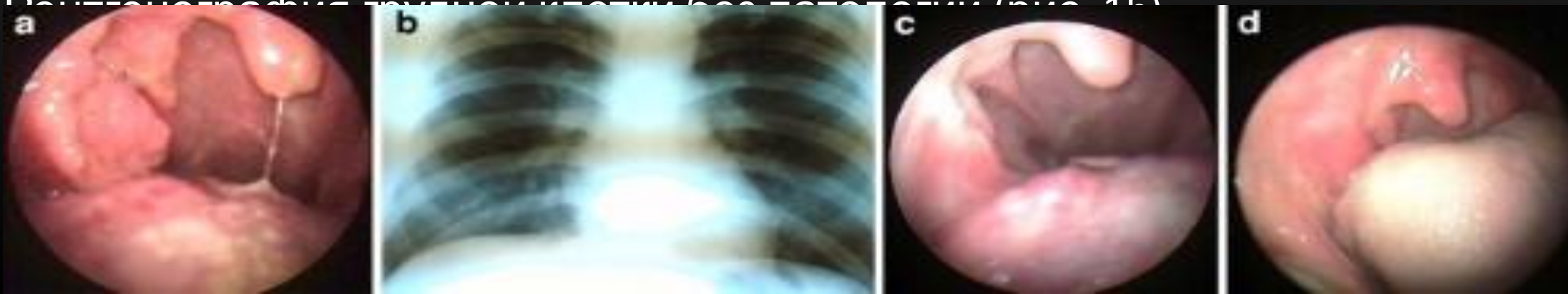
- Туберкулез верхних дыхательных путей как самостоятельное заболевание диагностируют очень редко.
- Наиболее часто эта форма является осложнением туберкулеза паратрахеальных, трахеобронхиальных или бронхопульмональных лимфатических узлов и легочного туберкулеза.
- Специфический процесс в бронхах и трахее может встречаться при любой форме туберкулеза легких и во всех фазах его течения

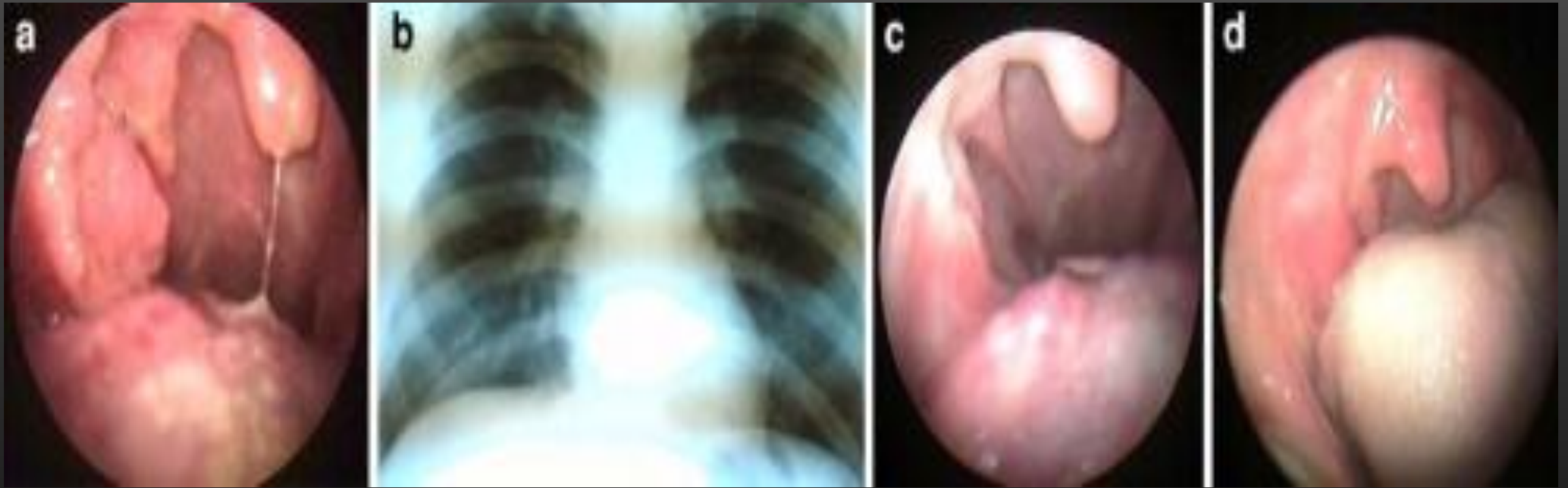
# Case report I

- A 48 year-old male presented with history of sore throat, occasional fever, malaise for 1 year duration. He had been taking treatment in form of various courses of antibiotics, analgesics, antihistamines since then without any relief. He had no previous history of any serious illness, chronic cough and other chest symptoms.
- While the general physical examination revealed normal findings, oral examination showed enlarged right tonsil which was granular and ulcerated. (Fig. [1a](#)). It was firm on palpitation and did not bleed on touch. There were no palpable neck nodes. Routine hematological evaluation revealed a raised erythrocyte sedimentation rate (ESR) of 40 mm in first hour. Chest radiography was normal (Fig. [1b](#)).

# Случай 1

- 48-летний мужчина с историей боли в горле, прерывная лихорадка, недомогание на протяжении 1 года. Он принимал различных антибиотиков, анальгетиков, антигистаминных препаратов с тех пор без каких-либо помощи.
- У него не было каких-либо серьезных заболеваний, хронический кашель и другие легочные симптомы.
- На осмотре обнаружено язва и зернистость правой миндалины. Плотная без кровотечения. (Рис. 1а). Лимф. Узлов не увеличены. СОЭ высокая.
- Рентгенография грудной клетки без патологии (рис. 1б)





a Granular tonsils, b chest X-ray (PA view) showing no abnormality, c after 1 month of ATT, d. after 6 month of ATT

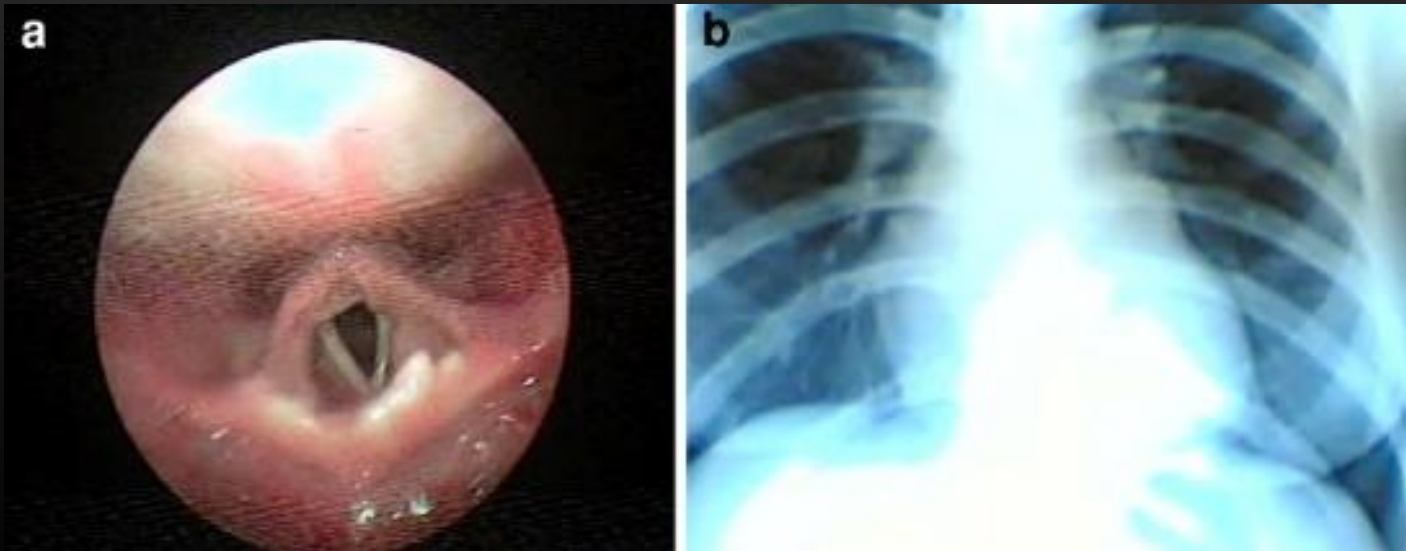
- Biopsy was taken from ulcerated area of right tonsils and sent for histopathological examination. Histology revealed granulomatous dense sub-mucosal lymphoid infiltrate with multiple epithelioid histiocyte granulomas, including multinucleate giant cells and caseous necrosis consistent with the diagnosis of tuberculosis. Serological tests for acquired immunodeficiency syndrome (AIDS) and syphilis were negative.
- Patient was managed with anti-tubercular treatment, with Rifampicin 450 mg, ethambutol 800 mg, isoniazid 300 mg and pyrazinamide 1,500 mg for 2 months and then a 4 month continuation phase of rifampicin 450 mg and isoniazid 300 mg. The patient had a good symptomatic response within the first month of treatment (Fig. [1c](#)) with total disappearance of ulcers and granular areas after completion of treatment (Fig. [1d](#)). On 1 year follow-up, he is free of disease.

# Case report II

- A 22 year old female presented with a history of odynophagia, haemoptysis, occasional fever and general malaise for 6 months. No history of cough, previous chest infection or any other significant past illness was given. Various empirical treatments consisting of antibiotics, antihistaminics, analgesics etc. were tried at peripheral institutes but not to her satisfaction.
- On general physical examination, the patient was thin built and mildly anaemic. There was no lymphadenopathy. Laboratory investigations revealed Hb-8g% and ESR 50 mm in first hour, with rest of the parameters being within normal limit. Chest X-ray shows no abnormality (Fig. [2b](#)).

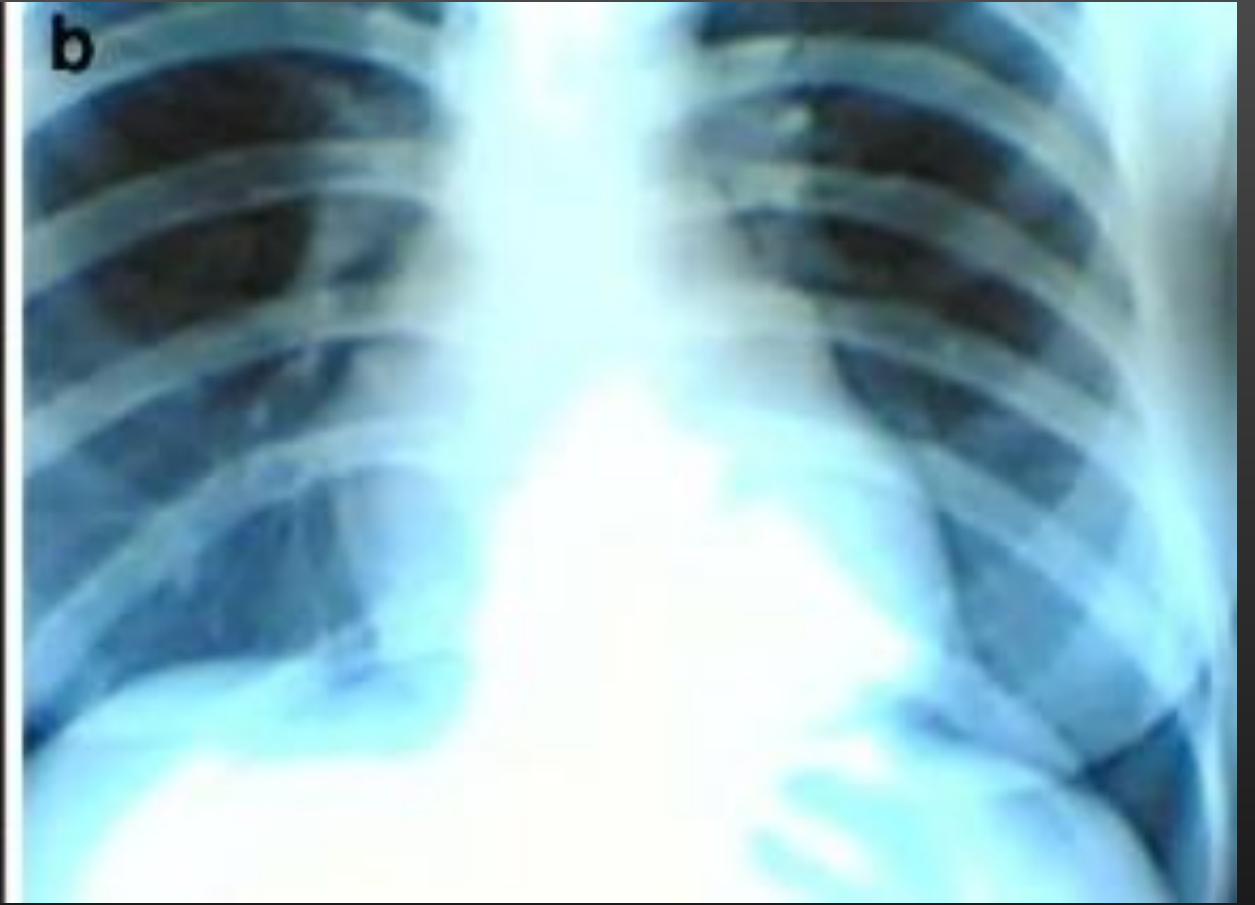
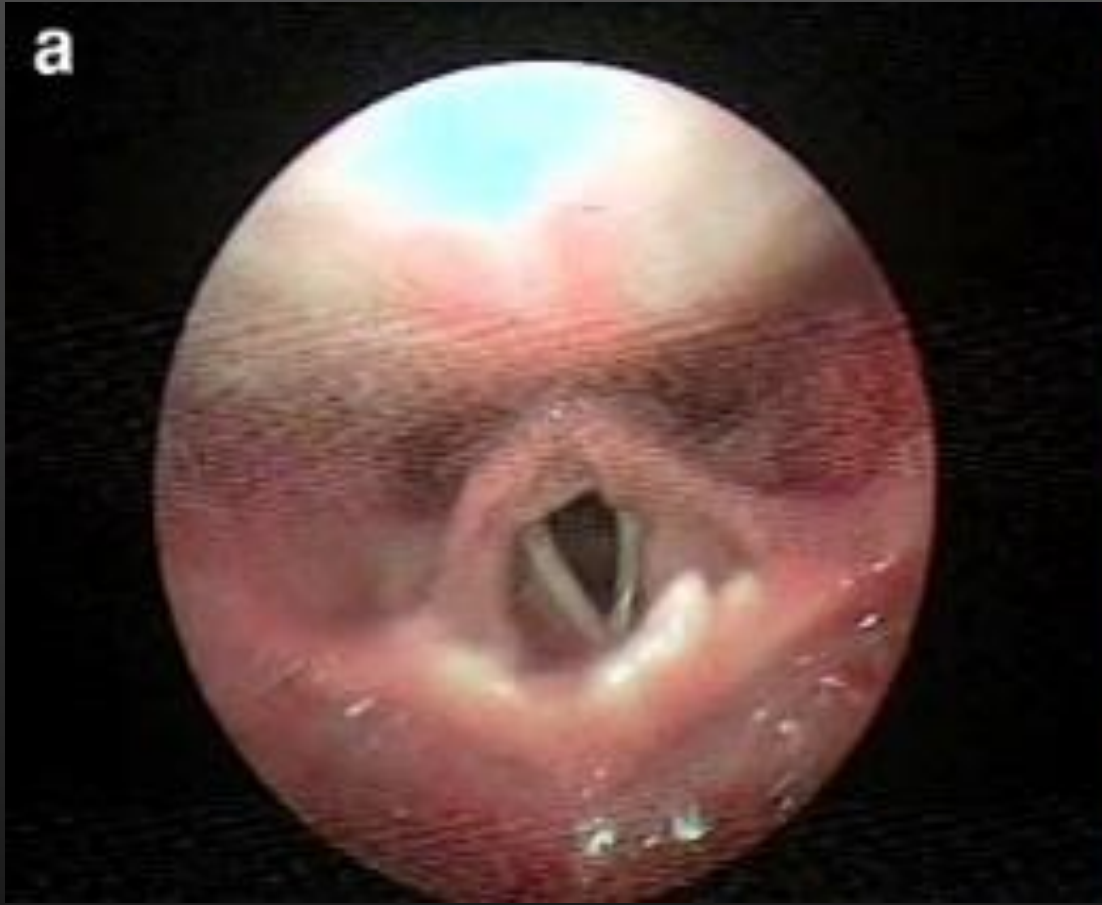
- Local examinations revealed congested and granular posterior pharyngeal wall. Indirect laryngoscopy revealed a moth eaten epiglottis with rest of the region congested. A telescopic laryngoscopy was done (Fig. [2a](#)). Biopsy was taken from the remnant of the epiglottis and sent for histopathological examination which revealed it to be an inflammatory mass of tissue with large infiltrations of histiocytes and lymphocytes and containing epithelioid granulomas, a feature suggestive of granulomatous lesion (kochs).



**a** Moth eaten appearance of Epiglottis, **b** X-ray (PA view) showing no abnormality



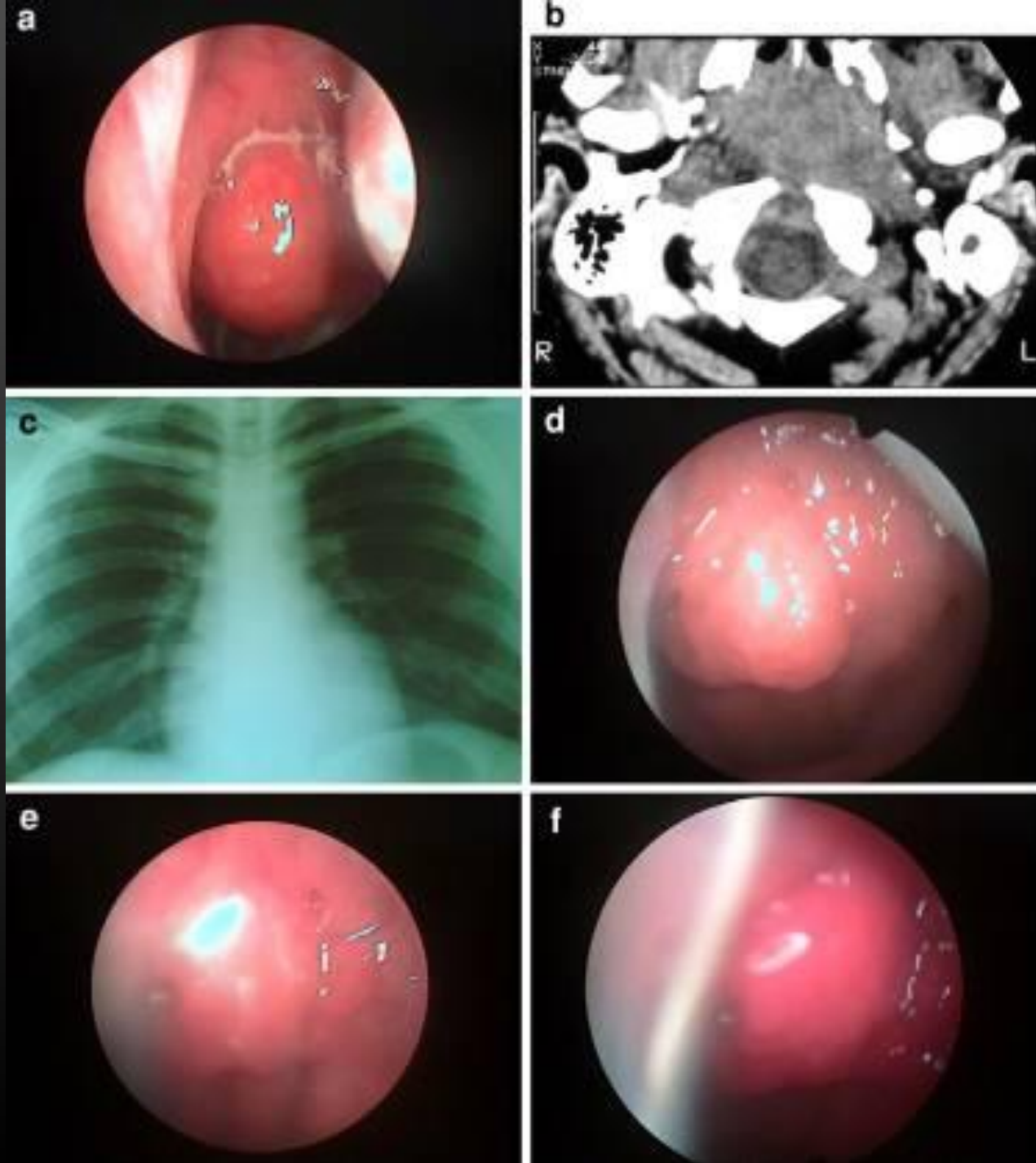


**a** Moth eaten appearance of Epiglottitis, **b** X-ray (PA view) showing no abnormality

# Case report III

- A 24 year old male student presented in the OPD with history of nasal block for the past 6 month. He has no other difficulties. He had consulted a number of times previously, and was treated as allergic rhinitis with steroid sprays, anti histamines, antibiotics, analgesics etc., however with no improvement.
- On examinations, he was found to have no gross abnormalities within the nasal cavities. Routine investigations revealed an abnormally high ESR of 86, with rest of the parameters within normal limit. Nasal endoscopy revealed a smooth mass in the nasopharynx (Fig. [3a](#)). A ct scan of the nose and PNS was asked for, whereby a report of a mass in nasopharynx with no extensions was given. The mass was not vascular. (Fig. [3b](#)). Punch biopsy was taken from the lesion and sent for HPE. histopathological diagnosis was given to be granulomatous lesion, probably tubercular. A repeat biopsy was done and chest x-ray was also done. Chest x-ray came to be normal. (Fig. [3c](#)). Repeat HPE report came as *“fragments of tissue lined with squamous and respiratory epithelium. The subepithelial tissue shows lymphoid tissue with many epithelioid cell granuloma. Some of the granulomas are confluent. Some show central necrosis. Stain for acid fast bacilli are positive. Features consistent with tuberculosis.”*

**a** smooth mass in nasopharynx,  
**b** C T features of a mass in nasopharynx,  
**c** normal chest X-ray,  
**d** mass after 1 month of ATT, **e** mass after 2 months of ATT, **f** mass after 4 months of ATT



# Case report III

- With all the above mentioned investigations, a diagnosis of primary tuberculosis of nasopharynx was reached and he was started on standard dose of ATT. (4 drugs-rifampicin 450 mg, isoniazid 300 mg, ethambutol 800 mg and pyrazinamide 1,500 mg for next 2 months followed by rifampicin 450 mg and Isoniazid 300 mg for 4 months). He showed remarkable regression of disease on follow-up at 1, 2 and 4 months. (Fig. [3d](#), e, f). At 6 months the mass completely regressed.
- The patient is under regular 6 monthly follow-up.

# Conclusion

- Commonly URT primary TB can be misdiagnosed as traumatic or aphthous ulcer, haematological disorder, other granulomatous disease, lymphoma or carcinoma. Diagnosis however must be based on high degree of clinical suspicion backed by histopathological and cytological identification of the bacilli. Hence, though uncommon, primary tuberculosis of the upper respiratory tract should be borne in mind, especially in a country like ours.

# Reference

- 1. Chakravarti A, Pal S, Sahni JK. Primary tuberculosis of tonsil and posterior oropharyngeal wall. Indian J Tuberc. 2008;55(1):48–50. [[PubMed](#)]
- 2. Usulu C, Oysu C, Ukluman B. Tuberculosis of the epiglottis, a case report. Eur Arch Otolaryngol. 2008;265(5):599–601. doi: 10.1007/s00405-007-0492-9. [[PubMed](#)] [[Cross Ref](#)]
- 3. Edizer DT, Karaman E, Mercan H, Alimoglu Y, Esen T, Cansiz H. Primary tuberculosis involving epiglottis, a rare case report. Dysphagia. 2010;25(3):258–260. doi: 10.1007/s00455-009-9256-6. [[PubMed](#)] [[Cross Ref](#)]
- 4. Savic D, Kosanovic H, Crejia D. Isolated tuberculosis of the nasopharynx. Srp Arh Celok Lek. 1961;89:99. [[PubMed](#)]
- 5. Martison FD. Primary tuberculosis of the nasopharynx in a nigerian. J Laryngol Otol. 1967;81:229–234. doi: 10.1017/S0022215100066998. [[PubMed](#)] [[Cross Ref](#)]
- 6. Graff S. Die Bedeutung des epipharynx für die menschl. Pathologie Klin Wschr. 1936;27:953. doi: 10.1007/BF01777670. [[Cross Ref](#)]
- 7. Hollander AR. The nasopharynx: a study of 140 autopsy findings. Laryngoscope. 1946;56(6):282–304. [[PubMed](#)]
-