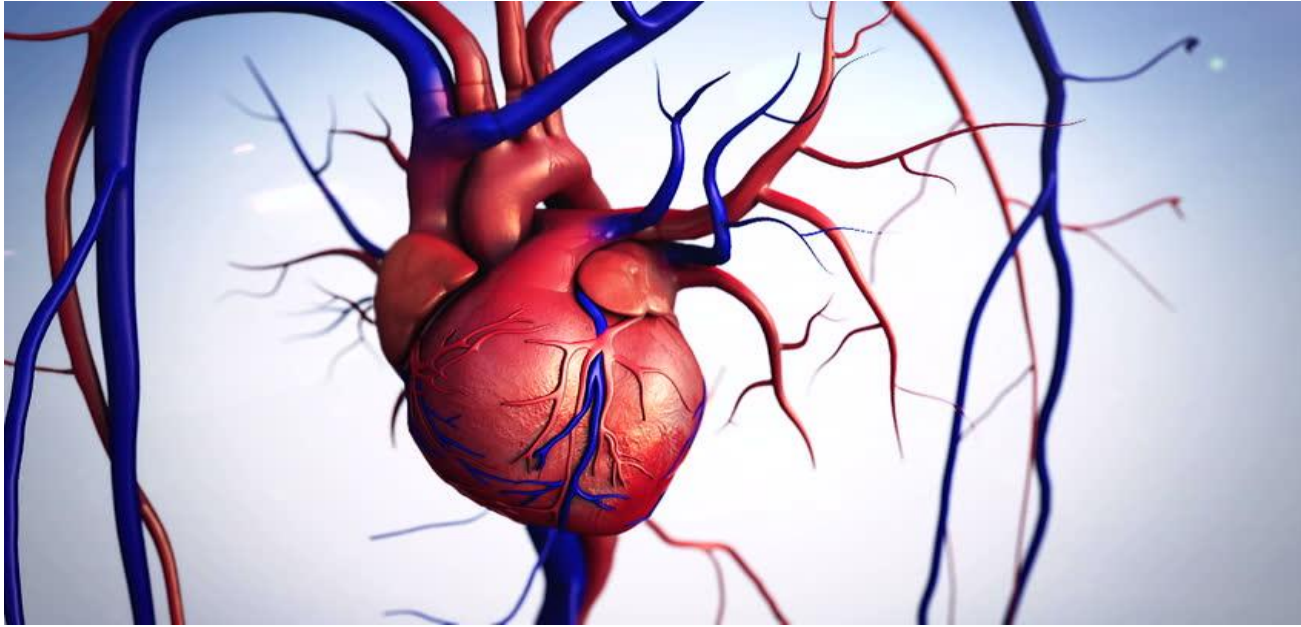


Electrical Processes of the Heart



CIE Biology Jones
pp 173-179

Extra For Students
A level notes
<https://alevelnotes.com/The-Mammalian-Heart/171>

G11 Biology 2017-2018

Learning Objective:

1. Explain the mechanism of cardiac automaticity.
2. Use and electrocardiogram to describe the cardiac cycle.

Success Criteria

1. Investigate the electrical process of in the heart .
2. Describe the structure of the heart and indicate the link between the structure of the heart muscles and its ability to automaticity.
3. Explain the mechanism of heart automaticity.
4. Explain the essence of **E**lectro**C**ardio**G**raphy (ECG)

Mrs Cooper – 4 videos
<https://www.youtube.com/watch?v=X9B6dfzlvBQ>

Terminology 1 – Cardiac Mechanism

English	Google Russian 😊
Functional syncytium	Функциональный синцитий
Automaticity	автоматизм
Myogenic action	Миогенное действие
Contraction	стягивание
Cardiac fibers	Сердечные волокна
Atria, atrium	Аtria, атриум
Ventricles	Желудочки
Aorta	аорта
Pulmonary vein	Легочная артерия
Pulmonary artery	Легочная артерия
Vena cava	Вена-кава
Voluntary – involuntary	Добровольное - непроизвольное
mononucleated – multinucleated	моноклеарный - многоядерный
Striated – non-striated (lines-stripes)	Полосатые - нестрисированные (линии-полоски)
Branched-non-branched-tapered (shape)	Разветвленная-неветвянная-коническая
Intercalated disks	(форма)
https://quizlet.com/173937887/chapter-7-cardiac-cycle-conduction-system-of-the-heart-flash-cards/	Интеркалированные диски

Single Circulation
2 chambers

2 chambers

Fish

1-atrium

1-ventricle

3 chambers

Amphibian/reptile

2-atrium

1-ventricle

Oxygenated and
deoxygenated blood is mixed

4 chambers

Mammalian

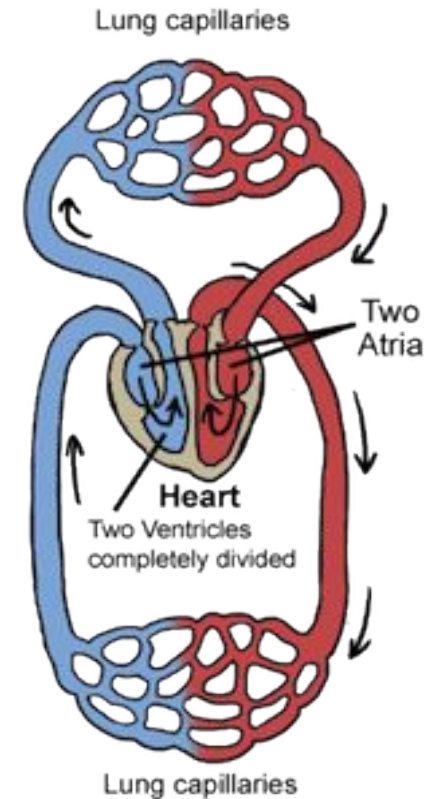
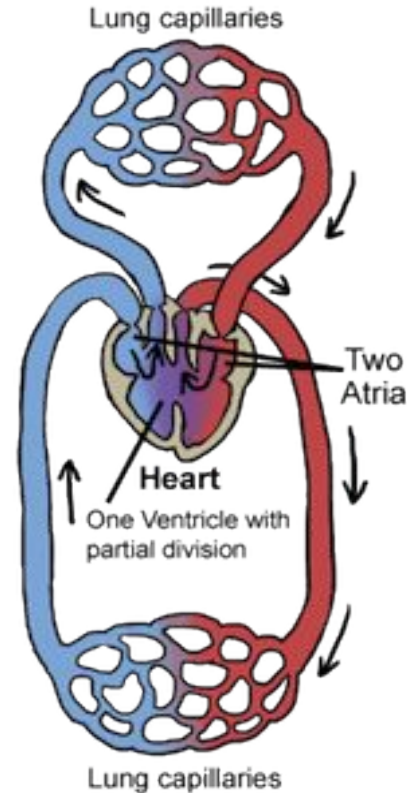
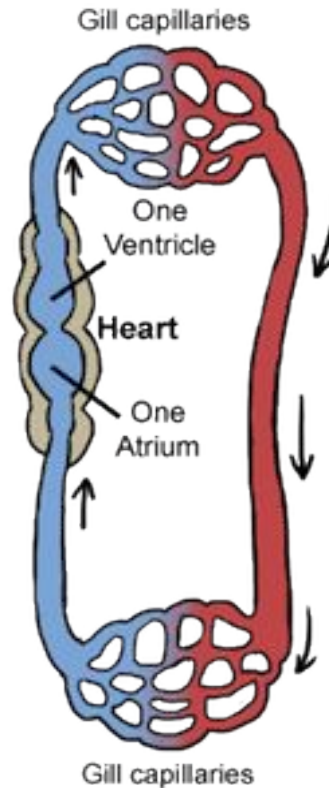
2-atria

2-ventricles

Separate ventricles keep
oxygenated and deoxygenated
blood from mixing

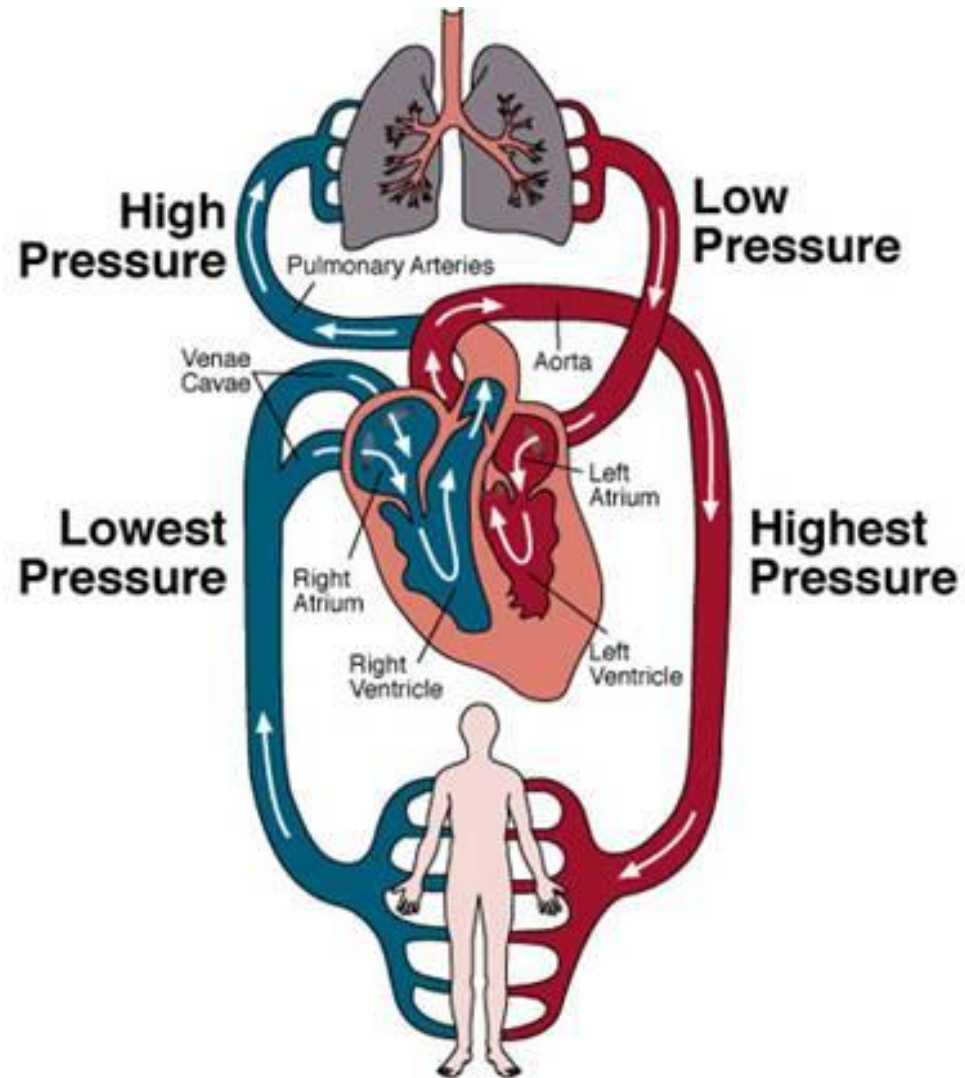
Double Circulation
3 chambers

Double Circulation
4 chambers



Blood travels through the heart **twice** before returning to the body

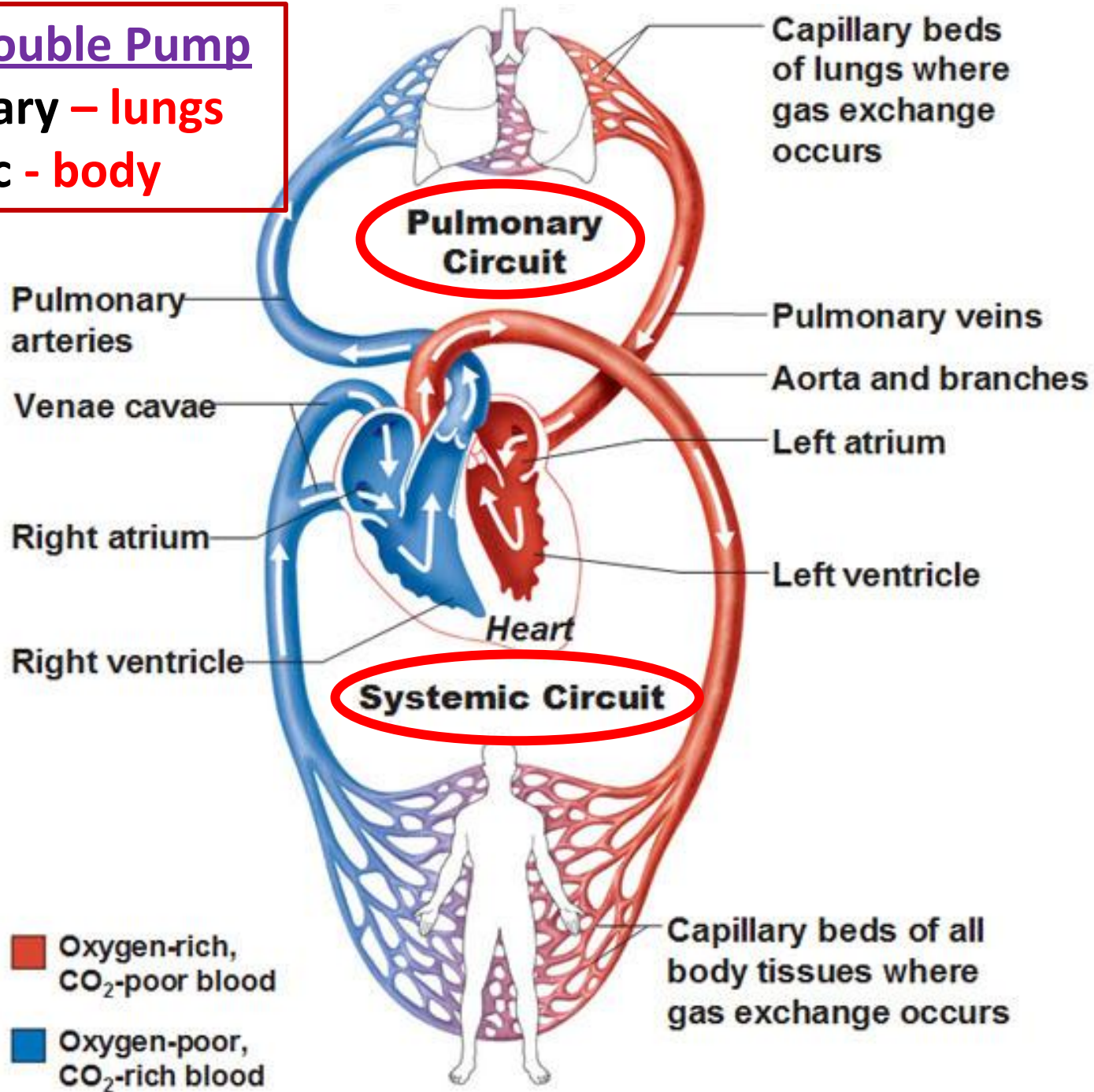
Double Circulatory System



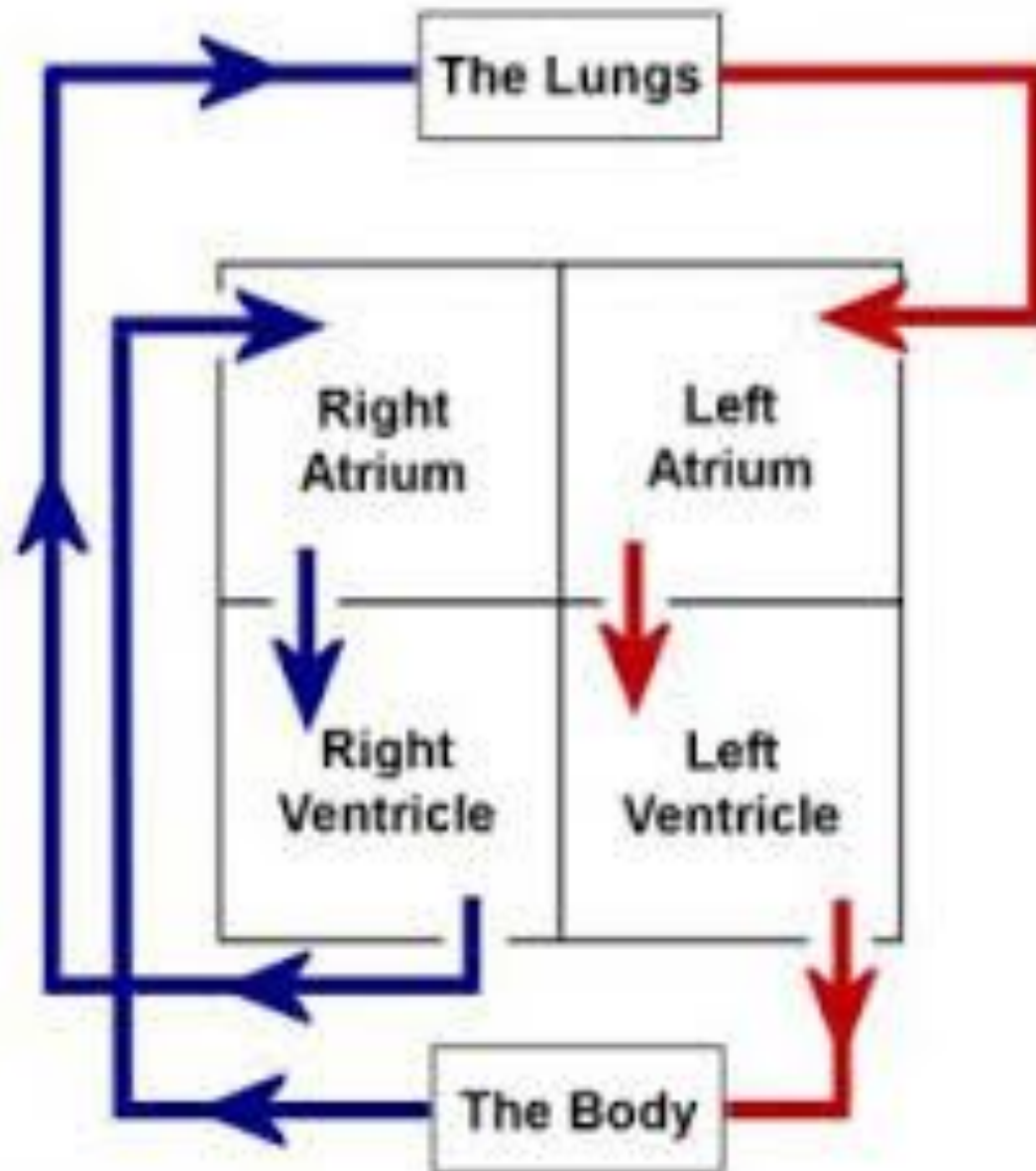
Heart Double Pump

Pulmonary – lungs

Systemic - body



-Short video fragment beating isolated rat heart:
<http://www.youtube.com/watch?v=CzIMSr-8Ko0>



Three Types of Muscle Tissue

Draw and Label

Skeletal



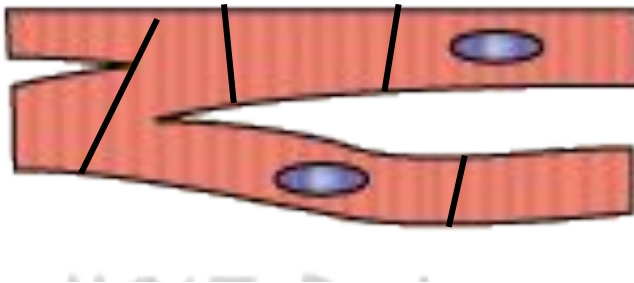
Voluntary

Striated

Multinucleated

Non-branched

Cardiac



Involuntary

Striated

Intercalated disks

Mononucleated

Branched

Smooth

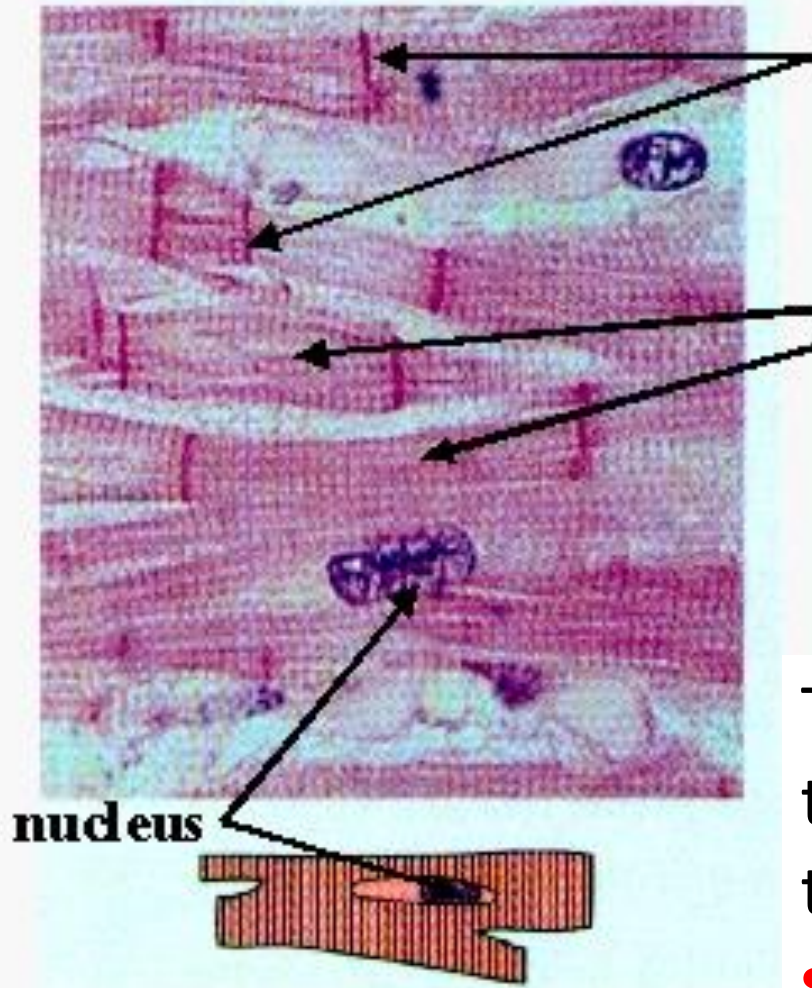


Involuntary

Non-striated

Mononucleated Tapered

Cardiac Muscle Structure



Intercalated disks are anchoring structures containing gap junctions.

Faintly striated, branching, mononucleated disks to form a functional network.

The action potential travels through all cells connected together forming a **functional syncytium** in which cells function as a unit.



Define the following terms

- Functional syncytium – the heart consists of individual cells, the entire mass normally responds as a unit and all of the cells contract together.
- Myogenic – cardiac muscle **can contract** without nervous input. BUT the strength and the rate of contraction is modified by nervous input.
- Automaticity – the cardiac cell's ability to spontaneously generate an electrical impulse (depolarize).

The heart is **myogenic** – it contracts on its own without stimulus from the nervous system.

But, the heart **RATE** is controlled by the nervous system

Two nerves link the **cardiovascular centre** in the medulla oblongata of brain with the **SA node** of the heart

Accelerator nerve

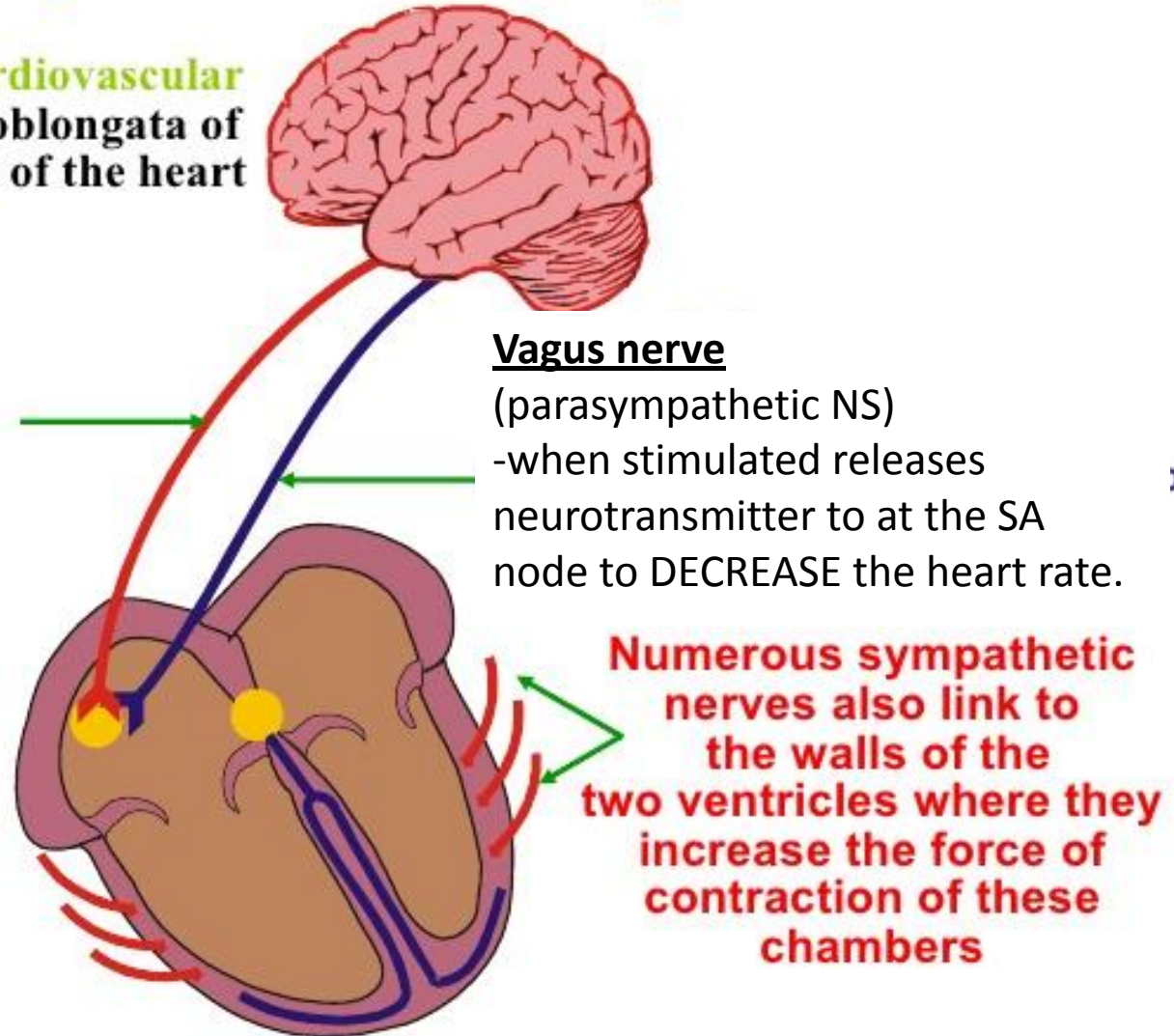
(sympathetic NS)

- When stimulated releases neurotransmitter at the SA node to increase the heart rate

Vagus nerve

(parasympathetic NS)

-when stimulated releases neurotransmitter to at the SA node to DECREASE the heart rate.



Heart Function- More definitions

Aorta-is connected to the left ventricle and carries **oxygenated** blood to all the parts of the body except the lungs.

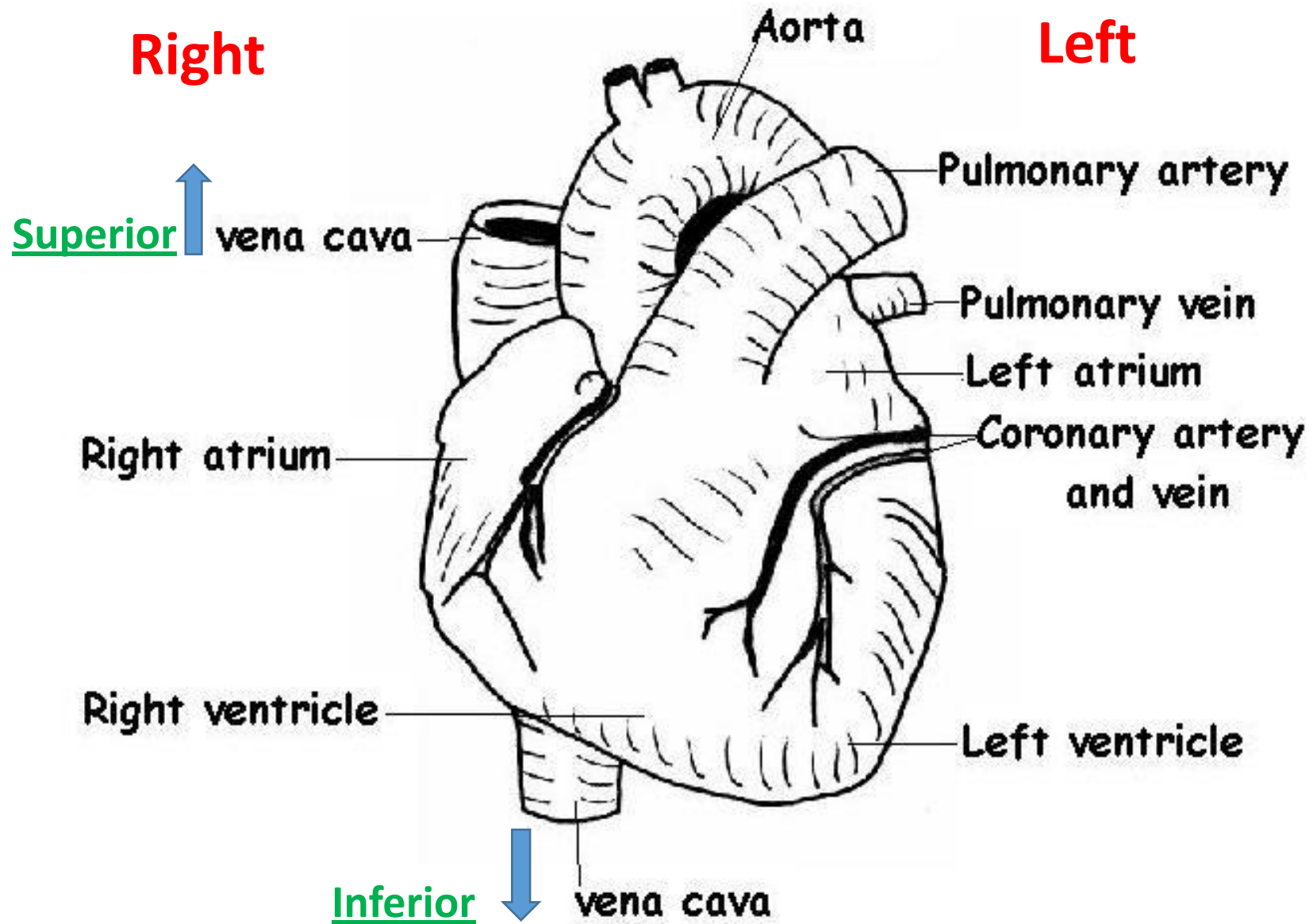
Vena cava – is connected to the right atrium and brings **deoxygenated** blood back from the tissues.

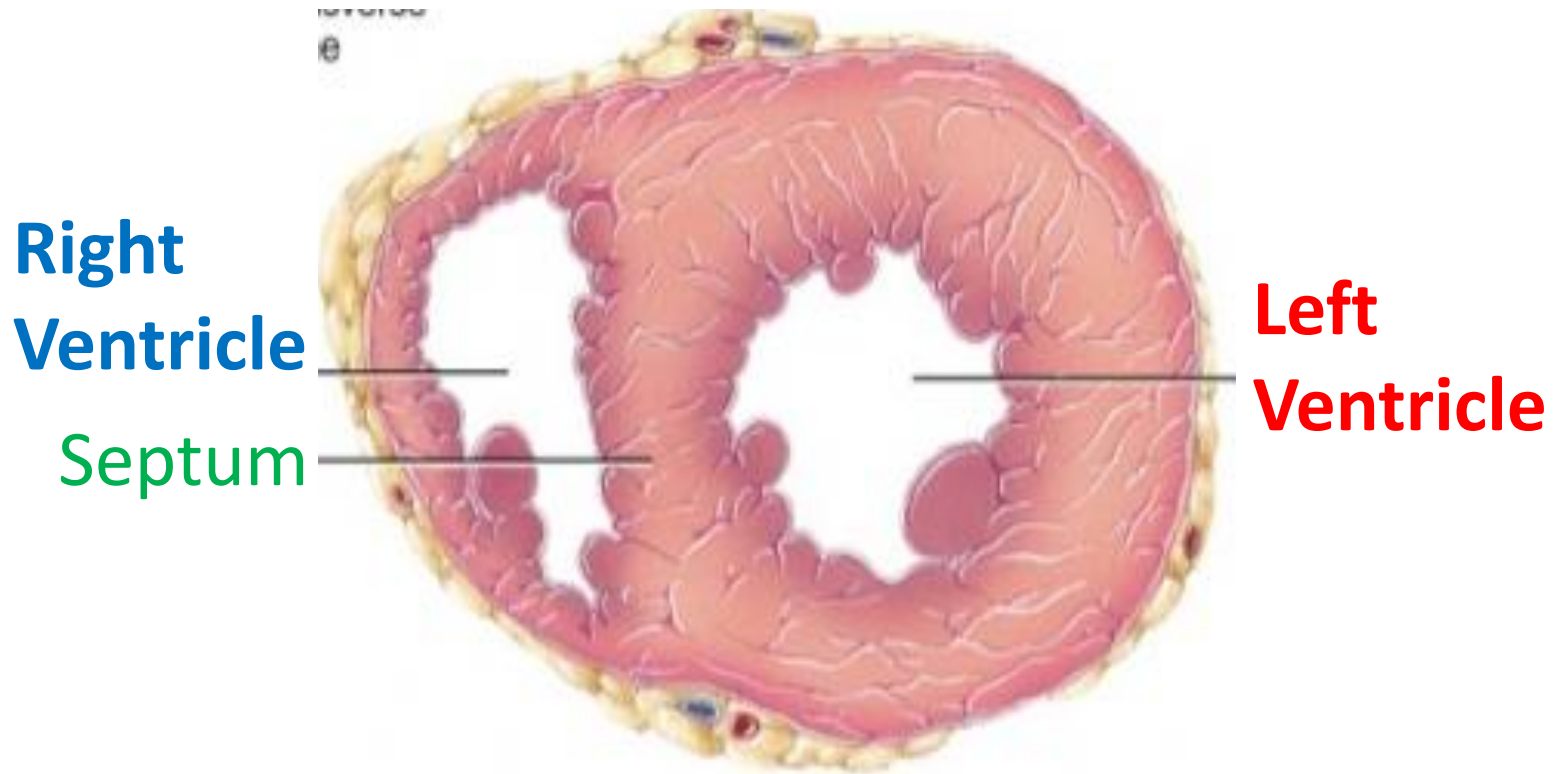
Pulmonary artery – is connected to the right ventricle and carries **deoxygenated** blood to the lungs, where oxygen is replenished and carbon dioxide is removed.

Pulmonary vein – is connected to the left atrium and brings **oxygenated** blood back from the lungs.

Label Heart - 1 min

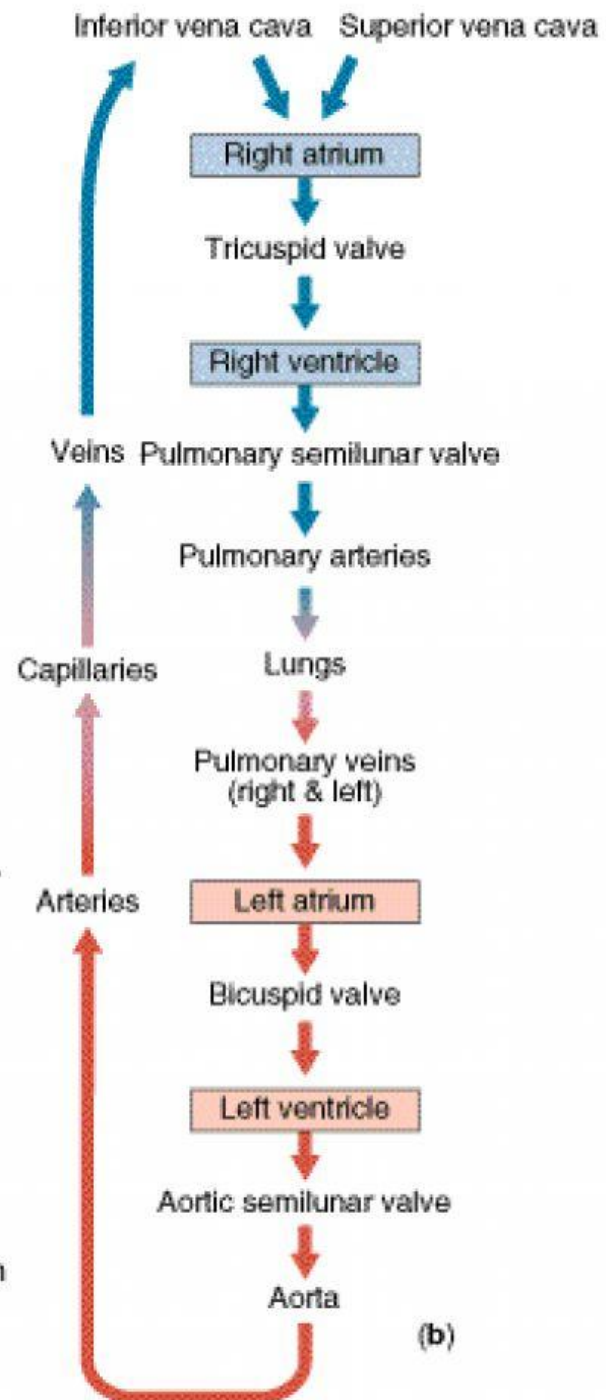
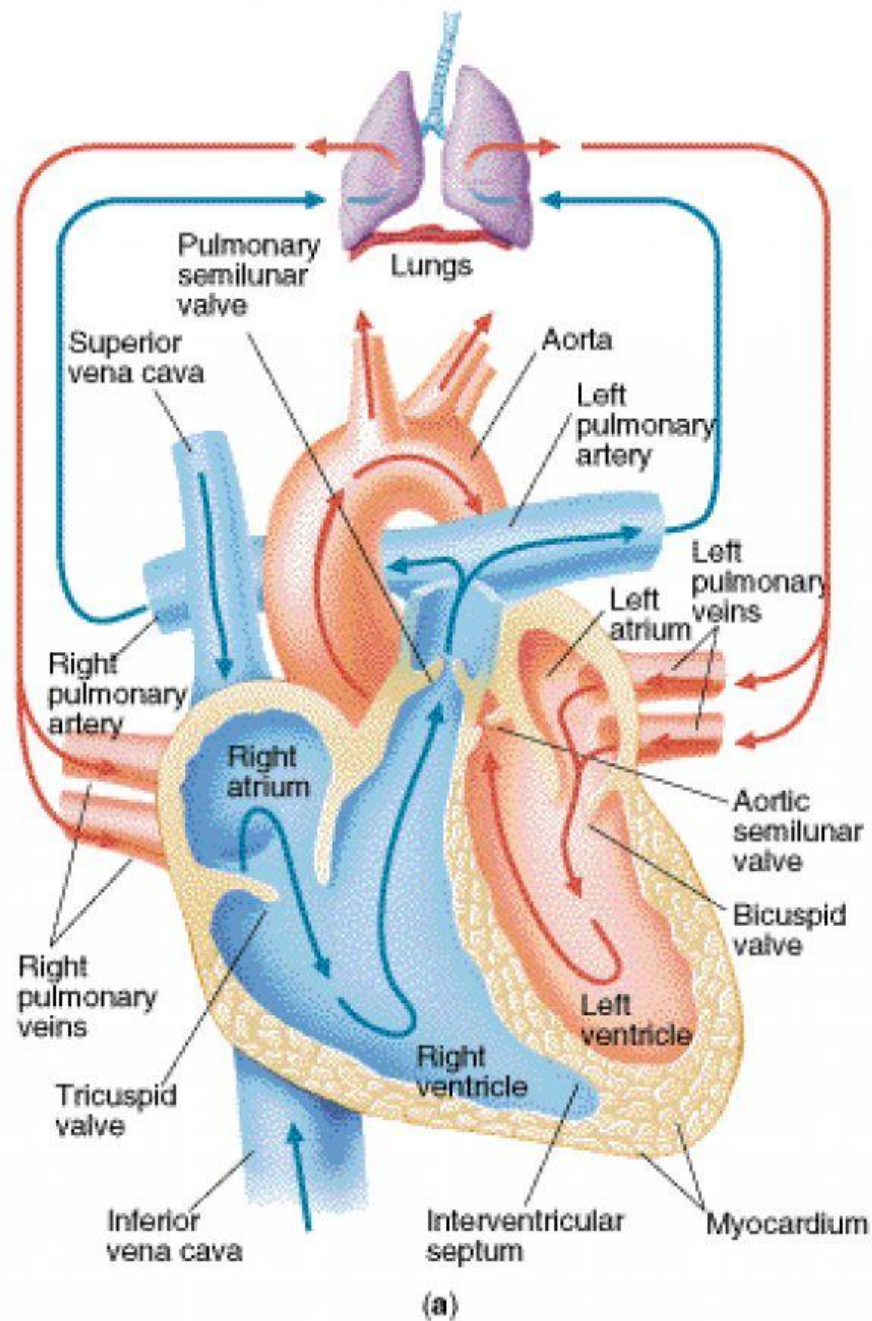
External Features-Label





Transverse section of the heart apex

-Left ventricle is thicker because it needs to pump blood all the way around the body, whereas the right ventricle only has to get blood to the lungs.



Blood flow steps

Oxygenated blood
to all the cells in the
body via aorta

Deoxygenated blood
from body to RA
through vena cava

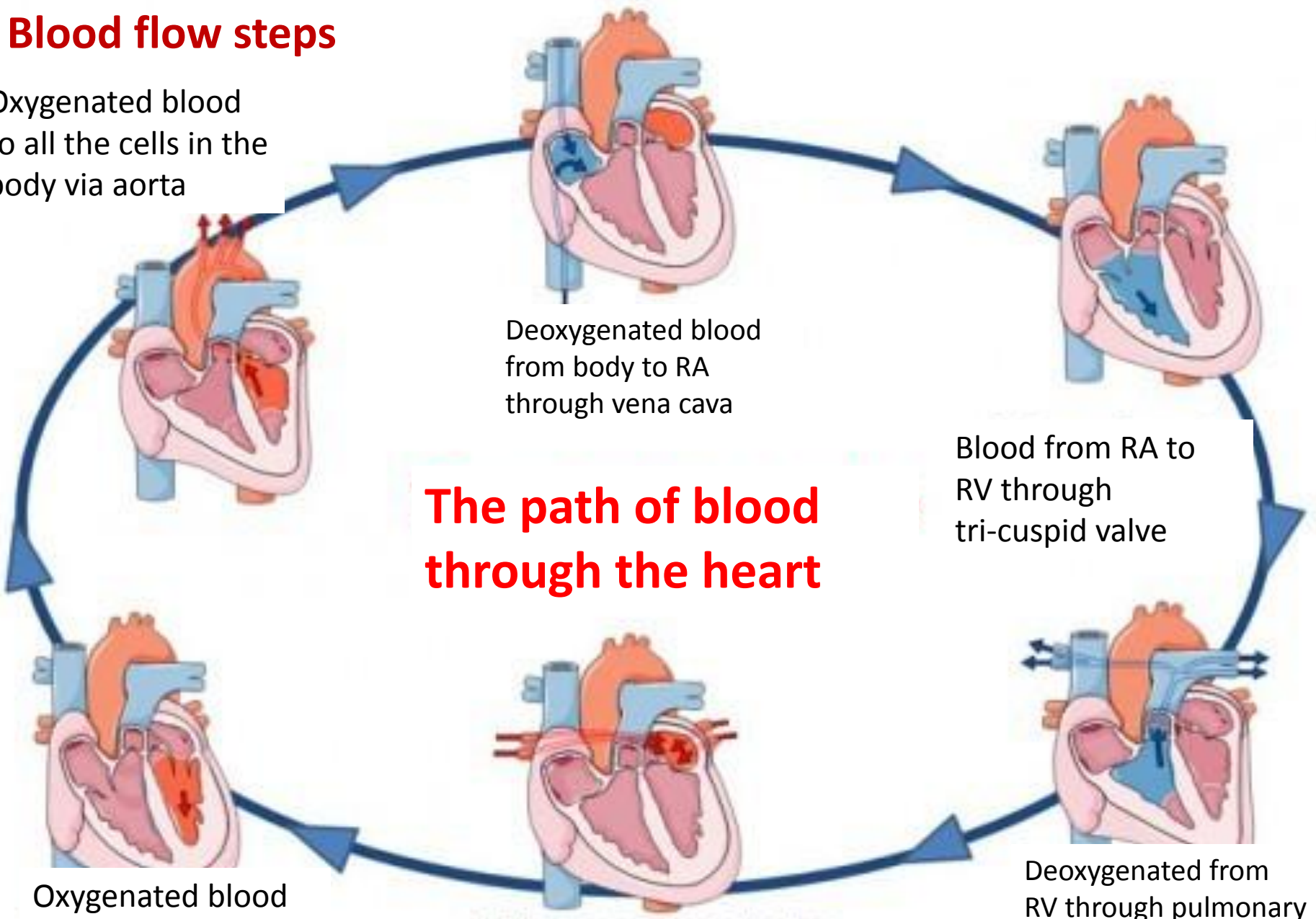
Blood from RA to
RV through
tri-cuspid valve

Deoxygenated from
RV through pulmonary
arteries to lungs to get
oxygen

Oxygenated blood returns
to LA via pulmonary veins.

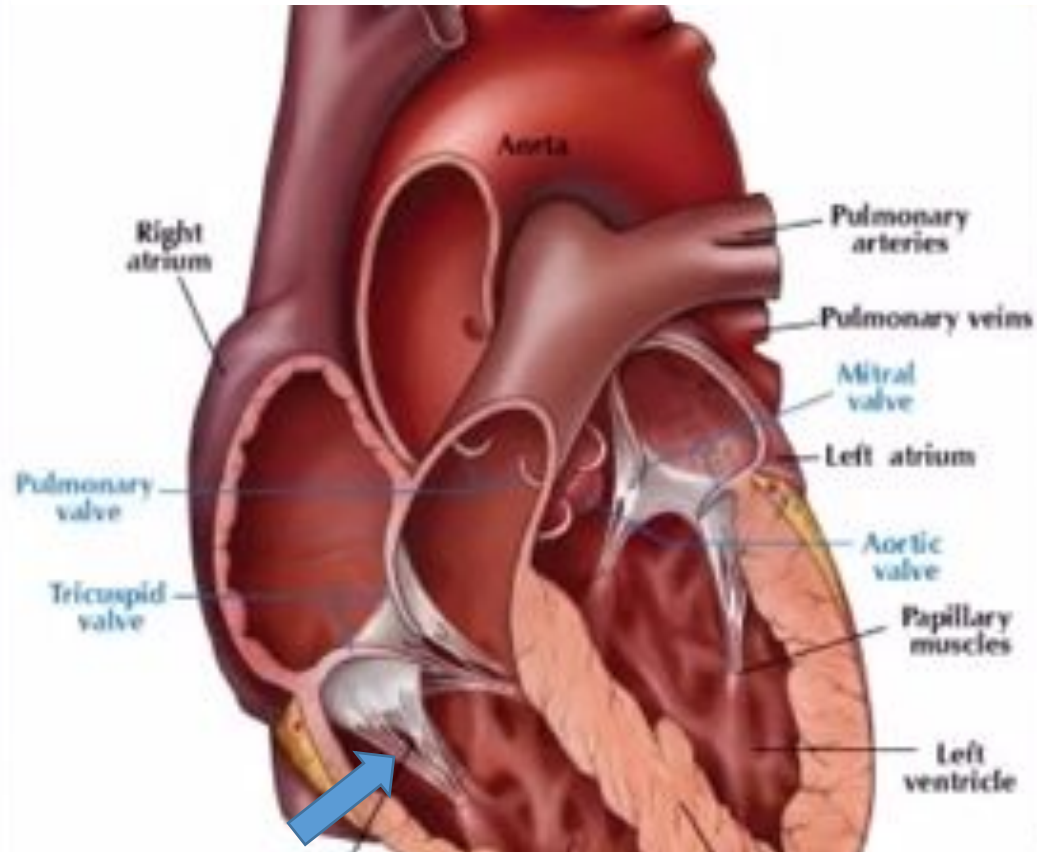
Oxygenated blood
to LV via the
bi-cuspid valve.

The path of blood through the heart



4 Valves of the heart, open only one way

- high pressure behind – **open**
- high pressure in front – **closed**.



Chordae tendinae- prevent the valves from turning inside out under pressure.

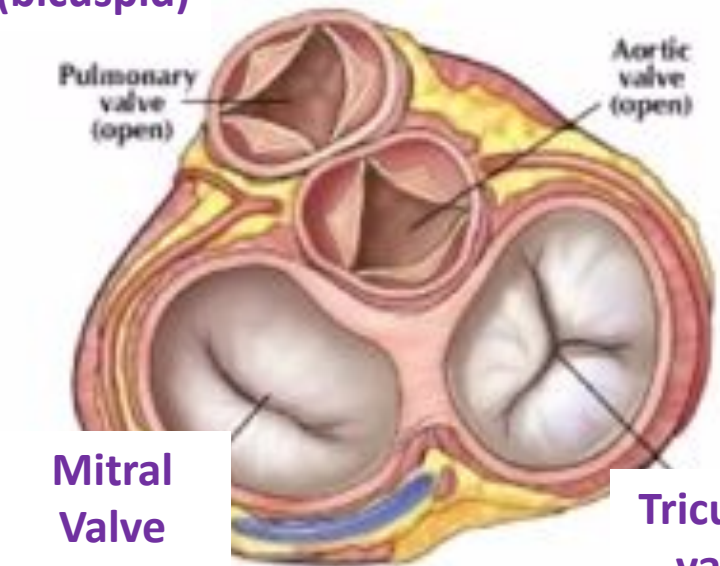
Pulmonary valve

VIEW FROM ABOVE

Aortic Valve

Mitral Valve (bicuspid)

Tricuspid valve

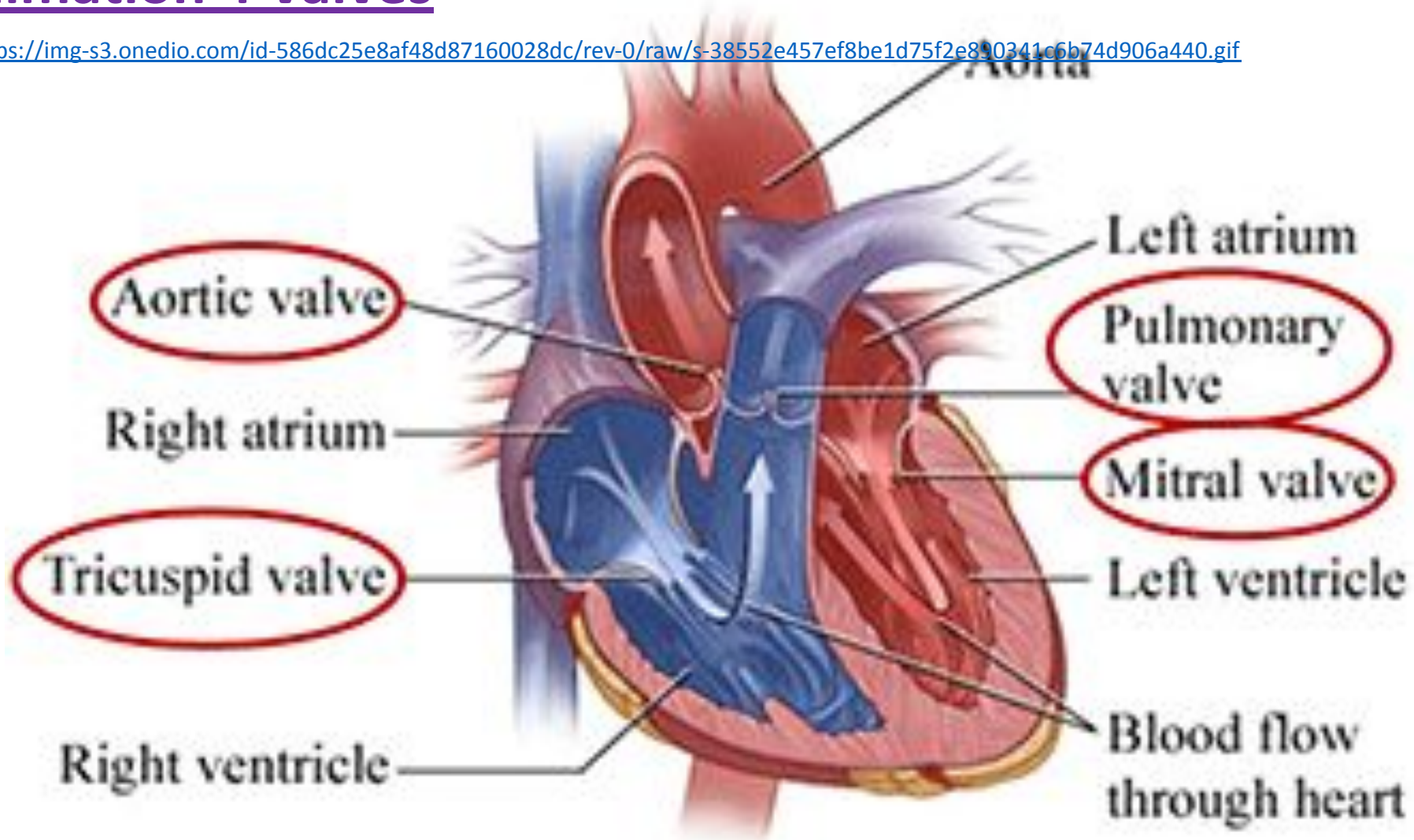


Mitral Valve (bicuspid)

Tricuspid valve

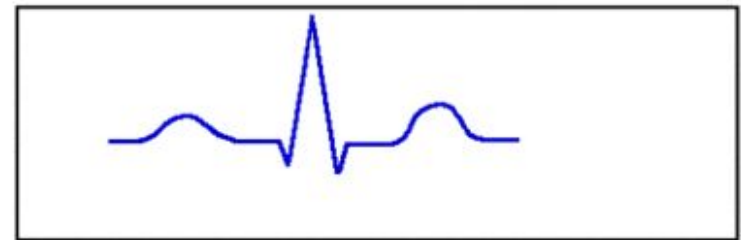
Animation 4 Valves

<https://img-s3.onedio.com/id-586dc25e8af48d87160028dc/rev-0/raw/s-38552e457ef8be1d75f2e890341c6b74d906a440.gif>



Chordae tendinae- prevent the valves from turning inside out under pressure

II. Cardiac Cycle



--Animation showing a cardiac cycle and the corresponding electrocardiogram wave

http://en.wikipedia.org/wiki/File:ECG_principle_slow.gif

Information on the ECG and examples of some common anomalies

<http://www.ivline.info/2010/05/quick-guide-to-ecg.html>

<http://www.happydoctor.ru/info/536>

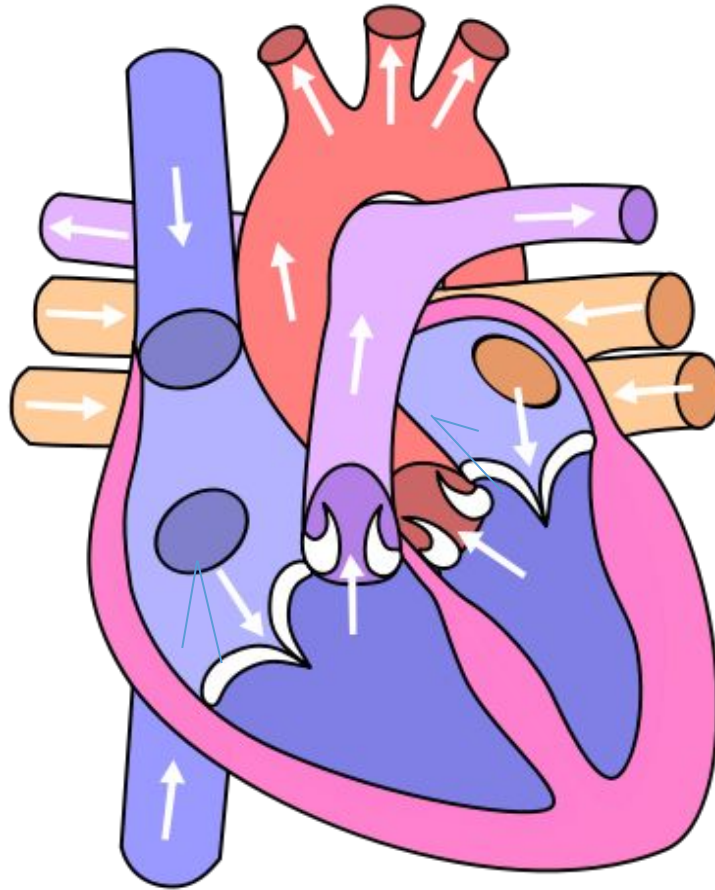
http://en.wikipedia.org/wiki/File:ECG_principle_slow.gif

Terminology 2

-Cardiac Cycle ECG

English	Google Russian
Myogenic / Myogenicity	Миогенная / миогенность
SAN node	Узел SAN
AV node	AV-узел
Bundles of HIS	Связки ЕГО
Purkinje fibers	Пуркинье
Septum	перегородка
Depolarization	деполяризация
Repolarization	реполяризация
Wolff-Parkinson-White Syndrome (WPW)	Wolff-Parkinson-White Syndrome (WPW)
Tachycardia >100 bpm	Тахикардия > 100 уд / мин
Bradycardia < 60 bpm	Брадикардия <60 уд / мин
Electrocardiography ECG	Электрокардиография ЭКГ

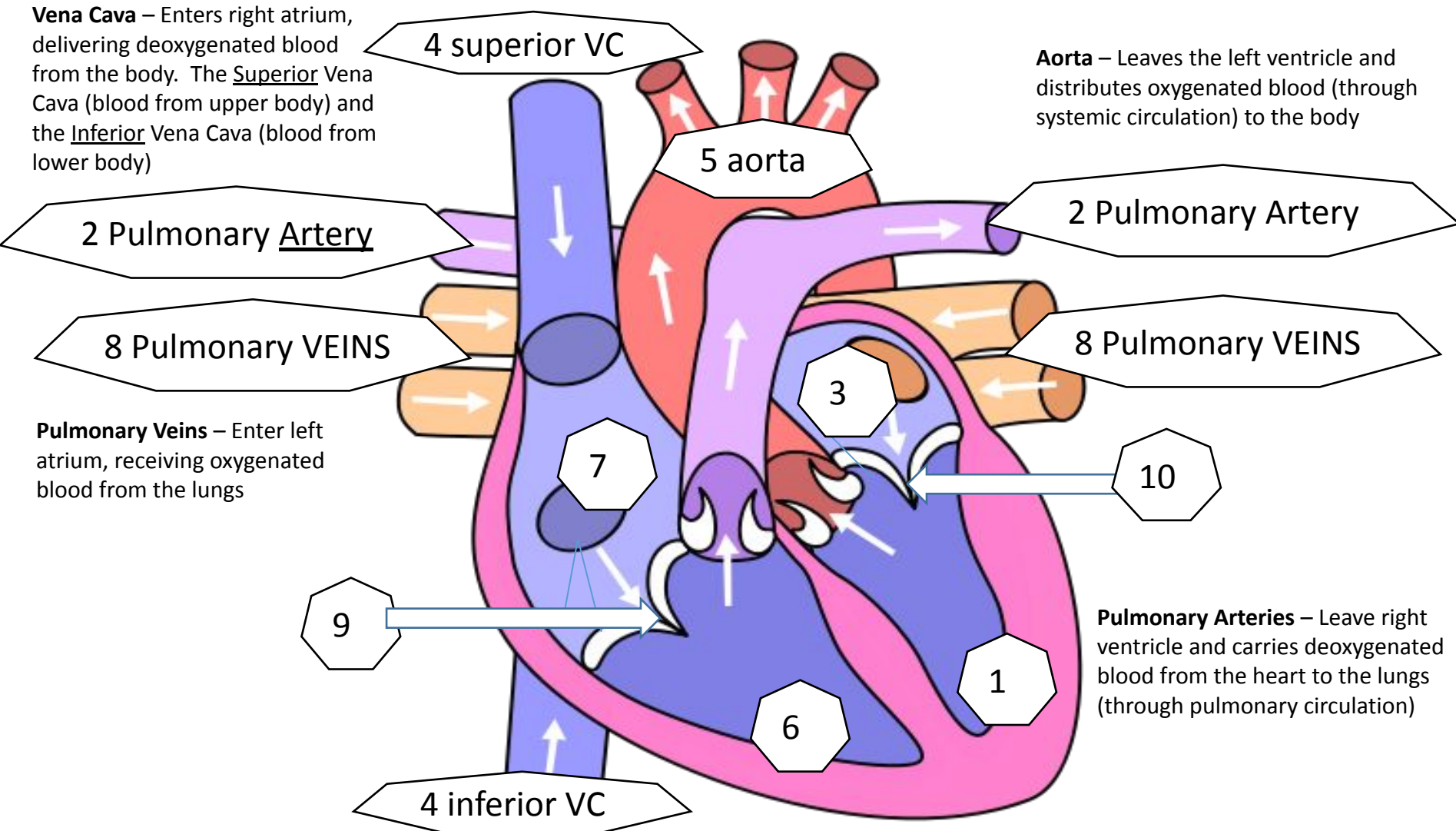
Label heart diagram! 1 min 😊



- 1) left ventricle 4) vena cava 7) right atrium
- 2) pulmonary artery 5) aorta 8) pulmonary vein
- 3) left atrium 6) right ventricle
- 9) atrio-ventricular (tricuspid) valve 10) semi-lunar (aortic) valve

Vena Cava – Enters right atrium, delivering deoxygenated blood from the body. The Superior Vena Cava (blood from upper body) and the Inferior Vena Cava (blood from lower body)

Aorta – Leaves the left ventricle and distributes oxygenated blood (through systemic circulation) to the body



Arteries carry blood AWAY from the HEART **Veins** carry blood TOWARD the HEART

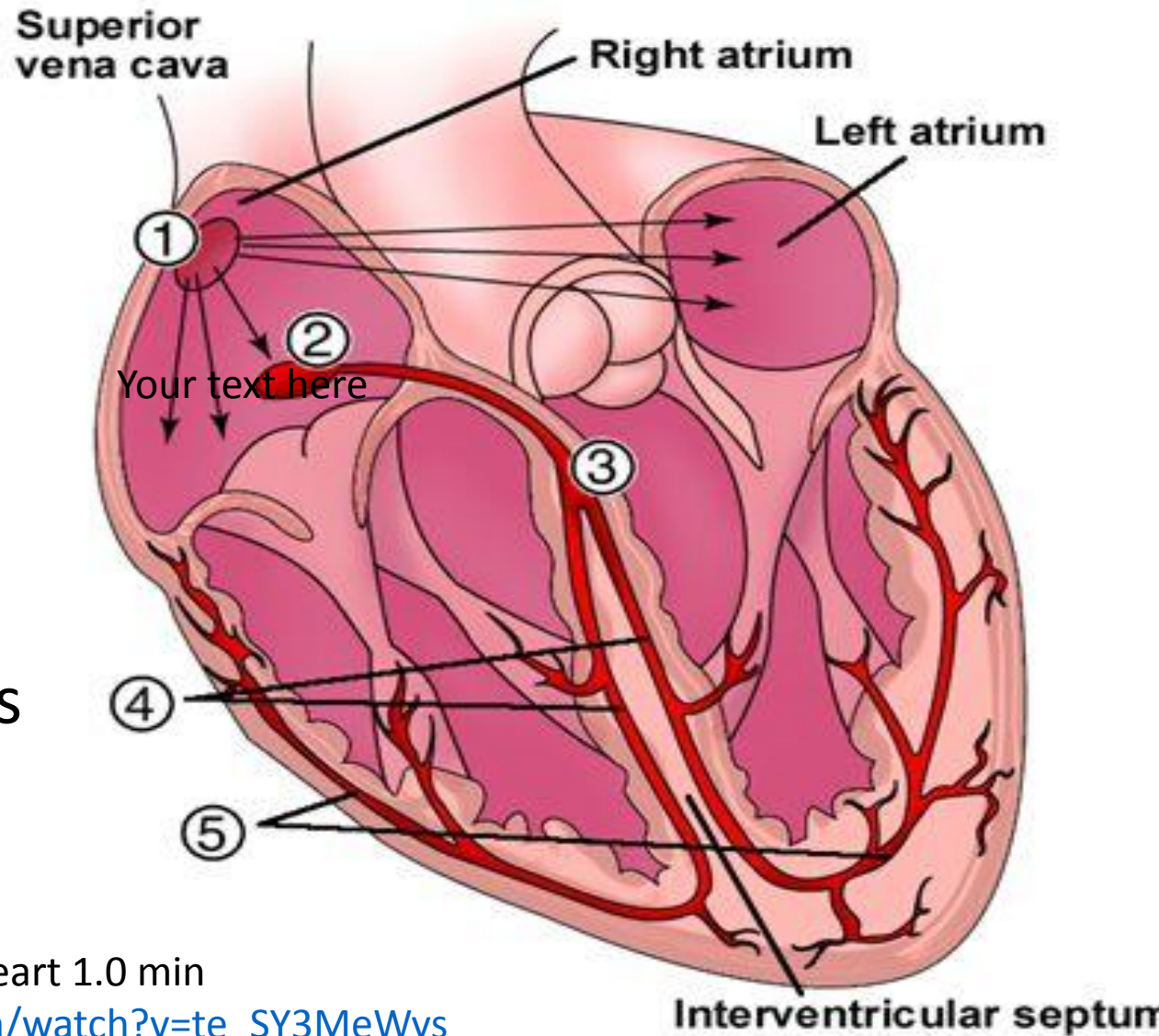
What is **myogenic**?

muscles or tissues that can contract on their own, without any external electrical stimulus from the brain or nervous system.

Electrical Activity of the Heart

Names of the numbers!

- 1- SAN node
- 2 – AV node
- 3 - Bundle of HIS
- 4 – Right / Left
Branch Bundles
- 5 - Purkinje fibers



Electrical Activity of the Heart 1.0 min

https://www.youtube.com/watch?v=te_SY3MeWys

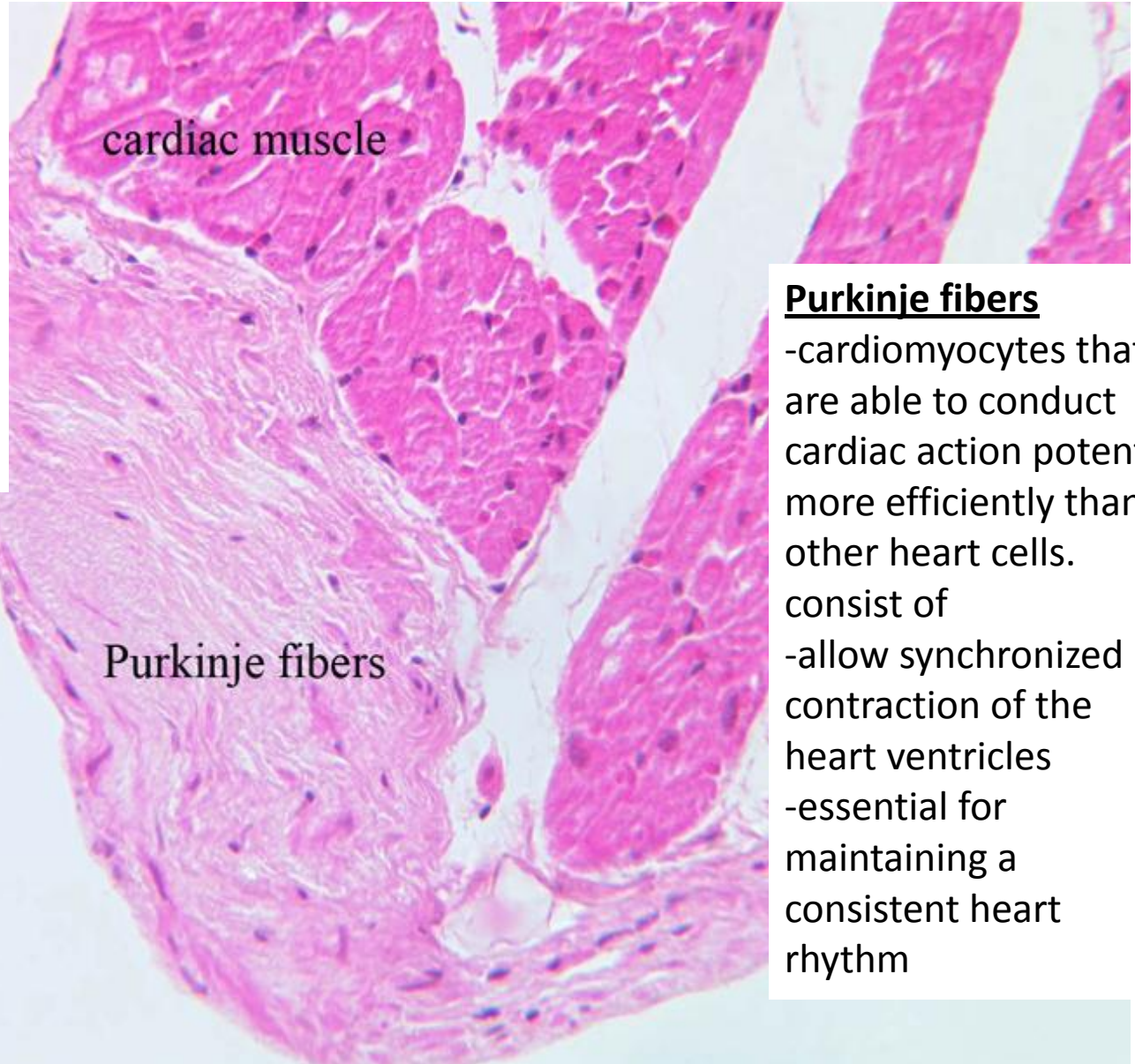
Electrical Activity 3 min <https://www.youtube.com/watch?v=RYZ4daFwMa8>

Micrograph of tissue found in the heart.

Bundle of His

-heart muscle cells specialized for electrical conduction

-transmit electrical impulses from AV node to apex via bundle branches.



Purkinje fibers

-cardiomyocytes that are able to conduct cardiac action potential more efficiently than other heart cells.

consist of

-allow synchronized contraction of the heart ventricles

-essential for maintaining a consistent heart rhythm

Atrioventricular valves- link the atria to the ventricles.

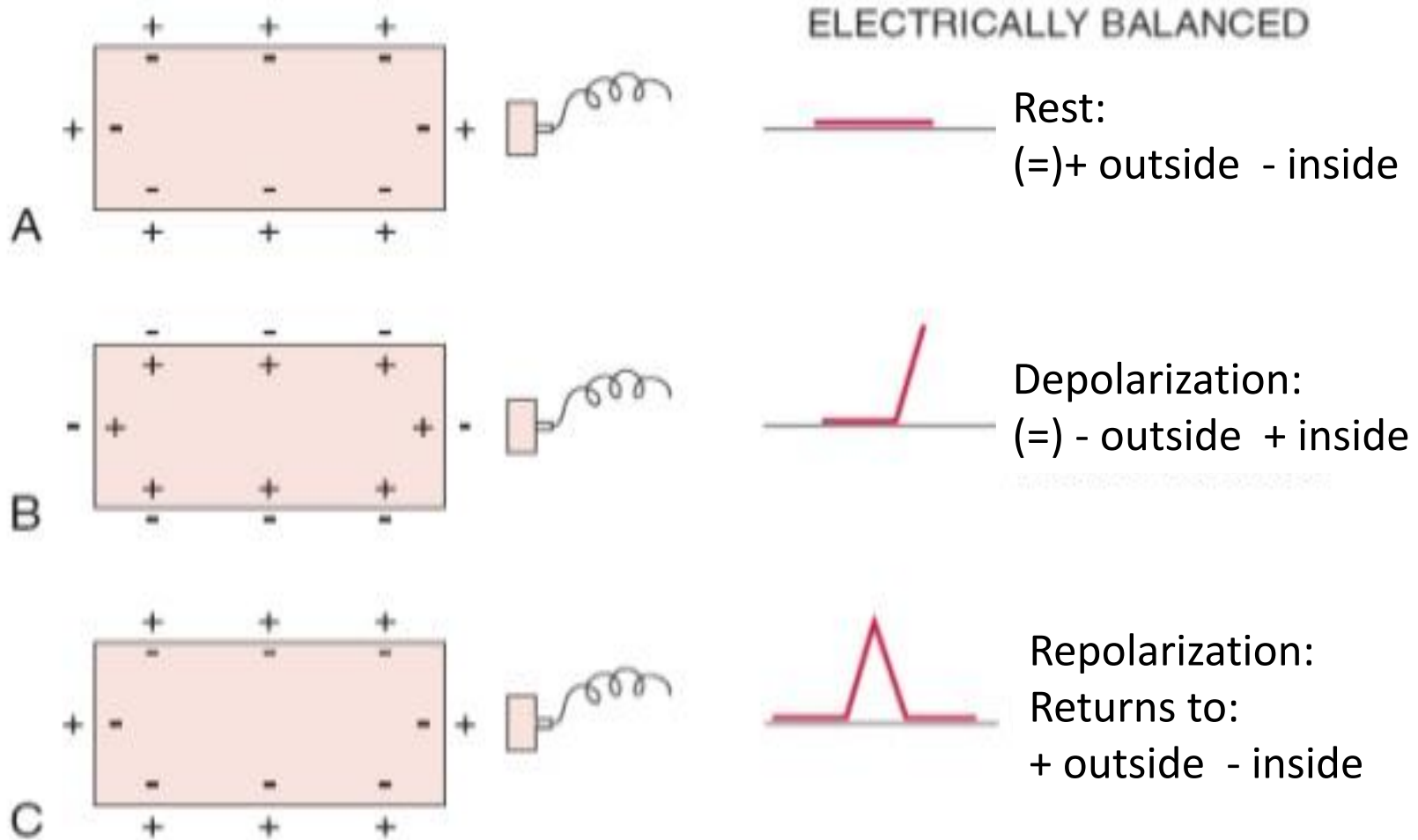
Semi-lunar- valves link the ventricles to the pulmonary artery and aorta

Bundle of His -heart muscle cells specialized for electrical conduction -transmit electrical impulses from AV node to apex via bundle branches.

Purkinje fibers -**cardiomyocytes** that are able to conduct cardiac action potential more efficiently than other heart cells. consist of

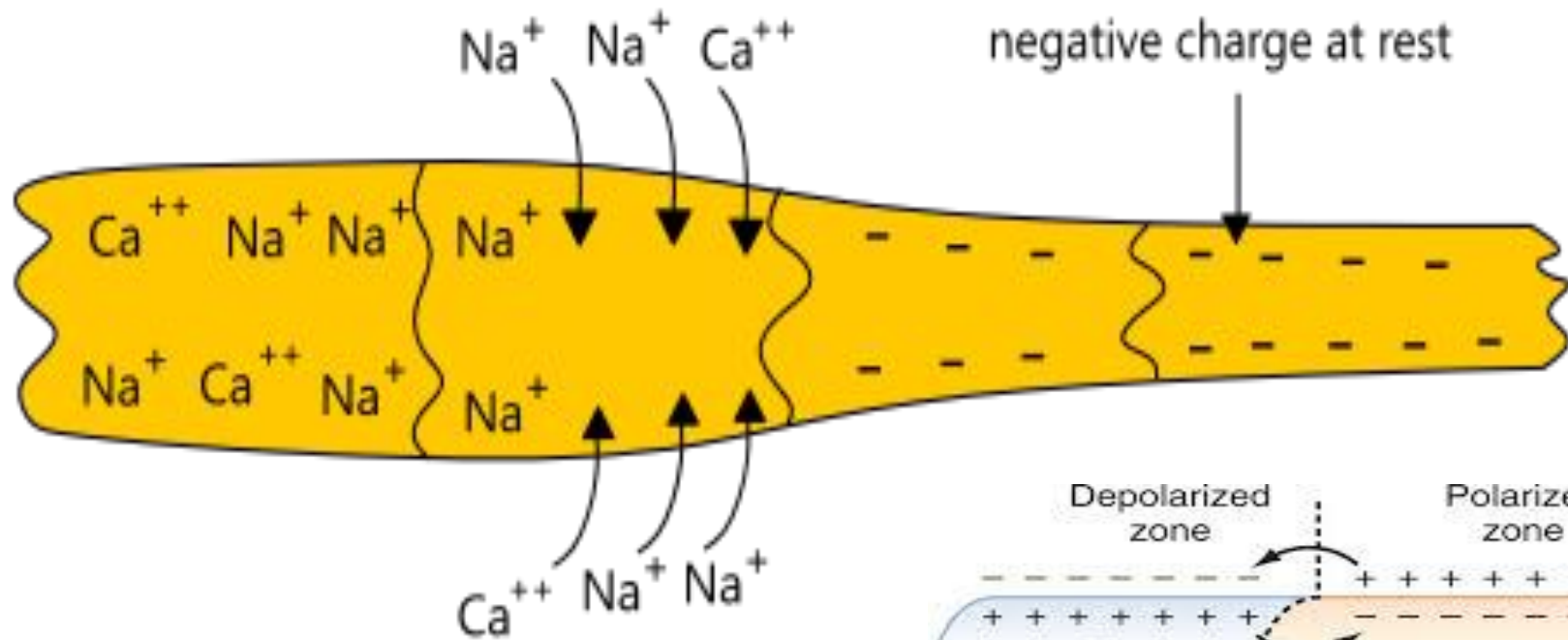
- allow synchronized contraction of the heart ventricles
- essential for maintaining a consistent heart rhythm

Action Potential in cardiac tissue

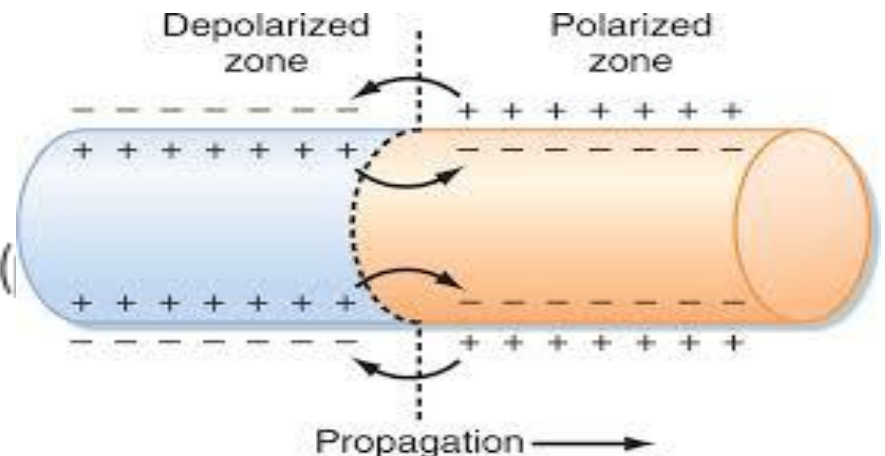


Heart Muscle - depolarization

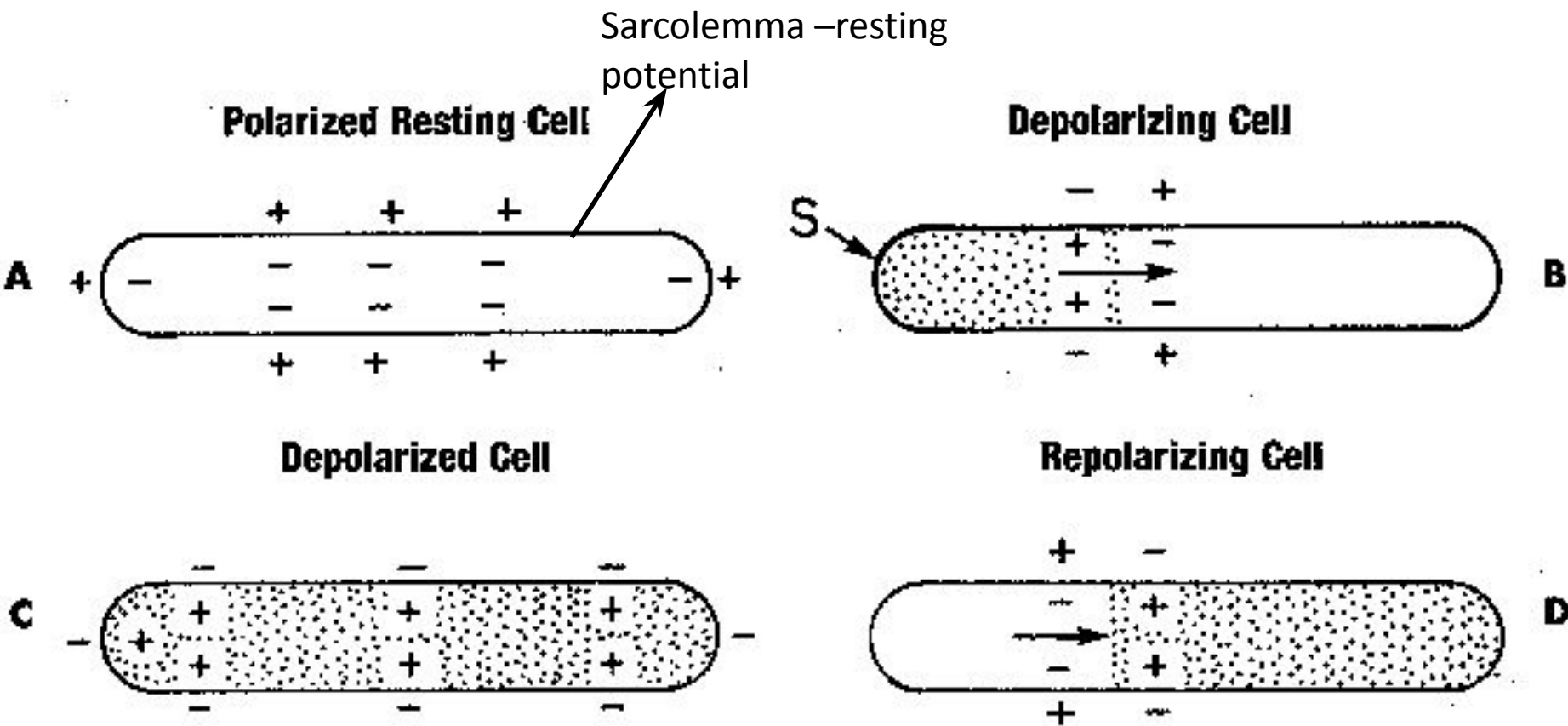
contraction
depolarization



Influx of Na^+ and Ca^{++} causes depolarization (



Describe the difference between polarisation, depolarisation and repolarisation.



IONS INVOLVED - K⁺, Na⁺ and Ca⁺ (from sarcoplasmic reticulum)

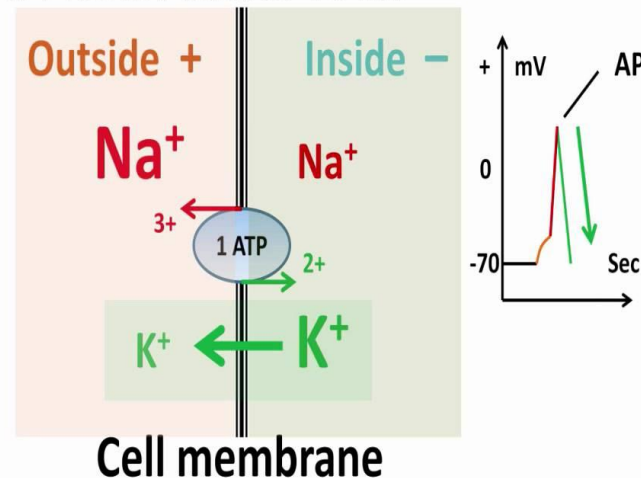
depolarization....

- Depolarization is when a cell membrane's charge becomes positive to generate an action potential. This is usually caused by positive sodium and calcium ions going into the cell

Action Potential (AP): Repolarization

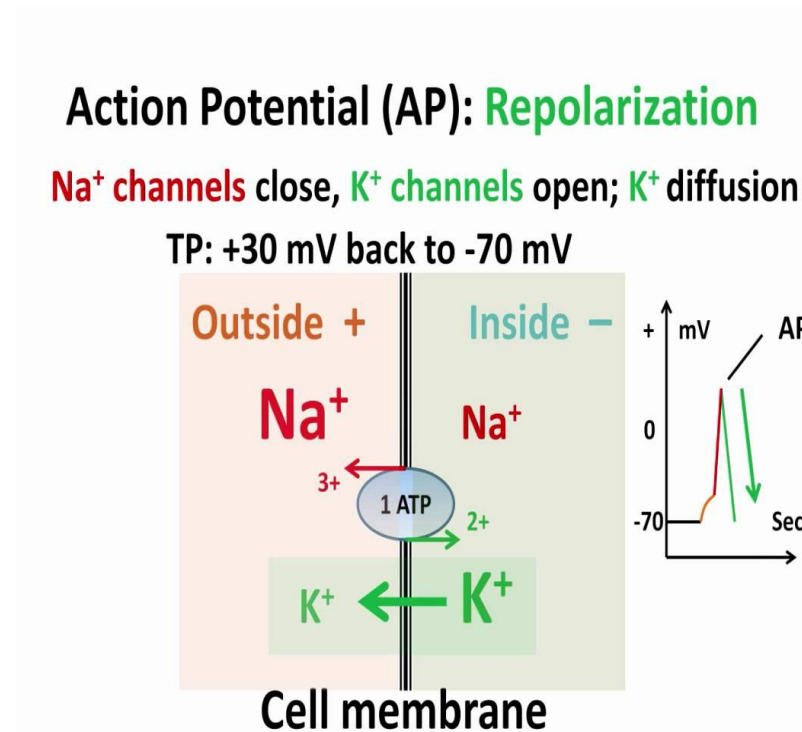
Na^+ channels close, K^+ channels open; K^+ diffusion

TP: +30 mV back to -70 mV



repolarization.....

- Repolarization is when a cell membrane's charge returns to negative after depolarization. This is caused by positive potassium ions moving out of the cell.

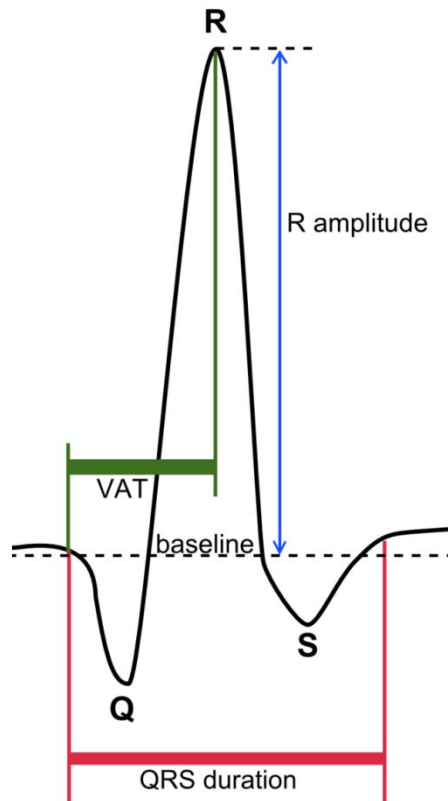


Depolarization and repolarization video

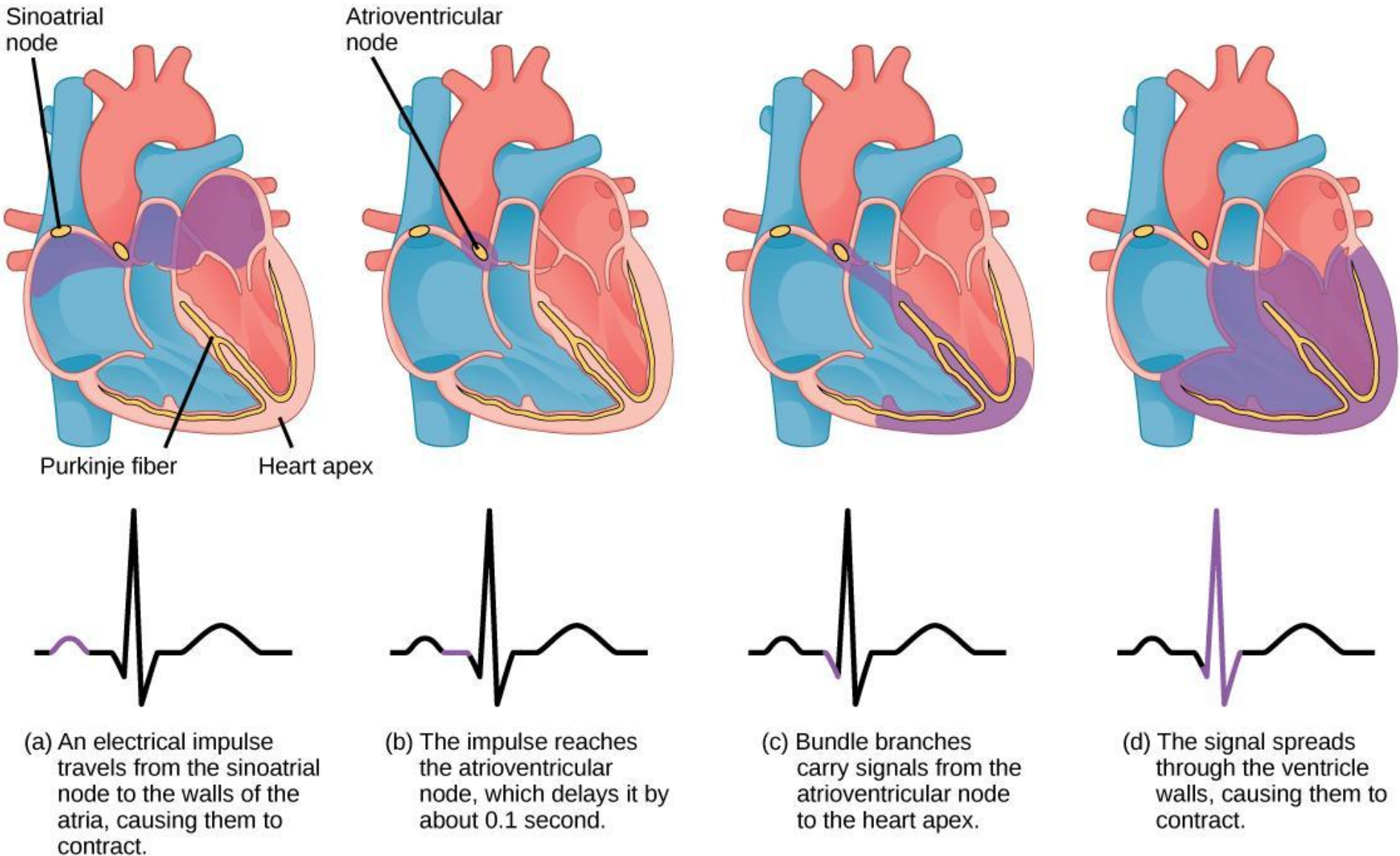
<http://www.youtube.com/watch?v=4vkbywows-o>

The QRS complex

the combination of three of the graphical deflections seen on a typical deflections on an electrocardiogram = ECG or EKG

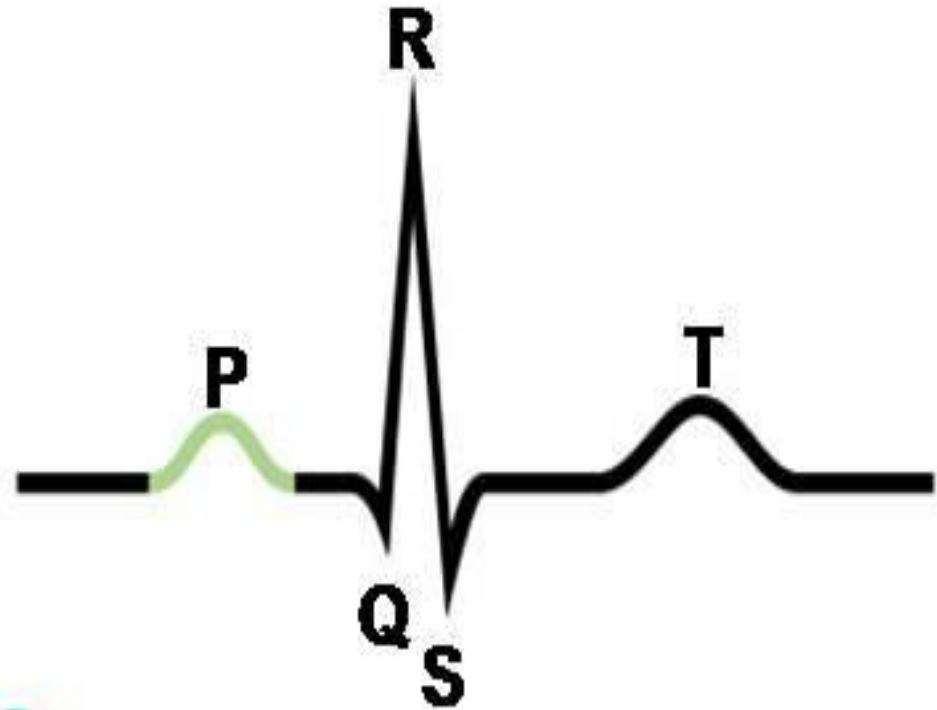
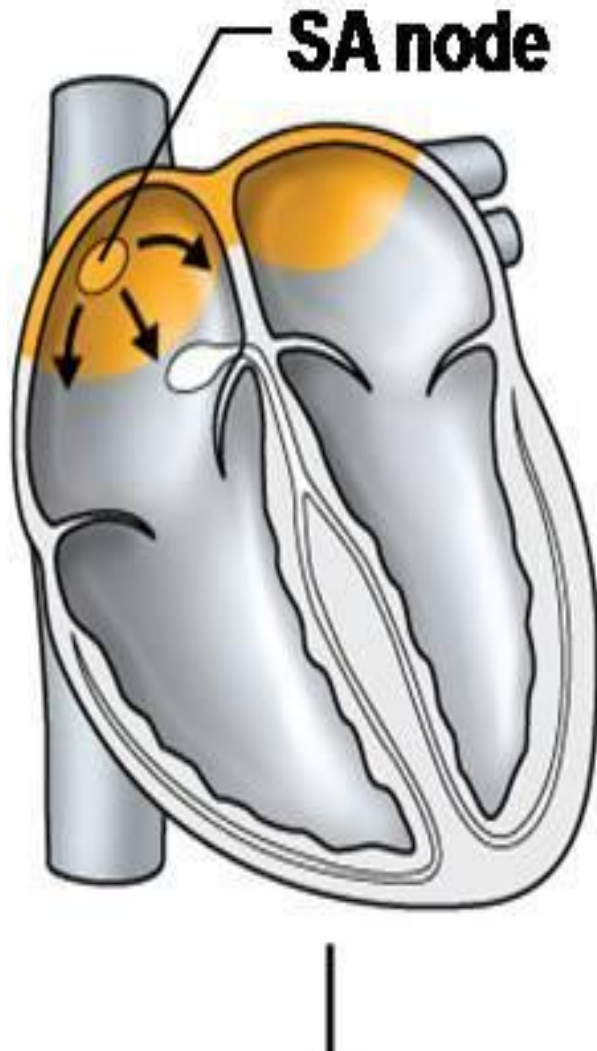


EKG or ECG - Electrocardiogram



Stop / play back / stop the animation of the cardiac cycle phases:

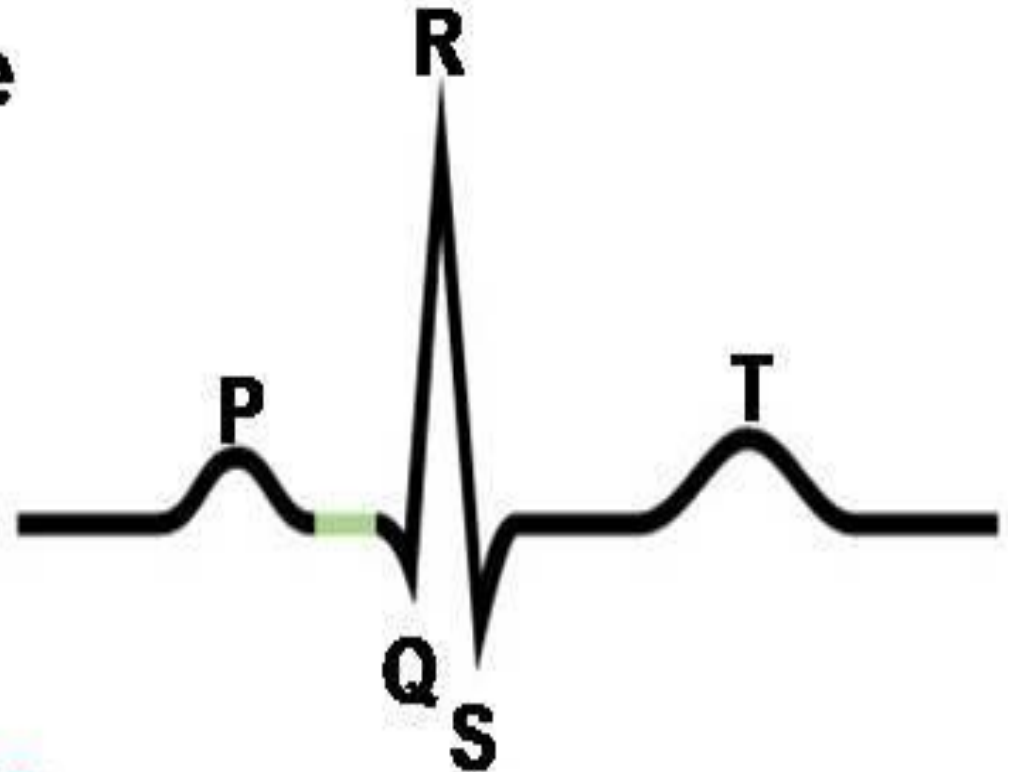
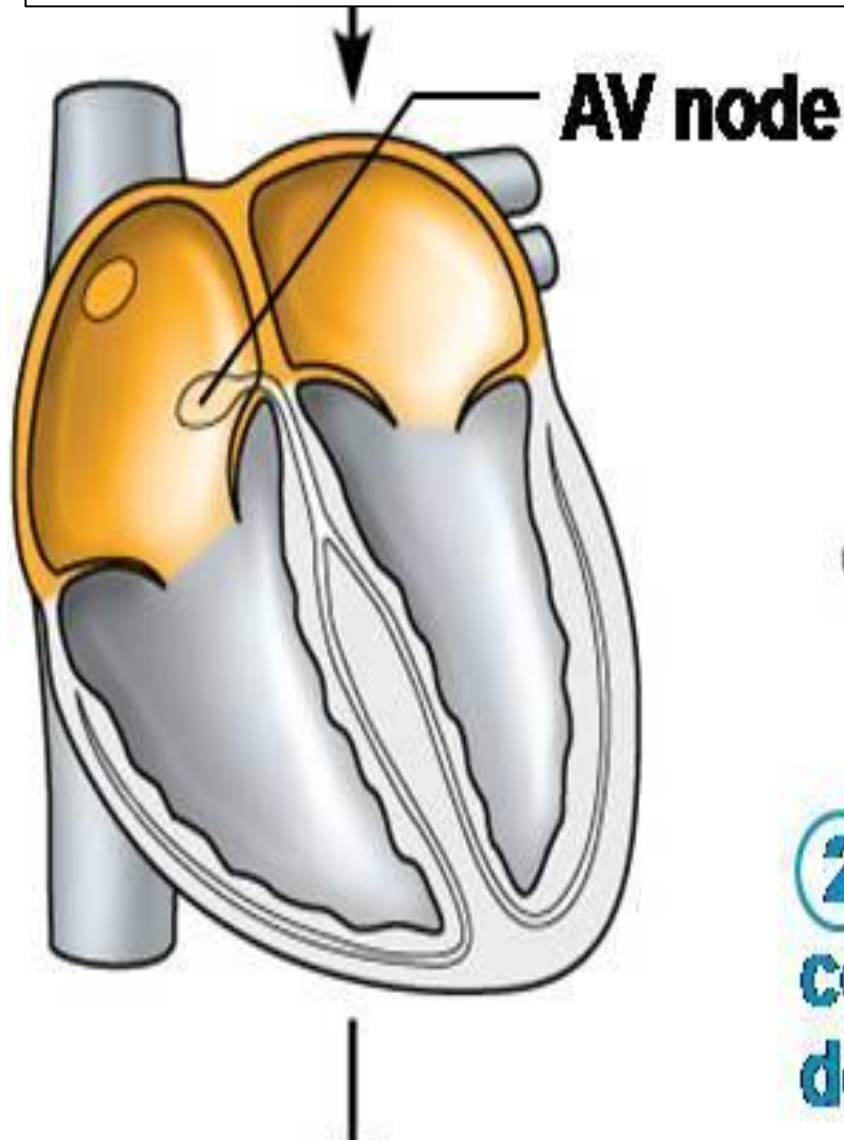
http://highered.mcgraw-hill.com/sites/0072495855/student_view0/chapter22/animation_the_cardiac_cycle_quiz_2_.html



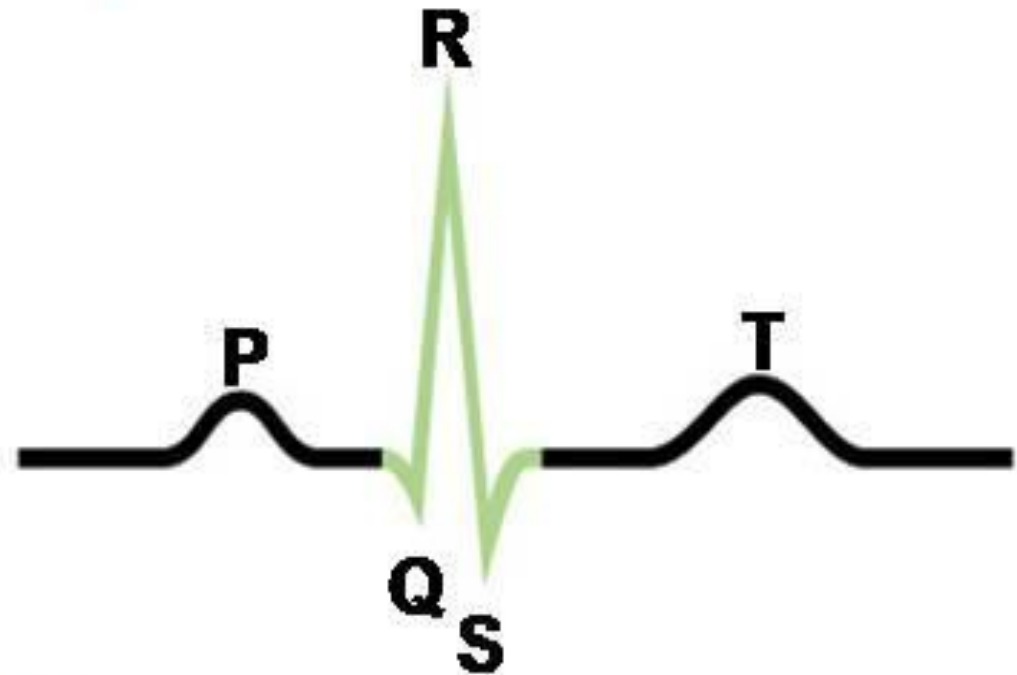
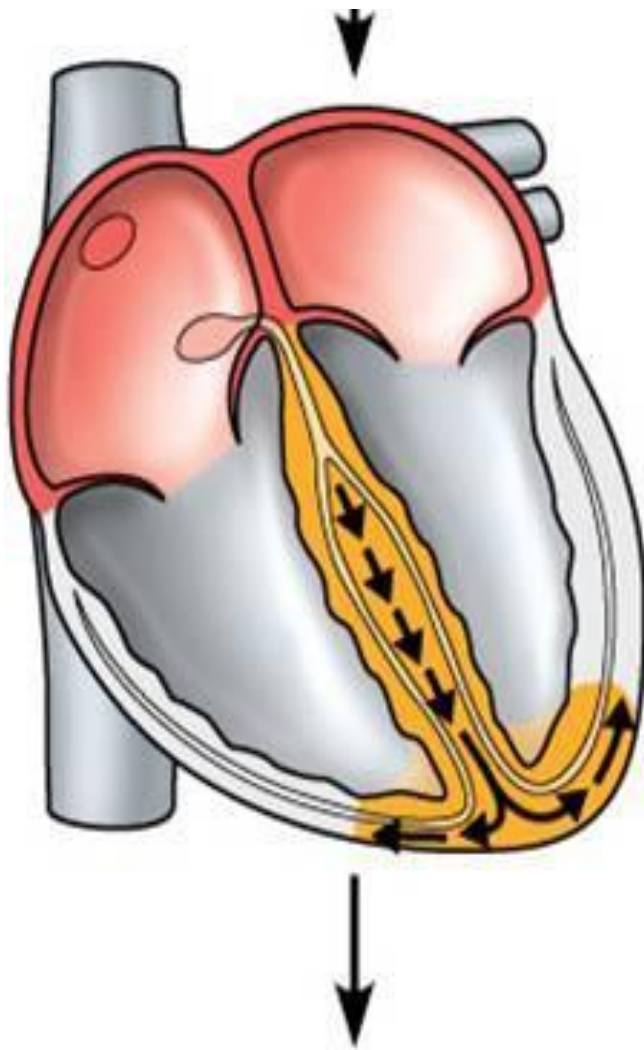
① Atrial depolarization, initiated by the SA node, causes the P wave.

SAN – pacemaker

0.2 seconds -- time for the impulse to be conducted from the SAN to the ventricles via the AVN (P—R). The edges of the atria have tough fibers that prevents the leakage of impulse from atrias. **AVN - gatekeeper**



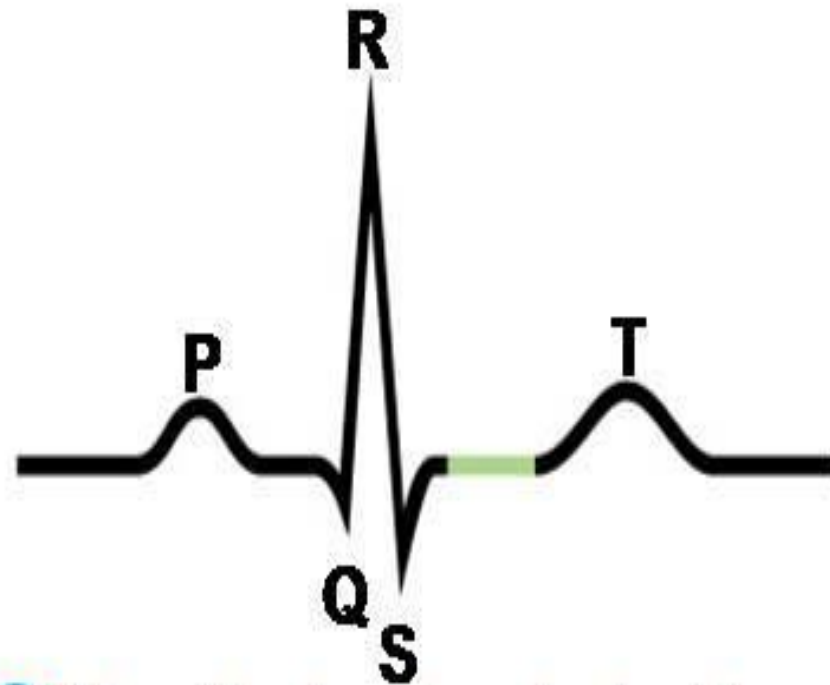
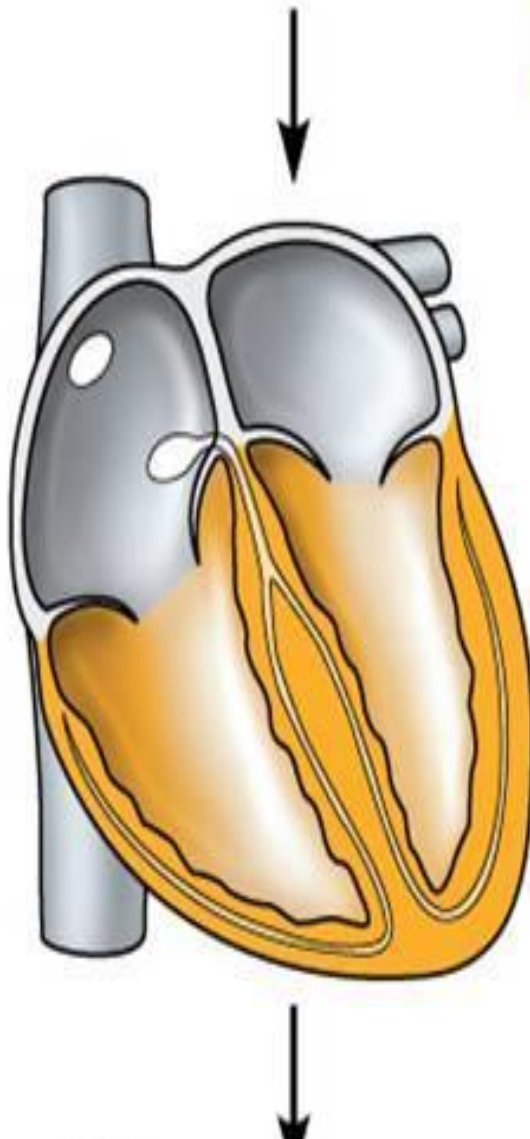
② With atrial depolarization complete, the impulse is delayed at the AV node.



③ Ventricular depolarization begins at apex, causing the QRS complex. Atrial repolarization occurs.

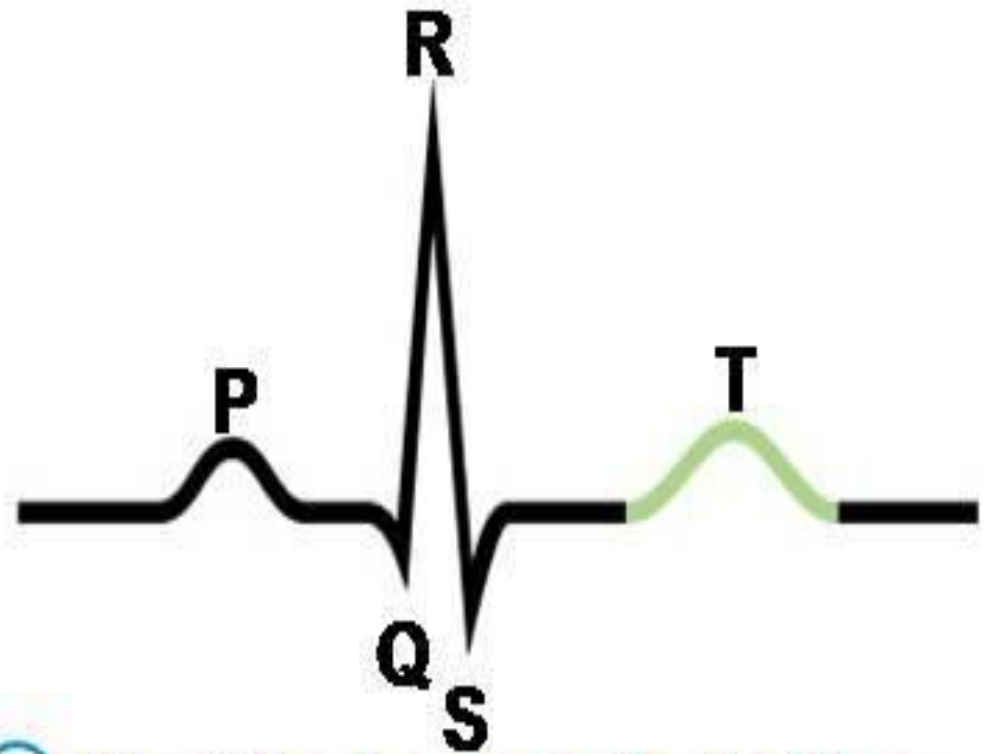
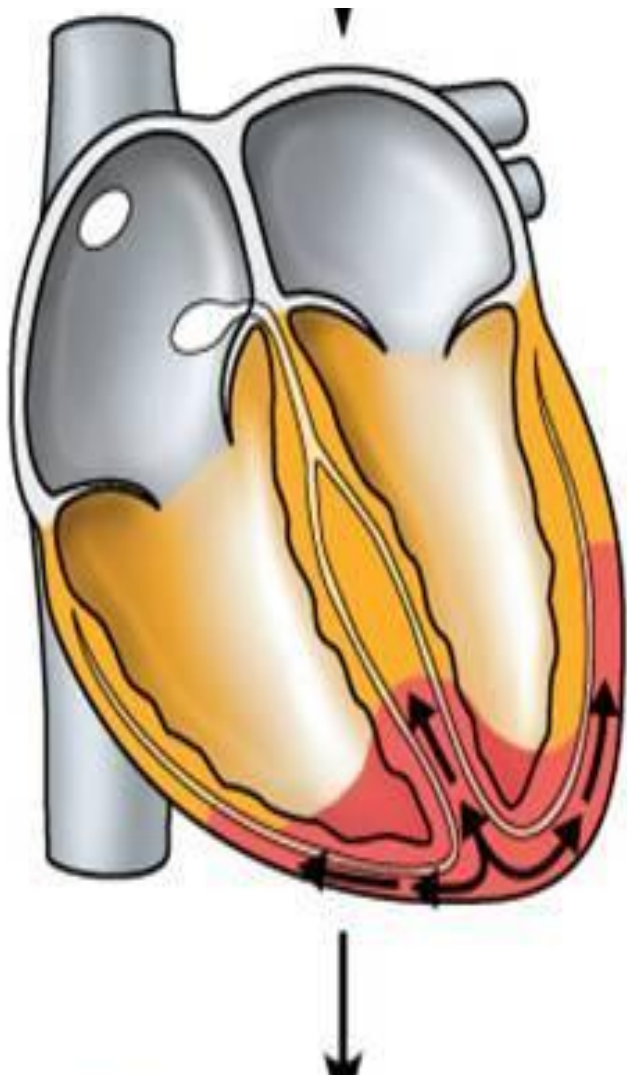
Ventricle contraction –
wave of depolarization flows through the B. of HIS.

 Depolarization  Repolarization



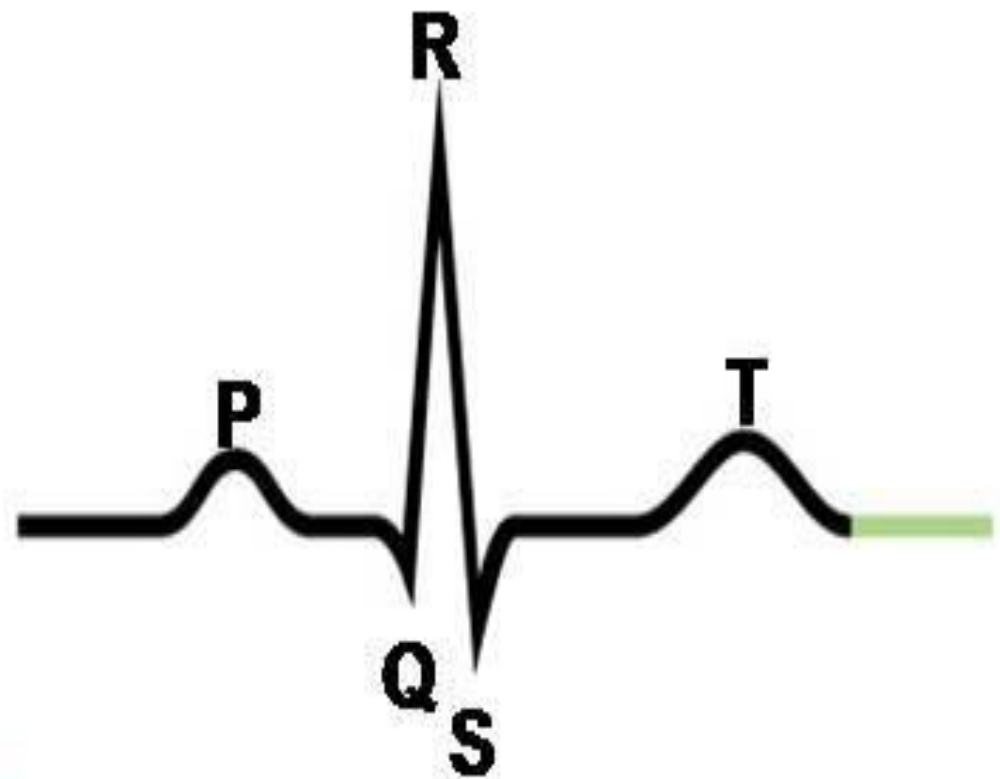
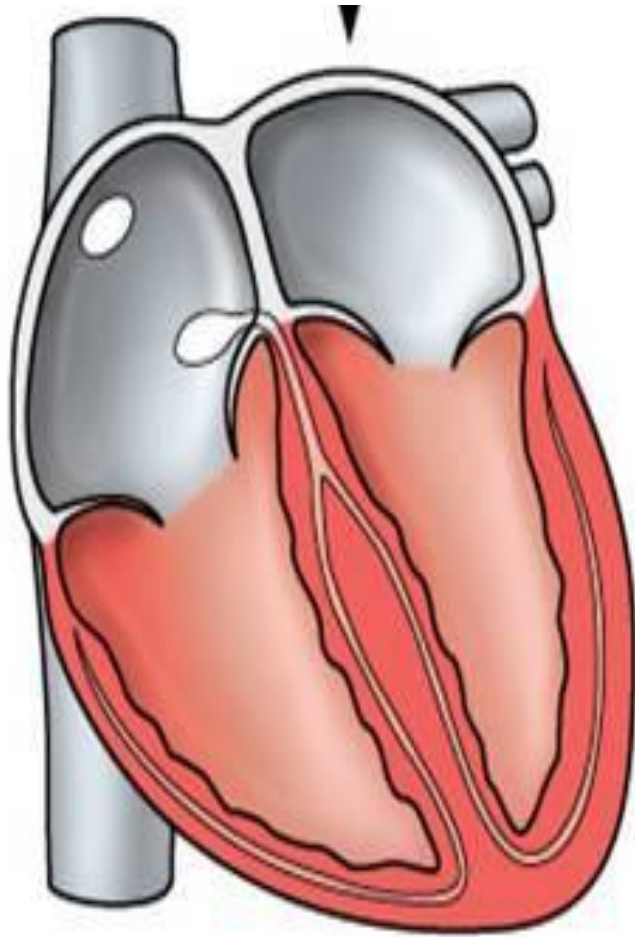
④ Ventricular depolarization is complete.





⑤ Ventricular repolarization begins at apex, causing the T wave.

Relaxation phase



⑥ Ventricular repolarization is complete.

**What are some ways that
SAN and AVN control the
heart beat?**

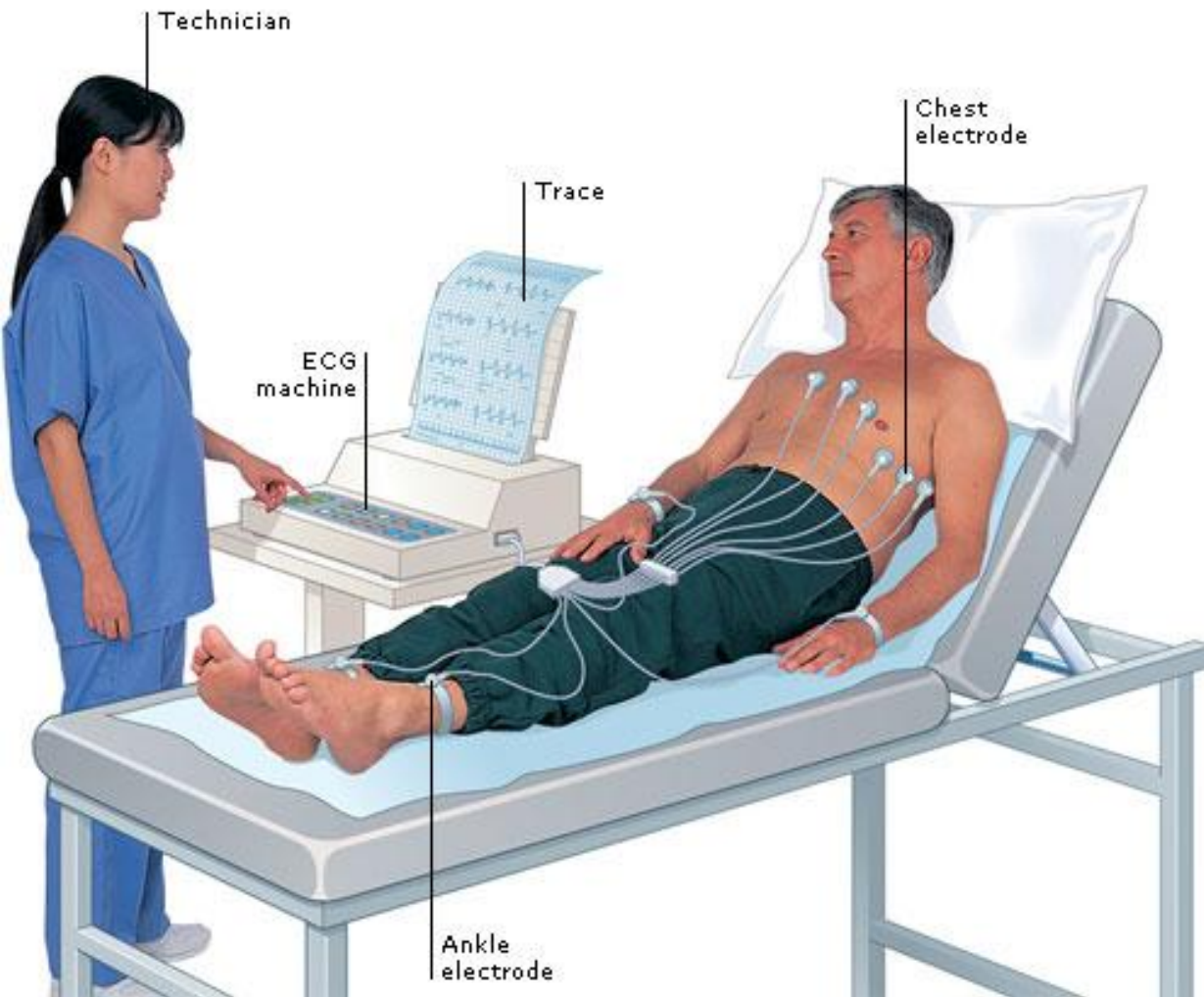
FACTS

- SAN initiates heartbeat**
- Beat of heart is myogenic – spontaneous not started by nervous system stimulus**
- Rate of heartbeat is influenced by nervous system**
- Wave of electrical activity, impulses over atria triggers contraction of atrium**
- Electrical activity may only pass to the ventricles via AVN and bundle of HIS (septum)**
- Fibrous tissue prevents passage beyond atria**
- Delay at AVN allows ventricles to fill completely from atria**

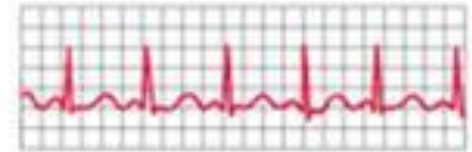
EKG wave animation..

- http://en.wikipedia.org/wiki/Electrocardiography#mediaviewer/File:ECG_principle_slow.gif

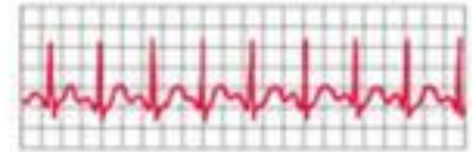
EKG or ECG - Electrocardiography



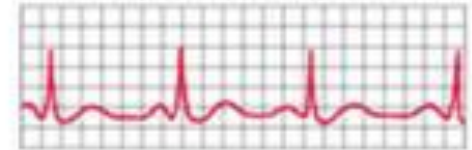
Normal Heartbeat



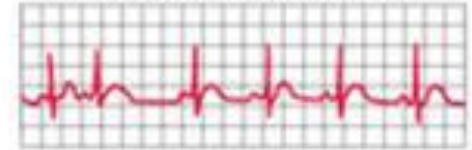Fast Heartbeat



Slow Heartbeat



Irregular Heartbeat



During the **cardiac cycle** (one contraction of the heart plus the relaxation period that follows), **electrical changes take place** in the heart. These changes can be visualized and recorded.

1) Detection of electrical forces in the heart.

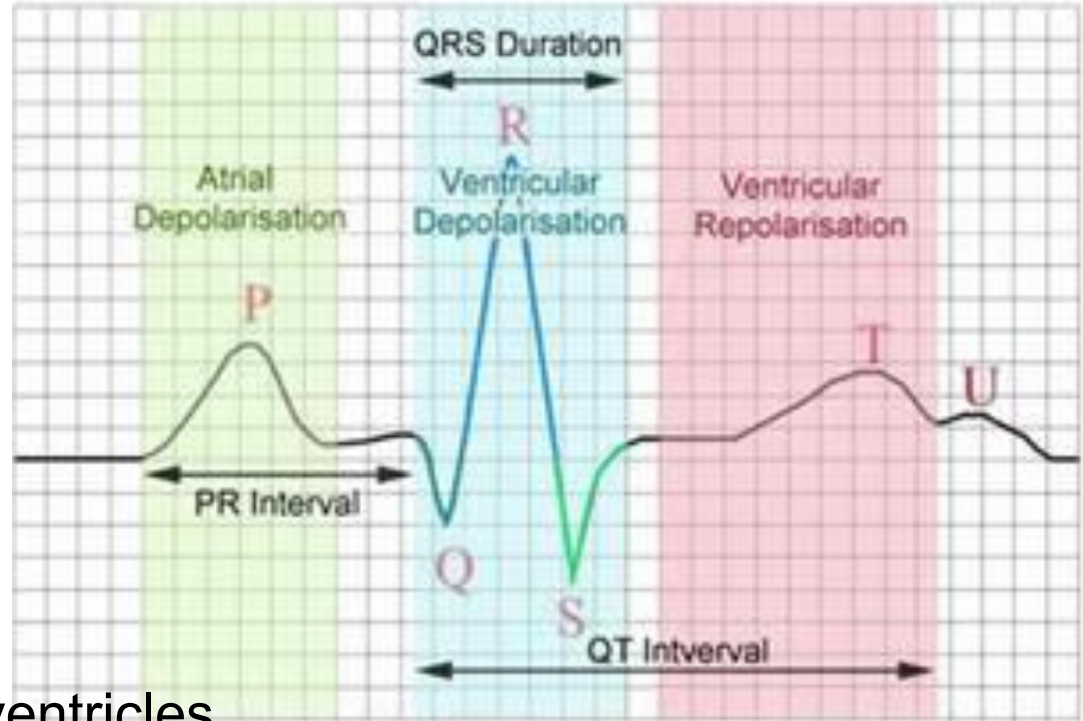
Electrical forces in the heart can be detected on the body's surface. Therefore, **electrodes** attached to the patient's **skin** can **detect electrical forces** in the heart.

2) Recording of electrical forces in the heart.

The **recording** of the electrical changes during the cardiac cycle is called an **electrocardiogram** (ECG or EKG). The instrument used to record these changes is an **electrocardiograph**.

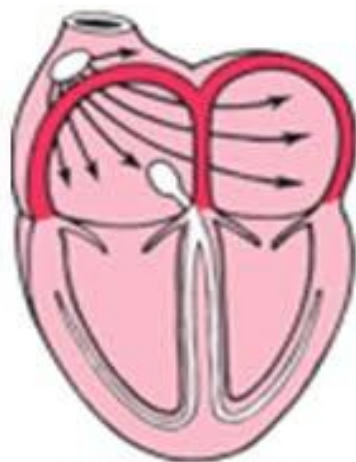
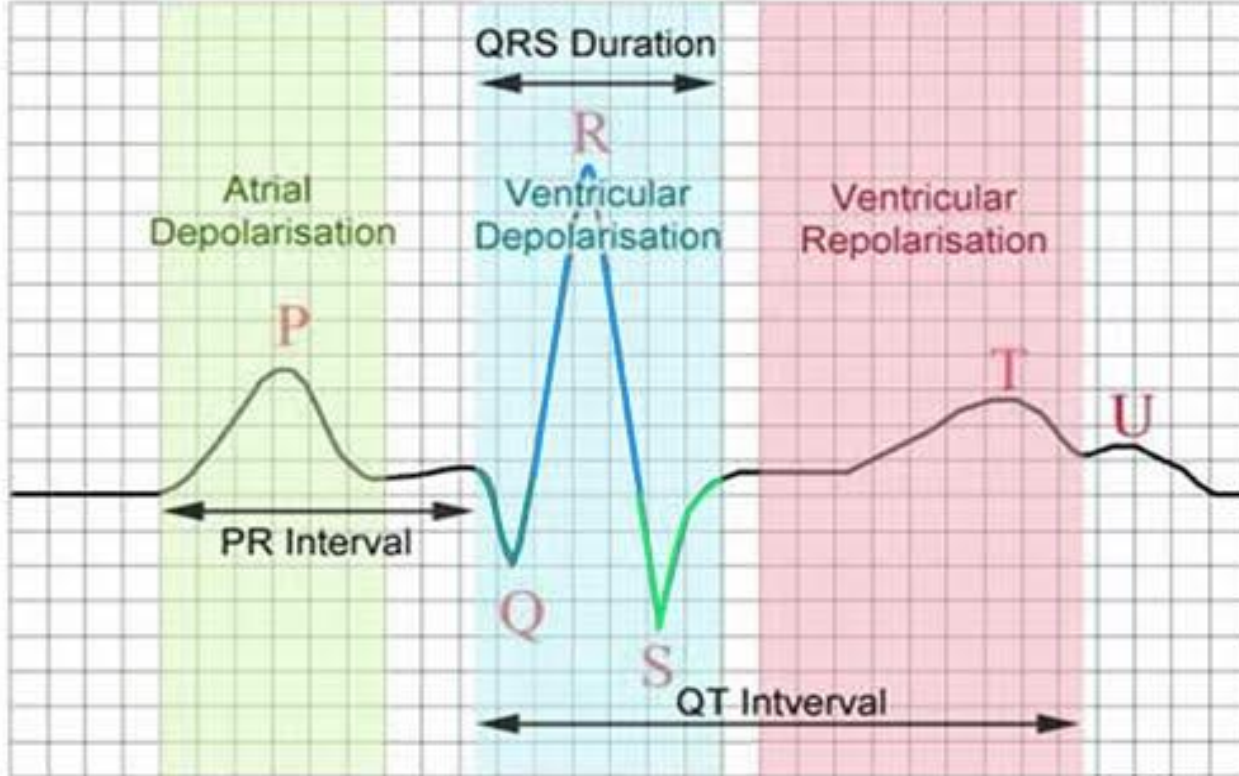
(1) **P wave**. A small upward (positive) wave that indicates atrial polarization (the spread of an impulse from the SA node through the muscle of the two atria). The atria contract a fraction of a second after the P wave begins.

(2) **QRS wave (complex)**. This second wave begins as a downward deflection and continues as a large, upright, triangular wave which finally ends as a downward wave at its base. This wave complex shows the spread of the electrical impulse through the ventricles.

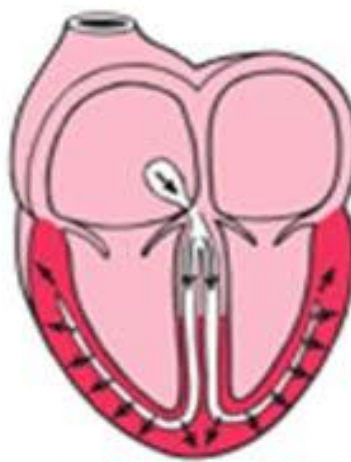


(3) **T wave**. The third wave shows ventricular repolarization.

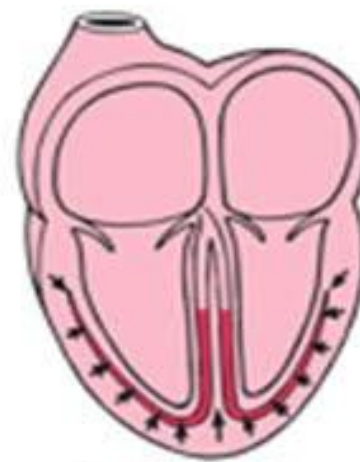NOTE: There is no deflection to show atrial repolarization because the stronger QRS wave masks this event.



Activation of the
atria

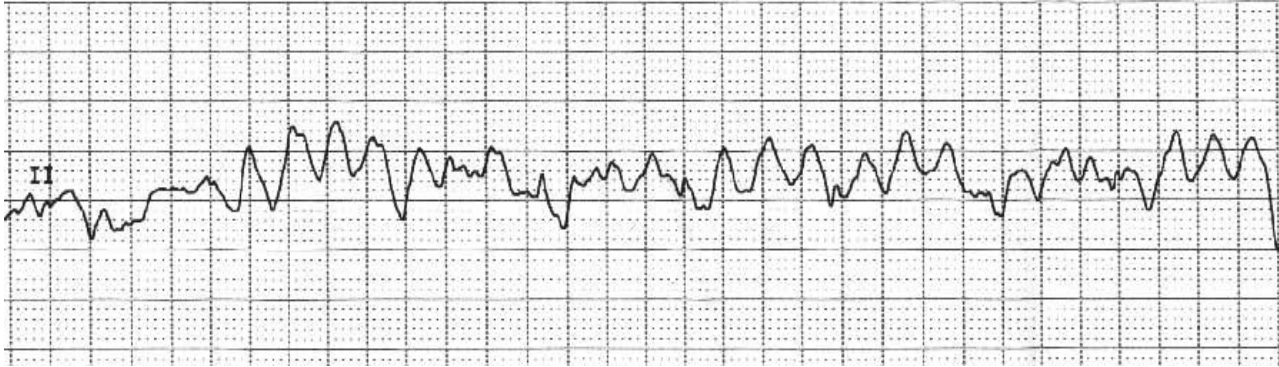


Activation of the
ventricles

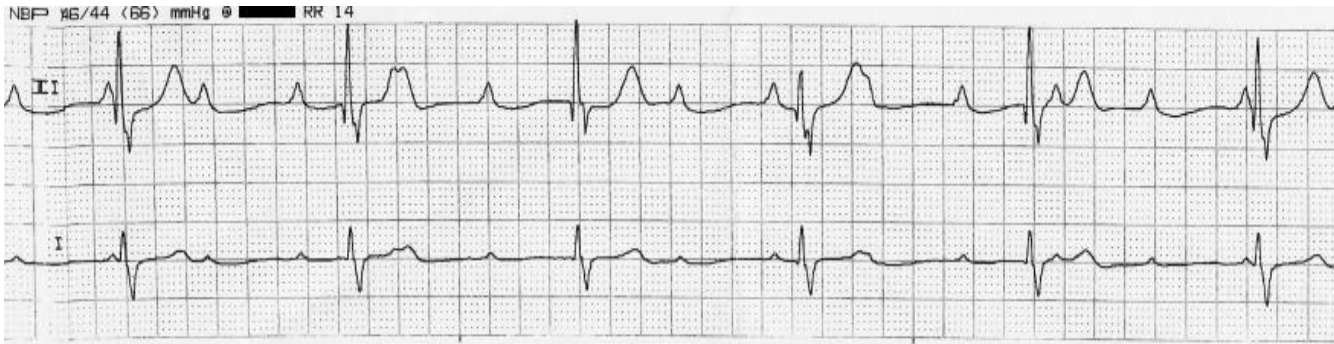


Recovery wave

Ventricular fibrillation

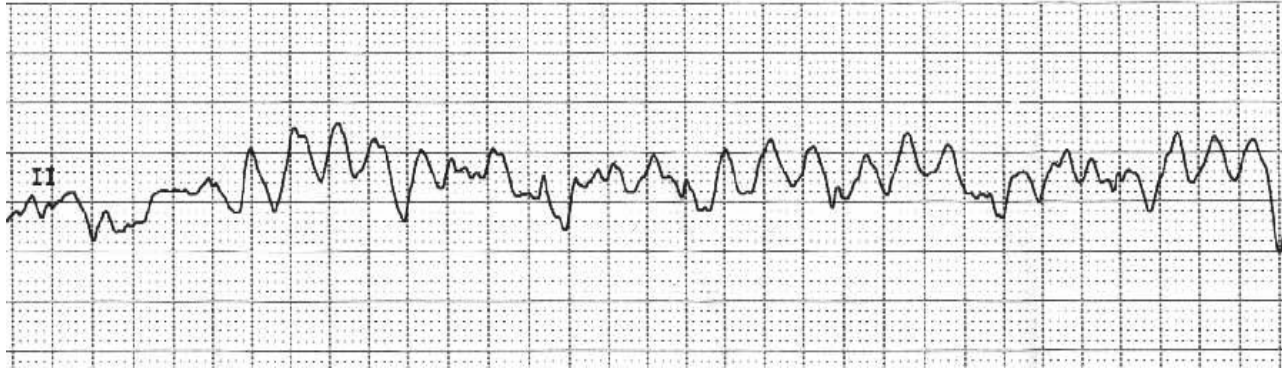


Heart Block



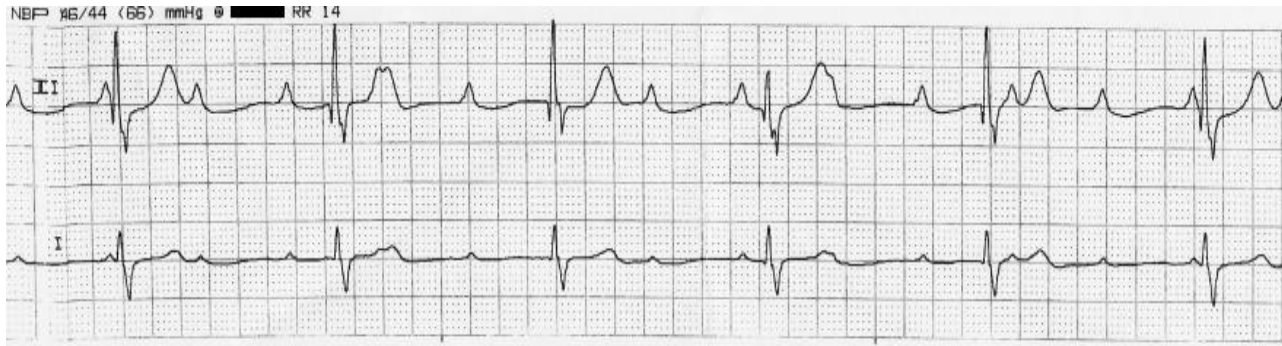
What do you think is happening in the ECG?

Ventricular fibrillation



Uncontrolled contraction of the ventricles causes little blood to be pumped

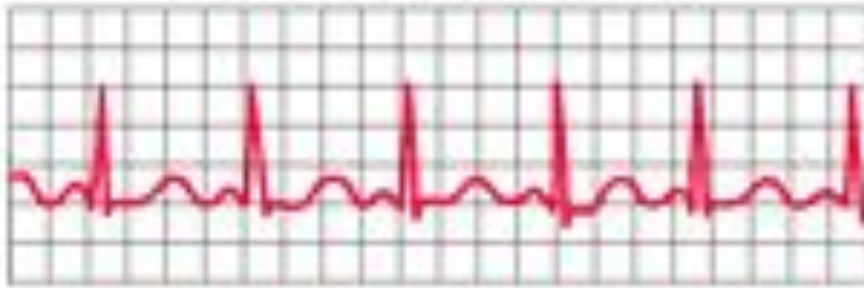
Heart Block



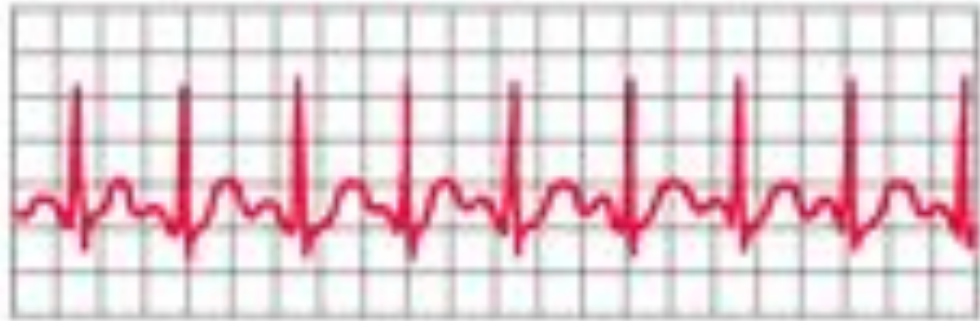
Ventricles are not always stimulated

What do you think is happening in the ECG?

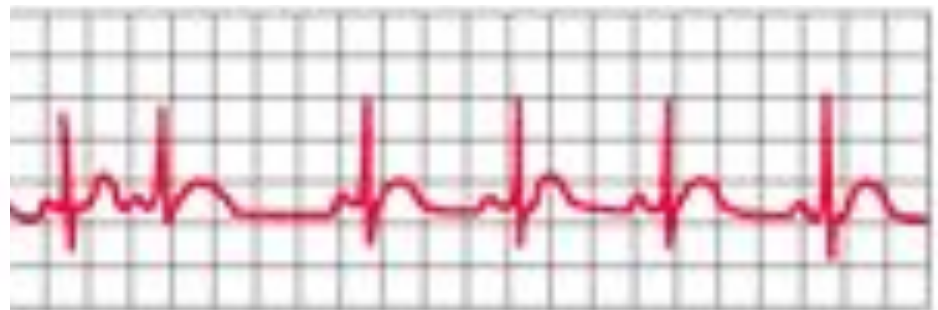
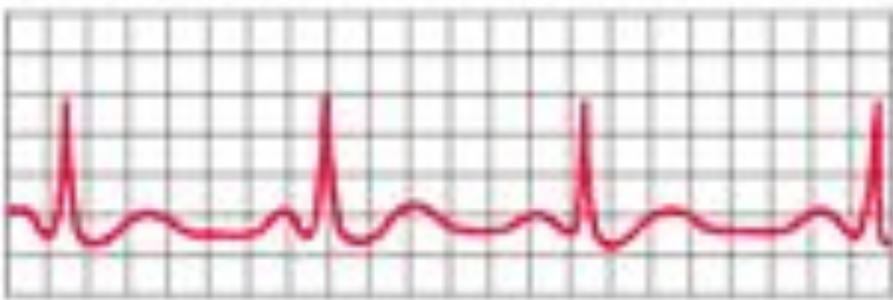
Match the beat with the ECG.



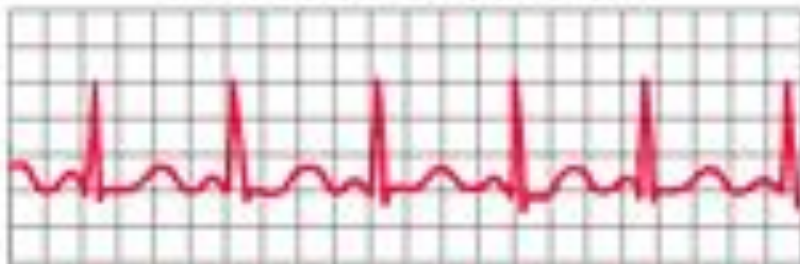
Irregular Tachycardia



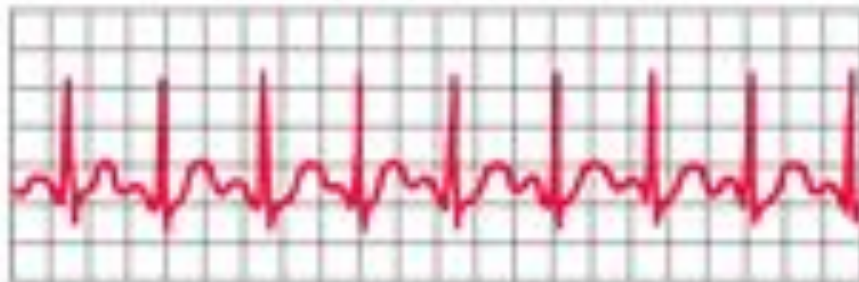
Bradycardia Normal



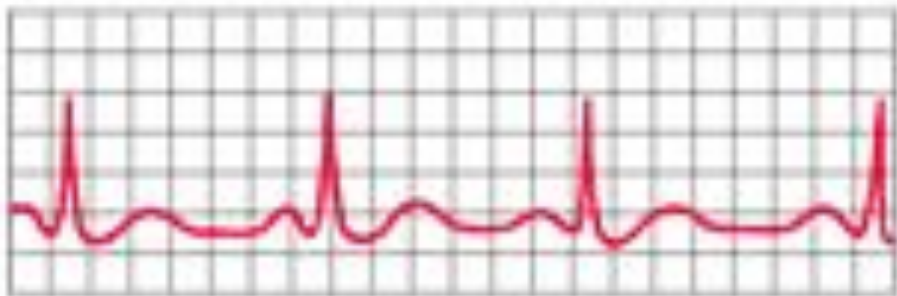
Normal



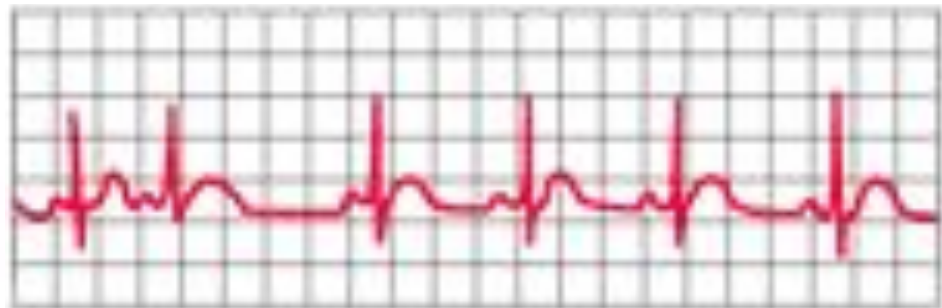
Tachycardia - Fast



Bradycardia - Slow



Irregular

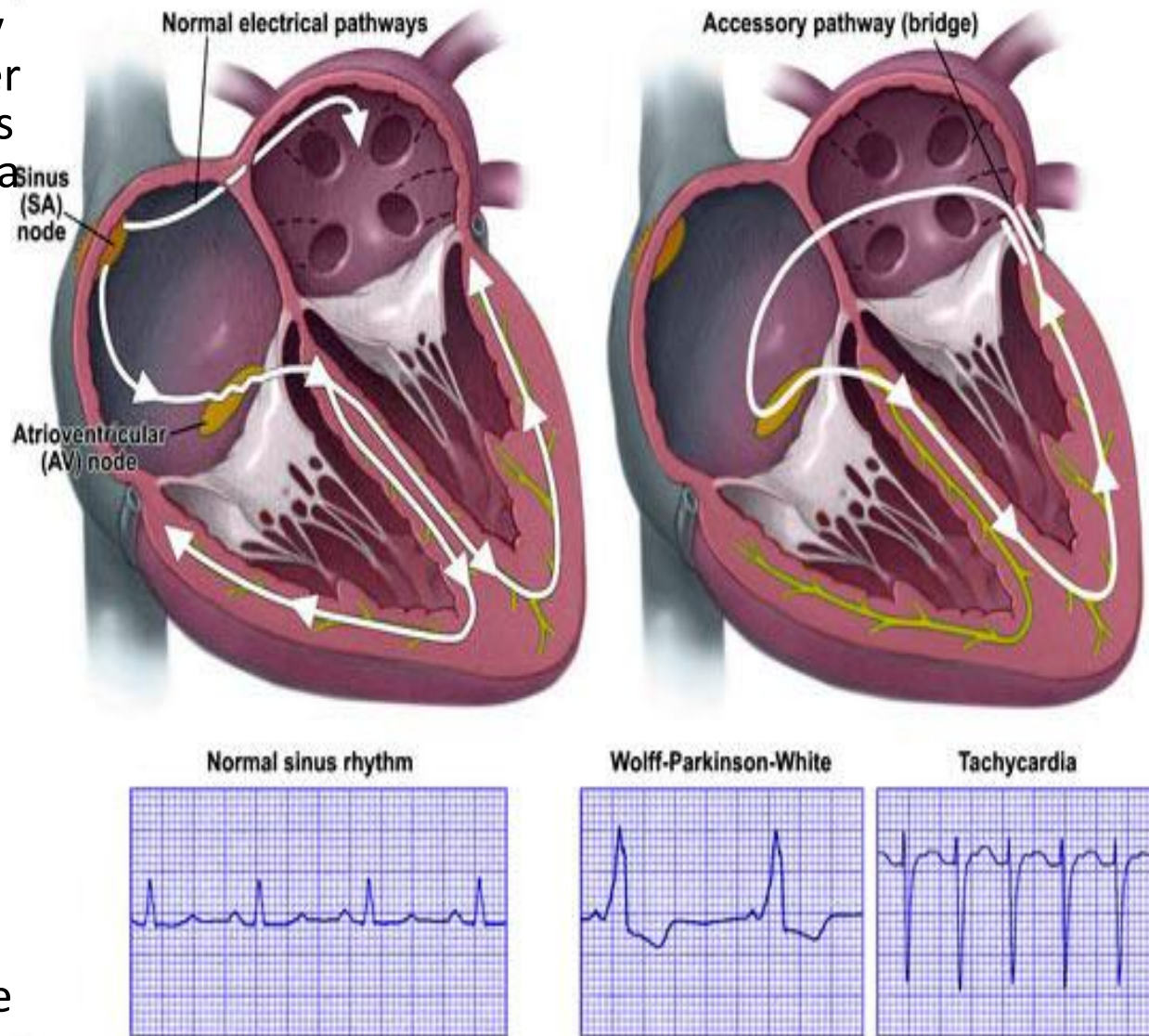


Wolff-Parkinson-White (WPW) Syndrome

An extra electrical pathway between your heart's upper and lower chambers causes a rapid heartbeat. The extra pathway is present at birth and fairly rare.

WPW syndrome is **defined** as a congenital condition involving abnormal conductive cardiac tissue between the atria and the ventricles that provides a pathway for a reentrant tachycardia circuit

The accessory bridge is called the **bundle of Kent**. It runs along the wall of the left ventricle.



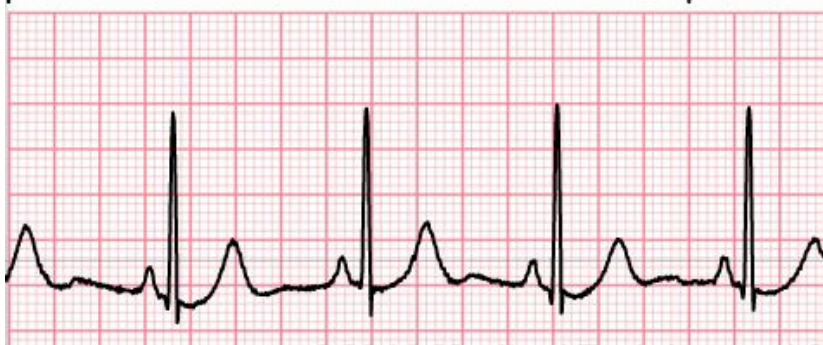Wolff Parkinson Wright Syndrome (WPW)

<https://www.youtube.com/watch?v=9MDRKId2d0Q>

- Write information from the video and label the 2nd heart on your worksheet.
- Record the information of the electrical circuit of WPW

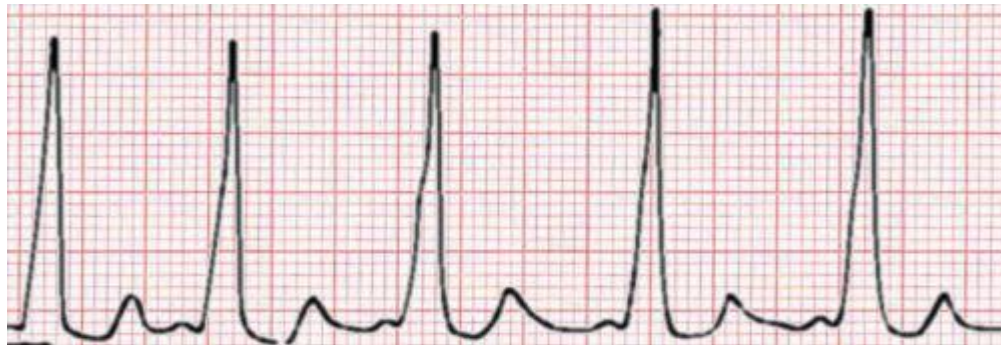
Accessory pathway

Normal



Bundle of Kent

Wolff Parkinson White Syndrome



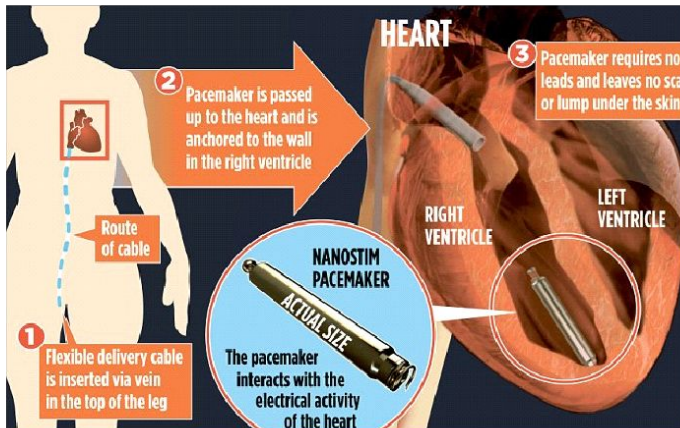
The AAA pacemaker: It's the size of a small battery and takes just seven minutes to fit... so could this revolutionary device give new heart to millions?

By ALICE SMELLIE
25 January 2014

- The new pacemaker is called the 'Nanostim'.
- Six Britons have been fit with the new pacemaker.
- The new pacemaker is ten times smaller than the traditional pacemaker
- It takes 10 minutes to fit. The traditional pacemaker takes 45 minutes to fit.

The first six British patients have been fitted with a wireless pacemaker – smaller than an AAA battery – that is expected to change the treatment of heart disease.

Traditional pacemakers have not changed much since 1958. Traditional pacemakers control the heart beat by sending electrical impulses into the heart using leads from a battery pack. The battery pack is put under the patients' collarbone.



Pacemaker Article



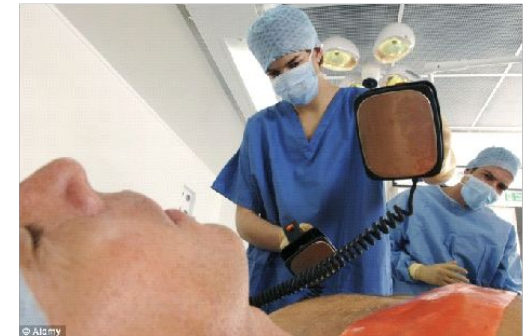The Nanostim has no leads and is ten times smaller than the traditional pacemaker. The nanostim sits in the right ventricle of the heart. It takes under ten minutes to fit. The traditional pacemaker took 45 minutes to fit.

The new pacemaker is put into a vein in the leg and is then pushed up to the heart by the surgeon. When the new pacemaker is inside the right ventricle, it is screwed into the wall. This keeps it in the same place.

The leads on traditional pacemakers sometimes caused clots and infections. This could be very dangerous. The new pacemaker has no leads and this makes it much safer.

Maureen McCleave, 77, has already had a new pacemaker fitted. She was surprised because it only took 10 minutes to fit. As soon as it had been fitted she felt much better.

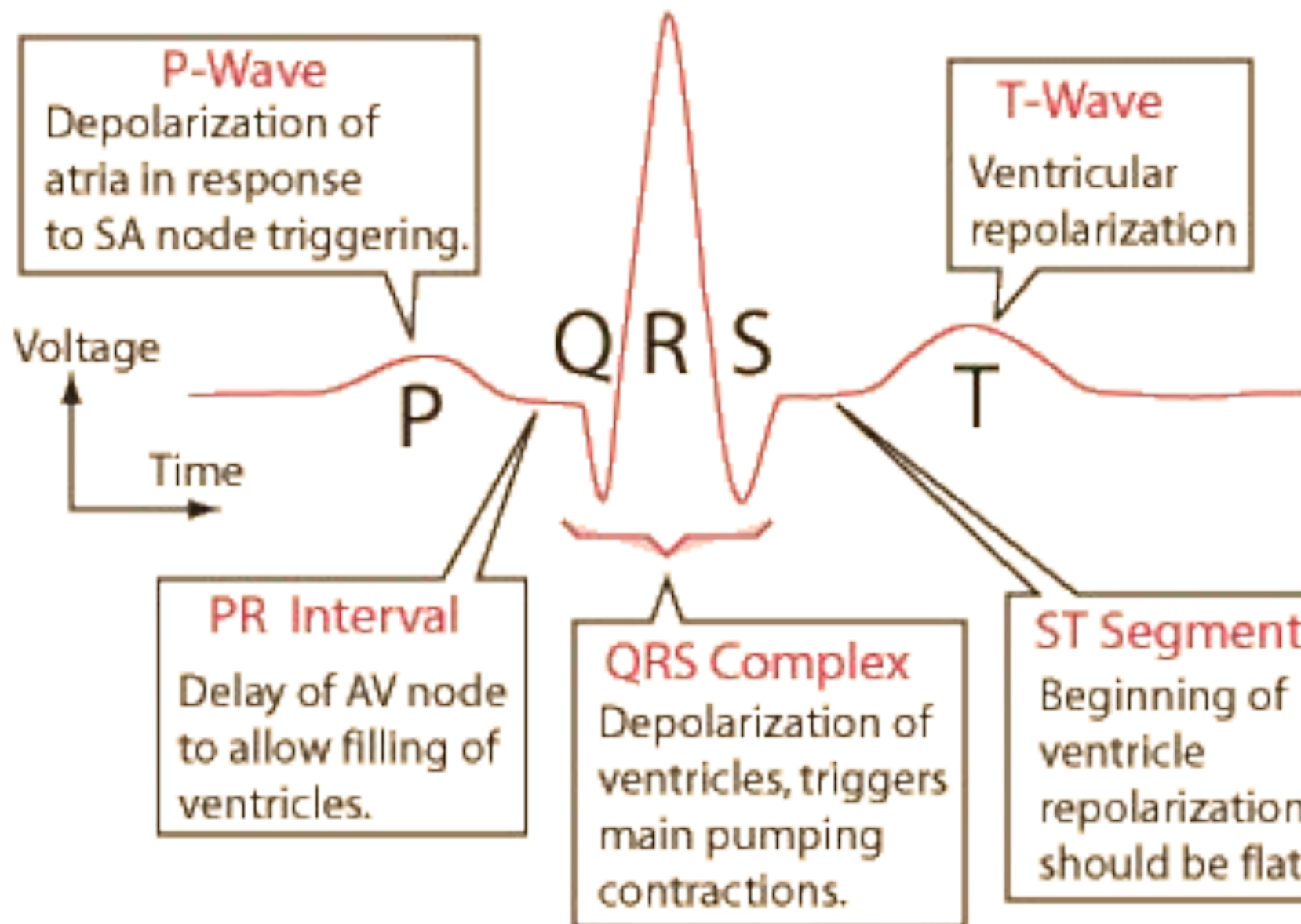
Last year, more than 40,000 Britons had a pacemaker fitted. They are used to treat people who have problems with their heartbeat. A person might need a pacemaker if their heart beats too fast or too slow. They might also need a pacemaker if their heart does not beat in a normal rhythm.



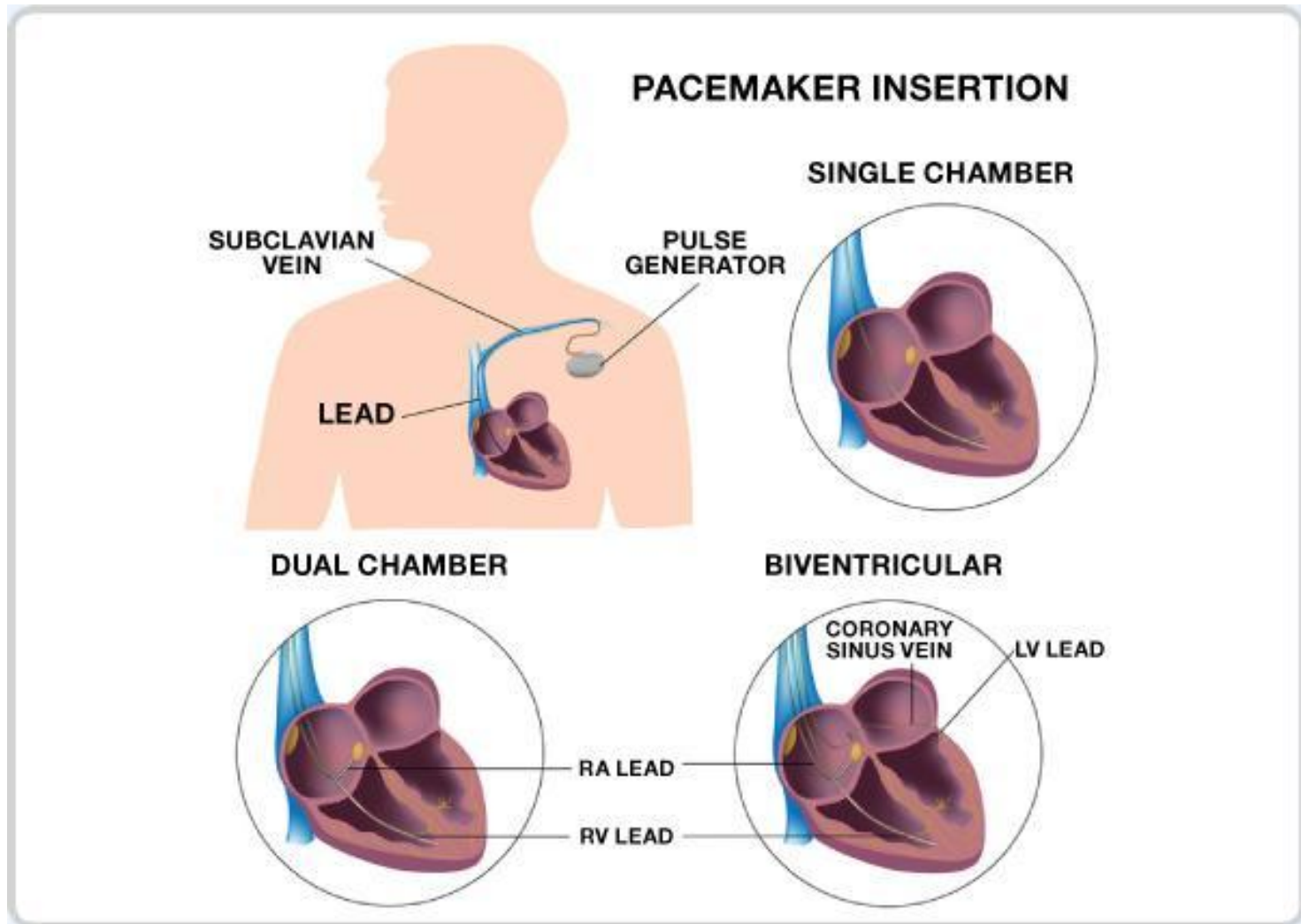
In traditional pacemakers, three electrical leads run into the heart. The pacemaker worked by sending an electrical impulse to the heart down the leads.

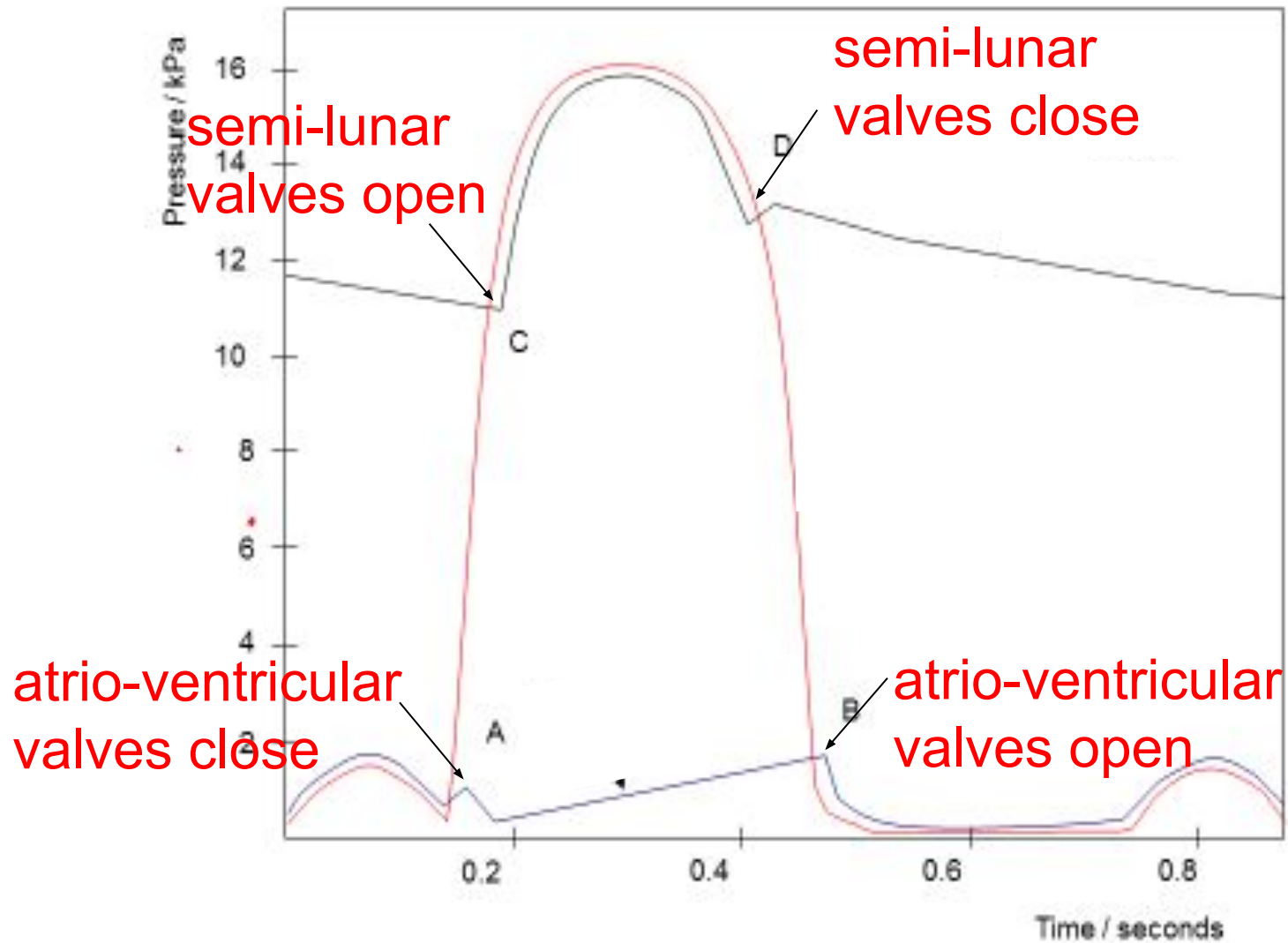
The new pacemaker works by checking the electrical impulses in the heart. If it notices that the heart has stopped beating it releases an electrical impulse. The battery lasts up to 13 years. When the battery runs out, the surgeon puts in another new pacemaker or changes the battery.

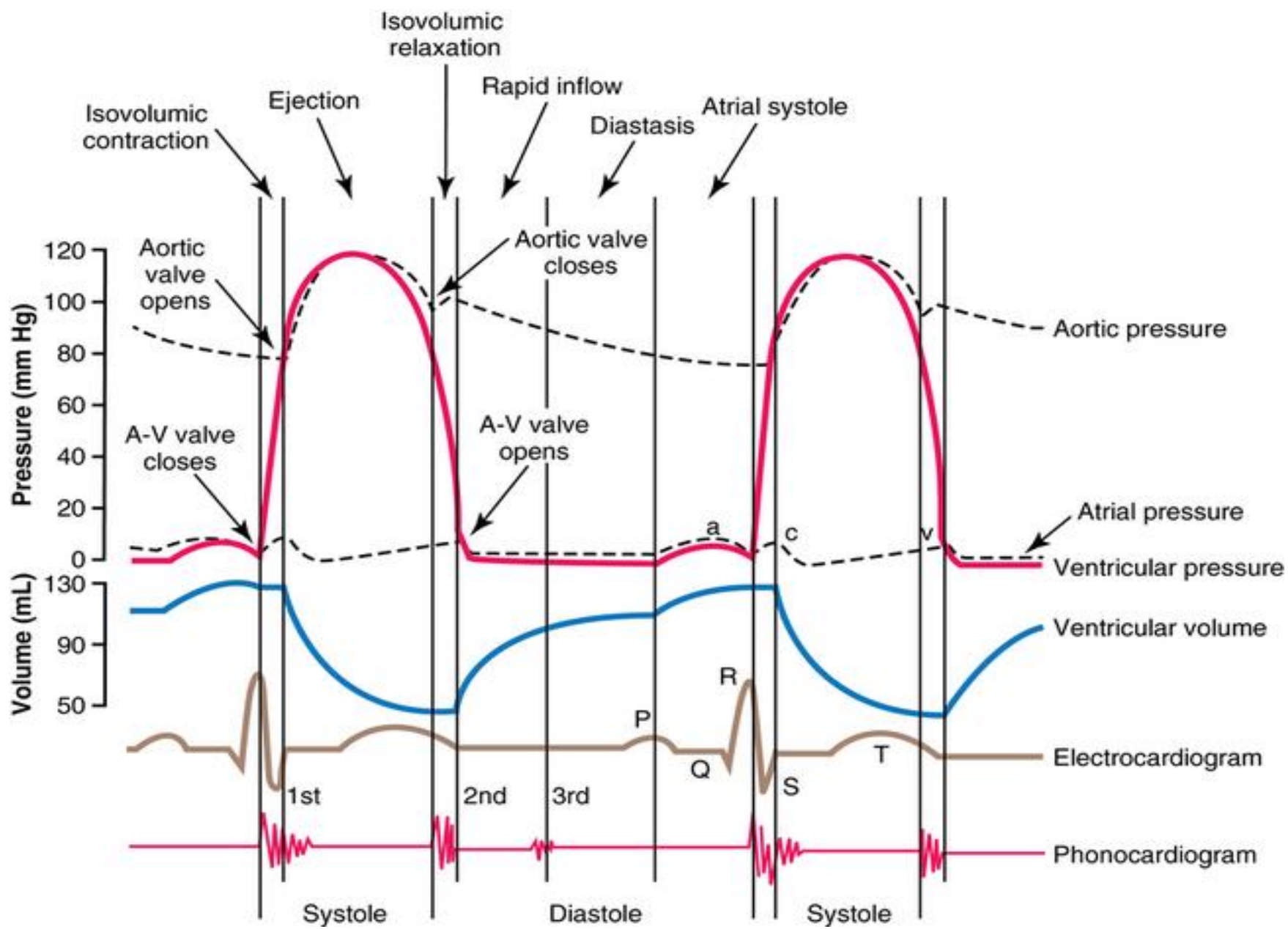
If the new pacemaker fell off the wall of the right ventricle it would not be dangerous. If it fell off it would go to the lung and surgeons could take it out.



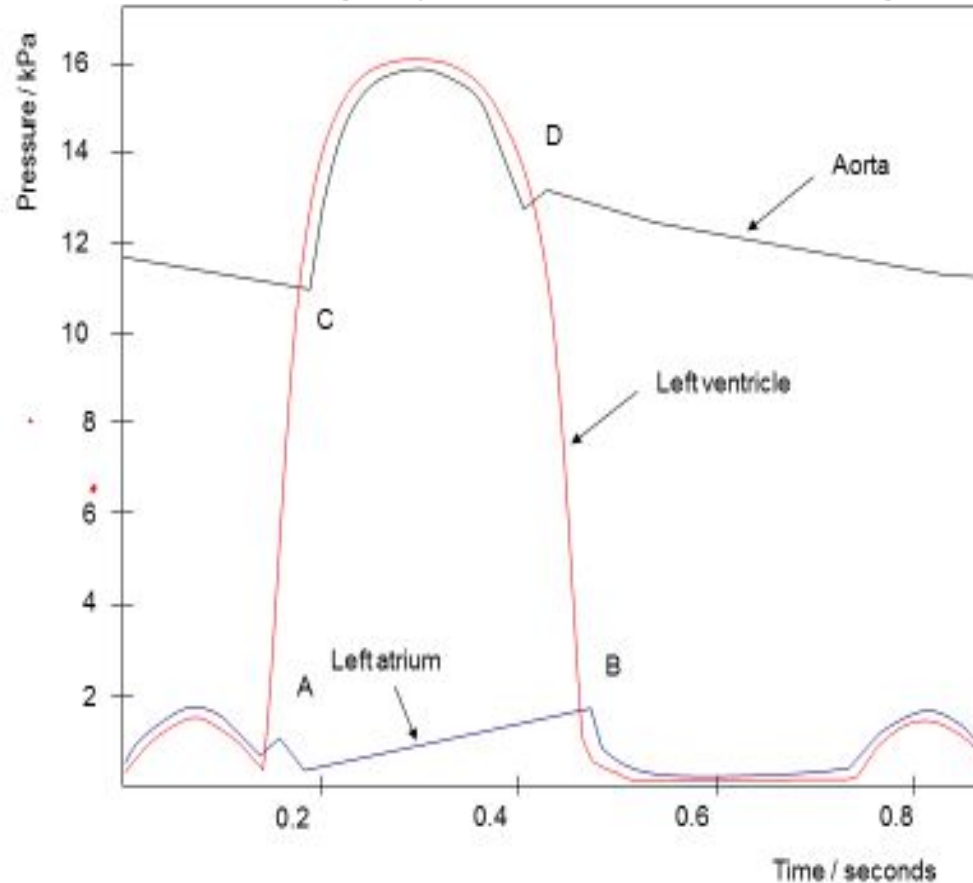
Pacemaker



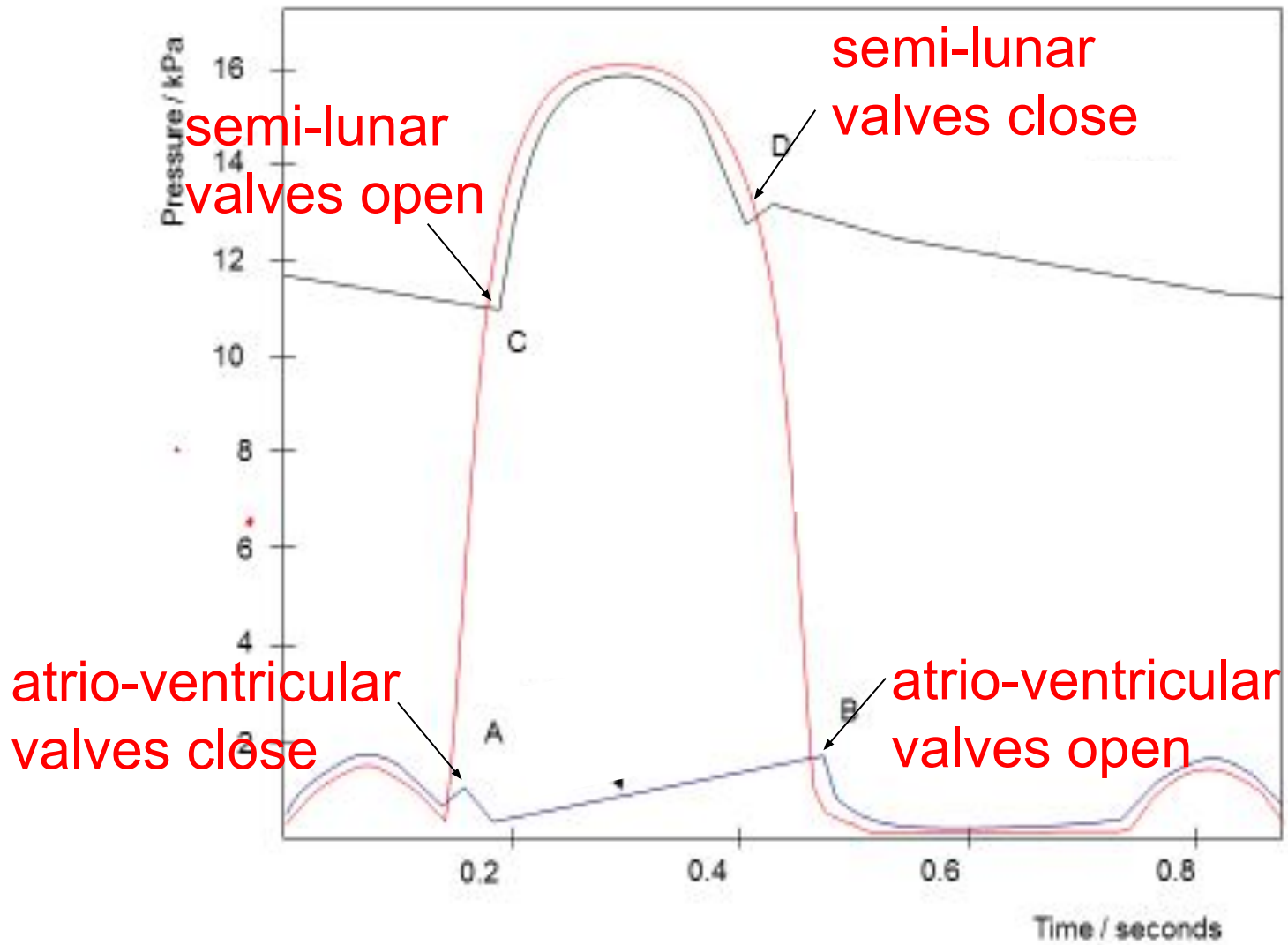




Match the letter on the graph to the following events



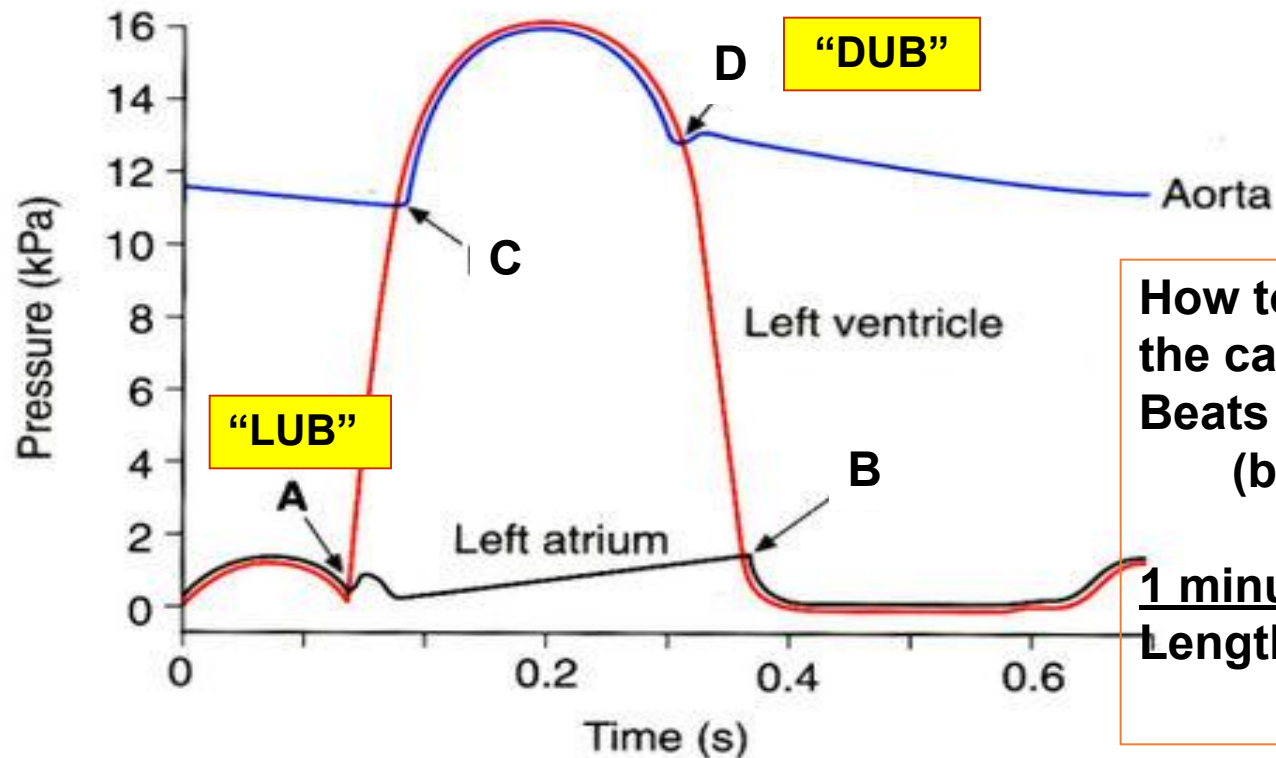
- _____ Semi-lunar valves open
- _____ Atrio-ventricular valves close,
- _____ Semi-lunar valves close
- _____ Atrio-ventricular valves open



Atrial
Systole

Ventricular
Systole

Diastole



- A Atrioventricular (bicuspid / mitral) valve(s) closes ("snaps shut"– makes 1st louder heart sound "LUB"
- B Semilunar valve(s) (aortic valve) opens
- C Semilunar valve(s) closes – makes second softer heart sound "DUB"- shut due to blood accumulating in their pockets
- D Atrioventricular (bicuspid) valve(s) opens

THE HEART – Electrical activity, ECG and EEG

You tube clips to down load or watch

<https://www.youtube.com/watch?v=8aLufvkRw-k> - Shows the heart and ecg trace

<https://www.twig-bilim.kz/film/heart-976/> - Revision of structure and function

On your own electrical one 7 min

<https://www.youtube.com/watch?v=zBj6btjdYHU>

<https://www.youtube.com/watch?v=RYZ4daFwMa8>

Electrical activity in heart

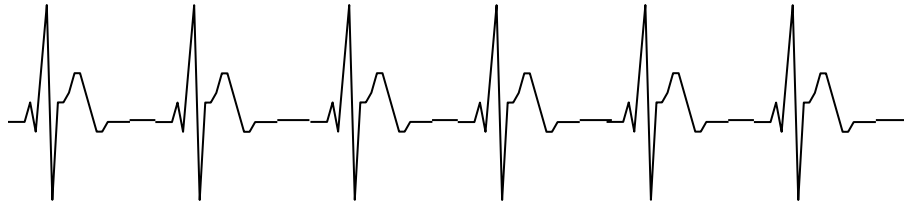
https://www.youtube.com/watch?v=bO-_Ztlxcr0 – Showing how EEG is done

<https://www.youtube.com/watch?v=HX7L11rhRTw> – Diagnosing epilepsy. Interesting.

Extra Information

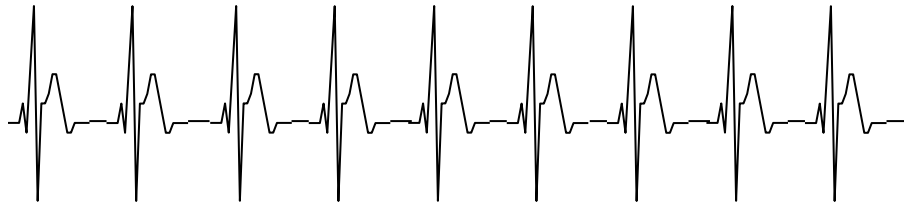Tachycardia

Normal – for reference



6 beats per 5 seconds 72
= bpm

Tachycardic

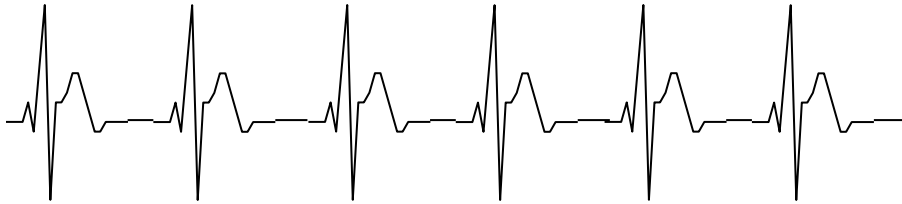


9 beats per 5 seconds = 108
bpm

- Increased heart rate is a normal response to:
 - exercise
 - excitement
 - stress
 - drugs e.g. caffeine, nicotine, amphetamine (speed).
- Tachycardia is elevated heart rate for no reason.
- Sometimes heart rate is so high that little blood is actually pumped:
 - filling time too short.
- Treatment might involve:
 - relaxation therapy
 - β -blocker.

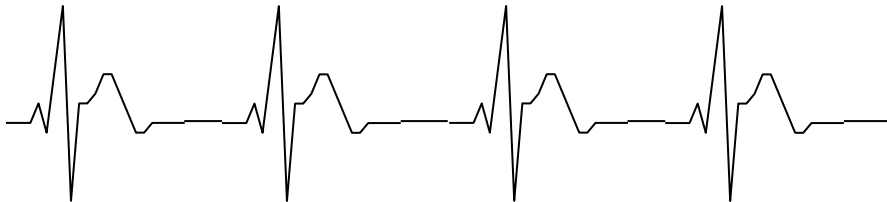
Bradycardia

Normal – for reference



6 beats per 5 seconds = 72 bpm

Bradycardic

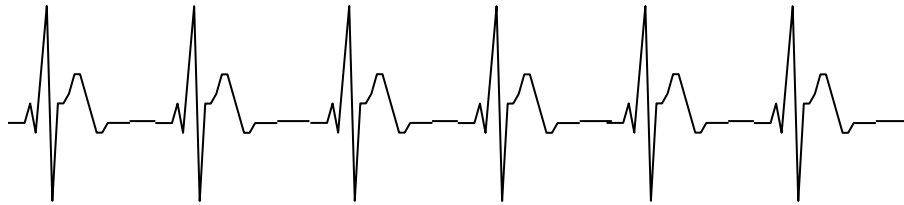


4 beats per 5 seconds = 48 bpm

- Pattern of electrical activity is normal but slow.
- Reduced heart rate could indicate:
 - good aerobic fitness (elite athletes like Steve Redgrave have resting heart of ca. 45 bpm).
 - Alternatively might be caused by drugs:
 - tranquilisers
 - β -blocker.
- Cause may need investigation:
 - stagnation
 - risk of blood clots.

Heart block

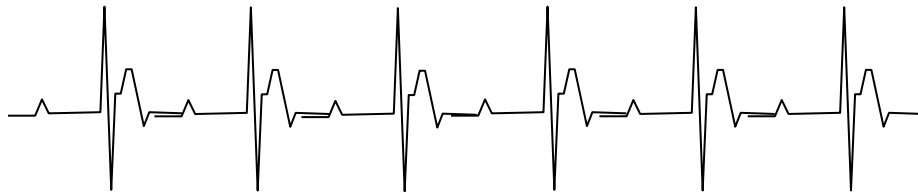
Normal – for reference



6 beats per 5 seconds = 72 bpm

- There is separation of the P wave and the QRS complex.
- Pacemaker activity and atrial contraction is normal.
- Delay in conduction between atria and ventricles.

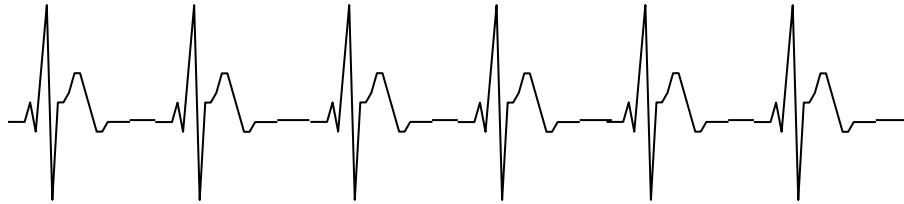
Heart block



Dissociated P and QRS complex

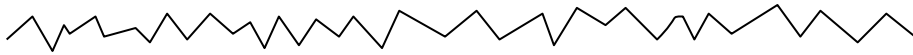
Fibrillation

Normal – for reference



6 beats per 5 seconds = 72 bpm

Ventricular fibrillation (VF)



Uncoordinated and weak contraction

- Contraction of cardiac muscle is normally coordinated.
- In VF the ventricles contract, but it is not coordinated:
 - fluttering
 - little blood is pumped.
- Defibrillation may work:
 - heart is shocked
 - heart stops
 - when it restarts, it may do so with a normal rhythm.

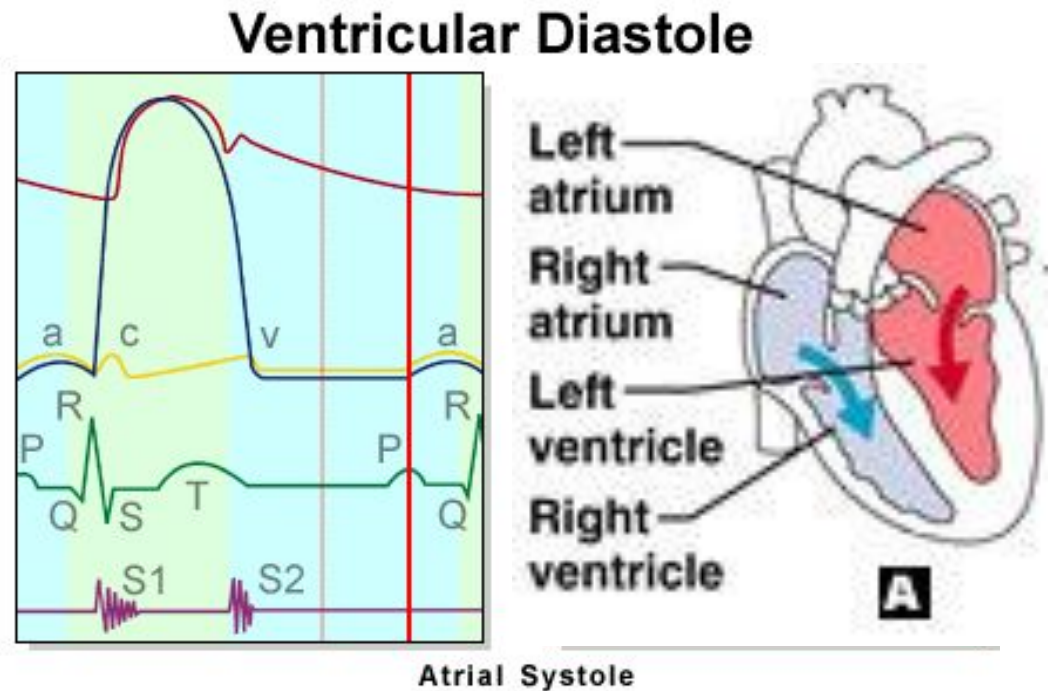
Cardiac Cycle

- General Principles.

- Contraction of the myocardium generates pressure changes which result in the orderly movement of blood.
- Blood flows from an area of **high pressure** to an area of **low pressure**, unless flow is blocked by a valve.
- Events on the right and left sides of the heart are the same, but pressures are lower on the right.

Atrial systole

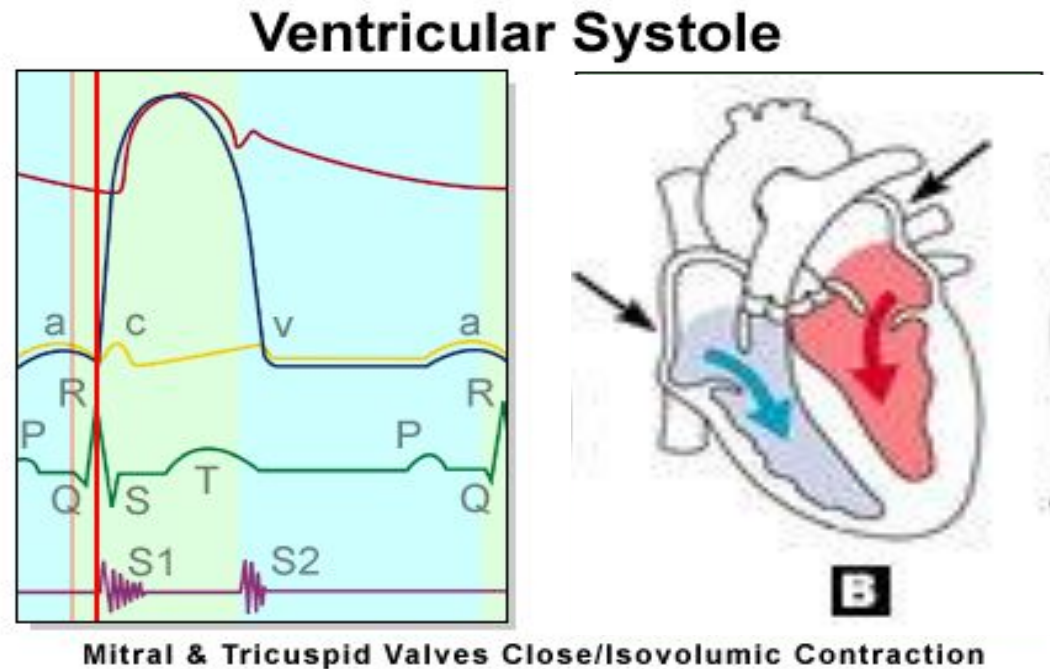
- The heart is full of blood and the ventricles are relaxed
- Both the atria contract and blood passes down to the ventricles
- The atrio-ventricular valves **open** due to blood pressure



70% of the blood flows ***passively*** down to the ventricles so the atria do not have to contract a great amount.

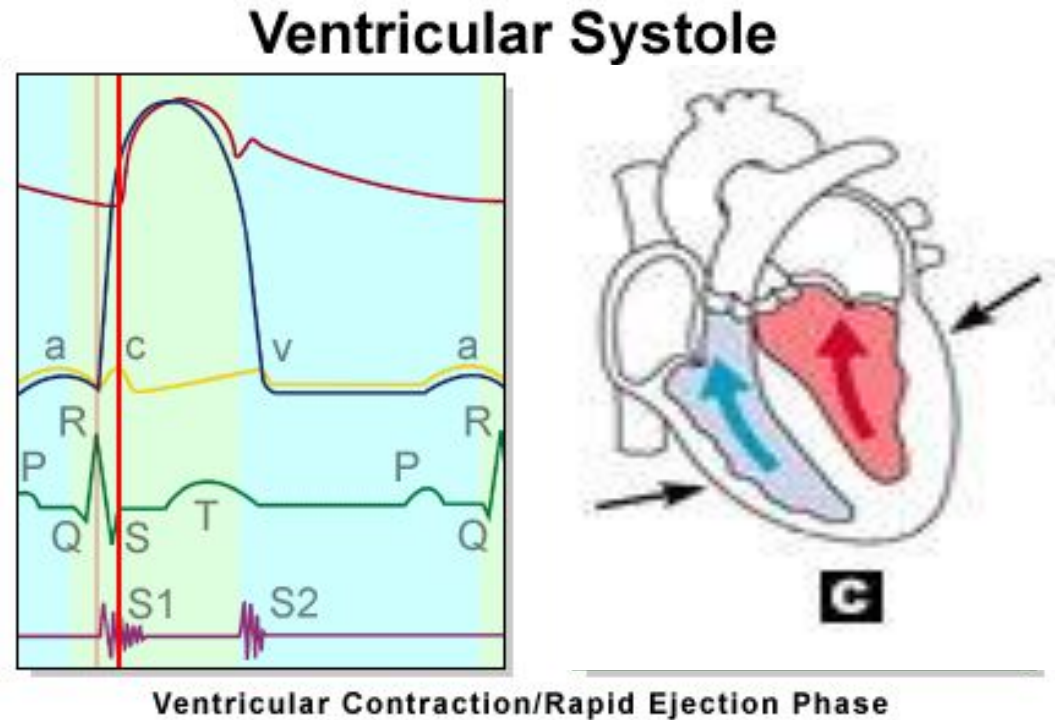
Ventricular systole

- The atria relax.
- The ventricle walls contract, forcing the blood out
- The pressure of the blood forces the atrio-ventricular valves shut (producing the heart sound 'lub')



Ventricular systole

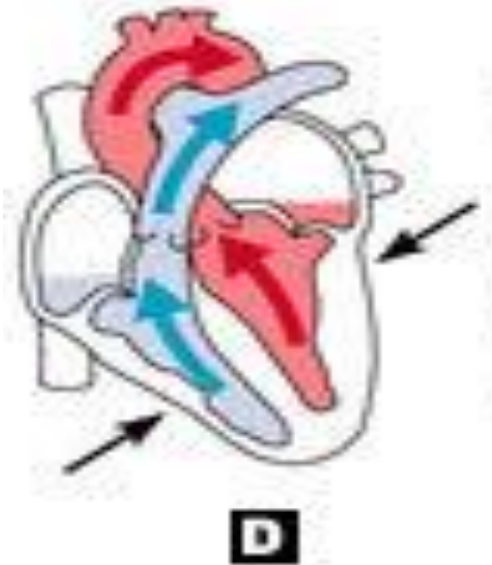
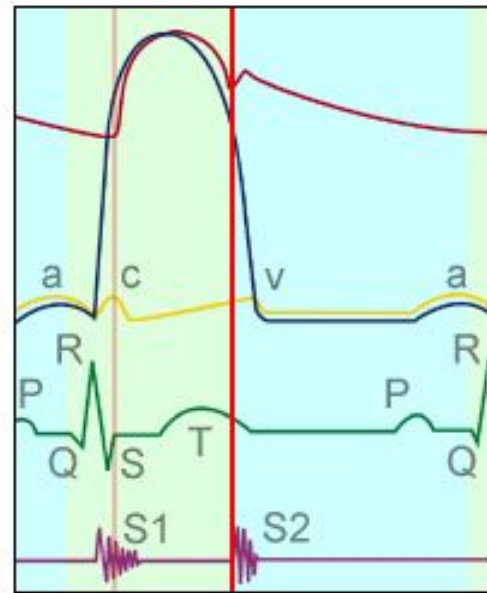
- The pressure of blood opens the semi-lunar valves.
- Blood passes into the aorta and pulmonary arteries.



Diastole

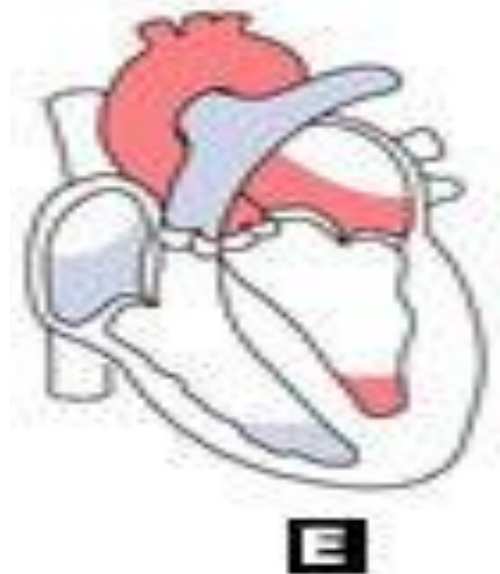
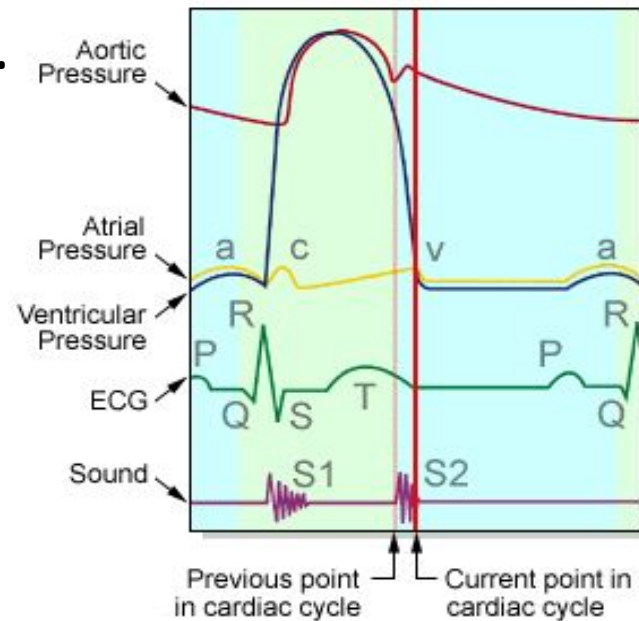
- The ventricles relax
- Pressure in the ventricles falls below that in the arteries
- Blood under high pressure in the arteries causes the semi lunar valves to **shut**. This produces the second heart sound, 'dub'.
- During diastole, all the muscle in the heart relaxes.

Ventricular Systole

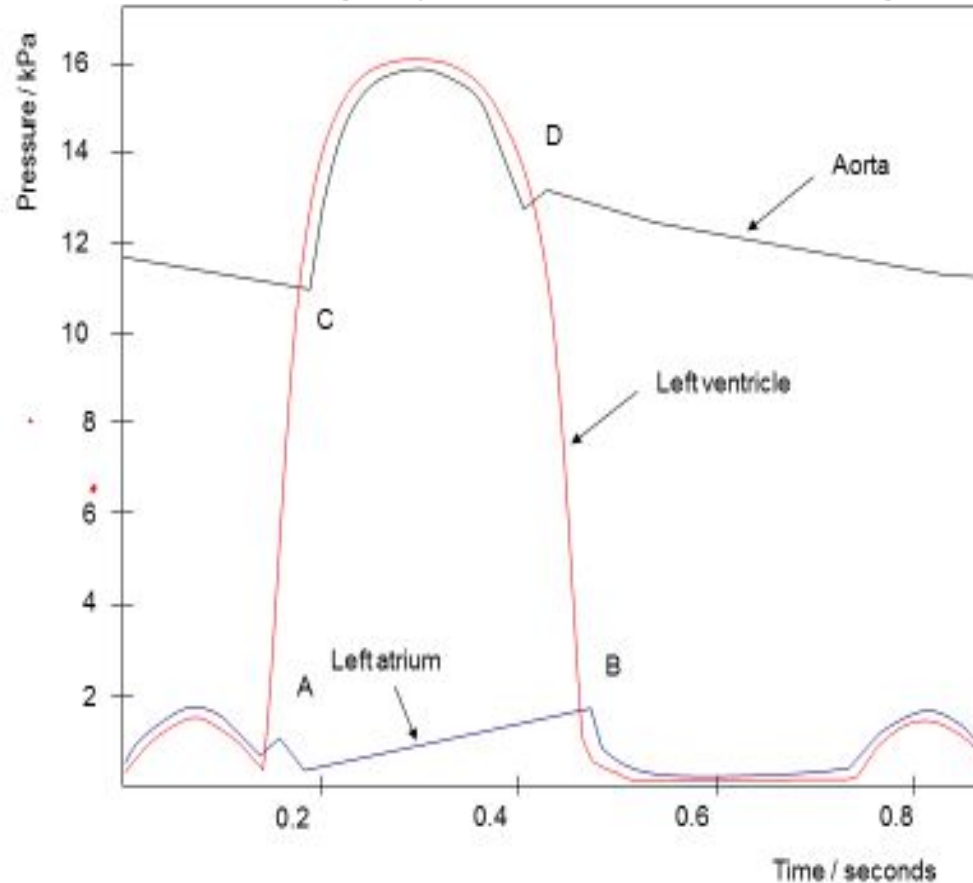


Aortic & Pulmonic Valves Close/isovolumic relaxation

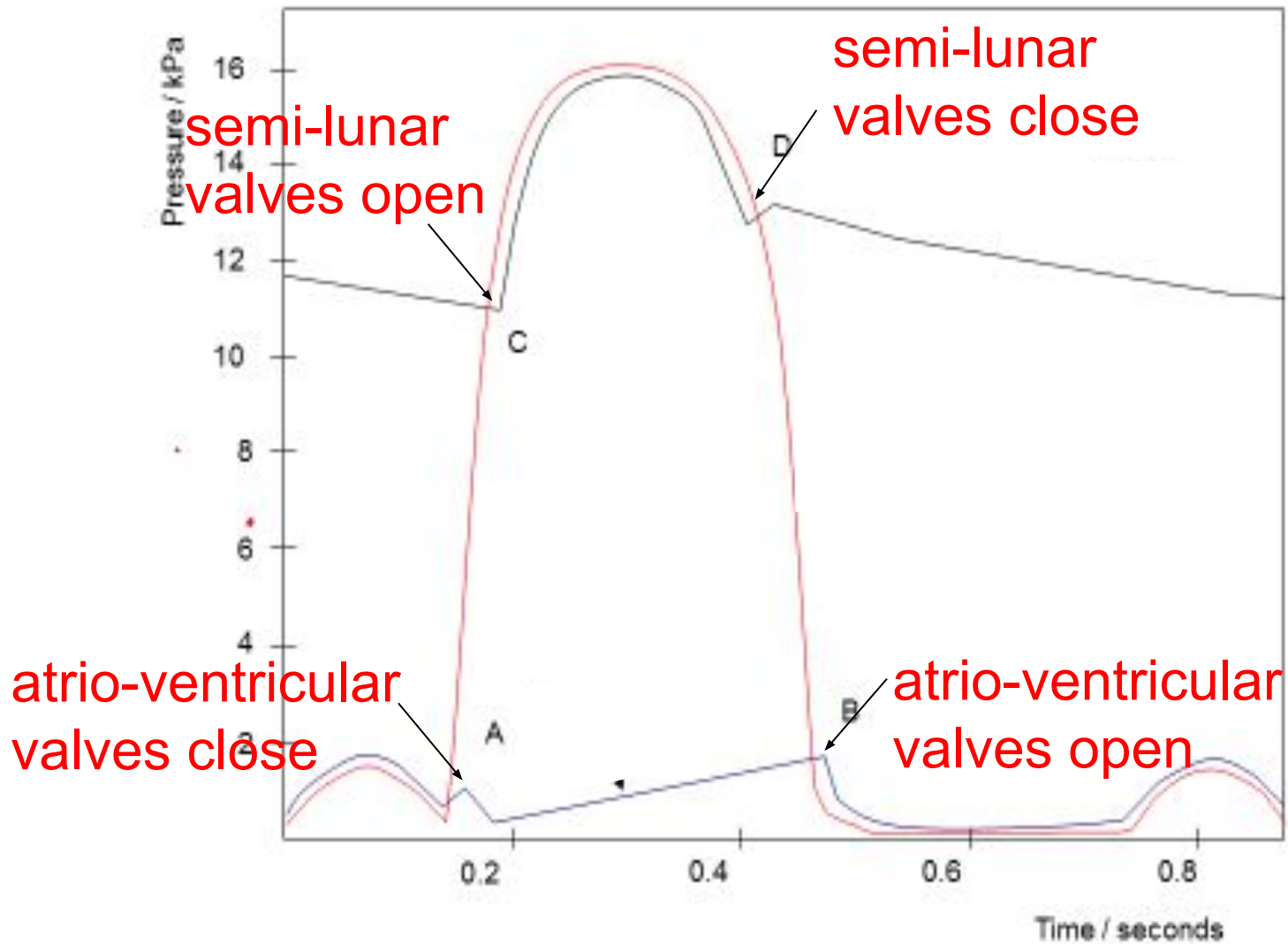
- Blood from the vena cava and pulmonary veins enter the atria.
- The whole cycle starts again.



Match the letter on the graph to the following events



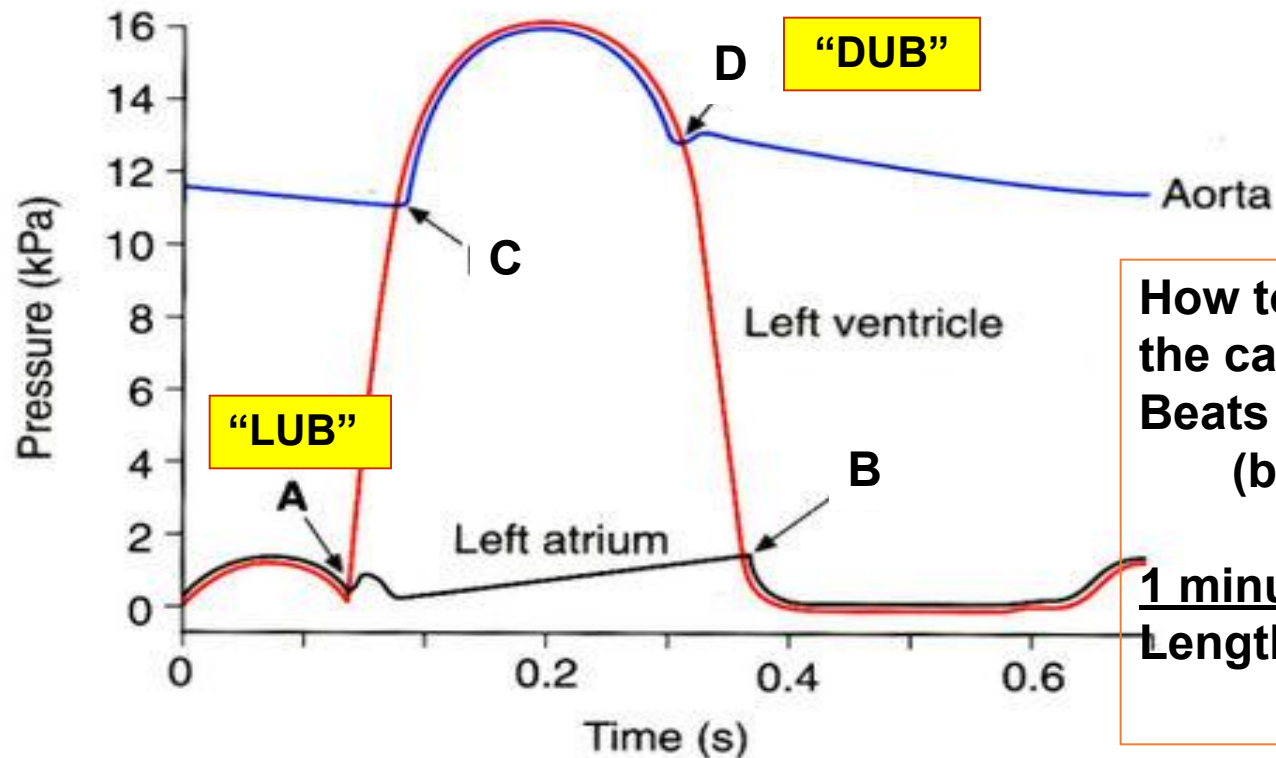
- _____ Semi-lunar valves open
- _____ Atrio-ventricular valves close,
- _____ Semi-lunar valves close
- _____ Atrio-ventricular valves open



Atrial
Systole

Ventricular
Systole

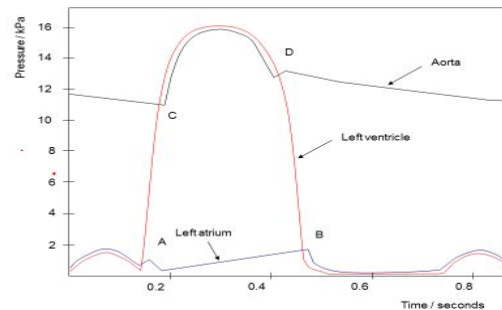
Diastole



- A Atrioventricular (bicuspid / mitral) valve(s) closes ("snaps shut"– makes 1st louder heart sound "LUB"
- B Semilunar valve(s) (aortic valve) opens
- C Semilunar valve(s) closes – makes second softer heart sound "DUB"- shut due to blood accumulating in their pockets
- D Atrioventricular (bicuspid) valve(s) opens

Answer the following questions using your notes and the given graph!

Examine the graph that shows pressure changes in the left ventricle, left atrium and aorta. Then answer the questions:



1. What is the maximum pressure reached in the left ventricle?
2. Why is the maximum pressure in the left atrium lower?
3. What is the length of one cardiac cycle?
4. Using the length of cardiac cycle, what is the pulse rate in bpm? Show your working out.
5. Describe and explain what happens to the aortic valve at points C and D.
6. Describe and explain what happens to the bicuspid (mitral) valve at points A and B.
7. Why is it important that these valves operate properly?

Answers to questions:

What is the maximum pressure reached in the left ventricle?

- 16 kPa. Corresponds to ventricular systole – contraction of the left ventricle reduces ventricle volume and so increases pressure.

Why is the maximum pressure in the left atrium lower?

- Left atrium muscle is much thinner, so cannot generate as much pressure. Does not need to pump the blood very far.

What is the length of one cardiac cycle?

- Approximately 0.75 s

Using the length of cardiac cycle, what is the pulse rate in bpm? Show your work!

- $60/0.75 = 80$ bpm

Answers to questions:

Describe and explain what happens to the bicuspid (mitral) valve at points A and B.

- A Mitral valve closes – pressure in the ventricle > in the atrium.
- B Mitral valve opens – pressure in the atrium > in the ventricle.

Describe and explain what happens to the aortic valve at points C and D.

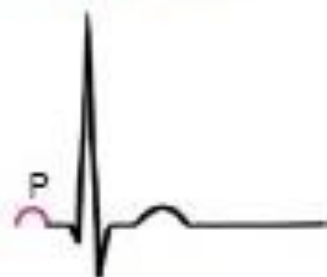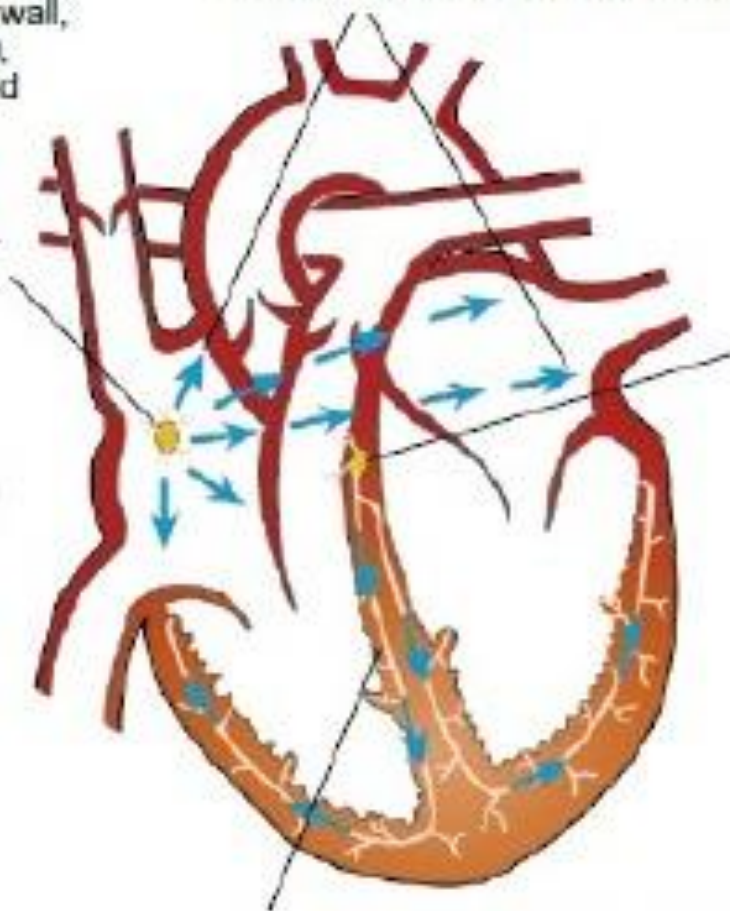- C Aortic valve opens – pressure in ventricle > in the aorta.
- D Aortic valve closes – pressure in the aorta > in the ventricle.

Why is it important that these valves operate properly?

- Ensures one-way flow of blood through the heart/prevents backflow of blood.

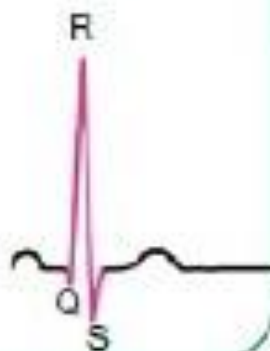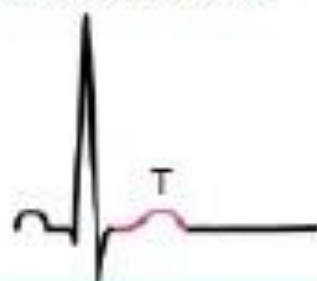
- 1 Each cardiac cycle begins in the right atrium. There is a small patch of muscle tissue in the right atrium wall, called the sino-atrial node (SAN), which automatically contracts and relaxes all the time. It doesn't need a nerve impulse to start it off, so it is said to be myogenic – that is, 'started by the muscle'. The SAN is often called the pacemaker, because it sets the pace at which the whole heart beats. However, the pacemaker's rate can be adjusted by nerves transmitting impulses to the pacemaker from the brain.

- 2 As the muscle in the SAN contracts, it produces an electrical impulse which sweeps through all of the muscle in the atria of the heart. This impulse makes the muscle in the atrial walls contract. The impulse shows up on the ECG as the P wave. So the P wave represents the electrical activity just before atrial systole.

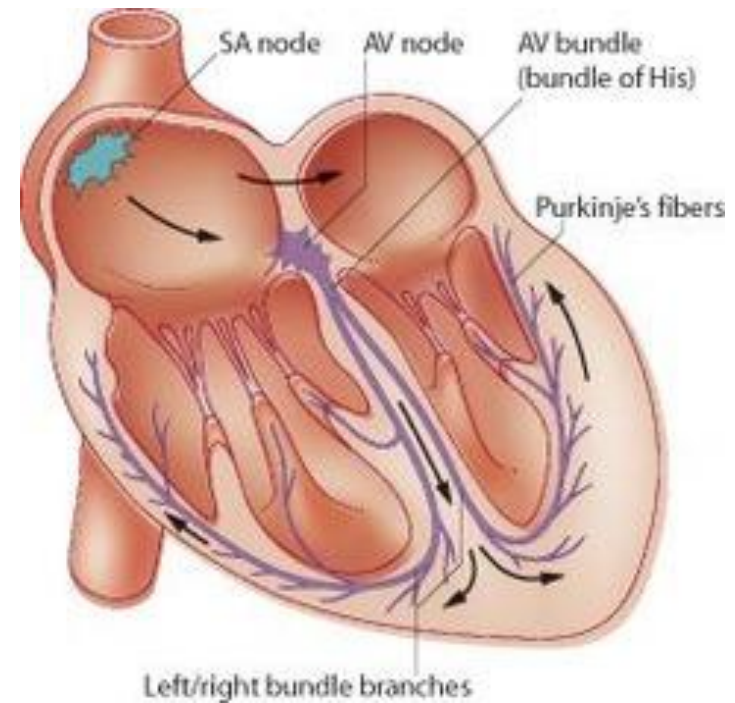
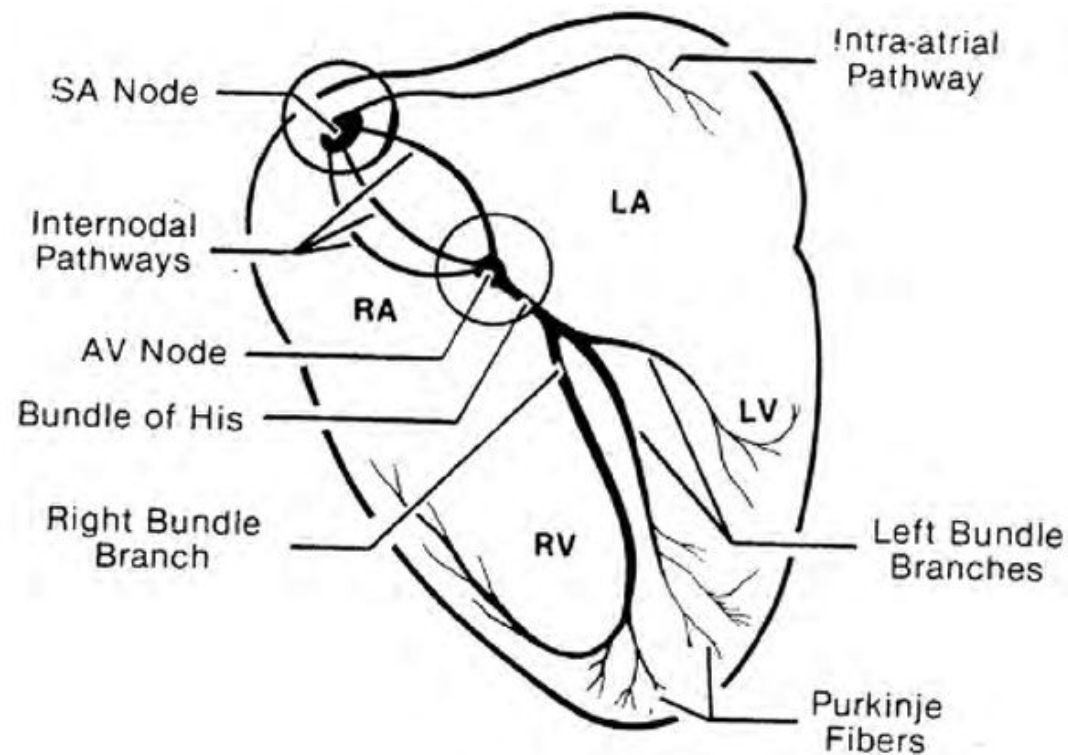


- 3 The impulse swoops onwards and reaches another patch of cells called the atrio-ventricular node (AVN). This node is the only way in which the electrical impulse can get down to the ventricles. The AVN delays the impulse for a fraction of a second, before it travels down into the ventricles. This delay means that the ventricles receive the signal to contract after the atria.

- 4 The impulse moves swiftly down through the septum of the heart, along fibres known as Purkyne tissue. Once the impulse arrives at the base of the ventricles it sweeps upwards, through the ventricle walls. This is shown by the Q, R and S part of the ECG. The ventricles then contract.



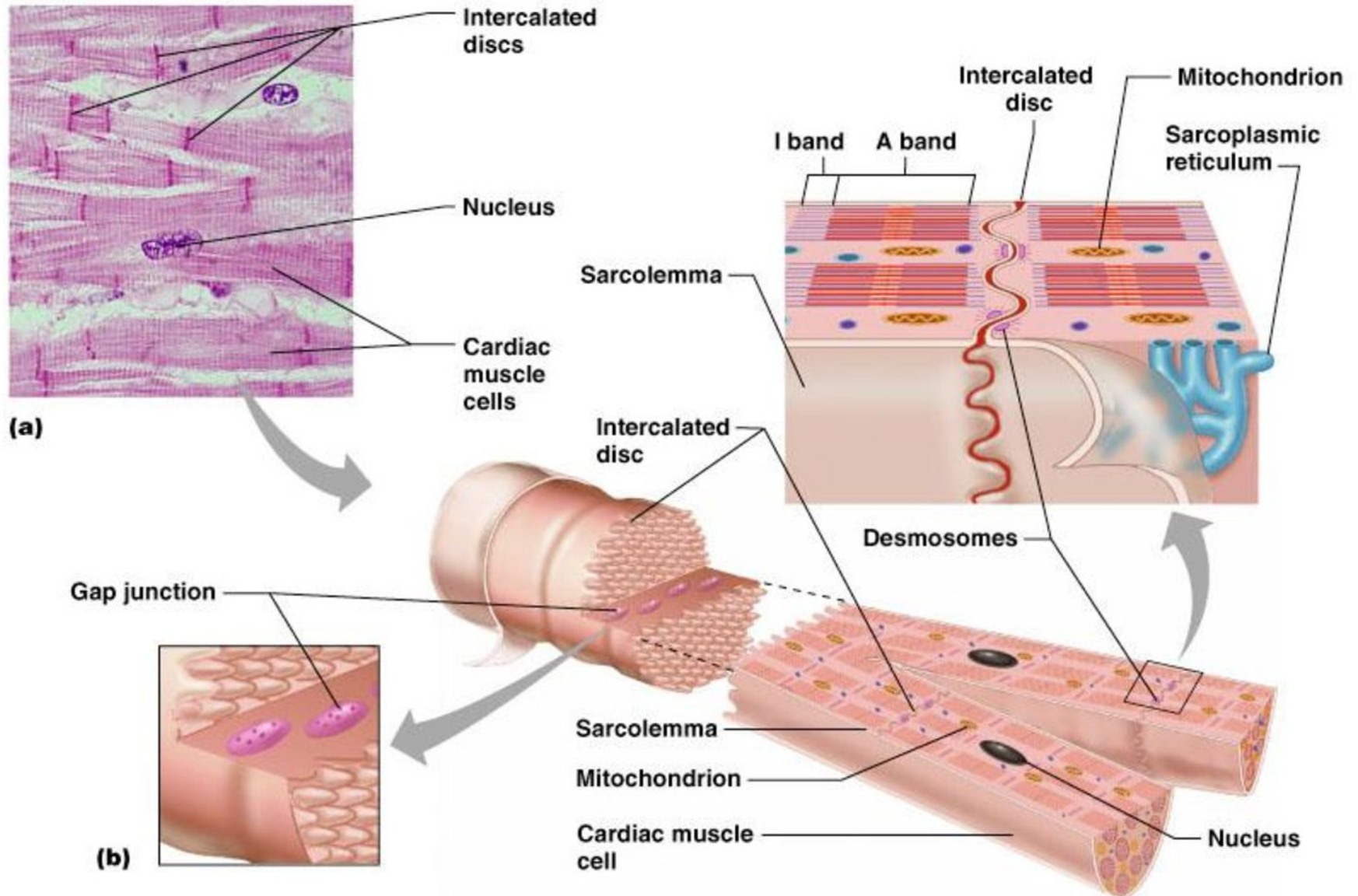
- 5 The ventricles then relax, indicated by the T wave. Then the muscle in the SAN contracts again, and the whole sequence runs through once more.



Electrical Activity In The Heart. The heart's electrical activity begins in the **sinoatrial (SA)** node and flows toward the **ventricles** via **internodal pathways**. From the **AV node** impulses are conducted along the **Bundle of His** and then along the **Purkinje fibers**. The SA node is the heart's **pacemaker**. All the areas of this conduction system initiate impulses, become irritable, and respond to an impulse. Impulses are initiated in each area of the conduction system as shown above.

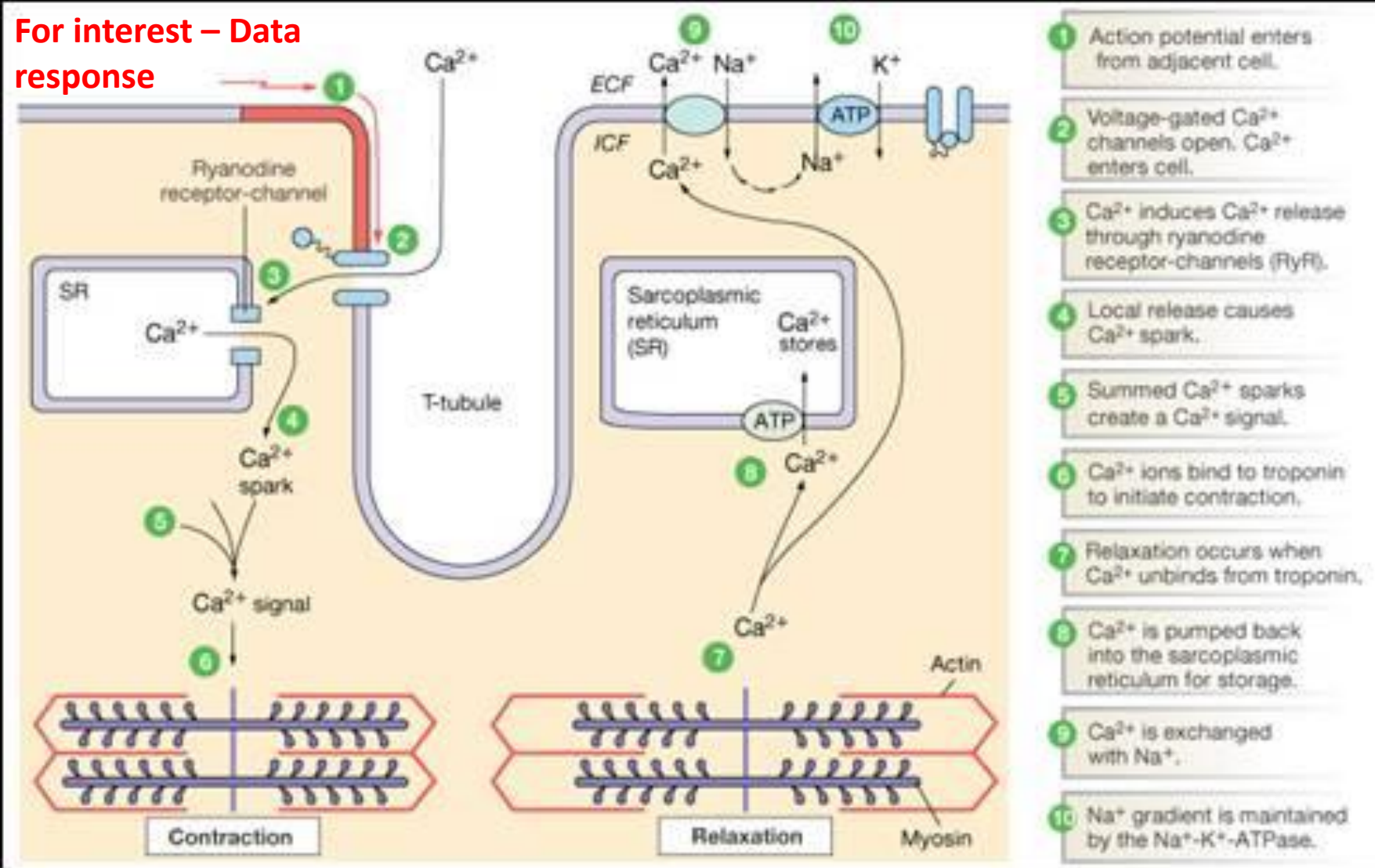
Microscopic Anatomy of Heart Muscle

Only know (a)



How does the structure of cardiac muscle differ from cardiac muscle?

For interest – Data response



- 1) Name the ions involved in cardiac muscle contraction.
- 2) Where does the action potential originate from?
- 3) How do you think the contraction of cardiac muscle differ from that of striated muscle?